

DENTAL TRIBUNE

— The World's Dental Newspaper · Middle East & Africa Edition —

PUBLISHED IN DUBAI

April 2011

No. 4 VOL. 9



News & Opinions
Events in the Middle East

Page 5



Media CME
Diode laser Surface

Page 6



Dental Cafe
Get eco-friendly Bra!

Page 11

WHO takes on global influenza threat

Daniel Zimmermann
DTI

Oberuzwil, Switzerland /LEIPZIG, Germany: Member of a working group set up by the World Health Organisation have agreed upon an international framework to enhance preparedness for influenza pandemics that threaten public health worldwide. The agreement, which is expected to provide clear legal regimes and responsibilities for all stakeholders involved in the prevention and management of pandemics, is the result of more than three years of negotiations which started back in 2007 during the height of the bird-flu influenza virus in Southeast Asia. It is expected to be ratified during the World Health Assembly in Geneva in Switzerland in May.

According to a joint statement, one of the key elements of the agreement will be an improved cooperation and exchange of information between key players such as the WHO, national laboratories and pharmaceutical manufacturers. Access

to live-saving vaccines and other resources for low-income countries which often cannot produce or afford required anti-viral medication for their population is also supposed to be improved.

"This agreement promotes global health security and solidarity in pandemic times," said Ambassador Bente Angell-Hansen, who also chaired the working group. "It also reflects a unique partnership with industry and contains concrete meas-

ures of cooperation with both industry and civil society."

Owing to increasing global transportation, locally active influenza viruses exhibit an increasing potential to become global pandemics that risks the life of many including medical and dental professionals. According to latest estimates of the WHO, the H1N1-virus or swine flu that first occurred in Mexico in early 2009 has killed almost 20,000 people worldwide. [DTI](#)



Periodontal treatment no harm to newborns



NEW YORK, USA/LEIPZIG, Germany: Pregnant women with gum disease may undergo non-surgical periodontal treatment without fear of consequences for their baby's health. In a large trial involving 400 infants between the ages of two and three from different paediatric clinics in the US, dental clinicians found that treating periodontitis during pregnancy did not affect the children's cognitive, motor or language capabilities later in life.

In the study, clinicians from universities in Minnesota, Ken-

tucky, Mississippi and New York compared development data of children born to women who were treated for gum disease before and after their delivery. However, the results between the control and experimental groups only differed slightly. Higher motor and cognitive scores were observed in the children of women who saw an improvement in their periodontal health.

Earlier studies indicated that paternal periodontal treatment

→ [DTI](#) page 5

PROMEDICA

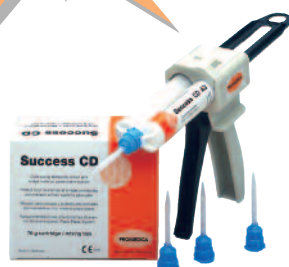Highest quality made in Germany

- ▶ high quality glass ionomer cements
- ▶ first class composites
- ▶ innovative compomers
- ▶ modern bonding systems
- ▶ materials for long-term prophylaxis
- ▶ temporary solutions
- ▶ bleaching products...

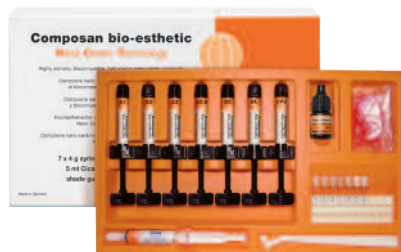All our products convince by

- ▶ excellent physical properties
- ▶ perfect aesthetical results

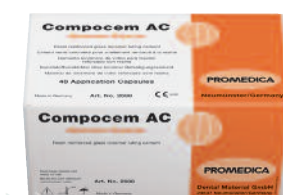Meet us at
several exhibitions -
www.promedica.de



Temporary crown and bridge material
• particular fracture and wear resistance
• now available in 6 attractive shades

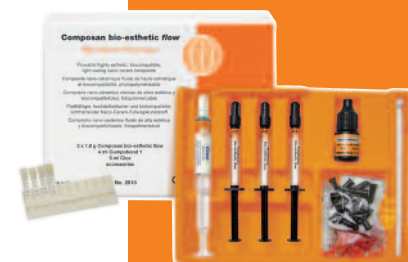

Light-curing nano-ceram composite
• universal for all cavity classes
• comfortable handling, easy modellation
• highly esthetic and biocompatible



Resin-reinforced glass ionomer luting cement
• strong adhesion, very low film thickness
• especially suited for zirconia-based pieces

Nano-Ceram-Technology



• exact match of translucency and shade to the packable Composan bio-esthetic

PROMEDICA Dental Material GmbH
Tel. +49 43 21 / 5 41 73 · Fax +49 43 21 / 5 19 08
Internet: <http://www.promedica.de> · eMail: info@promedica.de

PROMEDICA

AD

Dubai Health Authority signs agreement with Green Crescent Insurance Company



The Dubai Health Authority signed a service level agreement with Green Crescent Insurance Company, today, at the DHA headquarters making Green Crescent the first insurance company in UAE to have direct billing access to the DHAPublicHospitals and PrimaryHealthCareCenters.

The agreement was signed by His Excellency Khalid Al Sheikh

Editorial Board

Prof. Abdullah Al-Shammary, Restorative Dentistry, KSA
Prof. Hussain F. Al Huwaizi, Endodontics, Iraq
Prof. Samar Burgan, Oral Medicine, Jordan
Dr. Abdel Salam Al Askary, Implantology, Egypt

Dr. Talal Al-Harbi, Orthodontist, Qatar
Dr. Mohammed H. Al Jishi, Bahrain
Dr. Lara Bakaeen, Prosthodontist, Jordan
Dr. Aisha Sultan, Periodontist, UAE
Dr. Kamal Balaghi Mobin Aesthetics, Iran

DENTAL TRIBUNE

The World's Dental Newspaper - Middle East & Africa Edition

Published by Education Zone

in licence of Dental Tribune International GmbH

© 2011, Dental Tribune International GmbH. All rights reserved.

Dental Tribune makes every effort to report clinical information and manufacturer's product news accurately, but cannot assume responsibility for the validity of product claims, or for typographical errors. The publishers also do not assume responsibility for product names or claims, or statements made by advertisers. Opinions expressed by authors are their own and may not reflect those of Dental Tribune International.

President/CEO

Yasir Allawi
y.allawi@dental-tribune.ae

Director mCME:

Dr. D. Mollova
info@cappmea.com

Marketing manager

Khawla Najib
khawla@dental-tribune.ae

Production manager

Hussain Alvi
dentalme@dental-tribune.ae

PO Box 214592, Dubai, UAE, Tel + 971 4 391 0257
Fax + 971 4 366 4512 www.dental-tribune.com

AD

كلية نيقولا وآسب الجامعية NICOLAS & ASP UNIVERSITY COLLEGE Dubai - Abu Dhabi

First Postgraduate Dental Institution in UAE

All Programs Accredited by UAE Ministry of Higher Education & Scientific Research

Register NOW...

MASTER DEGREE IN ORTHODONTICS &
MALMO UNIVERSITY SPECIALIST DEGREE
Full and Part Time

MASTER DEGREE IN PEDIATRIC DENTISTRY
Swedish Recognition in Progress
Full and Part Time

NEW

SPECIALITY CERTIFICATE IN ORTHODONTICS
Full and Part Time

NEW

SPECIALITY CERTIFICATE IN PEDIATRIC DENTISTRY
Full and Part Time

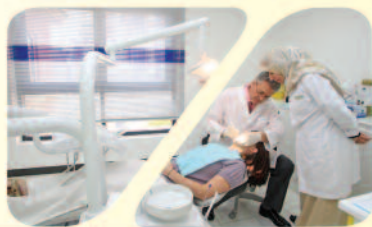MASTER DEGREE IN ENDODONTICS
Swedish Recognition in Progress
Full and Part Time

DIPLOMA IN ADVANCED EDUCATION IN
GENERAL DENTISTRY
Fulfill Experience Requirements
Full Time

NEW

SPECIALITY CERTIFICATE IN ENDODONTICS
Full and Part Time

HIGH DIPLOMA IN ORAL IMPLANTOLOGY
Modular option Available
Full and Part Time



Abu Dhabi Headquarters

Admission Office:
Al Nadi Al Seyahi
Sheikh Omar Bin Zayed Al Nahyan

Dubai Branch

Dubai Healthcare City
Ibn Sina Building (No. 27)
Block D, 3rd floor, Office 302
Telephone: +971 4 3624787

Fax: +971 4 362 4793

P.O. Box: 53382, Dubai, UAE

Website: www.dubaipostgraduate.com

Email: info@dubaipostgraduate.com

Mubarak, Deputy Director General of the DHA and Carl J. Sardegna CEO of Green Crescent Insurance Company.

The agreement provides 110,000 Green Crescent insurance card holders with access to all DHA hospitals and health centres.

Saudi Arabia seeks designers for medical cities

The Saudi health ministry has approached seven expert international firms to design the five medical cities ordered by King Abdullah, the Saudi Gazette has reported. In addition to the medical cities, which will be operational within five years, the number of beds at the ministry's hospitals will be increased by 70% in the next four years, from 54,200 to 54,000 beds at more than 349 hospitals and 2,750 primary care centres.

Qatar set for new oral health strategy

Qatar's Supreme Council of Health (SCH) is creating a national oral health strategy. The strategy is expected to be formulated after completing a nationwide survey on oral health among children and teenagers. Dental caries and periodontal diseases are the most prevalent among schoolchildren and teenagers in the Gulf state. The study, which will begin in the last quarter of this year, will help improve the existing oral health services and programmes in the country as well as assist to monitor the trends of oral and dental diseases in the country, SCH said.

Opening of Al Barsha Medical Centre

Qadhi Saeed Al Murooshid, Director General of the Dubai Health Authority (DHA) laid the foundation stone for the state-of-the-art Al Barsha Health Centre. The centre, which is located in Al Barsha 2, has a built up area of 70,000 sq ft, will be constructed with an investment of Dhs50m. The project will be completed by mid 2012 and will serve a population of approximately 60,000 people living in the vicinity.

Bugs threaten health of orthodontic patients

Daniel Zimmermann
DTI

LONDON, UK/LEIPZIG, Germany: Orthodontic retainers are a potential source of harmful microbes if not properly cleaned, scientists in the UK have warned. In a series of tests conducted at the UCL Eastman Dental Institute in London at least 50 per cent of all tested retainers contained species of *Candida* and *Staphylococcus* micro-organisms, including MRSA, a multidrug-resistant bacterium that can be fa-

tal to patients with a compromised immune system.

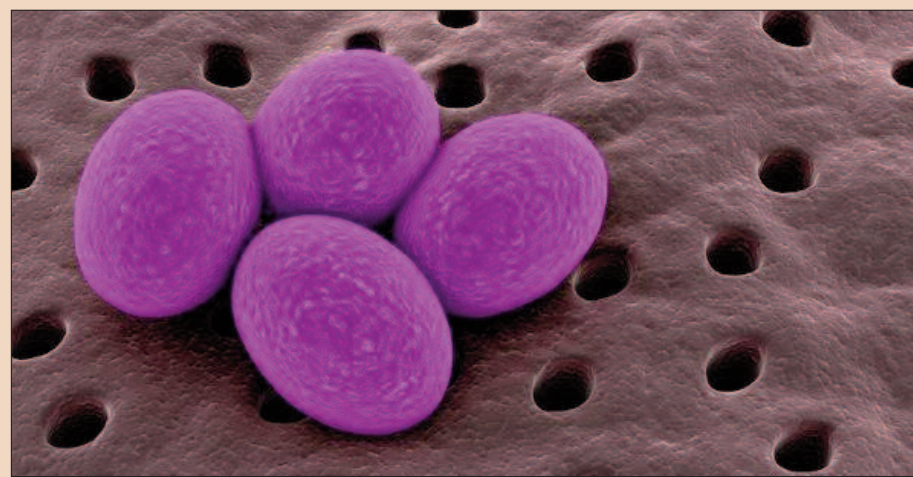
The *Candida* yeast, found universally on human skin and other areas, can also cause infections. Amongst other conditions, it has been associated with oral candidiasis, a condition often related to ill-fitting dentures.

Both species do not normally occur in the oral cavity.

The researchers said that the high number of harmful bacteria found in retainers is most likely the result of poor cleaning, allowing microbes to build up a re-

sistant biofilm and spread to other areas of the oral cavity such as interior cheeks and tongue. The potential for transmission is also high, as retainers are frequently removed and replaced in the mouth by the person who uses it, they added.

They recommend wearers wash their hands thoroughly before and after inserting their retainers. Proper dental hygiene through tooth brushing and the use of mouthwash also helps to keep harmful bacteria from entering the mouth. **DTI**



Iraqi doctors meet in Sharjah

WAM Sharjah, Sheikh Mohammed bin Saqr Al Qasimi, Assistant Undersecretary of Ministry of Health, opened the 6th conference of the International Iraqi Medical Association (IIMA) in collaboration with Sharjah Medical District under the auspices of UAE Health Minister Dr. Hanif Hassan and participation of Royal College of Surgeons in Ireland.

Addressing the medical gathering of 700 doctors of diverse specialisations, Sheikh Saqr said the three-day conference provides an ideal platform for sharing latest medical developments, knowledges and experiences.

About 75 speakers delivered 93 presentations through 18 panel of discussions. IIMA is a non-government organization (NGO) registered with the United Nations and seeks to raising awareness and increasing international exposure of Iraqi physicians and their contributions and services to the global medical profession, working and cooperating with prominent international scientific figures in the medical and healthcare industry. **DTI**

DTI Page 1

may be linked to different medical problems including low birth weight, preterm birth and long-term development delays, as bacteria released during treatment may enter the mother's bloodstream and harm the baby. According to research, pregnant women are prone to gingival bleeding, which is caused by a hormonal imbalance that encourages the growth of certain oral bacteria.

If the new data is verified, pregnant women throughout the US could have their gum conditions treated, confident in the knowledge that it will not have a clinically significant effect on their child's development, the researchers said. A spokesperson of the American Academy of Periodontology said that although the data remains inconclusive, the organisation generally recommends women to maintain their periodontal health during pregnancy.

AD



EMS⁺
ELECTRO MEDICAL SYSTEMS

EMS-SWISSQUALITY.COM

SUBGINGIVAL WITHOUT LIMITS

THE DEEPEST PERIODONTAL POCKETS NOW WITHIN REACH WITH THE ORIGINAL AIR-FLOW METHOD



AIR-FLOW® KILLS BIOFILM
ems-swissquality.com

> Subgingival application of the Original AIR-FLOW® method reduces periodontal pocket depth, removes biofilm, prevents periimplantitis

AIR-FLOW MASTER® is the name of the world's first subgingival prophylaxis unit. With two application systems in one. For sub- and supragingival use with matching handpiece and powder chamber.

Incredibly easy to operate. Uniquely simple to use.

Touch 'n' flow: Highly sensitive 3-touch panel for easy choice of settings.



The inventor of the Original Air-Flow Method is now first to cross the boundaries of conventional prophylaxis.

"I FEEL GOOD"

For more information > welcome@ems-ch.com

Industry veteran honoured with first DT Award

2011 nominations are now open at Dental Tribune website

Yvonne Bachmann
DTI

COLOGNE & LEIPZIG, Germany: Robert Gottlander from Sweden was announced the first winner of the Dental Tribune Industry Leadership Award, an honour for outstanding achievements in dental education and innovation. Gottlander received the award from DTI CEO Torsten Oemus during a recent award reception at IDS Cologne.

Gottlander attended the School of Dentistry at the University of Gothenburg. He started his career at Nobelpharma in 1984, which was later consolidated into Nobel Biocare.

During his time as executive vice president for education and products, from 1986 to 1987, Gottlander was responsible for the internationally acclaimed educational training programme, Nobel World Tour.

Being awarded annually, the Dental Tribune International's Global Dental Tribune Awards aims to recognise outstanding individuals, teams and practices that have an active interest in continuing professional development and staying at the top of the profession.

The audience consists of over 650,000 dental professionals, all readers of the Dental Tribune newspaper, which the net-

work is publishing in more than 25 languages.

Mr Oemus said that 15 categories are now open for nominations including Lifetime Achievement, Innovation in Dentistry or Dental Educator of the Year Award at the Dental Tribune Website (www.dental-tribune.com/awards.) The winners will be announced at this year's Greater New York Dental Meeting in November. [DTI](#)



Torsten Oemus (right) handing over the first Dental Tribune Award to Robert Gottlander. (DTI/Photo Yvonne Bachmann, DTI)

Scientists declare CUS an autoimmune disease



NEW YORK, USA/LEIPZIG, Germany: Patients that suffer from a very rare condition affecting the oral mucosa may soon get relief from new research conducted in the US. In a recent study, scientists from the Tufts University near Boston claim to have found evidence that the so-called Chronic Ulcerative Stomatitis (CUS), characterised by recurring painful ulcers, is mainly caused by an autoimmune response of the body that destroys the binding of cells inside the surface tissue layer of the mouth.

According to the scientist, only a dozen cases of CUS have been reported worldwide since the condition was first clinically identified in 1989 but more patients could be affected due to the extensive testing procedure and low awareness among dental clinicians.

They said although prior it was known that affected patients had specific autoantibodies, researchers were not able to determine how much these actually contributed to the condition.

With help of the new findings, CUS could now be classified as an autoimmune disease in order to allow better management of the symptoms.

Due to its unique resistance to standard medication like corticosteroids, successful treatment of CUS has been achieved only in some cases through hydroxychloroquine, a prescription drug primarily used to prevent malaria as well as to treat rheumatoid arthritis or lupus. By better understanding the mecha-

nisms linking the autoimmune response to ulcerative sores, new treatment approaches could be developed to manage the condition, the scientists said.

So far, CUS has been found primarily in middle-aged Caucasian woman. It can only be diagnosed by surgical biopsy using immunofluorescence microscopic examination in an outside lab. In normal clinical settings it can be taken for oral erosive lichen planus, another more common chronic condition affecting mucosal surfaces and also considered to be an autoimmune disease. [DTI](#)

No Pre-Registration Fee

2011
87th Annual Session

Greater New York Dental Meeting™

Scientific Meeting:
Friday, November 25 -
Wednesday, November 30

Exhibits:
Sunday, November 27 -
Wednesday, November 30

The Largest Dental Meeting/Exhibition/Congress in the United States

FDI Annual World Dental Congress
NEW HORIZONS IN ORAL HEALTH CARE

14 - 17 Sept. 2011

fdi
Mexico City 2011

www.fdiworldental.org
congress@fdiworldental.org

www.fdi2011.org
info@fdi2011.org



Events in the Middle East

CONGRESSES

May 1, 2011 - May 5, 2011 - Dubai, UAE
Dubai Oral & Maxillofacial Surgery Congress
Web: www.iir.dubaiofms.org
Email: meetings@imedex.com
Venue: Westin Dubai Mina Seyahi

May 6, 2011 - May 7, 2011 - Beirut, Lebanon
ITI Congress Middle East
Web: www.iti.org/congressmiddleeast
Email: events@iticenter.ch

May 12, 2011 - May 13, 2011 - Dubai, UAE
5th CAD/CAM & Computerized Dentistry International Conference
Web: www.cappmea.com
Email: info@cappmea.com

DT Group extends to platform

Daniel Zimmermann
DTI

Members of the Dental Tribune International Publishing Group (DTI) met in Cologne recently for the 7th Annual Dental Tribune International Publishers Meeting. The gathering, which is traditionally held prior to IDS, saw new licence partners from Slovenia, the Netherlands and the Czech Republic joining the Group. The largest global dental publisher's network now comprises 28 partners, including Russia, China and India, to name a few.

New features of DTI's online portfolio were also revealed in Cologne. According to Publisher and CEO Torsten Oemus, users of the website www.dental-tribune.com will now be able to post and search jobs and classifieds worldwide and in their respective local markets. He also announced a free app featuring a selection of news articles and videos from the DTI network and in different languages for Apple's iPhone and iPad.

Based in Hong Kong, New York and Leipzig in Germany, DTI currently publishes over 100 newspapers and magazines in 90 countries worldwide. Their offering is extended by online education realised by the Dental Tribune Study Club. [DTI](http://www.dental-tribune.com)

Jun 2, 2011 - Jun 4, 2011 - Istanbul, Turkey
European Academy of Esthetic Dentistry Spring Meeting 2011
"Controversies in Esthetic Dentistry"
E-mail: ersoytabaklar@plazatur.com
Venue: Swissotel The Bosphorus

TRADE SHOW

Jun 11, 2011 - Jun 14, 2011 - Tehran, Iran
14th IranMed 2011
E-mail: info@iranfair.com
Web: www.iranfair.com // www.iranmedonline.com

Jun 19, 2011 - Jun 25, 2011 - Istanbul
87th Congress of the European Orthodontic Society
E-mail: cnidus@cnidus.com
Website: www.cnidus.com
Venue: Istanbul Convention & Exhibition Center (ICEC)

Oct 8, 2011 - Oct 9, 2011 - Istanbul, Turkey
Dental Istanbul
E-mail: info@dentalistanbul.com // bilgi@vestiyer.com.tr
Website: www.dentalistanbul.com // www.vestiyer.com.tr

AD



DENTOFLEX®

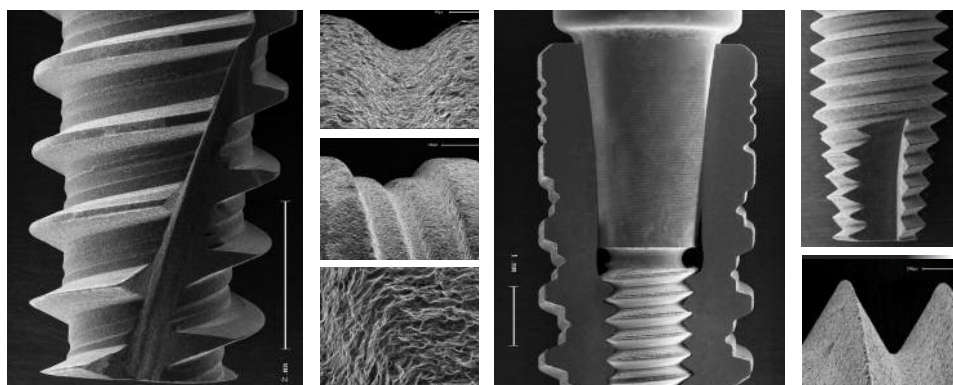
Implant System

For more than 30 years, Dentoflex has been creating healthy and attractive smiles in Brazil, and is now growing all over the world.

Dentoflex goes beyond

Dentoflex has been operating in the dental market for over three decades and doesn't stop reinventing itself. The company is **moving in the right direction by aiming to develop on a daily basis, invest** in the latest technology and expand into new horizons. Dentoflex has an ambition to break down and overcome any barriers and form strong relationships and alliances in countries worldwide.

Treatment Surface



The Dentoflex's surface treatments includes aluminum oxide blasting, followed by acid passivation which combines texture and perfect porosity for an excellent biological effect, and as a result giving conditions for osseointegration and clinical success. The Dentoflex implants offer a more rougher surface of up to 300 times greater than a machined surface, stabilising bone-implant contact by up to six times.



BRANCH OFICCE: JAFZA VIEW - LOB 19 OFFICE 1301 - P.O. BOX 261901 - DUBAI - U.A.E
TEL: +971 (0) 48855404 EXT: 304/305 - FAX: +971 (0) 48855405 MOB: +971 (0) 559250844
comex@dentoflex.com.br www.dentoflex.com.br



Diode laser surface decontamination in periodontitis therapy

(mCME articles in Dental Tribune (always page 6) has been approved by HAAD as having educational content acceptable for (Category 1) CME credit hours. Term of approval covers issues published within one year from the distribution date (September, 2010). This (Volume/Issue) has been approved by HAAD for 2 CME credit hours.

We don't always have the opportunity to provide long-term dental treatment for patients with a profound marginal parodontopathy who have undergone resective surgical therapy, at times including reconstructive work. Correspondingly, there is only a limited amount of literature available due to the aforementioned fact. The number of published studies/other publications is even more limited as regards new therapy concepts or adjuvant treatments to complement a proven therapy regimen. In 1995, the first diode laser (wavelength 810 nm) was presented at IDS in Cologne. This device—initially as a prototype—had been used within the scope of a test phase since 1994. At the end of 1994 patients were treated with this “new” laser wavelength for the first time, which had not been used in dentistry up until that time. The Freiburg laser work group led by Krekeler and Bach, who were the first ones to deal with the integration of diode laser light in dentistry, noticed the considerable advantages of this new technology.

High-performance diode lasers emit monochromatic coherent light at a wavelength of 810 nm. This light is absorbed particularly well by dark surfaces. Thus the injection laser (= diode laser) is ideally suited to perform cuts, as are common in dental surgery, as well as for the removal of benign tumors in the oral cavity, for exposing implants and for use in mucogingival surgery. This excellent cutting performance of the diode laser can be attributed to the exceptional absorption of the laser light by the hemoglobin in the tissue. Aside from an application in soft-tissue surgery, the diode laser is also used for decontaminating surfaces that are colonized by germs (on implants and teeth). It was proven in these applications that especially a gram-negative, anaerobic germ spectrum is sufficiently damaged by the laser light.

The following paper describes—by means of three selected patient cases—our “Freiburg” experience of incorporating laser light decontamination in the therapy of marginal parodontopathies.

Material and methodology

We are presenting treatment results for three patients who received dental treatment over a period of 15 years (12/94-04/10). Initially, these three patients suffered from a profound parodontopathy with inadequate degeneration of supportive tissue. The course of treatment for these three patients proceeded according to the following regimen:

1. Initial therapy (12-1994 through 01-1995)
 - Motivation and instruction of the patient
 - Cleaning and polishing
 - Application of disinfecting agents
2. Resective phase (01-1995 and/or 02-1995)
 - Creation of a mucoperiosteal flap
 - Removal of granulation tissue
 - Decontamination with diode laser light (p=1.0 Watt; tmax=20 sec)
 - Apical shifting of soft tissue
3. Reconstructive phase (01-1995 and/or 02-1995)

Fig. 6 Orthopantomogram after insertion of 3 short implants (“shorties”) in the atrophied left half of the mandible.

Fig. 7 6-year follow-up in 2001.

Fig. 8-11 Clinical findings in 2009, shortly prior to restoration of the maxilla (general view and details).

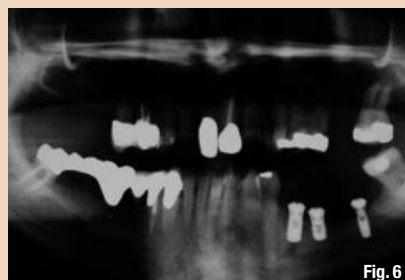


Fig. 6

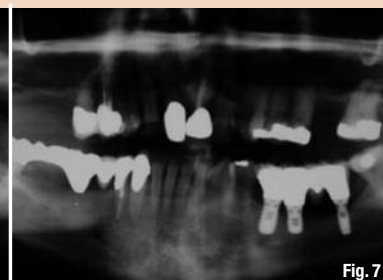


Fig. 7

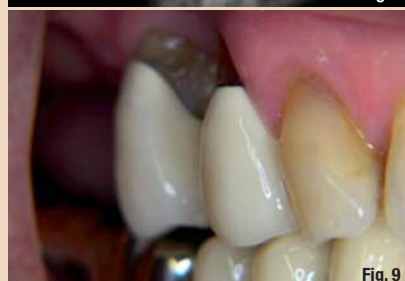

Fig. 9

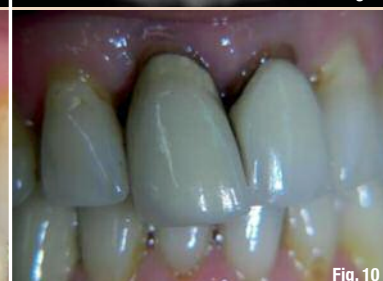

Fig. 10

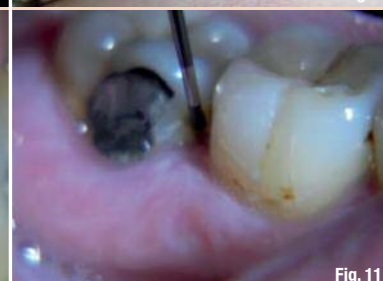

Fig. 11

- Bone augmentation, if required
- Mucogingival corrections, if required

4. Recall phase (from 05-1995 to present)

After 4 weeks, 6 months, 1 year and then annually: complete survey of clinical evidence, X-ray diagnosis, repeated decontamination with diode laser light of exposed root areas, if required.

Imaging procedures

As a general rule, the orthopantomogram (pano ramic tomography) and in special cases/as a supplementary measure dental film images as a parallel technique were the applied imaging procedures.

A-scan and B-scan ultrasonography was also used in a few cases of exacerbated inflammations. An orthopantomogram was taken preoperatively and

immediately post-operatively, and a pano - ramic tomography every three years thereafter.

The distinct advantage of an orthopantomogram is its panoramic view of all teeth, the osseous limbus alveolaris and important adjacent anatomic structures. By comparison, dental film images as a parallel technique provide information about the progression and stagnancy of the issue degeneration, because

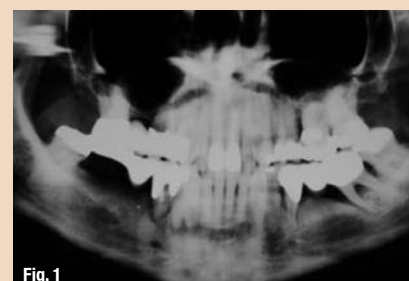

Fig. 1

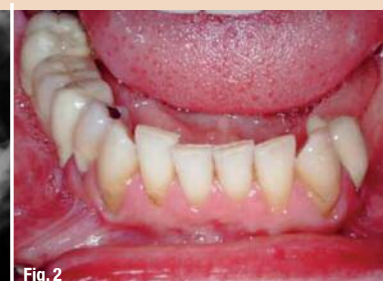

Fig. 2

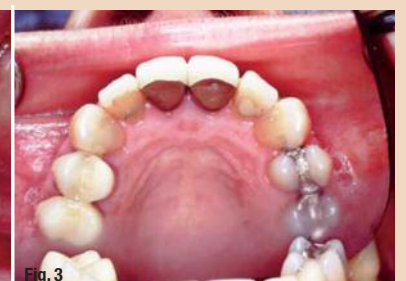

Fig. 3

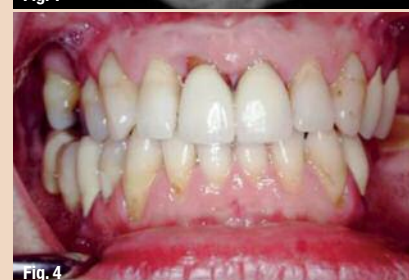

Fig. 4

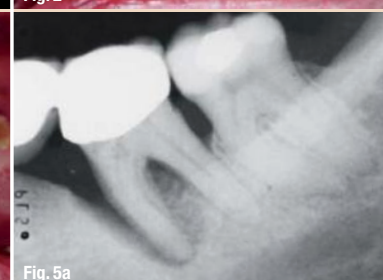

Fig. 5a

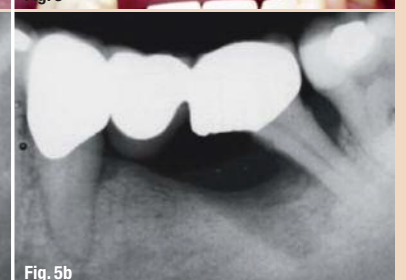


Fig. 5b

they enable statements about the behavior of the limbus alveolaris.

Microbial diagnostics

At the time of diagnostic radiology (see above), germ extractions of the affected areas were also performed. This was not done by way of the conventional microbial examination technique (germ extraction—cultivation—pure cultures—microscopic specimen—gas chromatography—sensitivity to antibiotics and color test strips);

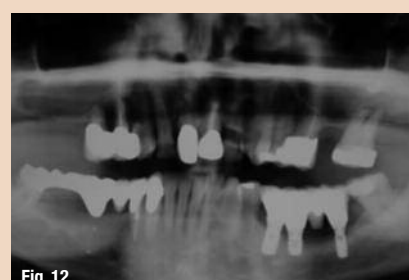

Fig. 12

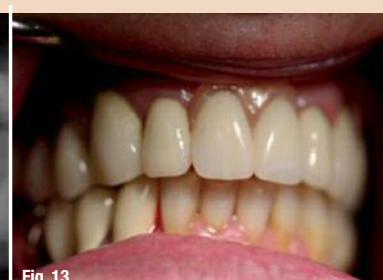

Fig. 13

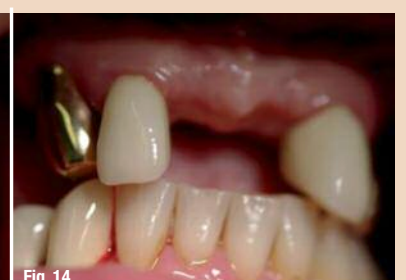

Fig. 14

instead, DNA-RNA hybridization tubes were used.

The advantage of these hybridization tubes was that no live material from the probed areas was required for cultivation, thus reducing work in the dental practice. In addition, the results were available much faster than with the classic microbial examination. The disadvantage of these rapid tests is a relatively high price and the fact that the em-

CASE 1

Fig. 1 Panoramic tomography (emergency service) dating back to 1995—immediately prior to commencement of treatment.

Fig. 2-4 Baseline findings in 1995.

Fig. 5a & b Tooth 37 was not conservable in spite of hemisection (August 1995), resulting in a large edentulous space in the third quadrant (November 1995).

germs and evaluated the so-called marker germ values.

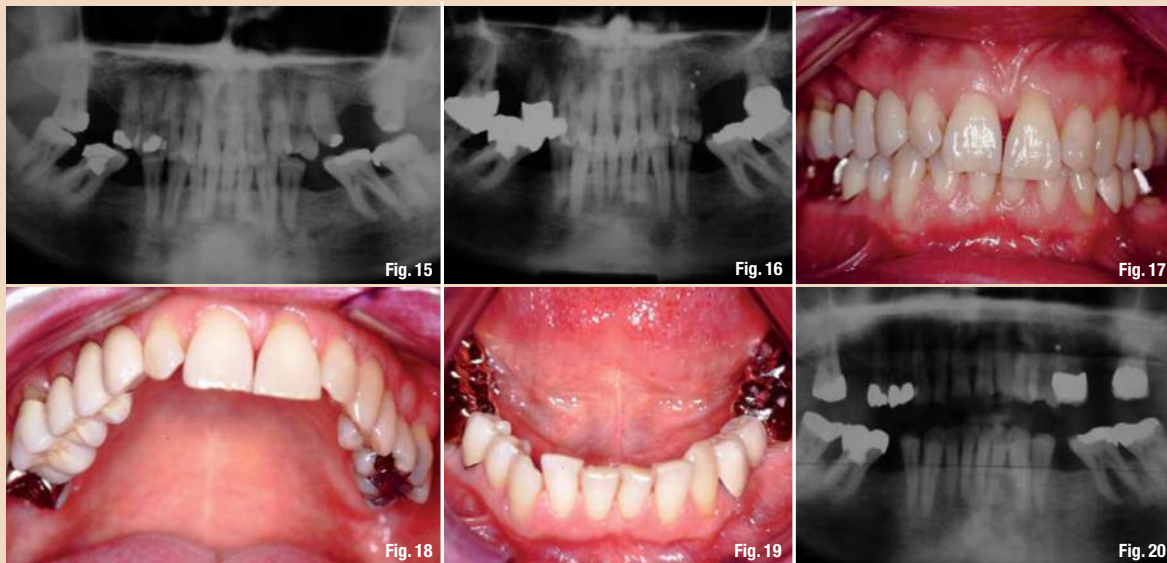
The result was considered negative if less than 0.1 % was identified as a marker germ. The result was considered to be low if 0.1–0.99 % was identified as a marker germ. The result was considered to be medium if 1.0–9.9 % was identified as marker germ and high if more than 10% was identified as marker germ.

Laser light decontamination

Decontamination was an essential part of the overall therapy: It was achieved with diode laser light of 810 nm wavelength, 1 watt of power and an application time of 20 seconds per tooth and implant under fiber contact

Fig. 12 The periodontal lesions (vertical bone degeneration) on teeth 15, 14, 24, 25 are so advanced that these teeth can be considered non-conservable.

Fig. 13 & 14 There are essential modifications in comparison with the baseline findings regarding the maxilla. Some teeth have to be extracted. Furthermore, a removable bridge (telescopic bridge) was inserted.



CASE 2

Fig. 15 Panoramic tomography dating back to 1994—prior to commencement of treatment.

Fig. 16 Initial X-ray image taken in 1995.

Figs. 17–19 Baseline findings in 1995.

Fig. 20 Four-year follow-up 1999.

Fig. 21 Panoramic tomography taken in 2004; dental implants were inserted to increase the number of abutment teeth.

Diagnosis

Most severe form of adult marginal parodontitis having portions with a fast-course component.

Course of treatment 1995–2010

Tooth 37 was extracted within the scope of initial pain treatment, as were teeth 26, 17 and 55. Removable immediate prostheses were incorporated because all three pontic reconstructions had to be destroyed during the extraction therapy. The pretreatment phase proved to be unproblematic; the patient was very motivated and eager to learn the oral hygiene techniques as instructed.

cleaning, motivation and instruction steps, a diode laser light application was always performed. Special emphasis was placed on the periodontally severely damaged premolars and the remaining molar 27.

First re-inflammations of the marginal parodontopathy were noticed in 2009; a curettement of teeth 14, 15 and 27 was performed once again. Due to subliminal but latent discomfort, teeth 15, 14 and 27 were removed at the beginning of 2010 and a new concept for treatment of the maxilla was developed.

A removable telescopic prosthesis (cuspidis are abutment teeth) was incorporated. The prosthesis on the mandible, which has been in place for 15 years, is still there, and there are no signs of a degeneration of the supportive tissue on the natural and artificial abutment teeth.

Epicrisis

Very remarkable in this patient was the considerable amount of trust she had—in spite of bad experiences in the past—in the new laser-assisted therapy concept, which was out of the ordinary at the time. Her compliance was exceptionally good for the entire 15 years. Because of her conscientious oral hygiene and strict adherence to the recall system she remained recur-

2nd Case (Figs. 15–24)

Success due to (laser-assisted) recall case
Male patient, born in 1938.

Medical history

This patient had been treated since childhood by a dentist who passed away in 1991. For some time the patient had been complaining of toothaches and bleeding of the gums, the latter also occurring spontaneously.

He consulted the successor of his former dentist at the dental practice. However, this dentist did not pay much attention to his descriptions (discomfort) and only remarked once that “there is nothing that can be done!”. The patient had obtained the last OPG that had been taken and brought it to the initial examination at our clinic, but he refused (three months later at our clinic) a new

in continuous wave mode. When adhering to these parameters (time limitation and power limitation) it can be guaranteed that the germ spectrum causing the disease can be sufficiently damaged and at the same time that pulpa and/or peri-implant or periodontal tissue structures do not suffer any thermal damage (Bach and Krekeler [1994]).

Three patient cases 1995/2010

Three patients are presented from the original patient group of the “diode laser basic study” (25 patients) from 1995 (Krekeler/Bach, Department of Parodontal Surgery of the University Dental Clinic, Freiburg/Breisgau) who showed “typical progression patterns” and whose treatment illustrates the advantage of integrating diode laser light application into a proven therapy regimen for the treatment of marginal parodontopathies.

CASE 3

Fig. 25 X-ray image dating back to 1994 (requested by a previous dentist).

Fig. 26 Panoramic tomography taken in 1995 (commencement of treatment).

Fig. 27 & 28 Initial clinical images dating back to 1995.

Fig. 29 Follow-up X-ray image taken in 2001 (6-year follow-up).

Fig. 30 11-year follow-up in 2006.

1st Case (Figs. 1–14)

The holding therapy case
Female patient, born in 1954.
Medical history

The patient went to the Sunday emergency service at the Freiburg dental clinic because of pain in tooth 37. A profound parodontopathy was diagnosed there, and the patient came to our department on the following Monday requesting treatment. She had received a complete fixed restoration from her dentist 6 months ago, but without a pre-prosthetic X-ray diagnosis. Ms. D. is a healthy and very health-conscious physiotherapist.

Clinical baseline findings (1995)

Abutment tooth 17 showed a degree of loosening of 2, as did tooth 26 and tooth 45. Mesial probing resulted in profuse, hard to arrest bleeding. BOP and high probing depths were found in general. The interdental spaces had soft deposits, also under the pontics.

X-ray diagnosis (1995)

The panoramic tomography (orthopantomogram) shows severe horizontal and vertical bone lesions. Teeth 55 and 26 have dish-shaped defects. Trifurcation 34 is opened radiologically

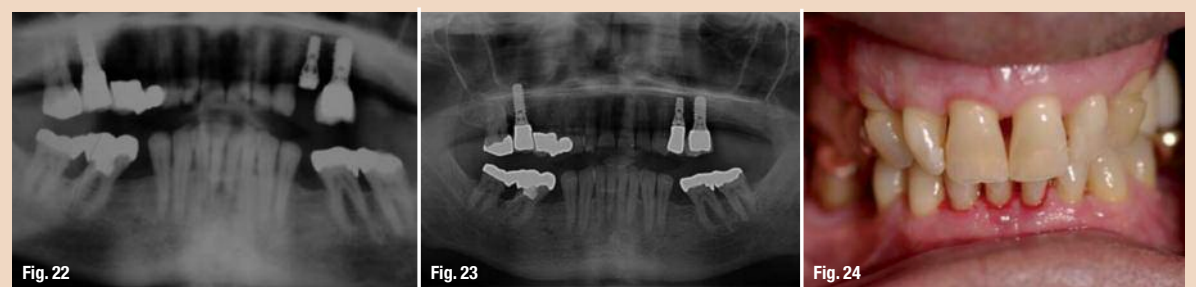


Fig. 22 The principle of increasing the number of abutment teeth is still being pursued twelve years after commencement of treatment (OPG dating back to 2007).

Fig. 23 Current panoramic tomography taken in 2010.

Figs. 24 Clinical images taken in 2010: In the frontal view as well as in the lateral views and both jaw views conditions without irritations prevail for the most part.

From June to August 1995 the remaining teeth were treated with open curettement. She had no recurrence for a long time. She received implants in the third quadrant while the remaining maxillary side teeth received fixed prostheses. The edentulous space in the second quadrant remained at the patient’s request; in the first quadrant, the principle of a shortened row of teeth was realized (up to 5’ to 5th).

This condition was maintained from the end of 1996 to 2008. The patient conscientiously observed all recall appointments. Aside from the usual

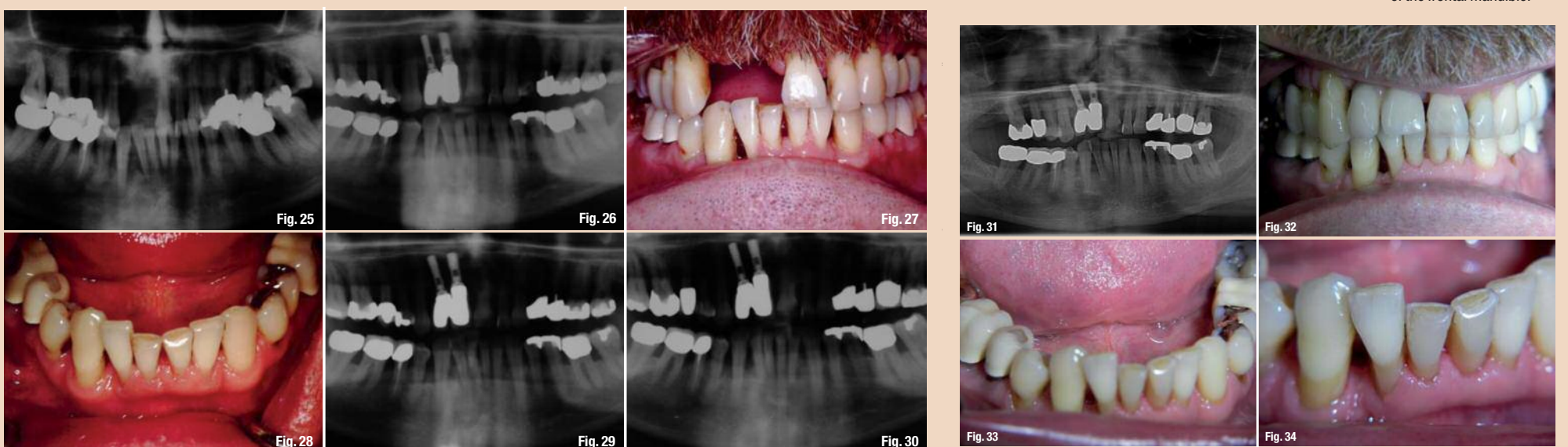recurrence-free for more than a decade. This still holds true for the mandible, while the antecedent massive degeneration of supportive tissue required the removal of three maxillary teeth. Thanks to the diode laser assisted periodontal therapy and the continuous recall, the patient was able to retain the majority of her teeth in the maxilla and the fixed prostheses for a longer period of time. It was only recently that this concept in the maxilla had to be modified in favor of a removable one; however, this occurred 15 years after a similar suggestion (removable prosthesis) had been made by her attending dentist at the time.

X-ray diagnosis, stating that he was completely healthy.

→ DT page 8

Fig. 31 The panoramic tomography taken in 2010 does not show any signs of progressive degeneration of the supportive tissue; the image rather shows a “stable osseous condition.”

Figs. 32–34 Clinical images 2010 (comprehensive and detail views) showing “reduced” but overall stable conditions. The condition of the mandible also appears normal, which is confirmed by the detail view of the frontal mandible.



→ DT page 7

Clinical baseline findings in 1995

Teeth 27 and 37, 38 showed a degree of loosening of I-II. The side teeth showed high probing depths, and a BOP was detected in general. The front mandible was found to be without irritation. The interdental spaces had soft deposits. There were edentulous spaces 16, 25, 26, 27, 45, 46, 35, 36.

X-ray diagnosis (1995)

The panoramic tomography (orthopantomogram) shows an adult dentition with general horizontal bone loss and profound vertical bone lesions on the following teeth: 17, 24, 27, 47 and 48. The patient had received primarily cast restorations. Tooth 24 shows two apical radiopaque structures on the root apex and a discrete periapical translucent zone.

Diagnosis

Adult marginal periodontitis.

Course of treatment 1995–2010

The entire pre-treatment phase proved to be without complication due to the patient's initially high compliance. The teeth of the maxilla and the mandible were treated with a mixed open (sidetooth area) and closed (front-tooth area) curettage in the subsequent surgical phase. The surgical part of the periodontal treatment was completed in April of 1995. Since then the patient has been in the recall system, which he took very seriously initially and which helped him to remain recurrence-free for four years after the surgical treatment. From 1999 to 2003 the recall started to become difficult because the patient did not show up in spite of appointments or rescheduled appointments on short notice. At the beginning of 2003 increased probing depth were found on 25, 24 and 27 and three additional teeth exhibited bleeding when probed. Another curettage with laser light decontamination resulted in a decrease of the inflammation; however, 27 could not be saved and had to be extracted, as did tooth 24 (condition after root apex resection), which fractured subgingivally. The resulting free-end situation starting with tooth 23 in the left half of the maxilla and the existing edentulous space in the right half of the maxilla, which had been there for a longer period of time, were treated with three implants that received crowns after a three-month osseointegration period. We arranged with the patient that he should participate in a quarterly recall and make a new appointment upon completion of the respective recall. He has been recurrence-free since then.

The X-ray images showed a marked tendency for reduction of the osseous supportive tissue on tooth 24. (Note: This tooth was also extracted.) None of the other teeth showed any substantial changes in the course of the os-

seous limbus alveolaris. The implants also did not show any changes of the periimplant osseous condition from insertion up to the present day.

Epicrisis

Our prognosis after removal of the non-conservable teeth and the systematic increase of abutment teeth is very favorable. The patient's compliance—after variations in the medium observation period—is stable and good. The long recurrence-free interval is also very gratifying.

3rd Case (Figs. 25–34)

The “completely delightful long-term patient”

Male patient, born in 1952.

Medical history

This patient had been with the same dentist for many years, whom he consulted for check-ups on a regular basis. The patient was surprised to find that his teeth 12 and 11 were “loose” and had to be extracted. He was then referred to our clinic. The patient was quite obviously unhappy with the loss of two teeth and the referral (“I feel pushed off”). He is a physical education teacher at a high school and stated that he was completely healthy.

Clinical baseline findings (1995)

Almost all teeth revealed increased probing depths, and probing on the gums in the side-tooth area resulted in bleeding. The smooth surface cleaning was very good; however, deposits were found in the interdental spaces. The dental necks of the maxillary premolars showed wedge-shaped defects. The patient had received primarily cast restorations.

X-ray diagnosis (1995)

In the maxilla, the osseous limbus alveolaris has a considerably reduced level. The alveolar ridge in the area of the tooth gap 12, 11 is severely atrophied. Bone mass in the mandible is also reduced, although not as extensively as in the maxilla. Tooth 45 had received a root canal treatment. The crown edges of the cast restorations do not align perfectly with the contour of the teeth and mostly have an overhanging design.

Diagnosis

Severe adult marginal periodontitis.

Course of treatment 1995 to present

Our most difficult task initially was to appease the patient's dissatisfaction because he felt he “had been taken for a ride.” After we had successfully done that, the patient eagerly followed our instructions and followed a frequent and sufficient oral hygiene regime. He grew especially fond of interdental cleaning which had never been mentioned to him before. In May 1995 we started the corrective phase, which was completed in July. We carried out lobe surgery with apical soft tissue fixation in all quadrants. The patient received two

implants in regions 12, 11 and, after their osseointegration, two blocked crowns. Due to the severe bone degeneration and the patient's wish to forego augmentation, we arrived far below the cement-enamel junction of the adjacent teeth in one oral implant; however, this did not pose a problem due to the patient's extremely deep-set upper lip. The patient has been in our recall system for 15 years now; he has not missed one recall appointment and has been recurrence-free ever since. A successive prosthetic re-treatment of some single (component) crowns, which had become insufficient, was carried out over the course of several years.

Epicrisis

I feel that—on the “credit side”—we have the patient's excellent cooperation, which has not diminished to this day, and the long recurrence-free period. In this context, one should not forget the extent of the previous periodontitis. These aspects leave a very satisfying impression.


AD

Discussion

The diode laser decontamination study (Krekeler/Bach; University Dental Clinic, Freiburg/ Breisgau) that started in 1994 and 1995 was made up of 25 patients, of which seven are still receiving treatment. The extremely long examination period (15 years) naturally limited the number of patients we could examine and treat. Some of the patients, who are no longer in our recall system, have unfortunately passed away in the meantime, while others have moved away or found a different dentist who is located closer to their new residence (usually a care home). Over the years, three “patient types” have emerged—the “holding therapy” type, the “imperative recall type to avoid being the unsuccessful type” and the “successful type”. The purpose of this paper is to present these three types by way of individual examples. Diode laser light decontamination proved to be very helpful in all examined patients—I feel that, based on the current results, this assessment is justified because the incorpo-

ration of diode laser decontamination into the proven treatment regimen for periodontitis resulted in a considerable reduction of the recurrence rate and a considerable improvement of the prognosis of this disease.

An evaluation of the significance of the laser treatment, which has been established as an integral part of a proven therapy regimen in our treatment philosophy, is certainly worthy of discussion. Laser critics will want to argue that a close-meshed and consistent recall, possibly supported by other adjuvant measures, would have yielded similarly positive results. This may indisputably be the case; in fact, I am sure that this assessment is true! However, if the key to treatment success is then rather the consistency and frequency of treatment, I consider laser-assisted treatment to be one of many options in the extensive field of periodontal therapy. Laser-assisted periodontal therapy thus makes no pretence of being a unique feature, but rather an adjuvant therapy with the claim to be efficient, gentle and ultimately successful.



ESTHETIC CURRICULUM

Program Chairs:
Dr. Ed McLaren & Dr. Sascha Jovanovic

Session Chairs:
Dr. Didier Dietschi, Dr. Daniel Edelhoff, Dr. Mauro Fradeani

**SESSION I - FEBRUARY 18 - 21, 2011
IN ATHENS, GREECE**

DIRECT RESTORATIONS AND ADHESIVES
with DR. DIDIER DIETSCHI and others

**SESSION II - JUNE 24 - 27, 2011
IN ATHENS, GREECE**

INDIRECT RESTORATIONS, FULL CERAMIC
CROWNS AND VENEERS
with DR. DANIEL EDELHOFF and others

**SESSION III - OCTOBER 2 - 5, 2011
IN ATHENS, GREECE**

ALL CERAMIC RESTORATIONS AND
FIXED PROSTHODONTICS
with DR. MAURO FREDEANI & DR. STAVROS PELEKANOS

**SESSION IV - NOVEMBER 28 - DECEMBER 2, 2011
IN LOS ANGELES, CALIFORNIA**


GRADUATING WEEK AT UCLA
with DRS. ED MCLAREN, SASCHA JOVANOVIC, BRIAN LESAGE
TODD SCHOENBAUM, PASCAL & MICHEL MAGNE

PROGRAM FEATURES

- CLASSROOM EDUCATION
- LIVE PATIENT TREATMENTS
- CASE PRESENTATIONS
- HANDS-ON
- 90 HOURS SELF-STUDY
- 217 HOURS CE
- 2 CERTIFICATES from gIDE and UCLA

2011 gIDE/UCLA 1 YEAR MASTER PROGRAM IN ESTHETIC DENTISTRY

EXPERT FACULTY
DIDIER DIETSCHI, MAURO FRADEANI,
DANIEL EDELHOFF, STAVROS PELEKANOS,
PANOS BAZOS, ED MCLAREN,
SASCHA JOVANOVIC, PASCAL &
MICHEL MAGNE, BRIAN LESAGE & OTHERS...



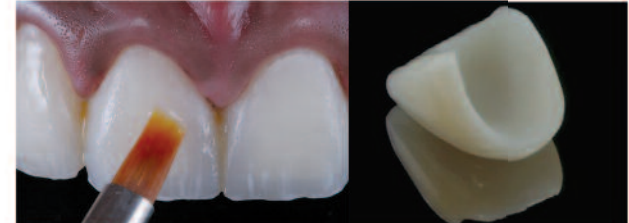
Register & More Information at:

Contact in Athens:
Lito Christophilopoulou
Tel: +30 210 213 2084, +30 210 222 2637
E-mail: lito@omnipress.gr, omnipress@omnipress.gr
Web: www.omnicongresses.gr

Contact in the US:
Nena Puga
Tel: +1 310 696 9025
E-mail: nena@gidedental.com
website: www.gidedental.com

Media Partner: dti

SPONSORS
ivoclar vivadent | WGH | collène whaludent

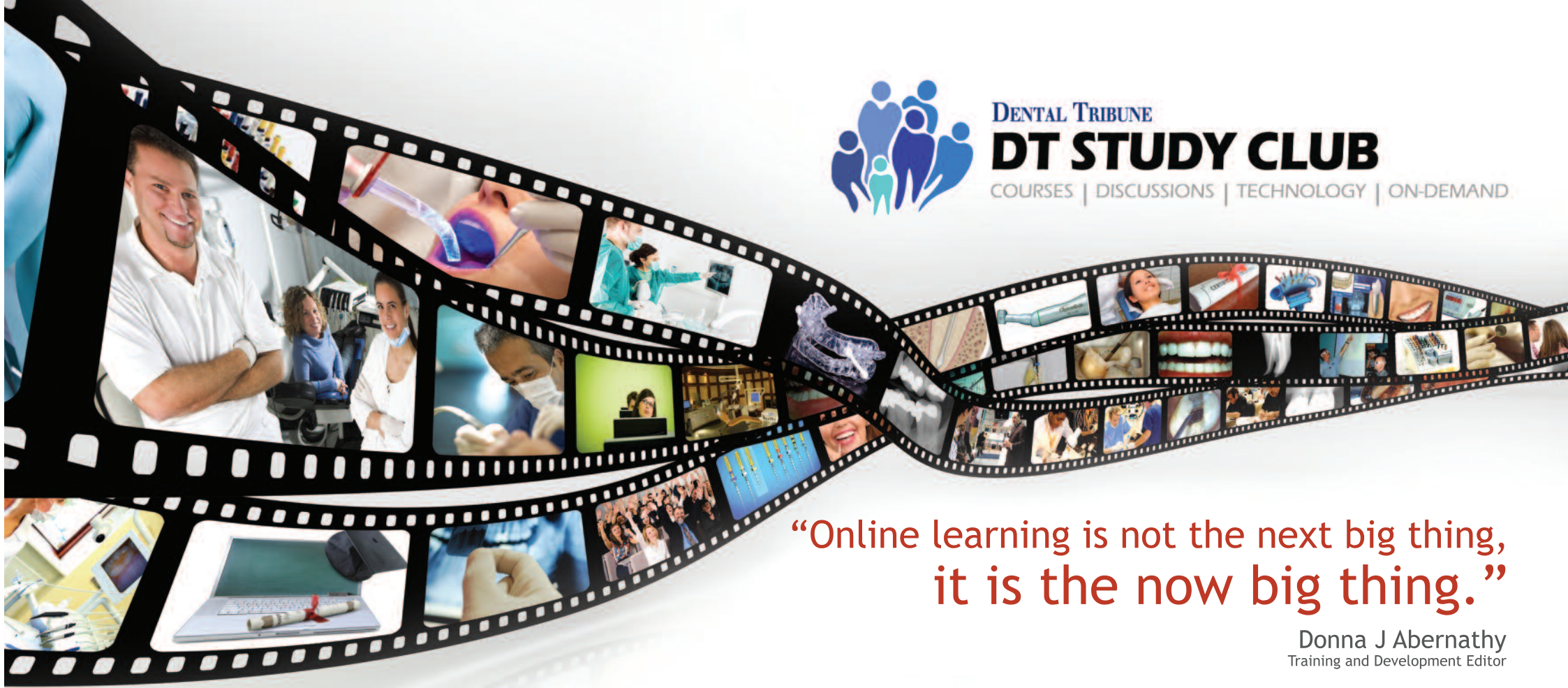



DENTAL TRIBUNE

DT STUDY CLUB

COURSES | DISCUSSIONS | TECHNOLOGY | ON-DEMAND



**“Online learning is not the next big thing,
it is the now big thing.”**

Donna J Abernathy
Training and Development Editor

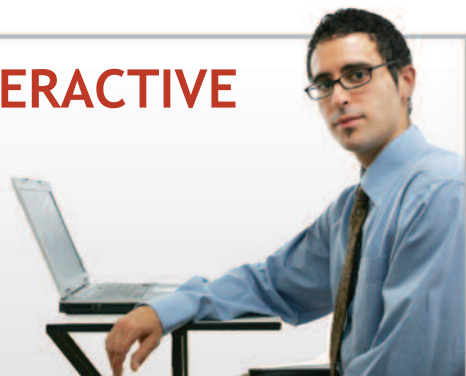DTSC - COURSES, COMMUNITY, TECHNOLOGY, ON-DEMAND

The DT Study Club makes all of this possible from the comfort of your own computer and without travel expenses. In other words, welcome to the community!

The purpose of this study club is to provide practitioners like yourself an opportunity to learn and network with like-minded colleagues in a friendly, non-threatening environment. We encourage you to take advantage of Dental Tribune’s global outreach to access a variety of fresh perspectives and cultures, enhancing your educational mix.

24/7 LIVE AND INTERACTIVE ONLINE COURSES

Fulfill your yearly CE requirements with our growing list of archived ADA CERP approved courses.



DISCUSSION FORUMS

focused on helping today’s practitioners to stay up to date. Networking possibilities that go beyond borders to create a truly Global Dental Village



VIDEO REVIEWS OF PRODUCTS

Our opinion leaders unveil new products, services, and give you their first impressions of the industry’s hottest topics.



PEER REVIEWED CASE STUDIES

Upload, comment, participate. We encourage you to share your cases for review with like-minded practitioners.



REGISTER FOR FREE ON WWW.DTSTUDYCLUB.COM

CONTESTS WITH CHANCES TO WIN FREE TUITION FOR ADA/CERP C.E. ACCREDITED WEBINARS

SPONSORSHIP AND SPEAKING INQUIRIES:

JULIA WEHKAMP, J.WEHKAMP@DTSTUDYCLUB.COM, (416) 907-9836.

ADA CERP® | Continuing Education Recognition Program



PRACTICE MANAGEMENT



GENERAL DENTISTRY




COSMETICS




ENDODONTICS



IMPLANTOLOGY



PERIODONTICS



ORTHODONTICS



DENTAL HYGIENE

WWW.DTSTUDYCLUB.AE

