

DENTAL FOR PROFESSIONALS

DENTAL TRIBUNE

The World's Dental Newspaper • Middle East & Africa Edition

PUBLISHED IN DUBAI

www.dental-tribune.me

March-April 2017 | No. 2, Vol. 7

ENDO TRIBUNE

Exploring the fracture resistance of retentive pin-retained e.max press onlays in molars

►A1-8

LAB TRIBUNE

Technology meets craftsmanship

►B1-4

HYGIENE TRIBUNE

Interview: "Around 50 per cent of children have cavities by 6 years of age"

►C1-4

IMPLANT TRIBUNE

Implant-Supported Fixed Restorations for the Partially Edentulous Arch

►D1-4

ORTHO TRIBUNE

Functional & Cosmetic Excellence: Revitalization of a Proven Treatment Philosophy

►E1-4

Visit DTMEA / CAPP at IDS Cologne 2017

By Dental Tribune MEA / CAPPmea

COLOGNE, Germany: CAPP (License holder of Dental Tribune Middle East & Africa edition) will once again participate at IDS Cologne, the world's largest dental trade show as part of the global Dental Tribune International (DTI) family exhibiting at the

cosy 100 square meter DTI Media Lounge (Hall 4.1, booth D60 F61). CAPP will play its part in delivering the latest news from and to the Middle East by providing a knowledge bridge through numerous channels supporting the activities of DTI.



Dental Tribune International (DTI) family exhibiting at the cosy 100 square meter DTI Media Lounge (Hall 4.1, booth D60 F61)

In collaboration with its German licensee OEMUS MEDIA, DTI will be publishing a new issue of its

well-established Today newspaper on each of the five days, providing comprehensive coverage of the previous day's events. For the first time, the two publishers will be setting up a lecture forum at their booth—known as the Media Lounge, a restaurant and meeting area at which leaders in dentistry conventionally gather during IDS. At the forum, which will seat up to 200 participants, DTI will be holding Dental Tribune Study Club lectures and press conferences through DTI Communication Services.

The DTI portfolio spearheaded by CEO Mr. Torsten Oemus reaches over 650,000 dental professionals worldwide in 25 different languages in over 90 countries. Live daily coverage will take place daily through multiple channels including DTI Press events, DTI Lecture Corner, daily today show publications, digital e-newsletters, e-blasts, social media and live video broadcasting. CAPP representing the Middle East publication of Dental Tribune will do its part to present the news to the large (?) following of dental professionals from the Middle East region.

The latest news and innovations from IDS Cologne will be presented at the coming 12th CAD/CAM & Digital Dentistry Conference & Exhibition in Dubai

In the quest to bring the latest dental industry novelties, products and scientific cases to MEA region as soon as possible, CAPP will ensure dental professionals who are unable to travel to Cologne will have the opportunity to see the latest news in Dubai coming May 2017. The 12th CAD/CAM & Digital Dentistry Conference & Exhibition will take place on 05-06 May 2017 at the Intercontinental Hotel Dubai Festival City - a venue now famous for hosting a Guinness World Record for 'Largest water screen projection of 893 square meters'. The two-day scientific conference and exhibition will provide more insights into the latest launched CAD/

CAM and digital techniques opening its doors to all dentists, dental technicians and other dental industry interested in these fields. One of the major themes this year will be the focus on 3D Printing in the dental field, a subject widely discussed within the dental profession. Dental Technician Intentional Meeting (DTIM) will take place as a parallel session on 05 May targeted to gathered 250 dental technicians from the MEA region for scientific lectures, hands-on presentations and table clinics. A total of 16 multidisciplinary hands-on courses are scheduled to take place between 01-08 May 2017 a falling under the umbrella of "Dubai Dental Week", the largest scientific continuing dental education programme in the region presented over 8 days. This year's exhibition will feature the latest product launches from IDS Cologne presented by the industry players: Platinum Sponsor: Dentsply Sirona, Crystal Sponsor: Ivoclar Vivadent AG, Silver Sponsor: GSK, Gold Sponsors: Planmeca OY, MAC Digital Dental Systems LLC/3 shape, VITA Zahnfabrik, Official Sponsors: Coltene Whaledent AG, Amann Girschbach AG, Carestream Dental LTD, Neoss Ltd DMCC Branch as well as Other Industry Players: Eisenbacher Dentalwaren ED GmbH, Jordan (Castel General Trading), Adentatec GmbH, Roland Dental Solutions/ Emirates Computers Co LLCr, Horico Hopf, Ringleb & Co/ SMS Medical & Dental Supl, Dubai Medical Equipment, Qualident Dental Lab, High Technology Dental Lab, Centuar Software, Bilkim Ltd Co., Dynamic Abutment Solutions, Zirkonzahn GmbH / Srl, Henry Schein, Melat Trading/ Datron, Hager & Meisiger

12th edition CAD/CAM & Digital Dentistry Conference/Exhibition

5-6 May 2017, Dubai

05-06 MAY 2017 | CONFERENCE
05-06 MAY 2017 | EXHIBITION
05 MAY 2017 | DENTAL TECHNICIAN INT'L MEETING
01-08 MAY 2017 | HANDS-ON COURSES



InterContinental Hotel
Festival City Dubai
Dubai, UAE

ACCREDITATIONS:
HAAD | DHA | CE Credits



CAPP

Contact Us
Mobile: +971502793711
Telephone: +97143616174
FAX: +97143686883
E-mail: events@cappmea.com
www.cappmea.com/cadcam



◀Page 1

GmbH, Al Thanaya Pharmaceuticals LLC, Willmann & Pein GmbH, Green Dental Lab, Sinterex Metal 3D Printing LLC, Med Door/ EVE GmbH and others.

At its 12th edition, the exhibition will provide an excellent platform for dental professionals and industry experts to network, exchange ideas and do business. During the two-day exhibition, range of latest dental products and services will be introduced for the first time in the Middle East after IDS, Cologne.

MEA Region amongst dentistry's top high potential markets

With its rapid and dynamic markets, continuously educated workforce and support from local governments, the Middle East region is amongst dentistry's top high potential markets in the world. Conducting business in the MEA region however, is far from easy unless dealing with the right partners. Meet CAPP at IDS Cologne to find out how you can expand your business in the region. Explore "Innovative Dental Solutions" the marketing concept developed by CAPP, feel welcome to visit us at the DTI Media Lounge (Hall 4.1, booth D60 F61) at the upcoming IDS Cologne (21-25 March 2017).

About CAPP

Centre for Advanced Professional Practices (CAPP) was founded in 2005 by Dr. Dobrina Mollova in Dubai, UAE with the sole purpose of delivering excellence in Dental Continuing Medical Education in the



Middle East and beyond. CAPP is an American Dental Association (ADA) C.E.R.P Recognised Provider, specialising in Continuing Medical Education (CME) and Continuing Professional Development (CPD) dental education programmes – conferences, short and long term hands-on courses, workshops and self-instruction programmes.

CAPP is the organiser of the two leading dental scientific conferences in the region: CAD/CAM & Digital Dentistry International Conference (1st edition in 2005) and Dental Facial Cosmetic International Conference (DFCIC) (1st edition in 2009). Both these conferences are annual events.

Growth

For the past 12 years CAPP has facilitated over 410 CME programmes educating over 62,000 international participants. Ever since 2005 CAPP has experienced year-on-year growth and in 2016 alone CAPP educated 13,856 international dental professionals (lower versus 2015 due to Asia Pacific CAD/CAM & Digital Dentistry Singapore being held bi-annually). CAPP has become the leader in Continuing Dental Education programmes in the region.

Provider of professional diploma's in dentistry

In 2016, CAPP-Tipton Dental Academy and the British Academy of Restorative Dentistry (BARD) has launched the Restorative & Aesthet-

ic Dentistry Certificate and Diploma courses in Dubai, UAE. Group 1 & Group 2 started in September 2016. Group 3 is starting on 05 October 2017. Year 1 (Certificate) is spread over 4 Modules (15 days in total) and it offers the participants a chance to obtain a Certificate in Restorative Dentistry (PG Cert Rest Dent) from the British Academy of Restorative Dentistry (BARD). After a successful completion of the Year 1 Certificate course, the participants will have the chance to sign up for Year 2 Diploma (4 Modules, 15 days in total) which will lead to Post-Graduate Diploma in Restorative & Aesthetic Dentistry from the British Academy of Restorative Dentistry (BARD). The courses will comprise of lectures, practical's and seminars. After completion of the Diploma, there is an option for delegates to take the pathway to MSc (Masters of Science) in Restorative and Aesthetic Dentistry with The University of Manchester and Healthcare Learning or Masters in Clinical Dentistry (MClinDent) Restorative and Cosmetic Dentistry with City of London Dental School (CoLDS) / BPP University.

CAPP-Tipton Dental Academy and British Academy of Restorative Dentistry (BARD) in addition launched the Clinical Endodontics Dentistry Certificate and Diploma programme in Dubai, UAE, starting on 20 April 2017.

Asia Pacific Market Opportunities

With the opening of CAPP Asia in 2012, the company's reach has expanded to the Asia-Pacific region and beyond. CAPP Asia main focus in the region is the Asia-Pacific Edition of the CAD/CAM & Digital Dentistry International Conference held in Singapore on a bi-annual basis. This year will see the 4th Asia Pacific and 15th Global Edition of the famous CAD/CAM & Digital Dentistry Int'l Conference – the world's only completely dedicated event in these fields of dentistry.

Dental Tribune MEA

CAPP is the proud owner of the Dental Tribune Middle East & Africa print and digital publication. CAPP is delivering six print editions annually to over 20,000 dental professionals (120,000 copies annually) in the Middle East and Africa region and delivers newsletters to over 41,000 active subscribers every two weeks (approx. 984,000 e-mail annually). Through its international website, the latest industry news reaches the largest dental community worldwide - an audience of over 1,000,000 dental professionals. [DTI](#)

IMPRINT

GROUP EDITOR
Daniel ZIMMERMANN
newsroom@dental-tribune.com
Tel.: +44 161 223 1830

CLINICAL EDITOR
Magda WOJTKIEWICZ
Nathalie SCHÜLLER

ONLINE EDITOR
SOCIAL MEDIA MANAGER
Claudia DUSCHEK

EDITORS
Kristin HÜBNER
Yvonne BACHMANN

ASSISTANT EDITOR
Julia MICHEL

MANAGING EDITOR & HEAD OF DTI COMMUNICATION SERVICES
Marc CHALUPSKY

JUNIOR PR EDITORS
Brendan DAY
Julia MACIEJEK

COPY EDITORS
Hans MOTSCHMANN
Sabrina RAAFF

PUBLISHER/PRESIDENT/CEO
Torsten R. OEMUS

CHIEF FINANCIAL OFFICER
Dan WUNDERLICH

CHIEF TECHNOLOGY OFFICER
Serban VERES

BUSINESS DEVELOPMENT MANAGER
Claudia SALWICZEK-MAJONEK

PROJECT MANAGER ONLINE
Tom CARVALHO

JUNIOR PROJECT MANAGER ONLINE
Hannes KUSCHICK

E-LEARNING MANAGER
Lars HOFFMANN

EDUCATION DIRECTOR TRIBUNE CME
Christiane FERRET

EVENT SERVICES/PROJECT MANAGER TRIBUNE CME & CROIXTURE
Sarah SCHUBERT

MARKETING SERVICES
Nadine DEHMEL

SALES SERVICES
Nicole ANDRA

ACCOUNTING SERVICES
Anja MAYWALD
Karen HAMATSCHEK
Manuela HUNGER

MEDIA SALES MANAGERS
Antje KAHNT (International)
Barbora SOLAROVA (Eastern Europe)
Hélène CARPENTIER (Europe)
Maria KAISER (North America)
Matthias DIESSNER (Key Accounts)
Melissa BROWN (International)
Peter WITTECZEK (Asia Pacific)
Weridiana MAGESWIKI (Latin America)

EXECUTIVE PRODUCER
Gernot MEYER

ADVERTISING DISPOSITION
Marius MEZGER

DENTAL TRIBUNE INTERNATIONAL
Holbeinstr. 29, 04229 Leipzig, Germany
Tel.: +49 341 48 474 302
Fax: +49 341 48 474 173
www.dental-tribune.com
info@dental-tribune.com

DENTAL TRIBUNE ASIA PACIFIC LTD.
Room A, 20/F
Harvard Commercial Building
105-111 Thomson Road, Wanchai, HK
Tel.: +852 3113 6177
Fax: +852 3113 6199

THE AMERICA, LLC
116 West 23rd Street, Ste. 500, New York
N.Y. 10011, USA
Tel.: +1 212 244 7181
Fax: +1 212 244 7185

DENTAL TRIBUNE MEA EDITION EDITORIAL BOARD
Dr. Aisha SULTAN ALSUWAIDI, UAE
Dr. Ninette BANDAY, UAE
Dr. Nabeel HUMOOD ALSABEEHA, UAE
Dr. Mohammad AL-OBAIDA, KSA
Dr. Meshari F. ALOTAIBI, KSA
Dr. Jasim M. AL-SAEEDI, Oman
Dr. Mohammed AL-DARWISH, Qatar
Prof. Khaled BALTO, KSA
Prof. Paul TIPTON, UK
Dr. Dobrina MOLLOVA, UAE
Dr. Munir SILWADI, UAE
Dr. Khaled ABOUSEADA, KSA
Dr. Rabih ABI NADER, UAE
Dr. George SANOOP, UAE
Dr. Olivier CARCUAC, UAE
Dr. Ehab RASHED, UAE
Aiham FARRAH, CDT, UAE
Retty M. MATTHEW, UAE

PARTNERS
Emirates Dental Society
Saudi Dental Society
Lebanese Dental Association
Qatar Dental Society
Oman Dental Society

DIRECTOR OF mCME
Dr. Dobrina Mollova
mollova@dental-tribune.me
Tel.: +971 50 42 43072

DIRECTOR
Tzvetan Deyanov
deyanov@dental-tribune.me
Tel.: +971 55 11 28 581

DESIGNER
Kinga Romik
k.romik@dental-tribune.me

PRINTING HOUSE & DISTRIBUTION
Al Nisr Printing
P. O. Box 6519, Dubai, UAE
800 4585/04-4067170



Dental Technician Int'l Meeting

5 May 2017, Dubai

Joint meeting with
12th CAD/CAM & Digital Dentistry Conference/Exhibition

The Art of Craftsmanship





Contact Us
Mobile: +971502793711
Telephone: +97143616174
FAX: +97143686883
E-mail: events@cappmea.com
www.cappmea.com/cadcam

ACCREDITATION:
HAAD | DHA | CE Credits





Solutions for better, safer, faster dental care

Dentsply and Sirona have joined forces to become the world's largest provider of professional dental solutions. Our trusted brands have empowered dental professionals to provide better, safer and faster care in all fields of dentistry for over 100 years. However, as advanced as dentistry is today, together we are committed to making it even better. Everything we do is about helping you deliver the best possible dental care, for the benefit of your patients and practice.

Find out more on
dentsplysirona.com

Clinical Procedures

- Preventive
- Restorative
- Orthodontics
- Endodontics
- Implants
- Prosthetics

Platform Technologies

- CAD/CAM
- Imaging Systems
- Treatment Centers
- Instruments

THE DENTAL
SOLUTIONS
COMPANY™

 **Dentsply
Sirona**

Balancing Efficiency and Esthetics – Maximizing Today’s Modern Materials

By Dr. Cory Glenn, DDS, USA

As many dentists in busy practices may know, being efficient during each procedure is a key to success on a day-to-day basis. I continually strive to hone my skills to make procedures faster and better, and a large part of my ability to do this is my product mix. And although efficiency is extremely important to me, I won't choose a set of products, even if they offer great efficiency, if the end result becomes compromised.

A large part of my practice is performing direct posterior restorations, which can often become time consuming for me because of the need for multiple steps and multiple composite layers. Over the years I've been incrementally placing composites with great results, but I wanted something easier for my posterior restorations. To make restorations simpler, I began researching new products marketing themselves as efficient and esthetic. I'm not the type to simply switch everything over to one new product without ample research and science backing up the product, so I began testing a select group of products I thought would work well.

I began experimenting with a new adhesive, a new composite material, a new curing light, and a new finishing and polishing system. After the first few restorations I began achieving great results quickly and easily.

Characteristics of Adhesive

Universal adhesives have been available for several years and their goal is to be exactly what they say: universal. In most cases, there's no need for multiple bottles for different indications and most can be used in self-, selective-, and total-etch mode. After some initial research and talking with colleagues I began trying Single Bond Universal Adhesive. In order to lessen the risk of using a new product, I began using it for a few procedures at first to gauge its performance and kept my old adhesive material on standby.

Finding the Right Bulk Fill

I've been intrigued with the advent of bulk fill composite in the last few years and their ability to be placed in one increment. But my experiences with these materials had been less than impressive in the past. Even though they were extremely efficient, I wasn't comfortable using them.

When I tested Filtek™ Bulk Fill Posterior Restorative, I saw many characteristics and results that I liked. A large concern I had with these composites was the amount of polymerization stress that acts on the tooth, but research shows that Filtek Bulk Fill Posterior offers stress relief compared to many incremental fillings, which is great for my peace of mind. The esthetics of this material has also been pleasantly surprising to me.

With Filtek Bulk Fill Posterior I can improve productivity and save valuable chair time. It has excellent handling like the traditional Filtek materials I use and is easy to shape. I now have several minutes left after a restoration where I can quickly look over case notes or take a short mental break before the next patient. It's great not rushing from one restoration to another, and it really seems to create space in my day.

The Importance of Proper Curing

Not all curing lights are created equal. New LED models can produce higher light output and can cure materials more efficiently than previous types of lights while also making user operation easier. I've been experimenting with the Elipar™ DeepCure-S LED Curing Light and have found great success with it. It increases my confidence of a full cure at the bottom of the proximal box and has an ergonomic shape which makes operation easier by me or my assistants. With old and inefficient curing lights, I would sometimes worry about achieving a reliable result and that's not the case with this new curing light.

Simple Finishing and Polishing

Finishing and polishing a restoration can mean the difference between a lifelike shine and a dull looking restoration. Switching between the traditional points, cups and discs, polishing can be tedious and time-consuming for me. I've been utilizing the Sof-Lex™ Spiral Finishing and Polishing Wheels* and have seen great esthetic results. With this two wheel system, I simply run each wheel over the restoration to polish restorations quickly. I find it to be extremely quick, which in the end saves me time.

Case Study

The below case was completed with the products that I discussed above. When these products are used to-

gether, they can create a truly efficient procedure for posterior restorations.

The patient, a female in her mid-50's, presented with two leaking amalgam restorations on teeth #30 and #31. The patient desired a more esthetically pleasing composite restoration and after examination, a bulk fill composite technique was deemed an appropriate treatment option.

Step 1

The existing amalgam restorations (Fig. 1) are removed and caries dye is applied. When no additional caries are detected, the cavity preparation (Fig. 2) is sandblasted with aluminum oxide to ensure the preparation is free of all contaminants.

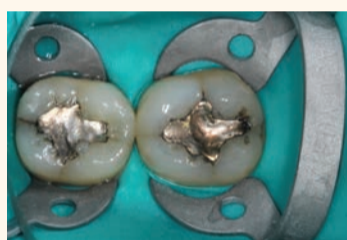

Figure 1

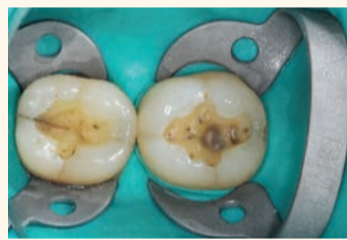

Figure 2

Step 2

The preparations are selectively etched (Figs. 3) with Scotchbond™ Universal Etchant Gel and Single Bond Universal Adhesive is rubbed into the surface for 20 seconds (Fig. 4). The adhesive is then gently air dried for 5 seconds (until the adhesive doesn't move) to evaporate the solvents, and it's light cured for 10 seconds (Fig. 5).

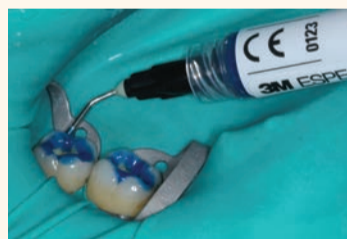

Figure 3

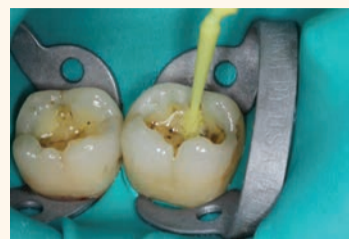

Figure 4

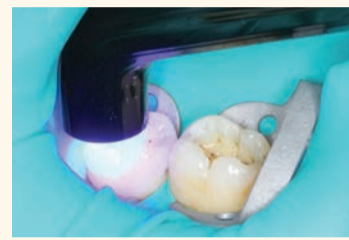

Figure 5

Step 3

As the preparation is less than 4mm deep, Filtek Bulk Fill Posterior Restorative is placed in one step (Fig. 6). A more detailed shaping and contouring of the composite is then done with a metal instrument (Fig. 7). The composite is then light cured for 20 seconds (Fig. 8).

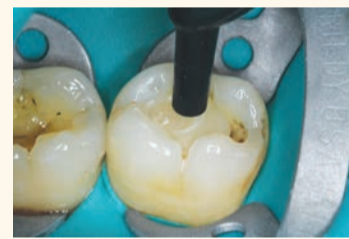

Figure 6

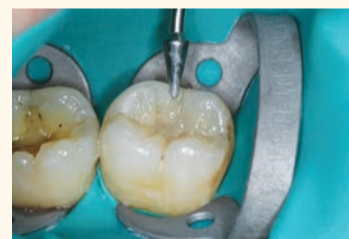

Figure 7

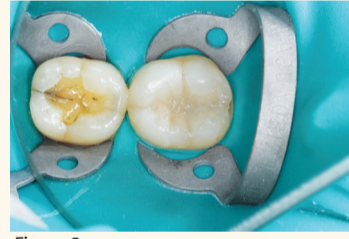

Figure 8

Step 4

After adjustment using a finishing bur, the final polishing is completed with the Sof-Lex Spiral Finishing and Polishing Wheels. The beige finishing wheel (Fig. 9) is used first to remove

surface scratches and the white polishing wheel (Fig. 10) is used to create a high shine. The composite restorations are complete (Fig. 11).

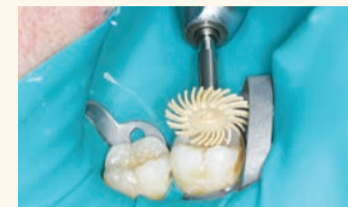

Figure 9

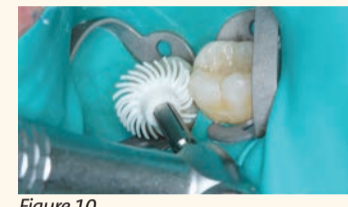

Figure 10

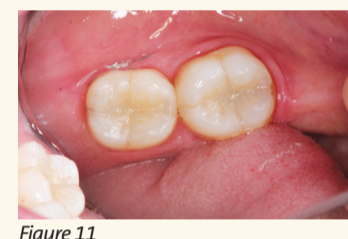

Figure 11

Final Thoughts

The newfound efficiency I've discovered for my posterior restorations has provided me several benefits. For instance, my restorations are quicker, they require fewer products, and there are fewer steps needed. This all adds up to less stress for me during each procedure and in my day-to-day practice.

For more information on the Efficient Restoration Procedure, visit 3M.com/EfficientRestorations [DT](#)



Dr. Cory Glenn
Dr. Glenn graduated from University of Tennessee Health Science Center College of Dentistry. Following graduation, he went on to complete the Lutheran Medical Center's advanced education in general dentistry residency at the UT Memphis branch. He is a graduate of the Georgia Maxi Course in Implant Dentistry, and is an Associate Fellow in the American Academy of Implant Dentistry. Dr. Glenn operates a private practice in Winchester, TN where he performs all disciplines of dentistry with a particular focus on utilizing technology and innovative techniques.

*Replaced with the new Sof-Lex™ Diamond Polishing system consisting of two new wheels - pre-polishing spiral (beige) and diamond-impregnated polishing spiral (pink) in 2016.

3M Oral Care Solutions at AEEDC, 2017

By 3M

On 7-9 February 2017 3M Oral Care took part in AEEDC, one of the largest regional trade shows for oral care professionals in the MEA Region. During the 3 days of AEEDC exhibition 3M Booth was attended by visitors from various countries across the Region and get familiar with vast procedure solutions for greater clinical, professional and personal success.

In the Direct Restorative Procedure area dentists could learn more about Esthetic Procedure Solution with Filtek™ Z350XT Universal restorative, Single Bond Universal adhesive, new Elipar™ DeepCure curing light and

Sof-Lex™ Diamond Polishing system allowing to create beautiful, natural-looking restorations having diamond paste-like gloss. Or to try Efficient Procedure Solution with Filtek™ Bulk Fill Posterior restorative designed to improve productivity by enabling fast and easy posterior restorations. The Indirect Procedure area was dedicated to the sub-procedure solutions, such as impressioning with Impregum™ and Express™ Penta™ materials, cementation with RelyX™ U200 composite cement and temporization with Protemp™ 4 material which all together enable less complicated process, fewer missteps, and therefore more productive and prof-

itable procedure.

In the Orthodontic Procedure area doctors had an opportunity to learn more about the Esthetic Procedure with Clarity™ Advanced ceramic brackets and Efficient Procedure with Metal brackets complemented with APC™ Flash-Free adhesive coated appliance system which allow growing orthodontic practice with esthetics and efficiency.

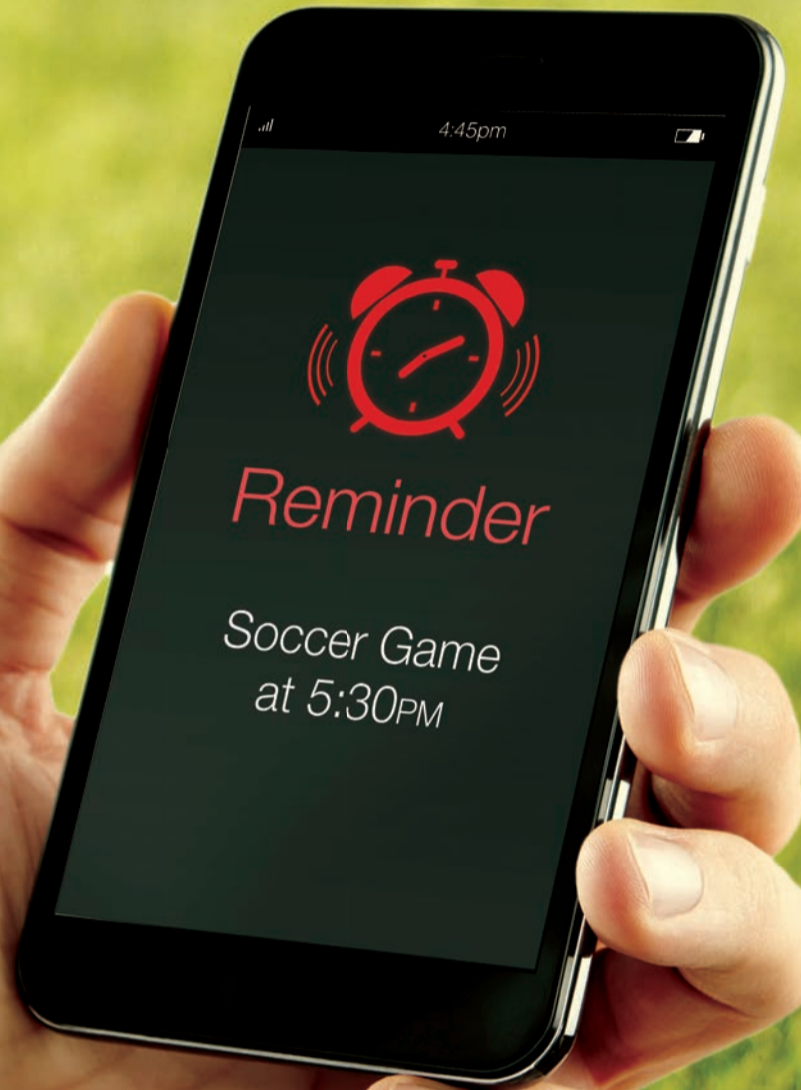The Education area of the booth equipped for short lectures and demo-sessions attracted a lot of doctors who could to learn about such procedures as esthetic composite restorations using Style Italiano technique, posterior restorations with Filtek™



3M booth at AEEDC 2017

Bulk Fill Posterior restorative, precision impressions and reliable cementation techniques.

To learn more about 3M Oral Care products please visit: www.3mgulf.com/espe [DT](#)



3M Oral Care

Takes less time, so you have more time.

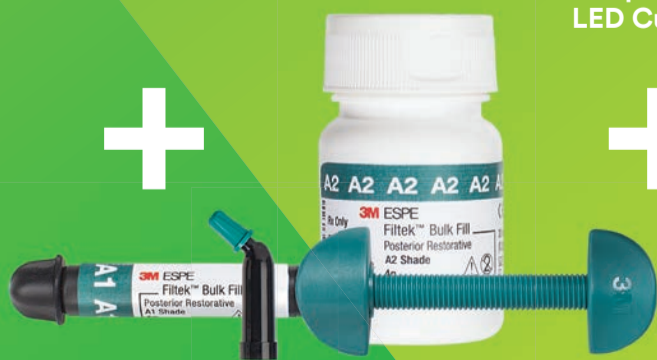There are things in life you don't want to miss. And the more complicated a procedure is, the greater chance there is for something to go wrong and disrupt your day. That's why 3M Oral Care has simplified posterior restorations ... the most frequently performed direct restoration. By using Filtek™ Bulk Fill Posterior Restorative with three other innovative products, you'll move through posterior restorations with speed and simplicity. See how our Posterior Restorative Procedure can help keep you on schedule ... because we know your time outside of work matters.

www.3MGulf.com/espe

Single Bond
Universal Adhesive



Filtek™ Bulk Fill
Posterior Restorative



Elipar™
DeepCure-S
LED Curing Light



Sof-Lex™ Spiral
Finishing and
Polishing Wheels



Treatment options for the edentulous arch



mCME articles in Dental Tribune have been approved by:
HAAD as having educational content for 1 CME Credit Hours
DHA awarded this program for 1 CPD Credit Points

ADA C.E.R.P.® Continuing Education Recognition Program
Centre for Advanced Professional Practices (CAPP) is an ADA C.E.R.P. Recognized Provider. ADA C.E.R.P. is a service of the American Dental Association to assist dental professionals in identifying quality providers of continuing dental education. ADA C.E.R.P. does not approve or endorse individual courses or instructors, nor does it imply acceptance of credit hours by boards of dentistry.
CAPP designates this activity for 1 CE Credits

By Marc Montana

Introduction

Historically, when a patient's dental condition reached a state of total tooth loss, treatment was limited to a complete denture with no hope of improving that status. The greatest challenge, particularly when working with a lower jaw was providing a denture with reasonable stability and retention. Success was greatly dependent upon the skill of the practitioner but also on the neuromuscular ability of the patient, their supporting structures and a philosophical attitude toward their condition. Treatment for patients suffering complete edentulism has been revolutionized by the ongoing success of dental implants such that the standard of care for the mandible is an implant overdenture.

The spectrum of prosthetic modalities developed since the acceptance of endosseous implants to the dental market ranges from the very simple to the astoundingly complex. As this field of study once directed by specialists has evolved into a mainstay of the general practice, favor of expeditious and reproducible methods has gained dominance over complex therapies. Implant overdentures and fixed hybrid prostheses are choices typically offered by the dentist based upon a patient's financial ability. While both are generally successful, the overdenture and the hybrid prosthesis are not without pitfalls.

The implant-retained overdenture

The implant-retained overdenture is described as a prosthesis that covers, and is supported by, the natural tissues retained by the dental implant; the design is considered implant-assisted rather than supported. Placement of two to five implants is commonly found for the edentulous mandible with emphasis on creating a large anteroposterior spread between the endosseous pillars. If more than two implants are clustered in a small AP range, the prosthesis cannot move freely about a single axis of rotation and the denture may dislodge during function.

By creating the fulcrum on the most posterior overdenture abutments, the denture will pivot in function resulting in disengagement from the attachment mechanism and cause premature wear of the retentive components. Therefore, an increase in the number of implants beyond two does not necessarily provide a linear increase in retention and stability. In fact, the opposite may be true. Because support is provided by the mandible itself, resorption of the supporting structure will result in increased tipping of the denture during function, resulting in dislodgment. Therefore, the dentist and patient must be cognizant of the need for relining of the prosthesis periodically to assure optimal performance.

Recommendation is, therefore, placement of two implants in the anterior mandible to allow one axis of rotation. These implants should also be positioned such that future implants may be considered should the patient wish for an implant-supported alternative.

The hybrid prosthesis

The screw-retained hybrid prosthesis is a fully implant-supported structure and, therefore, is not affected by incremental resorption of the residual ridges. It has gained in popularity as the technically difficult and costly gold frameworks have been replaced by CAD/CAM titanium structures and by proven success of angled implant placement to increase the AP spread. Because the restoration has a metal substructure, it is possible to cantilever posterior to the terminal abutment, increasing the length of the functional arch.

However, the esthetic component of the restoration, namely the denture teeth and acrylic resin matrix, are inherently weak materials originally intended for use in complete and partial dentures where functional load is comparatively low. If insufficient inter-arch space is available, the risk of fracture or displacement of denture teeth or resin base is high as the materials will be too thinned to withstand forces generated during function and especially parafunction.

Unfortunately, this is an increasingly common occurrence, especially in restoration of the maxilla with a fixed hybrid prosthesis. Inconvenient screw-access holes may further weaken the prosthetic teeth. Repair of a fractured or lost tooth requires removal of the hybrid prosthesis and correction in the dental laboratory. The dentist must be prepared to remove the structure and later reseat it once the repair is completed. The patient must accept they will be without "teeth" for the length of time required for the technician to fix the problem. Attempts to prevent fracturing by increasing the thickness of the resin is limited by the space available to do so. If inadequate inter-arch space is encountered, correction cannot be achieved by adding more material. Rather a change in design to a different and possibly more expensive restoration may be needed. When hybrids are used in the maxilla, conflict may arise in attempting to improve the esthetic and phonetic result by use of ridge lapping and the limitations such shapes impose on proper oral hygiene.

The benefits of the fixed hybrid prosthesis are clearly improved function and minimal post-treatment complications as long as the patient is able to properly clean it and breakage is avoided. Because it is fixed, the patient cannot remove it to clean away entrapped debris and properly remove plaque. Repair or replacement of the resin teeth requires removal and re-seating by a dentist.

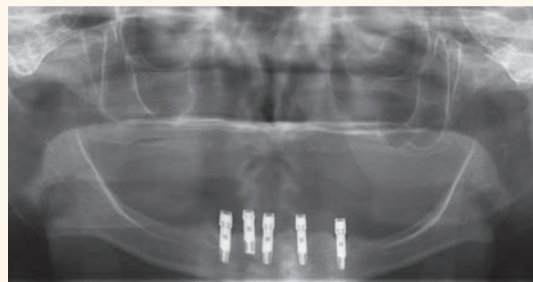

Figure 1. Pre-treatment radiograph showing five implants clustered in the anterior mandible

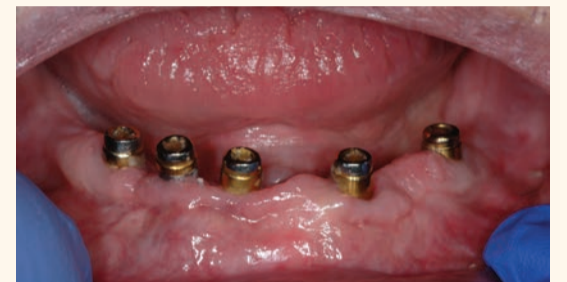

Figure 2. Clinical image of patient. Note the wear of the metal abutments due to disengagement of the nylon retention inserts as a result of fulcrum during function.

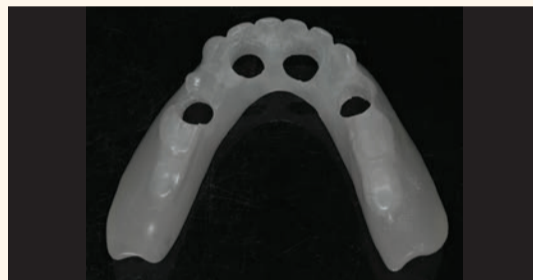

Figure 3. Duplication of an acceptable denture serves as a custom tray. Holes of sufficient diameter to accommodate impression copings have been prepared.

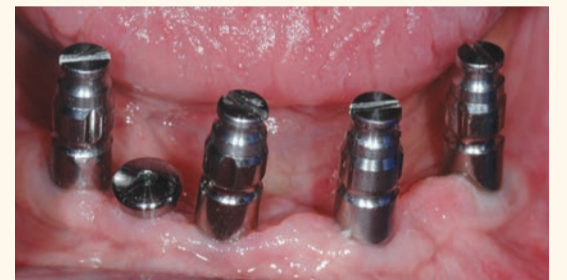

Figure 4. Open tray impression copings seated on the dental implants. One implant is selected for disuse and covered with a transmucosal abutment.

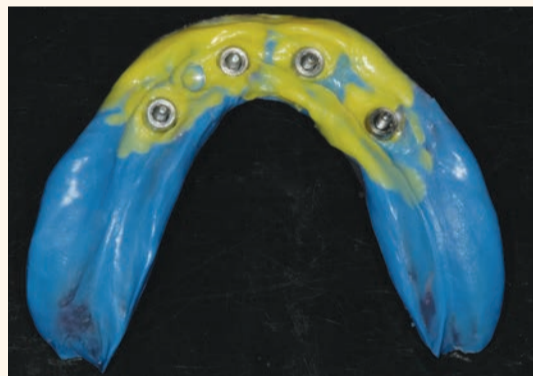
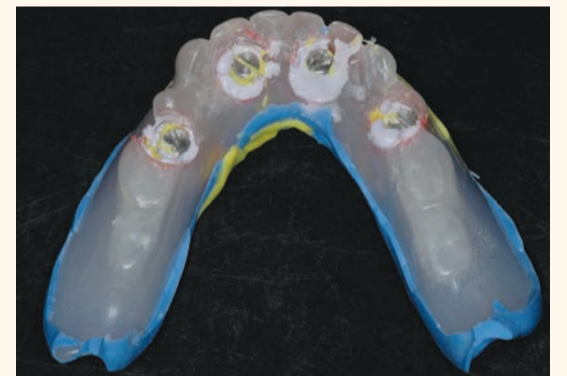
Figure 5, 6. Completed final impression using the custom tray and light body and medium body PVS, as well as rigid bite registration material around the impression copings to eliminate any movement of the copings.



ATLANTIS Conus concept: the removable implant-supported bridge

As described above, the tissue-supported overdenture performs best with only two implants placed in the anterior region. When more than two implants are placed, the goal should be to provide a completely implant-supported result. The Atlantis Conus concept (DENTSPLY Implants) provides the optimal functioning convenience of a fixed hybrid but also allows patient retrievability for unobstructed oral hygiene practice, regardless of the degree of ridge lap. It is in effect, a prosthesis that can be removed by the patient, with the stability of a fixed bridge.

The concept centers around patient-specific abutments, each milled to a 5 degree convergence, and parallel to each other in the dental arch. Recommendation is for at least four implants in the mandible and four to five implants in the maxilla. These uniquely designed, conical abutments are fitted by corresponding metal SynCone caps (DENTSPLY Implants) which are incorporated into the prosthesis. The result is a friction-fit, stable, retentive and fully implant-supported bridge that remains removable by the patient.

No special latches or plunger attachments are necessary to retain it. The patient merely slides the bridge in vertically onto the abutments and removes it in the opposite way. Because the abutments are a part of the ATLANTIS (DENTSPLY Implants, Waltham, MA) portfolio, it is available for all major systems. In addition, because each abutment is custom made, correction of angled implant placement is possible up to 30 degrees. Two major requirements are necessary: the dentist must make an accurate, implant-level impression and a scan must be made of either an approved denture set-up or of a completed denture to be retro-fitted. The ATLANTIS Conus Abutments are then designed to be positioned optimally within the denture confines. The fixed yet removable prosthesis offers the advantages of excellent chewing function, improved esthetics and fracture resistance (as no screw access holes are present) and optimally facial supporting contours, without compromising cleaning by the patient.

Case Report

A 73-year-old woman with a history of 11 years of complete edentulism of the maxilla and mandible, and five endosseous implants in the anterior mandible, presented with a chief

complaint of a non-retentive and unstable lower denture. The implants were standard diameter, externally hexed, Branemark fixtures. She had moderate resorption of both the maxillary and mandibular residual ridges (Fig. 1).

The patient had bone loss involving the implant bodies but comparing the radiographic evidence available, documenting her condition through the years, it appears the bone loss occurred soon after implant placement and no appreciable change was seen thereafter.

During those 11 years, her treatment history included initial restoration of the implants with a complete denture retained by the Locator attachment system (Zest Anchors); and the maxilla was restored with a complete denture. She advised that the result was unsatisfactory as the lower denture displaced during function.

Her history further reveals that the Locators were replaced with Preci-Clix attachments (Ceka Attachments) with no demonstrable improvement. The patient was later retreated by the author, with new maxillary and mandibular complete dentures and new Locator attach-

◀Page 6

ments used to retain the lower prosthesis. The attachment male components were secured intra-orally using auto-polymerizing resin to eliminate the possibility of laboratory error. The patient continued to experience problems with the lower denture coming loose during function and required frequent replacement of the nylon male inserts; replacement with Extended Range inserts did not vary performance. The metal abutments demonstrated considerable wear as well (Fig. 2). Relining the lower denture did not improve the performance of the anchor system.

At the subsequent appointment, the patient was presented with the ATLANTIS Conus concept as a potential solution to her ongoing dilemma. Treatment options were presented as well including a fixed hybrid prosthesis and a 2-in-1 bar overdenture. These were rejected as inter-arch space was less than optimal, requiring compromise to the strength of the design. The patient also expressed a desire for a removable design as she was concerned with having adequate facial support and wished to be able to remove the prosthesis for proper hygiene and maintenance. It was agreed that a new maxillary and mandibular complete denture would be fabricated, and ATLANTIS Conus abutments would be made to secure the lower restoration.

Clinical and laboratory procedures

Because the existing dentures were made within the last five years and were acceptable with regard to tooth position and vertical dimension, it was decided that clear, acrylic resin duplicates of each denture would be made to serve as custom trays. Double-sided impressions of each denture were made and delivered to the dental laboratory for fabrication of the duplicates. Once processed, the copy denture borders were shortened by 2 mm to allow border molding. The duplicate of the mandibular denture clearly showed the position of each Locator housing and therefore the position of the dental implants. Holes of adequate diameter to allow the duplicate denture to be placed in the patient's mouth over impression copings were prepared (Fig. 3). The intaglio surface of both the upper and lower duplicate denture were relieved to allow for a wash impression.

The patient returned for final impressions, and the Locator abutments were removed and kept in appropriate order to avoid confusion when re-seating them at the appointment completion. Open tray impression copings were connected to each of the four dental implants to be restored and tightened into place; one implant with greater bone loss and placed significantly more shallowly than the rest was omitted (Fig. 4). Light-body poly vinyl siloxane was injected around the base of each impression coping and medium-body PVS was placed in the custom tray.

The tray was seated, ensuring that the impression copings were completely accessible through the holes previously prepared. The patient was instructed in facial and tongue movement to achieve proper peripheral border extension. Regisil Rigid (DENTSPLY) bite registration material was injected around each impression coping to rigidly adhere them to the impression tray. This step is critical as reliance on flexible impression material may allow transfer error when constructing the working cast.

Once the impression materials were fully set, the screws retaining the im-

pression copings were removed and the final impression and tray were withdrawn from the patient (Fig. 5, 6). All Locator abutments were re-seated and tightened. Final impression of the maxilla was completed with border molding using modeling plastic and a wash impression with light-body PVS. Upon completion, the patient was dismissed.

In the dental laboratory, implant analogs were secured to the impression posts, gingival moulage was injected around the analogs to an adequate depth to completely cover the coping-analog interface. The impressions were boxed with wax and poured in vacuum-mixed die stone. After setting, the impression coping screws were removed and the impressions were separated from the hardened casts; standard laboratory procedures were followed in cleaning and trimming the working casts. Base plate and wax rims were made for continuation of the denture fabrication. The impression materials were removed from the duplicate denture and it was positioned back onto the mandibular cast to be scanned. An online order was completed including identification of the implants involved and the case was shipped to DENTSPLY Implants for the design and manufacture of the ATLANTIS Conus Abutments.

The working cast, implant analog connections and the denture duplicate were scanned at the ATLANTIS production site and the abutments were individually designed using ATLANTIS VAD (Virtual Abutment Design) software to ensure that all abutments were parallel to each other. The restorative margin of each abutment were placed close to the soft tissue height surrounding each implant, but always supra-gingival to guarantee unobstructed seating of the finished restoration.

Each abutment was milled to a 5 degree taper to match the SynCone caps ensuring an intimate friction-fit. Upon design completion, the images of the abutment designs were made available for review and approval before manufacturing (Fig. 7). Once the design presented was found to be satisfactory, approval for production of the patient-specific abutments was granted. It is important to note that no fees are incurred by the dentist or dental laboratory during this process until design is agreed upon and authorization to proceed is given. The abutments are custom designed to fit specifically to the denture set-up or duplicate denture provided; there are no sizes, heights, angles or collars to select from a catalog and, therefore, no risk of choosing incorrectly.

When received, the ATLANTIS Conus abutments were secured to the working cast with abutment screws, along with four prefabricated SynCone caps (Figs. 8, 9). The caps were seated on the abutments and sent to the dental laboratory to be impressed. The impression was poured twice, one in improved dental stone and one in refractory material for fabrication of a cast metal frame. While waiting for the frame to be completed, final try-in appointments for the denture set-up were completed, and the patient approved fabrication of the dentures.

The denture set-up with a final bite record were returned to the dental lab, the cast metal frame was seated on the improved dental stone cast and areas around the stone copy of the SynCone caps were blocked out prior to processing. The SynCone caps will be captured intraorally, rather than having them processed in the dental laboratory. All work was completed on the duplicate stone cast rather than the original

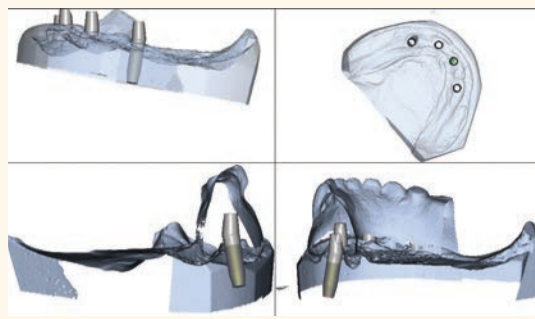


Figure 7. Design images showing the contour and tooth position of the duplicate denture and proposed design of the ATLANTIS Conus Abutments

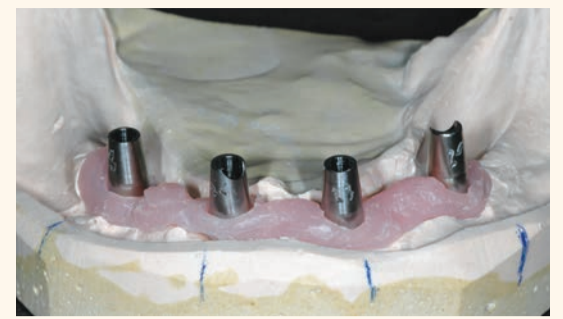


Figure 8. ATLANTIS Conus Abutments on the working cast. Each abutment has the tooth number location scribed on the buccal-facing surface

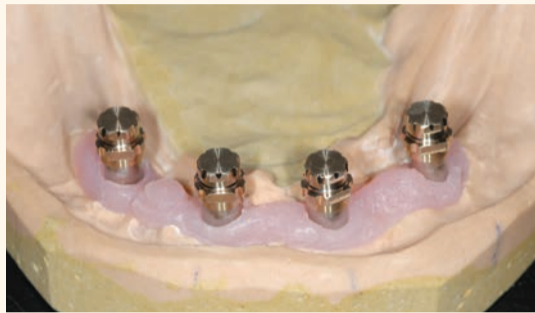

Figure 9. SynCone caps seated on the abutments on the working cast. An impression of this arrangement is made to fabricate a cast metal frame to reinforce the final restoration

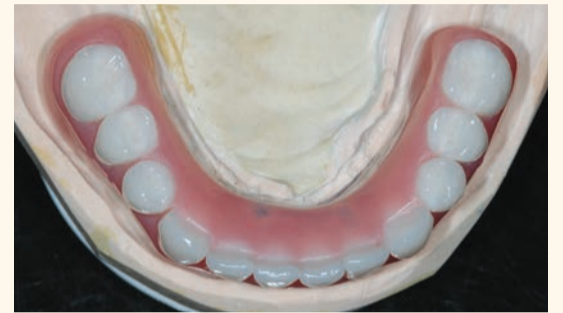

Figure 10. Completed laboratory restoration; note the termination the arch at the first molar to avoid excessive cantilever length. The chrome frame is opaqued on the functional side to prevent gray show-through

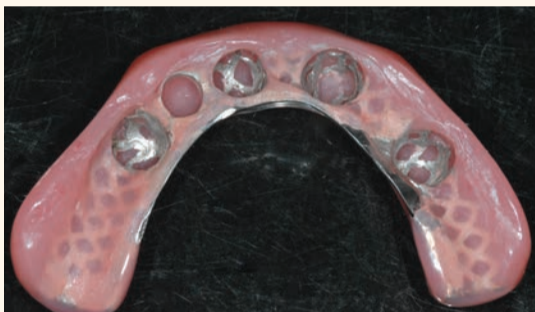

Figure 11. Completed laboratory restoration showing the metal frame and recessed area to receive the SynCone caps

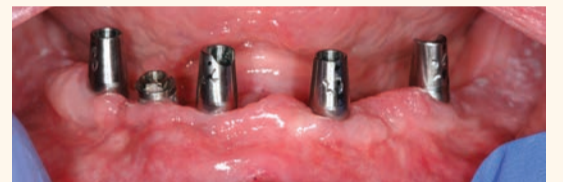

Figure 12. ATLANTIS Conus Abutments seated. Note the "margins" of the abutment, and the point where the parallel preparation begins, is supra-gingivally positioned

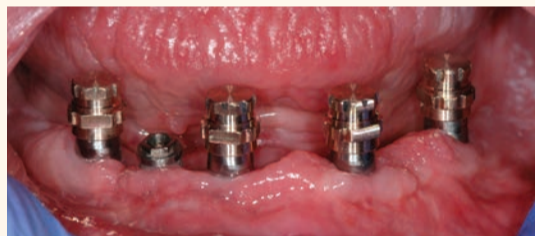

Figure 13. SynCone caps are fitted to the abutments to verify unobstructed and complete seating

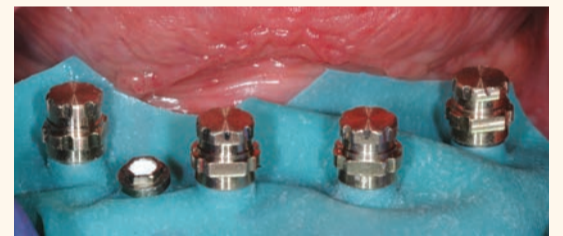

Figure 14. Rubber dam is placed over the abutments to prevent pick-up material from locking into undercut areas below the prepared margin. SynCone caps are seated and ready to be captured into the prosthesis

working cast. The cast metal frame was opaqued to prevent gray show-through. The set up was transferred to the cast with the metal frame and the dentures were processed (Figs. 10, 11).

Because the ATLANTIS Conus concept results in a fully implant-supported prosthesis, the peripheral borders of the finished structure were greatly reduced and the occlusal table was abbreviated at the first molar. The length of functional arch follows the identical AP spread principles used for hybrid prosthetics to avoid excessively long cantilevers.

At this point, the structure is a bridge and not an overdenture. To facilitate seating of the abutments in the patient, a clear matrix was made with the abutments on the original working cast; where they have remained since receipt. Each abutment was identified with one, two, three and four black ink dots respectively, based on their position on the cast. The clear matrix was seated over the abutments and corresponding black dots were drawn on it to line up exactly with those on the abutments. The completed mandibular bridge was double-side impressed by the dental technician and an injection-mold copy of clear acrylic resin was made.

The patient was scheduled for completion of treatment. The Locator abutments were again removed and Teflon tape was placed in the implant excluded from the design.

The abutments were seated onto the dental implants (Fig. 12), and the clear matrix was placed to verify that each abutment was correctly orientated by checking that the dots on the matrix superimposed with those on the abutments.

Once verified, the abutments were torqued to 20 Ncm, appropriate for the implants involved. The SynCone caps were placed and viewed with magnification to assure that they were superior to the gingival tissues (Fig. 13). The prosthesis was placed over the caps to verify there was no obstruction of complete seating. The prosthesis was removed and vent holes were drilled through the buccal contours of the acrylic resin to relieve hydraulic pressure during capture of the caps. The SynCone caps were lifted and a rubber dam was placed around the abutments to prevent pick-up resin from locking into undercuts, and the caps were re-seated (Fig. 14).

Attachment processing material (Chairside by Zest Anchors) was placed in the reservoirs of the prosthesis and seated over the SynCone caps. The upper denture was placed and the patient was instructed to gently close into full occlusion and to maintain position for two minutes while setting occurred. After two minutes, the excess flow of pick-up resin was checked for hardness and after an additional minute the prosthesis was ready for removal. Removal was uneventful although retention was considerable; removal

of the bridge can only occur following the long-axis of the abutments, no tipping or rotating is possible (Fig. 15, 16).

Once removed, the excess pick-up material was removed and the bridge was properly polished where needed. The abutments were packed with Teflon tape to within 3 mm of the surface, and the remaining space was filled with flowable composite resin (Fig. 17). The patient was instructed on placement and removal and repeated the exercise until we were satisfied she would experience no difficulties performing this. The clear, duplicate copy of the bridge was seated onto the abutments using a chair-side soft lining material (Fig. 18).

This copy serves as a temporary device for the patient to wear when cleaning the finished bridge or when sleeping to protect the tongue from scraping against the abutments. A panoramic radiograph was taken at completion of treatment (Fig. 19).

The patient returned after one week and again after six weeks, and reported at both visits that the lower bridge did not move at all during function and stayed seated until she removed it. She commented on the ease of cleaning the dental abutments, and she reported no discomfort and no food entrapment. Overall, the patient was very pleased with the result (Fig. 20).

Intraoral welding and lingualized (lingual contact) occlusion: a case report

ADA CER-P® Continuing Education Recognition Program

Centre for Advanced Professional Practices (CAPP) is an ADA CER-P Recognized Provider. ADA CER-P is a service of the American Dental Association to assist dental professionals in identifying quality providers of continuing dental education. ADA CER-P does not approve or endorse individual courses or instructors, nor does it imply acceptance of credit hours by boards of dentistry.

CAPP designates this activity for 1 CE Credits



mCME articles in Dental Tribune have been approved by:
HAAD as having educational content for 1 CME Credit Hours
DHA awarded this program for 1 CPD Credit Points

By Dr. Luca Dal Carlo, Dr. Franco Rossi, Dr. Marco E. Pasqualini, Dr. Mike Shulman, Dr. Michele Nardone, MD, Tomasz Grotowski, Dr. and Sheldon Winkler

Intraoral welding was developed by Pierluigi Mondani of Genoa, Italy, in the 1970s to permanently connect submerged implants and abutments to a titanium wire or bar by means of an electric current (Fig. 1). The current is used to permanently fuse the titanium to the abutments in milliseconds, so the heat generated does not cause any pathology or patient discomfort.

If possible the implants are placed without flaps. The titanium wire or bar is bent and aligned passively to the contour of the labial and lingual surfaces of the implants before applying the electric current to permanently connect titanium implants.

The technique follows a strict surgical and prosthodontic protocol, which includes using a number of implants as close as possible to the number of teeth to be replaced, achieving primary stability by engaging both cortical plates (bicorticalism), immediate splinting of the implants utilizing intraoral welding and immediate insertion of a fixed provisional prosthesis with satisfac-

tory occlusion. The technique provides for immediate loading and does not jeopardize the integration process.²

Although intraoral welding has been used successfully in Europe, especially Italy, for many years, it has yet to achieve everyday use in the United States.

Members of the Italian affiliate of the American Academy of Implant Prosthodontics, NuovoGISI, have long and successful experiences with immediate loading of maxillary implants connected together by intraoral welding.²

By inserting the prosthesis with adequate retention and stability the same day as the surgery, patient complaints and discomfort can be avoided or substantially reduced. The instantaneous stability that results from the splinting can reduce the risk of failure during the healing period. Intraoral welding can also eliminate errors and distortions caused by unsatisfactory impression making, as the procedure is performed directly in the mouth.

Intraoral welding can fulfil a great need for business and socially active

►Page 9

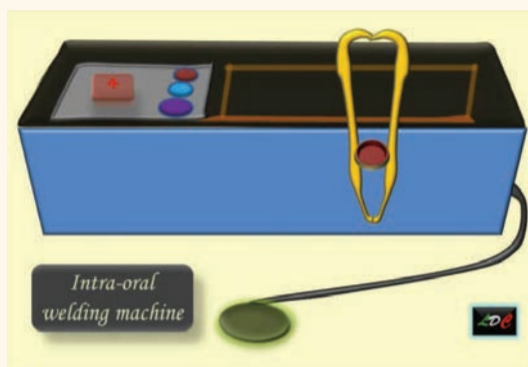


Fig. 1. Schematic drawing of Mondani intraoral solder unit

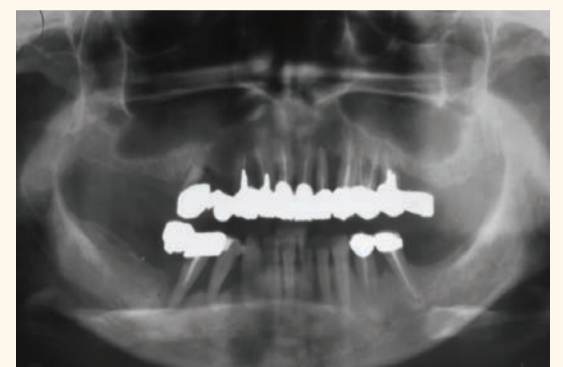

Fig. 2. Preoperative panoramic radiograph of 50-year-old caucasian woman

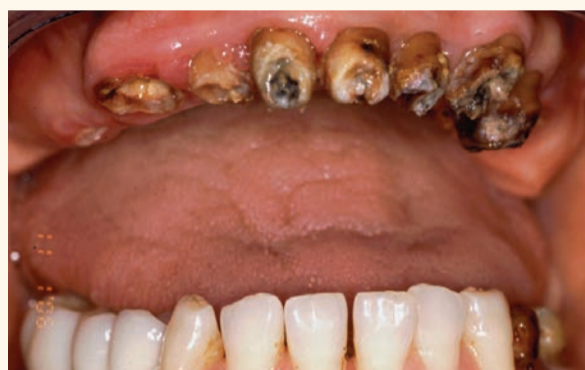

Fig. 3. Nonrestorable teeth visible after removal of the patient's prosthesis

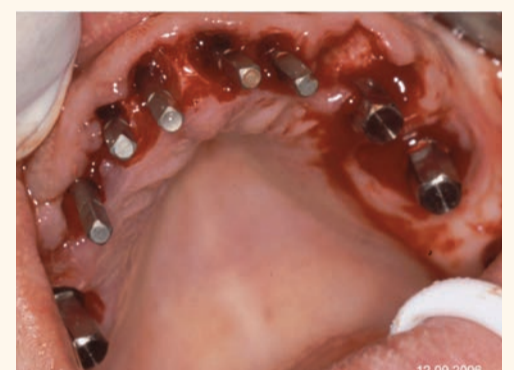

Fig. 4. Eight titanium one-piece implants are inserted.

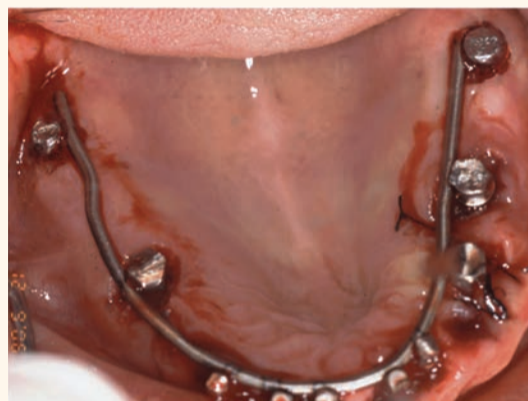


Fig. 5. Immediate stabilization of the eight implants and two additional implants previously inserted in the posterior regions, by welding each implant to a 1.5 mm supporting titanium bar

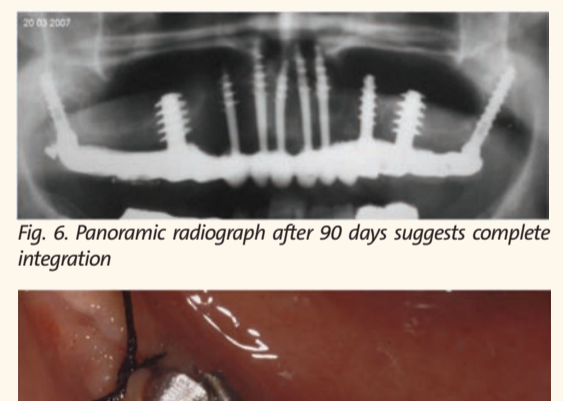

Fig. 6. Panoramic radiograph after 90 days suggests complete integration

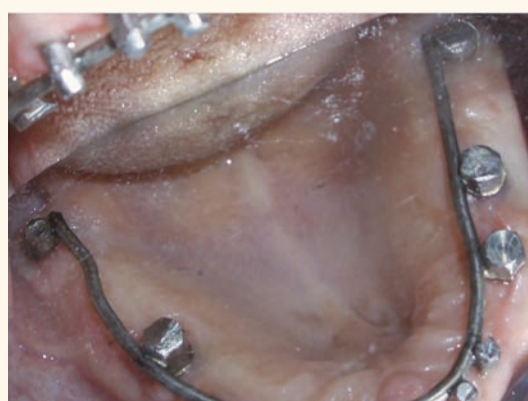

Fig. 7. Healthy gingiva was observed after 90 days

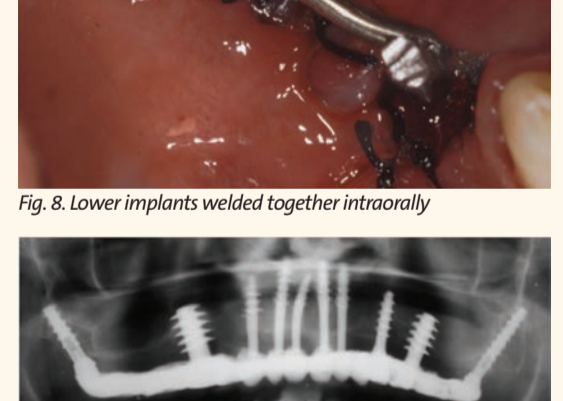


Fig. 8. Lower implants welded together intraorally

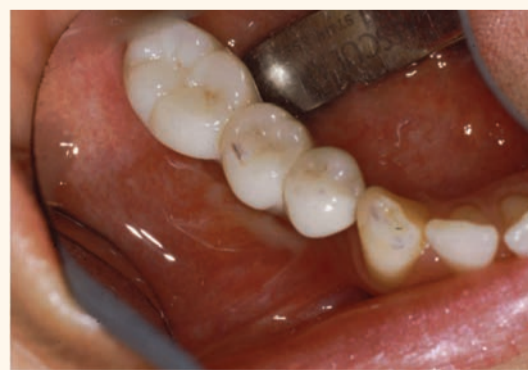

Fig. 9. Three-tooth mandibular fixed prosthesis

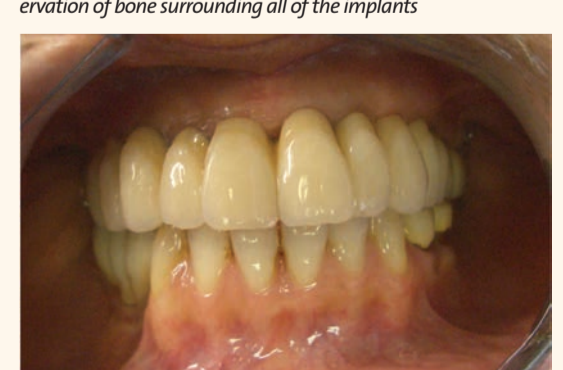

Fig. 10. Seven-year follow-up radiograph shows satisfactory preservation of bone surrounding all of the implants

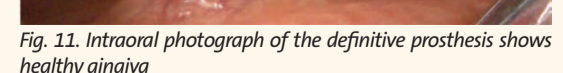


Fig. 11. Intraoral photograph of the definitive prosthesis shows healthy gingiva

mCME SELF INSTRUCTION PROGRAM

CAPPmea together with Dental Tribune provides the opportunity with its mCME - Self Instruction Program a quick and simple way to meet your continuing education needs. mCME offers you the flexibility to work at your own pace through the material from any location at any time. The content is international, drawn from the upper echelon of dental medicine, but also presents a regional outlook in terms of perspective and subject matter.

Membership

Yearly membership subscription for mCME: 1,100 AED
 One Time article newspaper subscription: 250 AED per issue. After the payment, you will receive your membership number and allowing you to start the program.

Completion of mCME

- mCME participants are required to read the continuing medical education (CME) articles published in each issue.
- Each article offers 2 CME Credit and are followed by a quiz Questionnaire online, which is available on www.cappmea.com/mCME/questionnaires.html.
- Each quiz has to be returned to events@cappmea.com or faxed to: +97143686883 in three months from the publication date.
- A minimum passing score of 80% must be achieved in order to claim credit.
- No more than two answered questions can be submitted at the same time
- Validity of the article – 3 months
- Validity of the subscription – 1 year
- Collection of Credit hours: You will receive the summary report with Certificate, maximum one month after the expiry date of your membership. For single subscription certificates and summary reports will be sent one month after the publication of the article.

The answers and critiques published herein have been checked carefully and represent authoritative opinions about the questions concerned.

Articles are available on www.cappmea.com after the publication. For more information please contact events@cappmea.com or +971 4 3616174

FOR INTERACTION WITH THE AUTHORS FIND THE CONTACT DETAILS AT THE END OF EACH ARTICLE.

◀Page 8

persons, as the surgical and prosthodontic procedures are accomplished on the same day. Patients can leave the dental office with a stable, esthetic and retentive prosthesis.

The flapless technique, first proposed by Tramonte³, can be performed when the bony crest is wide and an adequate amount of attached gingiva is present. The technique allows for uneventful healing, a reduction of postsurgical inflammation and only moderate inconvenience for the patient, who can eat efficiently the same day.

Provisional prosthesis and tooth arrangement

During the surgical session a temporary resin prosthesis is inserted. Occlusal plane height must be correct. A lingualized (lingual contact) scheme of occlusion is recommended. The upper anterior teeth are best arranged without any vertical overlap. The amount of horizontal overlap is determined by the jaw relationship. A vertical overlap for appearance can be used, provided that an adequate horizontal overlap is included to guard against interference within the functional range.⁴

Lingualized (lingual contact) occlusion

Lingualized (lingual contact) occlusion maintains the esthetic and food penetration advantages of anatomic teeth while maintaining the mechanical freedom of nonanatomic teeth. Among the advantages of a lingualized occlusion are occlusal forces centered over the ridge crest in centric occlusion, masticatory force is effectively transferred more "lingual" to the ridges during working side excursions, the "mortar and pestle" type of occlusion minimizes the occlusal contact area providing for more efficient food bolus penetration and elimination of the precise intercuspatation that can complicate the arrangement of anatomic denture teeth.

Lingualized occlusion also prevents cheek biting by holding the buccal mucosa off the food table by eliminating occlusal contacts on the maxillary buccal cusps, minimizes occlusal disharmonies created from errors in jaw relationships, denture processing changes and settling of the denture base, and simplifies setting of denture teeth, balancing the occlusion and any subsequent occlusal adjustment procedures.⁵

Clinical report

A healthy 50-year-old caucasian woman presented for treatment at the office of one of the co-authors (LDC) with a mobile, painful, 12-tooth semiprecious alloy-ceramic fixed prosthesis (Fig. 2). The prosthesis was removed and all of the remaining abutment teeth were found to be nonrestorable with extraction indicated (Fig. 3). After removal of the retained teeth, eight titanium one-piece implants were inserted in one session (Fig. 4).

Immediate stabilization of the eight implants and 2 additional implants that were previously inserted in the posterior regions was achieved by welding (Acerboni Intraoral Welding Unit, Casargo, Italy) each implant to a 1.5 mm supporting titanium bar (Acerboni, Casargo, Italy), which previously had been bent to fit passively on the palatal mucosa (Fig. 5). A provisional resin prosthesis was inserted, which provided an acceptable vertical dimension and lingual contact occlusion. Oral hygiene procedures were demonstrated to the patient and reviewed at all future appointments.

After 90 days, a panoramic radio-

graph suggested complete integration (Fig. 6) and a healthy mucosa was observed. (Fig. 7). The definitive full-arch gold-ceramic maxillary prosthesis was inserted, which greatly pleased the patient and her family.

In the lower arch, the right first and second bicusps were extracted and implants placed in the first bicuspid and first molar regions. The implants were welded together intraorally (Fig. 8), followed by the fabrication and cementation of a three-tooth fixed prosthesis (Fig. 9).

A 7-year follow-up radiograph (Fig. 10) shows satisfactory preservation of bone surrounding all of the implants. An intraoral photograph of the definitive prosthesis shows healthy gingival tissue (Fig. 11).

References

1. Mondani PL, Mondani PM. The Pierluigi Mondani intraoral electric solder. Principles of development and explanation of the solder using syncrystallization. *Riv Odontostomatol Implantoprosesi*. 1982;4:28-32.
2. Rossi F, Pasqualini ME, Dal Carlo L, Shulman M, Nardone M, Winkler S. Immediate loading of maxillary one-piece screw implants utilizing intraoral welding: a case report. *J*

Oral Implantol (in press).

3. Tramonte, S. A further report on intraosseous implants with improved drive screws. *J Oral Implant Transplant Surg*. 1965;11:35-37.
4. Winkler S, ed. *Essentials of Complete Denture Prosthodontics*. 3rd ed. Delhi, India: AITBS Publishers; 2015.
5. Lang BR, Lauciello FR, McGivney GP, Winkler S. *Contemporary Complete Denture Occlusion*, revision 4. Amherst, NY: Ivoclar Vivadent, 2012. **DT**

Dr. Luca Dal Carlo is in private practice in Venice, Italy. Dr. Franco Rossi is in private practice in Varese, Italy. Dr. Marco E. Pasqualini is in private practice in Milan, Italy. Dr. Mike Shulman is in private practice in Clifton, N.J., and adjunct associate professor at the School of Oral Health Sciences, Kingston, Jamaica. Dr. Michele Nardone is with the Ministry of Public Health, Rome, Italy. Dr. Sheldon Winkler is adjunct professor at Midwestern University College of Dental Medicine, Glendale, Ariz., and School of Oral Health Sciences, Kingston, Jamaica. Dr. Tomasz Grotowski is in private practice and professor at the School of Minimally Invasive Implantology, Szczecin, Poland.

◀Page 7

Discussion

The number of implants placed for an edentulous patient should be based upon whether the design is to be implant-assisted or implant-supported. If the goal is a minimalist design utilizing the soft tissue for support, two implants using Locator attachments are appropriate to retain a mandibular denture and will provide a predictable outcome. However, when more than two implants using resilient overdenture retainers are employed, there is not a corresponding linear increase in retention of the denture and the result may suffer. Therefore, when at least four implants are planned, the restoration should be designed as implant-supported to maximize the value of the patient's greater investment.

This article discusses just such a situation where a patient had experienced repeatedly low value from her investment of five implants. By redesigning her treatment to become implant-supported through the use of the ATLANTIS Conus concept, a successful result was achieved without the greater expense of a fixed hybrid. The final result was functionally comparable to a fixed restoration while providing lip and cheek support of a removable prosthesis without complicating or obstructing oral hygiene.

The telescopic design of the ATLANTIS Conus concept provides outstanding retention of the prosthesis during function as edentulous patients chew in a relatively flat elliptical pattern and the bridge can only be removed vertically. The abutments themselves are patient-specific and can be made for all major implant systems, allowing rescue of many frustrating results with overdentures.

As long as there is sufficient inter-arch space (at least 12 mm), existing finished dentures can be retro-fit with ATLANTIS Conus abutments, reducing patient cost while providing a stable result. Cast chrome frame reinforcement is advised for all new ATLANTIS Conus prosthe-

ses as the tremendous increase in strength of the bridge by the frame more than offsets the slight increase in cost and may actually reduce required inter-arch space.

The clinical procedure is relatively simple and comparable to implant overdentures; however, because

the abutments are patient-specific, tooth position must be established before the design of the abutments is begun.

Conclusion

A patient with an 11-year history of frustration with her dental implant

investment was treated successfully with the ATLANTIS Conus concept using patient-specific abutments and SynCone caps, providing an implant-supported, removable bridge with all the benefits of a fixed design and none of the limitations.

Acknowledgements

The author would like to thank Fred Senne, John Bergstresser and Sean Ferguson (DENTSPLY Implants) for their expertise and information. The author would also like to thank Tom Wiand and the talented team at Wiand Dental Laboratory for the laboratory procedures and products described in this article.

References

1. Zarb G A. The edentulous milieu. *J Prosthet Dent* 1983; 49: 825-831.
2. Fish E W. Using the muscles to stabilize the full lower denture. *JADA*, Dec 1933; 2163-69.
3. The Glossary of Prosthodontic Terms. Eighth edition. *J Prosthet Dent*, 2005, 94; 1: 10-92. **DT**

Editorial note: The full list of references is available from the publisher.

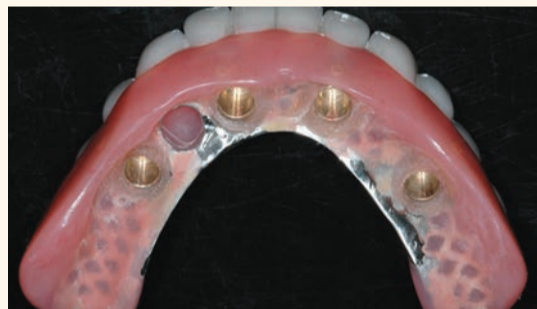

Figure 15. Completed bridge with SynCone caps processed in position. Because they have been processed intra-orally, there is no error in fit, these caps are extremely retentive allowing only vertical displacement of the prosthesis

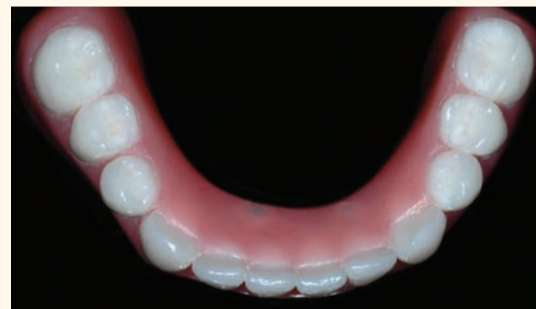

Figure 16. Completed restoration. Note the absence of screw access holes for a prosthesis that looks like a denture yet fits like a bridge

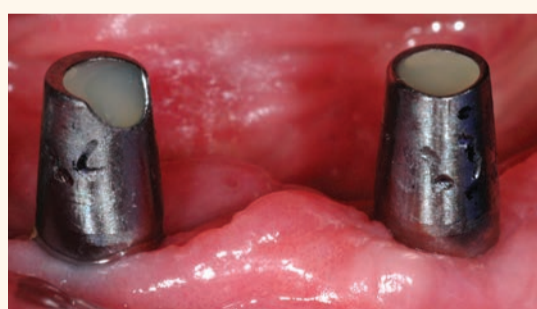

Figure 17. ATLANTIS Conus abutments torqued to specified level, obturated with Teflon tape and composite resin

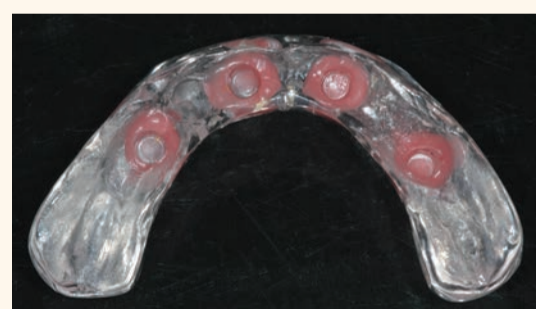


Figure 18. Laboratory processed, clear duplicate prosthesis with siliconized relene material to improve retention; to be used as a nighttime appliance to protect the tongue from the sharper edges of the abutments

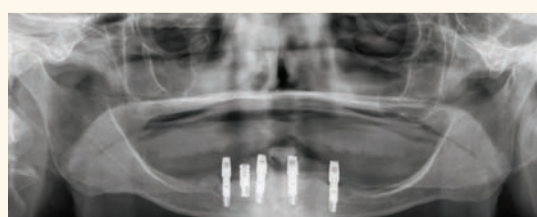


Figure 19. Panoramic radiograph of the abutments seated on the four selected implants. Because the restoration is fully implant-supported, gradual diminution of the residual ridge will present no consequence to the patient

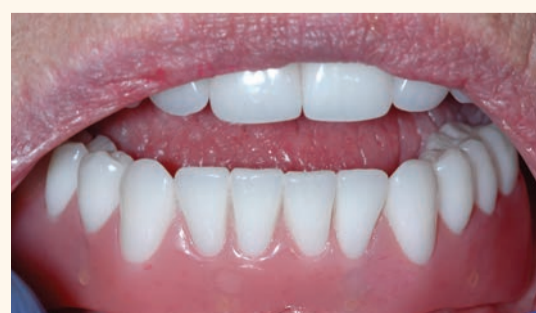

Figure 20. Completed bridge in place showing flange length suitable to prevent food



Dr. Marc Montana
Dr. Montana graduated from the University of Southern California School of Dentistry in 1987 and completed his certificate in Advanced Prosthodontics at USC in 1989. He has maintained a full-time private practice in Tempe, Arizona since 1989, emphasizing fixed, removable and implant prosthodontics. He has been a clinical instructor while attending USC and currently is a clinical instructor and lecturer in the Advanced Education of General Dentistry program at the Arizona School of Dentistry and Oral Health. He is a member of the Dentsply Implants' PEERS North America study club, the American College of Prosthodontists, the American Academy of Fixed Prosthodontics, the Pacific Coast Society for Prosthodontics, the Academy of Osseointegration and the American and Arizona Dental Associations. He has lectured extensively throughout North America on the topics of implant, fixed and removable prosthodontics. He can be reached at 480-820-2901 or office@markmontanadds.com