

implants

international magazine of oral implantology

1 2013



| **research**

Structure and volume in delayed immediate implantation

| **overview**

Applications of hollow osteotomes in dental Implantology

| **case report**

Treatment of a mandibular cyst with synthetic bone graft substitute



tiologic[®]

Implant system

Quality in Motion.



Discover it now on the IDS – Hall 10.1, Stand E10 / F11.



New augmentation materials—What is the gold standard?



Dr Rolf Vollmer

Now that we are on the verge of IDS, International Dental Show, I personally am eager to see what is going to be presented, especially with regard to the latest developments in bone augmentation materials. Osteogenesis takes place only in the sense of enclosing newly formed bone, which remains a biofunctionally foreign body within the augmented area for many years. The maxillary sinus seems to be a special subject and location with regard to osteogenesis. In sinus lift procedures with or without simultaneous implantation, many materials are working very well because of its special conditions. Lundberg et al. found out that the sinus is a sterile cavity. Its sterility is based on the epithelium cells' potential to produce nitric oxide, which has an aseptic effect. Another important factor for the regeneration of the augmented material is the blood supply, according to Benner and Schlehuber.

I think we all agree that, for small multi-wall defects, xenogeneic grafts are helpful and usually produce a non-vital, hard ceramic regeneration result. The subsequent drilling at such sites, however, is probably not a pleasure. In addition, many xenogeneic materials cannot be absorbed and the blending of autologous bone with xenogeneic material seems a challenge. In their studies at the University of Düsseldorf, Becker and Schwarz observed the best results with 50 % and a minimum of 30 % of autogenous bone in a mixture with a two-phase bone substitute material. Sinus lifts by crumbly grafts are easy to handle, but they should be given at least six to twelve months to heal. This amount of time can be a disaster for the patient. If it comes to an infection, the decomposition products of consequent mass cell deaths are a feast for invading bacteria. The situation for vertical augmentation is even worse. Bone graft materials of varying forms are available in unlimited quantities, which might make them suitable even for large defects. But do they really have high resorption stability and do they thus serve as guide rails for the ingrowths of new blood vessels and a subsequent osteoneogenesis?

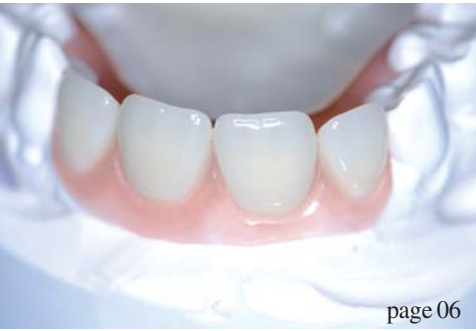In endogenous bone augmentation, I transfer vital cells, mineralised bone, fibrin and platelets and achieve a high biological potency for regeneration. In addition, I can then be sure that there will be no problems with the material I added to the bony structures. The fear of a second surgical defect is justified, but for smaller defects I can usually use the bone from the surgical site or nearby. Furthermore, I do not have additional material costs with autologous bone. Because of these considerations, I still use the endogenous bone for augmentation.

The surgeon has to decide upon the procedure after investigating the amount of bone that is missing. For this, DGZI wants to support our colleagues by postgraduate education and aid to decision-making.

I hope to see you all in Cologne, Germany, at our DGZI booth and look forward to discussing everything which can make our life easier and help our patients in the future.

Yours,

Dr Rolf Vollmer



page 06



page 24



page 28

| editorial

- 03 New **augmentation** materials—What is the **gold** standard?
| Dr Rolf Vollmer

| research

- 06 **Structure** and **volume** in delayed immediate **implantation**
| Dr Georg Bach *et al.*
- 14 **Mini implants**: a useful **complement** to conventional **implants**?
| Dr Friedhelm Heinemann *et al.*
- 20 **Ridge augmentation** for an **atrophied posterior mandible**—Part I
| Dr Omar Soliman *et al.*

| overview

- 24 Applications of **hollow osteotomes** in dental Implantology
| Dr Rolf Vollmer *et al.*

| case report

- 28 From **orthopaedics** to dental **implantology**
| Dr Suheil M. Boutros
- 34 Treatment of a **mandibular cyst** with **synthetic bone graft substitute**
| Dr Damian Dudek *et al.*

| industry report

- 38 Time proven **clinical success** of the SHORT™ **implant**
| Dr Vincent Morgan *et al.*

| news

- 42 **Manufacturer** News
- 48 **News**

| education

- 45 The next chapter in the **IDS success** story
| Koelnmesse

| events

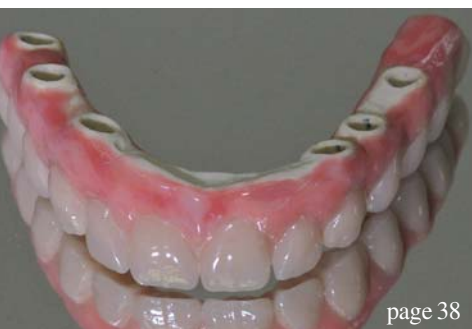- 46 More than 500 attendees visit **ISOI Conference** in **Tokyo/Japan**
| Dr Georg Bach

| about the publisher

- 50 | imprint



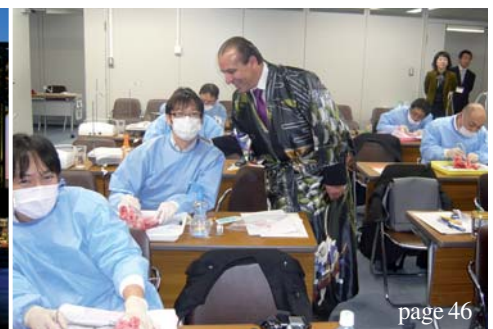Cover image courtesy of Bicon, www.bicon.com



page 38



page 45



page 46



CONOLOG® offers benefits!
www.camlog.com

**VISIT US
AT THE IDS
HALL 11.3
BOOTH A10-B19**



Excellent conical connection

Simple abutment positioning through three grooves and cams

Millionfold proven SCREW-LINE outer geometry

Highly precise transfer without transfer aid

High radial position precision

7 mm implants optionally available

BENEFITS

The CONOLOG® Implant System offers a comprehensive prosthetic portfolio for all indications. The conical implant/abutment connection with its proven CAMLOG positioning through three grooves and cams provides maximum precision and user-friendliness. More infos: www.camlog.com

CAMLOG® offers benefits!

a perfect fit™

camlog

Structure and volume in delayed immediate implantation

Authors_Dr Georg Bach & Christian Müller, Germany

Introduction

Delayed immediate implantation is a viable alternative to immediate implantation, for which there is no distinct evaluation in the literature, and a "regular" implantation after complete osseous healing of the former extraction area, generally associated with volume loss.

Loss of osseous volume after extraction of a non-conservable tooth may be a limiting factor for later implantation. To avoid this problem, many authors recommend immediate implantation, where an implant is inserted immediately after careful and gentle tooth extraction. In cases where immediate implantation is not wanted or possible, delayed immediate implantation after reconstruction of the former tooth area, which is generally carried out three to four weeks after extraction of the non-conservable tooth, is a viable alternative. If the alveolus is (still) mostly intact after extraction, the precondition for immediate implantation can be optimised with a collagen membrane and cone unit.

The procedure presented in the form of the following three exemplary patient cases also acknowledges this easy surgical procedure.

The focus of interest is on procedures for preserving osseous volume after extraction—many authors emphasise the value of closing the wound by means of a "punch", which they claim to have considerable advantages with regard to protection against resorption. Undisturbed growth of bone-forming cells in the former tooth socket is promoted by preventing the connective tissue from growing into the alveolus. However, this procedure presents more of a challenge for the surgical skills of the dental surgeon in terms of production and insertion, and it is more demanding for the patient, both surgically and financially.

The insertion of so-called collagen membrane and cone units can simplify closure of the alveolus considerably and avoid removal of the punch at a later time. A second procedure is not required because of the absorbability of the material, since the collagen membrane cone unit does not have to be removed.

Procedure

The manufacturer recommends the following procedure for the insertion of collagen membrane and cone unit:

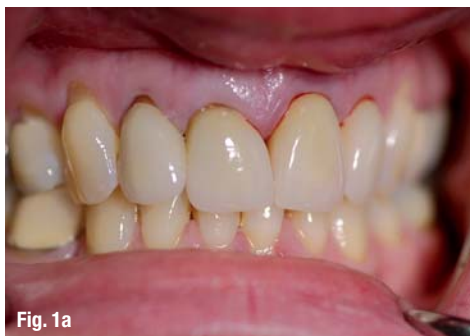

Fig. 1a

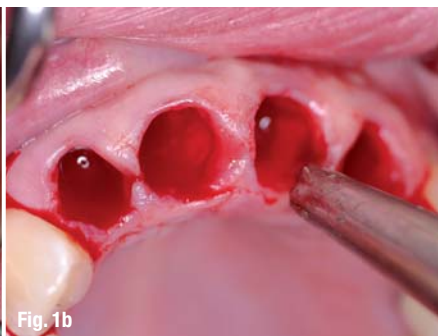


Fig. 1b

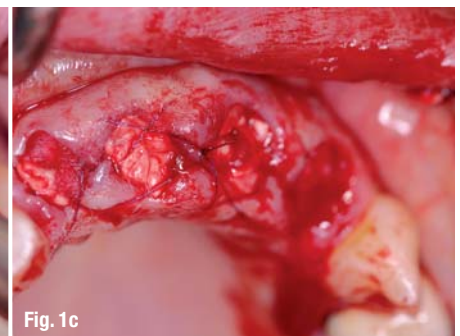


Fig. 1c

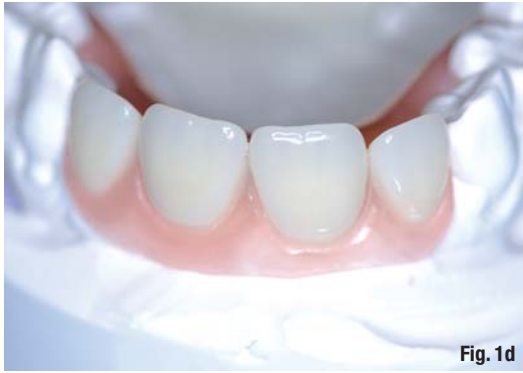

Fig. 1d

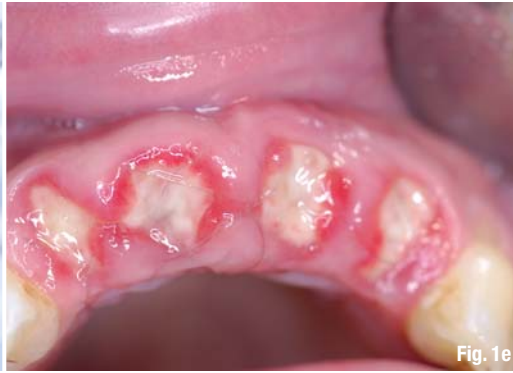

Fig. 1e

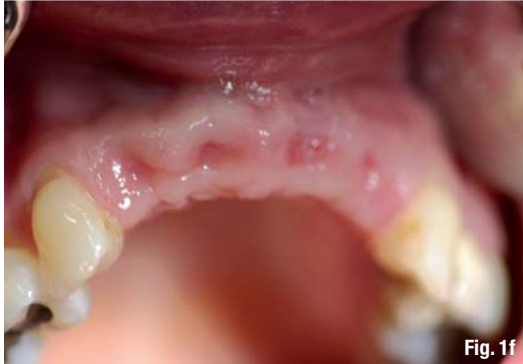

Fig. 1f

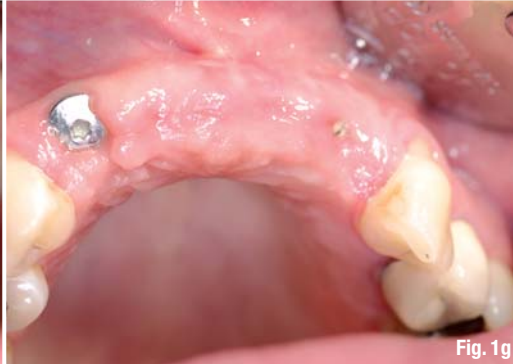

Fig. 1g

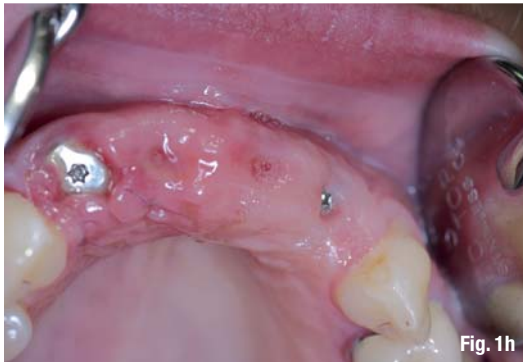

Fig. 1h

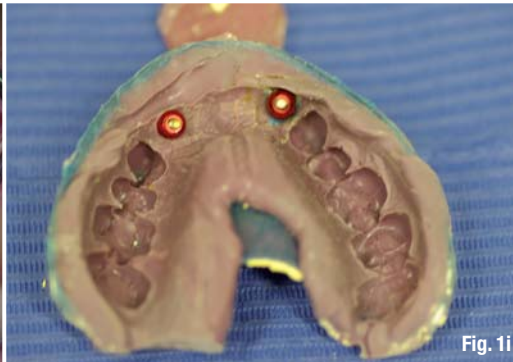


Fig. 1i

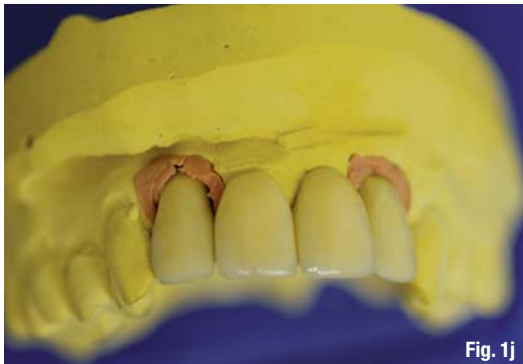

Fig. 1j

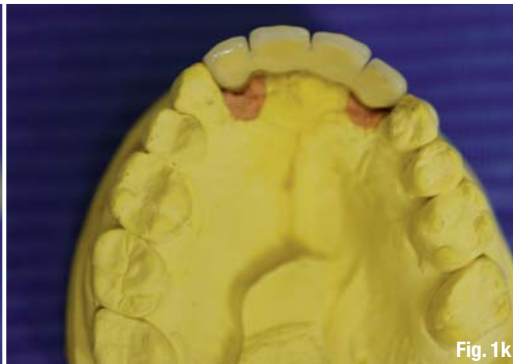

Fig. 1k

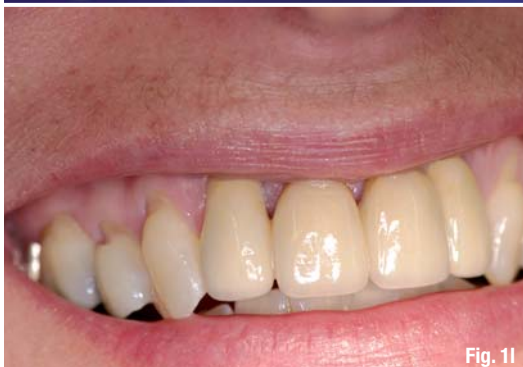

Fig. 1l

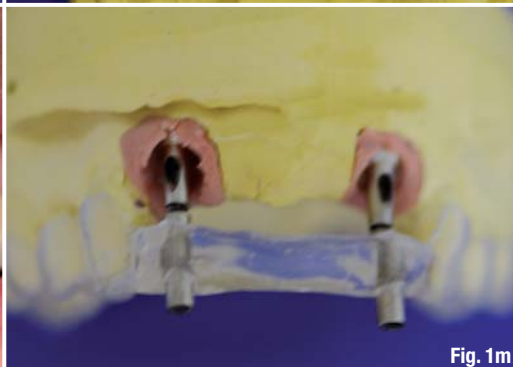

Fig. 1m

Case 1

Due to an extensive dental history, none of the anterior teeth of the maxilla were conservable (Fig. 1a) and had to be removed gently (Fig. 1b). Immediately following extraction of the teeth, collagen and membrane cones were inserted (Fig. 1c) for the purpose of socket preservation and integration of the previously produced (Fig. 1d) interim prosthesis. Figures 1e and 1f show the clinical situation one and four weeks after surgery; Figure 1g shows the situation after delayed immediate implantation. The intraosseous suture material was removed seven days after implantation (Fig. 1h). After completion of the osseointegration phase, the casting was done (Fig. 1i), followed by insertion of the abutments using the prepared insertion aid (Figs. 1j–l). Figure 1m shows the exact conformity between planning (template) and achieved result (abutments).

Case 2

In the right half of the maxilla, the two remaining posterior teeth were fractured and deeply damaged by caries (Fig. 2a), thus non-conservable. The two alveoli remained largely intact (Fig. 2b) after gentle removal of the roots, and a customised collagen membrane and cone unit was inserted (Fig. 2c).

The suture material was removed one week after surgery (Fig. 2d).

After four weeks, the bone bed showed no irritation and a primary reconstruction to a large extent. We were able to insert two implants after this short waiting period. Figure 2e shows the condition after implant bed drilling; Figure 2f shows the two inserted implants. Please also see the corresponding dental panoramic X-ray (Fig. 2g).

Upon completion of the osseointegration period, the implants showed no irritation (Fig. 2h), so that the impression could be taken with a customised spoon (Fig. 2i) and the dental lab work (Figs. 2j and k) was executed. Figure 2l shows the inserted abutments, and figure 2m shows the integrated product in the patient's mouth. Figure 2n shows the corresponding sagittal view.

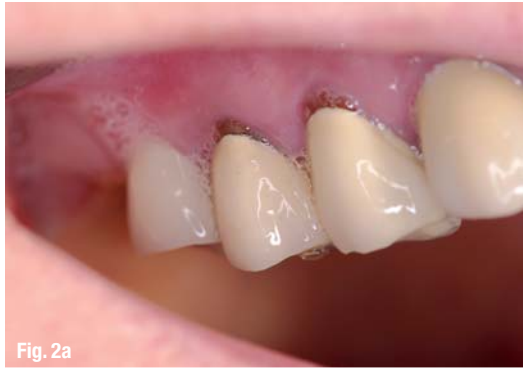

Fig. 2a

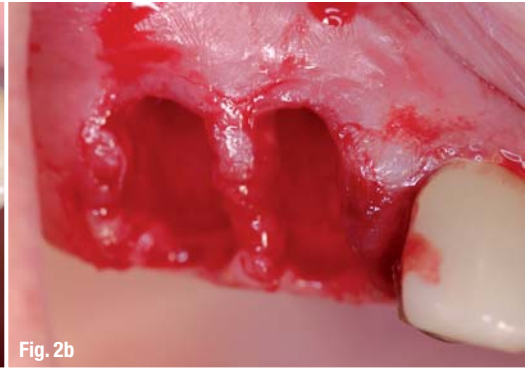

Fig. 2b

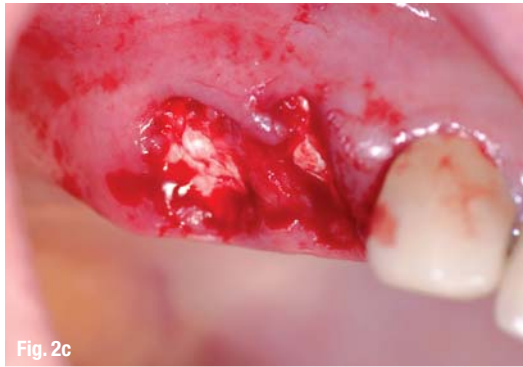

Fig. 2c

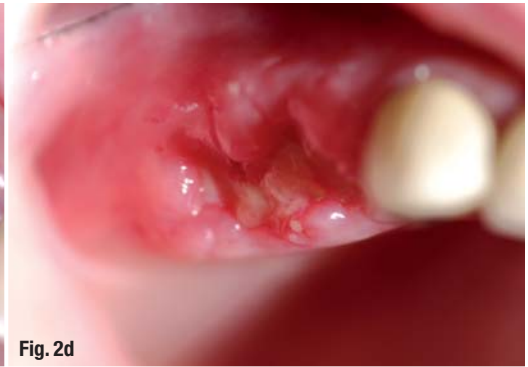

Fig. 2d

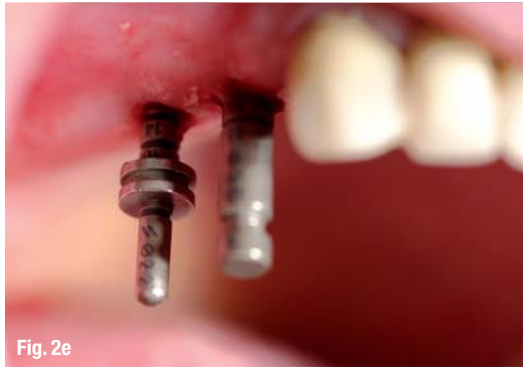

Fig. 2e

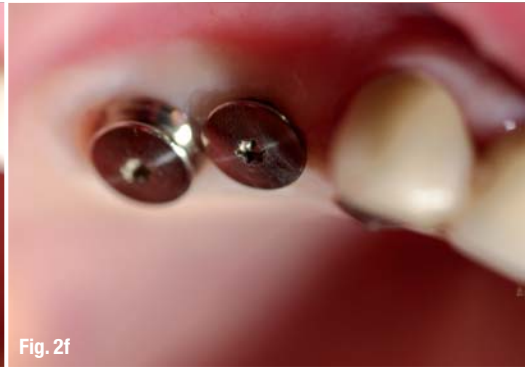

Fig. 2f

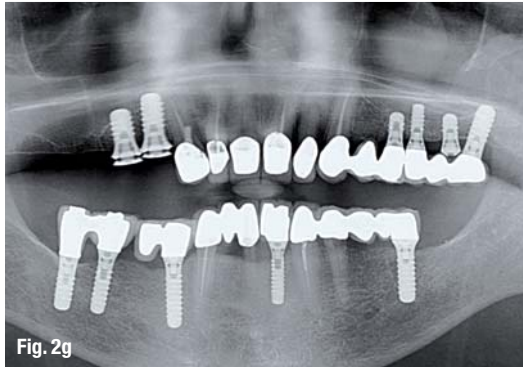


Fig. 2g

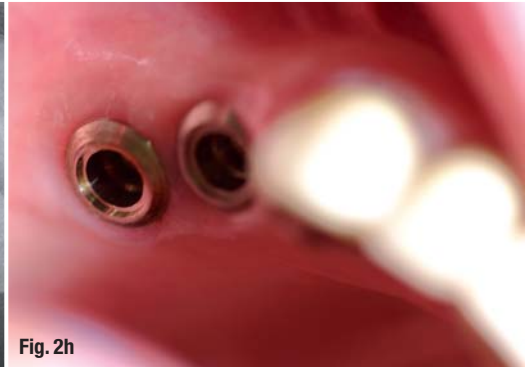


Fig. 2h

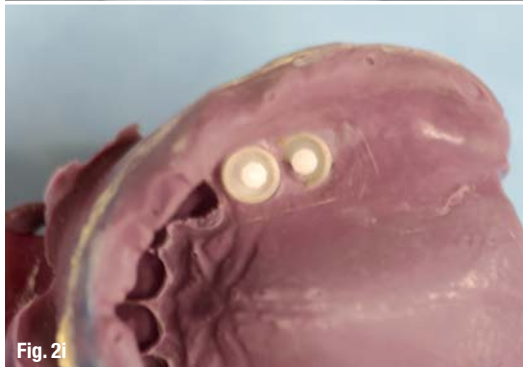

Fig. 2i

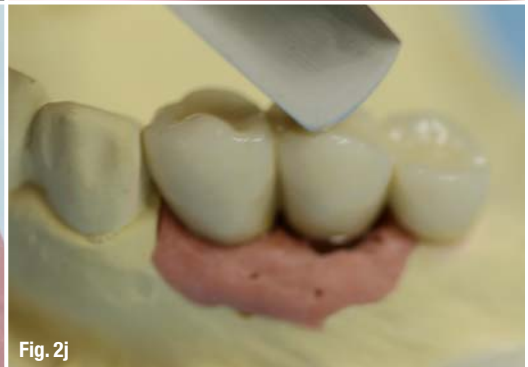

Fig. 2j

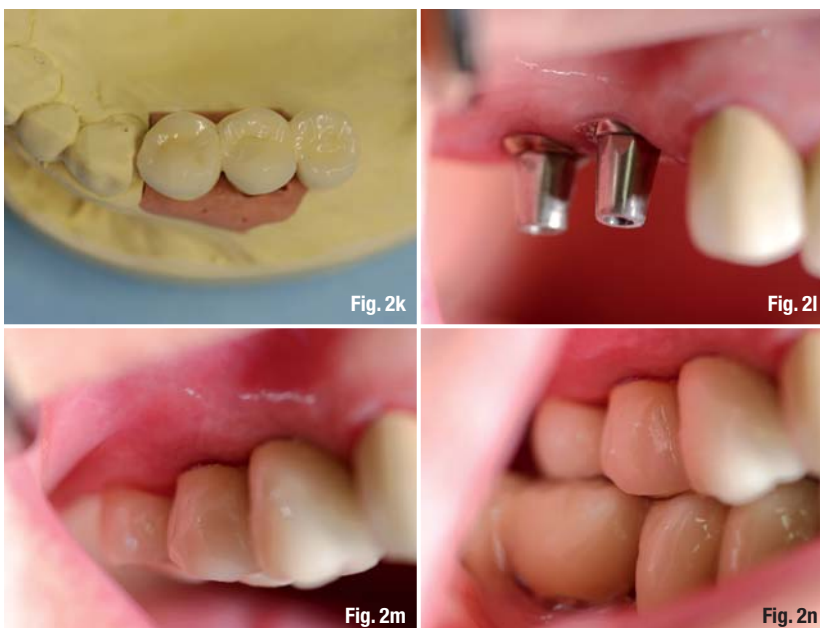


Fig. 2k

Fig. 2l

Fig. 2m

Fig. 2n

1. Preparation for a tight closure

After gentle and non-traumatic extraction of the non-conservable tooth, the marginal gingiva is minimally detached to the alveolar process so that the free membrane side of the collagen membrane and cone unit can be inserted.

2. Customising collagen membrane and cone unit

Moistening is to be avoided because this would make it more difficult to achieve a good fit to the alveolus. Rather, the collagen cone is fitted to the alveolus with the scalpel, and the membrane is configured with small scissors to facilitate insertion under the marginal edges, while at the same time achieving an ideal defect-congruent coverage. To achieve this, the dimensions of the membrane should be approximately 1–2 mm wider than the diameter of the alveolus.

3. Insertion of collagen membrane and cone unit

Using dry, anatomical, wide tweezers, the collagen membrane and cone units are inserted into the alveolus and then pushed in deep with a moist swab. The membrane part should be seated exactly at the level of the marginal gingiva. Now the free and slightly oversized part of the membrane is pushed carefully under the edges of the marginal gingiva.

4. Protective measures

A back-and-forth suture with a non-absorbable suture material will secure the position of the collagen membrane and cone unit in the alveolus and also adapt the free gingiva edges on the membrane.

_Case presentations

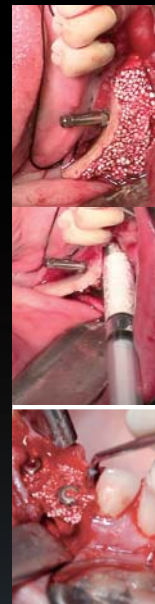The following three patient cases serve to illustrate and ultimately evaluate the procedure of a delayed immediate implantation using an absorbable collagen membrane and cone unit.

Case 1: Four non-conservable teeth in the anterior maxilla

Due to a trauma of the anterior teeth during adolescence, the patient received endodontic treatment and crowns on the four front teeth, which—after recurring problems—resulted in apicoectomies. The second set of crowns at ten years after the first prosthetic treatment was followed immediately by a second resection due to persistent discomfort. The patient is in her late thirties, and now the four front teeth 12,

sticky granules

bionic



easy-graft®CRYSTAL



easy-graft®
CRYSTAL

Ingenious: Simple handling and accelerated osteoconduction for long-term volume preservation.

SUNSTAR
GUIDOR®

Degradable Solutions AG
A Company of the Sunstar Group
Wagistrasse 23
CH-8952 Schlieren/Zurich
www.easy-graft.com