

# DENTAL TRIBUNE

—The World's Dental Newspaper • Middle East & Africa Edition—

Printed in Dubai

www.dental-tribune.me

July-August 2014 | No. 4, Vol. 3



## EVENT


**6th Dental Facial Cosmetic Int'l Conference**  
14-15 November 2014

>Jumeirah Beach Hotel Dubai

## mCME

**"Dental Photography Part II: Protocol for shade taking and..."**

>Page 6



## NEWS

**"New treatment center from Sirona: Quality 'made in Germany'..."**

>Page 4



The Palace Hotel Downtown Dubai, UAE

## CEREC Desert Fest

12-13 September, 2014  
DUBAI, UAE

*Part of Continuing Dental Education CAPP Series Dubai Dental Meetings*

### By Centre For Advanced Professional Practices (CAPP)

**D**UBAI, UAE: CAPP has the pleasure to welcome you to a Dubai dental meeting from the upper echelon in Dental Medicine at the spectacular The Palace Hotel Downtown Dubai. The full solution for

clinical and Lab restorations, designed for beginners, advanced and future CEREC users will get together the 'creme de la creme' in Prosthodontics, Implantology, Aesthetics and digital dentistry. An event, first of its kind taking place in the heart of Dubai featuring exceptional panelists and trainers, rounding up with an

unforgettable social program.

The event featuring Dentists and Dental Technicians – beginners, advanced and future CEREC users who are just considering this revolutionary system or for the professionals who would like to keep up with latest trends in high tech dentistry. The two days

will cover a Panel Show on 12th of September and Table Clinic Presentations on 11, 12 and 13th September 2014.

The panel show on 12th September, known as CEREC Desert Fest will look at the networks, which exist within the digital dental world. The five panelists

with their vast knowledge will show how fast the digital technology and science joined up unexpectedly in dentistry, faster than we ever imagined. All panelists will have debates after each presentation amongst each

> Page 4

## Dr. Aisha Sultan Al Suwaidi officially elected to lead the APDF for 2014-2015



Dr. Aisha Sultan Al Suwaidi, President Emirates Dental Society

### By Emirates Dental Society

**D**UBAI, UAE: In the presence of His Excellency, the Minister of Health, Dr. Abdulrahman Al Oweiss, Dr. Aisha Sultan Al Suwaidi, Head of Dental Services in Ministry of Health and Head of Dental Chapter of Emirates Medical Association, has been officially elected to lead the Asian Pacific Dental Federation for the year 2014-2015.

Representatives of 32 countries attended the ceremony. Accordingly, the United Arab Emirates has hosted the Asian Pacific Dental Congress from 17-19th June 2014, with pre-congress workshop and a very rich scientific program. [DT](#)

## Over 1,580 dental professionals attended the 9th CAD/CAM & Digital Dentistry Int'l Conference

### By Dental Tribune MEA

**D**UBAI, UAE: The 9th edition of the CAD/CAM & Digital Dentistry International Conference gathered 1,580 dental professionals, leading industrial players and visitors from 37 countries at the Jumeirah Beach Hotel on 09-10 May 2014 for the biggest Digital Dentistry Show.

### Participants Feedback

We received great feedback from participants attending the conference, which can all be summarized into a message



Social gathering at 9th CAD/CAM & Digital Dentistry Int'l Conference on 09-10 May 2014

> Page 34

## NEWS

Page 4

"New treatment center from Sirona: Quality 'made in Germany' at an attractive price"

## ACADEMIA TRIBUNE

Page 13

Pulp protection in today clinical practice: what about the role of materials?

## HYGIENE TRIBUNE

Page 17

"Philips introduces its best brush yet, Sonicare DiamondClean..."

"How much do you care for your hands?"

## CAD/CAM TRIBUNE

Page 22

"KaVo CAD/CAM workflow with the new products..."

Page 25

"Simple, planned aesthetic orthodontics for..."

## ORTHO TRIBUNE

Page 33

"Management Of Ectopically Erupted First Permanent Molars"

# Dental Wings integrates Neodent implants into guided surgery software

By Dental Tribune International

**CURITIBA, Brazil/ MON-TREAL, Canada:** Dental Wings, international provider of CAD/CAM and guided surgery solutions for dental laboratories and clinics, has announced that it has integrated products from Brazilian implant manufacturer Neodent into its coDiagnostiX software. Through the collaboration, users of the guided surgery software will gain access to Neodent's implant and sleeve system, consisting of two implant series, three sleeves and one fixation pin.

Neodent is one of the leading dental implant companies in Latin America and targets the nonpremium segment in the implant market, thus making its products accessible to a broader population. According to Matthias Schupp, Neodent's executive vice president of sales and marketing, the company has sold over 5 million implants to about 30,000 clinicians worldwide already.

Frank Stockmann, vice president of guided surgery at Dental Wings, said that his company is pleased to be able to give its cus-

tomers access to products from one of the most rapidly expanding implant companies in the world through its coDiagnostiX software. "We are confident that Neodent customers will enjoy the benefits of a sophisticated and user-friendly guided surgery solution," he added.

Neodent was founded in 1993 and was the first Brazilian company in the implant segment to receive certification from the Brazilian ministry of health. Headquartered in Curitiba in Brazil, the company runs subsidiaries in the U.S., Mexico,

Portugal and Spain. Today, Neodent employs more than 900 people, operates more than ten branches in Brazil and works with a wide network of distributors.

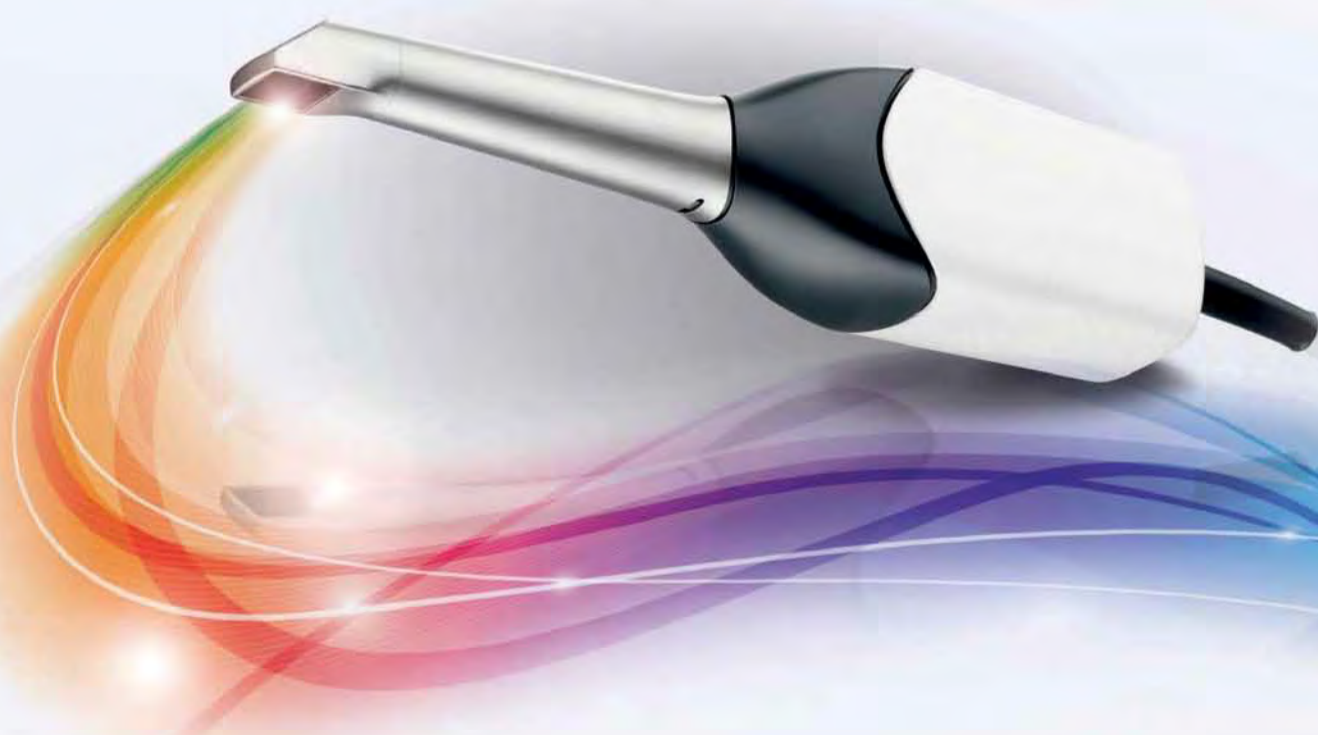In addition to coDiagnostiX, which was acquired from Straumann in 2013, Dental Wings offers an open CAD/CAM platform called DWOS, both of which are aimed at improving the quality of restorations and dental treatment, and increasing the productivity of laboratories and clinicians. The company announced that coDiagnostiX will be fully integrated with the DWOS platform by fall 2014. **DT**

SIRONA.COM

CEREC Omnicam

## POWDER-FREE AND IN NATURAL COLOR.

Scanning with the new CEREC Omnicam combines powder-free ease of handling with natural color reproduction to provide an inspiring treatment experience for the patient. Discover the new simplicity of digital dentistry. **Enjoy every day. with Sirona.**



Dubai Contact: Sirona Dental Sytsems Ltd, Dr Amro Adel, Building 49, Suite 304  
Dubai Healthcare City, Telephone: +971 4 375 2355, E-Mail: amro.adel@sirona.com

Kuwait Contact: Sirona Dental systems GmbH, Dr. Mostafa Al. Khouly  
Office: +965 2 224 6063, Mobile: +965 9 800 2225

The Dental Company

sirona.

### DENTAL TRIBUNE

—The World's Dental Newspaper—Middle East & Africa Edition—

#### GROUP EDITOR

Daniel Zimmermann  
newsroom@dental-tribune.com  
+49 541 48 474 107

#### CLINICAL EDITOR

Magda Wojtkiewicz

#### ONLINE EDITORS

Yvonne Bachmann  
Claudia Duschek

#### COPY EDITORS

Sabrina Raaff  
Hans Motschmann

#### PUBLISHER/PRESIDENT/CEO

Torsten Oemus

#### DIRECTOR OF FINANCE & CONTROLLING

Dan Wunderlich

#### BUSINESS DEVELOPMENT MANAGER

Claudia Salwiczek

#### EVENT MANAGER

Esther Wodarski

#### MEDIA SALES MANAGERS

Matthias Diessner (Key Accounts)  
Melissa Brown (International)  
Peter Witteczek (Asia Pacific)  
Maria Kaiser (USA)  
Weridiana Magewski (Latin America)  
Hélène Carpentier (Europe)

#### MARKETING & SALES SERVICES

Nadine Dehmel  
Nicole Andrä

#### ACCOUNTING

Karen Hamatschek

#### EXECUTIVE PRODUCER

Gernot Meyer

#### DENTAL TRIBUNE INTERNATIONAL

Holbeinstr. 29, 04229 Leipzig, Germany  
Tel.: +49 541 48 474 302  
Fax: +49 541 48 474 175  
www.dental-tribune.com  
info@dental-tribune.com

#### REGIONAL OFFICES

**ASIA PACIFIC**  
Dental Tribune Asia Pacific Limited  
Room A, 20/F, Harvard Commercial  
Building,  
105-111 Thomson Road, Wanchai,  
Hong Kong  
Tel.: +852 3115 6177  
Fax: +852 3115 6199

#### THE AMERICAS

Tribune America, LLC  
116 West 25rd Street, Ste. 500, New York,  
N.Y. 10011, USA  
Tel.: +1 212 244 7181  
Fax: +1 212 244 7185

#### DENTAL TRIBUNE MIDDLE EAST & AFRICA

#### EDITION EDITORIAL BOARD

Dr. Aisha Sultan Alsuwaidi, UAE  
Dr. Ninette Banday, UAE  
Dr. Nabeel Humood Alsabeeha, UAE  
Dr. Mohammad Al-Obaida, KSA  
Dr. Meshari F. Alotaibi, KSA  
Dr. Jasim M. Al-Saeedi, Oman  
Dr. Mohammed Sultan Al-Darwish  
Prof. Khaled Balto, KSA  
Dr. Dobrina Mollova, UAE  
Dr. Munir Silvadi, UAE  
Dr. Khaled Abouseada, KSA  
Dr. Rabih Abi Nader, UAE  
Dr. George Sanoop, UAE  
Retty M. Mathew, UAE  
Rodny Abdallah, Lebanon  
Victoria Wilson, UK

#### PARTNERS

Emirates Dental Society  
Saudi Dental Society  
Lebanese Dental Society  
Qatar Dental Society  
Oman Dental Society  
Int'l Federation of Dental Hygienists

#### DIRECTOR OF mCME

Dr. Dobrina Mollova  
mollova@dental-tribune.me  
+971 50 42 43072

#### BUSINESS PARTNER | BDM

Tzvetan Deyanov  
deyanov@dental-tribune.me  
+971 55 11 28 581

# CEREC

## *Desert Fest*



Panel  
Show

Desert  
Night

Clinic  
Presentations

The Palace Hotel Downtown  
12-13 September 2014  
Dubai, UAE  
[www.cerecfest.cappmea.com](http://www.cerecfest.cappmea.com)

# New treatment center from Sirona: Quality “made in Germany” at an attractive price

By Sirona

**B**ENSHEIM, Germany: On May 12, Sirona, global market and technology leader in the dental industry, has introduced a new treatment center: INTEGO offers top quality and flexible configuration options at an attractive price.

All dentists around the world share a common wish: To provide their patients with the best possible treatment. That's why they ideally want to work with high-quality devices and systems which offer optimum support for their day-to-day work. The treatment center plays a key role here; after all, this is where they spend a large part of their working day. As the global innovation and technology leader in the dental industry, Sirona has developed a new product generation for the treatment center division. This new product line can be very flexibly configured to suit the needs of various practitioners – introducing INTEGO! “Dentists should not have to forego outstanding quality, innovative features and modern design depending on how much they can afford to invest in a new center”, explained Michael Geil, Vice President Treatment Centers at Sirona and Managing Director of the Bensheim



Sirona CEO Jeffrey T. Slovin explaining the new INTEGO. The treatment unit was developed over a period of four years. (Photo: Daniel Zimmermann, DTI)

site in Germany. “INTEGO is a future-proof, high-quality German product which satisfies these demands.”

## Top quality and flexible configuration options

The new treatment center comes in two versions: INTEGO and INTEGO pro with extended functionality. Each model can be supplied as a hanging hoses model (TS) or with whip arms (CS) in a wide range of shades. Both versions are based on a chair concept which takes the four dimensions of ergonomics into account – intuitive sitting, comfortable positioning, optimum visibility and integrated workflows – and thus ensures that practitioners achieve ideal

results. The individual functions, the instruments and all the settings can be simply selected and controlled via an intuitive user interface. In comparison, INTEGO pro offers enhanced functionality. Some features, e.g., the 4-way foot switch and the automatic disinfection device, are even included in the basic INTEGO pro model. Furthermore, INTEGO pro offers more optional functions: For example, the customer can choose features such as the ApexLocator.

## INTEGO is the perfect complement to the product family

INTEGO is an ideal addition to Sirona's treatment center product family and fills the gap



Dental Tribune MEA was invited to the official Sirona presentation of INTEGO and Sirona Factory visit Bensheim.

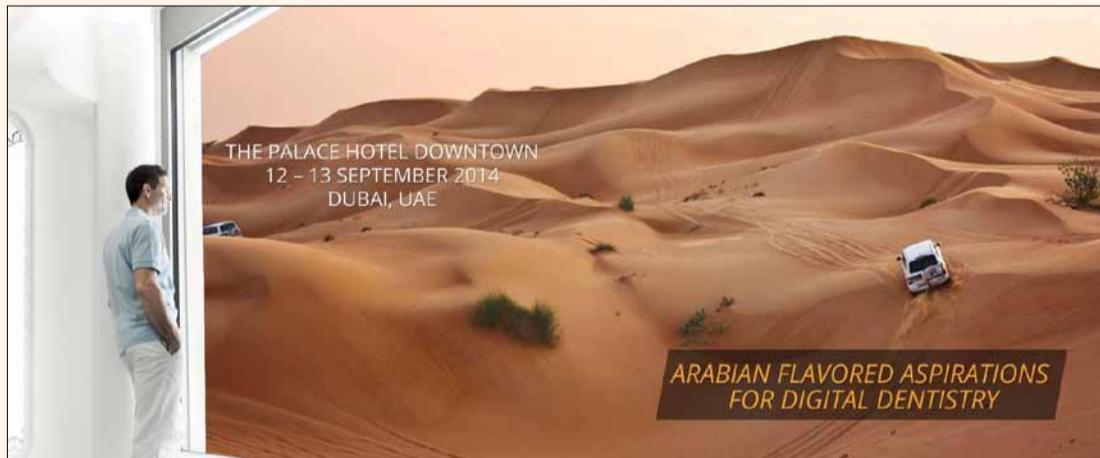
between C8+ and SINIUS. With INTEGO TS and CS versions, the dentist element can be positioned above the patient. In contrast, TENEO and SINIUS feature a sliding track which positions the dentist element either automatically or manually. As high-end products, SINIUS and TENEO also offer motorized functions, for example an adjustable headrest, a massage function to ensure patient comfort as well as the option of hand-free operation of the center. As such, Sirona satisfies a wide range of the most diverse requirements made by dentists and patients alike. The treatment centers represent high-quality and proven solutions at an attractive price. As with all other Sirona centers,

the INTEGO is also produced in Bensheim, Germany, where it is put through its paces. The long-lasting design, use of high-quality, robust materials, product quality “made in Germany” and a focus on ergonomic operating procedures and patient comfort make this a treatment center which is not only future-proof, but also facilitates the everyday working lives of dentists and assistants. INTEGO is available now from dental dealers. More detailed information on the functions and specifications of this treatment center can be found at the official Sirona company website. The price of the INTEGO will vary between 15.000 and 25.000 Euro, depending on individual configuration. <sup>DTI</sup>

< Page 1

other on stage. Open discussions with CEREC followers from the public will be made available through live-stream feed and the audience onsite in Dubai.

Let's look into what are our panelists are preparing for the delegates. Dr. Todd Ehrlich, who is using CEREC for a long time, said: “It is truly powerful this idea of a one visit dentistry – it's awesome! The Omnicam from Sirona is by far the greatest invention in dentistry today. I love using this thing every single day.” And his suggestion: “Make sure you get a good demo of it



Arabian Flavored Aspirations For Digital Dentistry.

*“I am honored to be a part of such a fine group of clinicians! This looks like a fabulous event!”*

- Dr. Todd Ehrlich, USA

– you are going to be fascinated how easy this camera really works. You can see his whole practical presentation about what the Omnicam can do on [www.cerecfest.cappmea.com](http://www.cerecfest.cappmea.com).

Dr. Bernd Reiss, teacher at the German Institute for Advanced Dental Studies since 1999 is a President of the Association for Ceramics in Dentistry and Executive Director ISCD. Since 1987 he lectured at more than 400 seminars, congresses and workshops in more than 40 different

countries worldwide. At CEREC Desert Fest he will bring a new Dimension into CAD CAM Dentistry with CEREC 2014. Clinical possibilities in the Dental practice, integration of different digital systems and integration of time in different ways will bring you to the question: What can we expect?

“It's incredible how easy and fast new users learn to operate the new Camera CEREC Omnicam. Come learn and engage in this one day lecture/hands-

on and discover in how you can integrate CEREC Omnicam to your practice.” - Dr Vasquez. Dr. Vasquez develops his passion for CAD-CAM dentistry leading him to be trainer for Patterson Dental and Sirona Dental Latin-American. He has lectured nationally and internationally for Sirona Dental Systems on CEREC

*“Digital advancements in dentistry are growing at a break-neck speed” - Todd Ehrlich, DDS*

BlueCam and Omnicam in restorative process, integration of CEREC / Galileos and “Speaking the same language with Sirona Connect”. Dr. Vasquez is an Apollo DI beta tester for Sirona Dental, Co-founder of CEREC®

En Español, Speaker/ trainer for CEREC On Demand and Trainer of Trainers for CEREC Latin America. “The Evolution of Simplicity with CEREC AC, New Possibilities No Alternative” - The only limitation you have today with the CEREC systems is your own imagination... The evolution of CEREC technology has

been progressing and forever changing the lives of people. 29 years ago when CEREC was first introduced into the dental society it was only to carve the basic inlay and onlay restorations. Today with the combinational

use of technology with CEREC Omnicam, the digital imprisoning has recreated dentistry to become simple, accurate, and cost effective. Who would have ever imagined that throughout the years dental techniques would become extremely high tech and evolve from the simple onlay restoration to now the most sophisticated implant restorations being created!

*“The Omnicam Rocks!”*  
– Dr. Tod Ehrlich

Prof. Att, the President of the Prosthodontics Group of the International Association for Dental Research (IADR) and the President of the Arabian Academy of Esthetic Dentistry (ARAED). Will talk about the Current aspect in contemporary implant dentistry. He has many publications focusing on implant therapy and basic science in the most respected journals in these fields. His research work about the discovery of biological aging and rejuvenation of implant surfaces was honored by listing under “Images of the Year” by Biomaterials journal.

CEREC meets SMILE DESIGN

> Page 31

**14- 15 NOVEMBER 2014**  
**JUMEIRAH BEACH HOTEL**  
**DUBAI UAE**

# **6<sup>TH</sup> DENTAL - FACIAL COSMETIC INTERNATIONAL CONFERENCE**

*Joint Meeting with*

## **3<sup>RD</sup> GLOBAL CONFERENCE OF AMERICAN ACADEMY OF IMPLANT DENTISTRY**

**ORGANIZED BY**



**CAPP**



**CO-ORGANIZED**



**MEDIA**

**dt** Dental  
Tribune  
MEA

[www.dental-tribune.me](http://www.dental-tribune.me)

**ADA C-E-R-P®** | Continuing Education  
Recognition Program

Centre for Advanced Professional Practices (CAPP) is an ADA CERP Recognized Provider. ADA CERP is a service of the American Dental Association to assist dental professionals in identifying quality providers of continuing dental education. ADA CERP does not approve or endorse individual courses or instructors, nor does it imply acceptance of credit hours by boards of dentistry.

**CAPP Designates this activity  
for 14 CE Credits**

**Direct Veneers;  
The Shades Dilemma**  
Dr. Eduardo Mahn, Chile

**Face & Smile Analysis No Software  
Solution, Clinical Photography**  
Dr. Eduardo Mahn, Chile

**Indirect Veneers**  
Tutor: Dr. Munir Silwadi

**Periodontal Instrumentation**  
Prof. Mary Rose Pincelli Boglione,  
Italy

**Veneers vs. Crowns The Challenge  
In Smile Design**  
Dr. Eduardo Mahn, Chile

[www.cappmea.com/aesthetic2014](http://www.cappmea.com/aesthetic2014)

# Dental Photography Part II: Protocol for shade taking and communication with the lab



*mCME articles in Dental Tribune have been approved by:  
HAAD as having educational content for 2 CME  
DHA awarded this program for 2 CPD Credit Points  
CAPP designates this activity for 2 CE credits.*

By Dr. Eduardo Mahn, DDS,  
DMD, PhD  
Universidad de los Andes  
Clinica CIPO Santiago-Chile

Part I of this article discussed the basic equipment that is necessary for dental photography. In addition, a few examples of pictures taken that were better than others for the same situation were also shown. In part II, a protocol of taking digital photographs will be presented which has been of great help to the author, specifically in achieving the right shade and value. It is based on standardized pictures that should be taken in order to show certain individual characteristics of the patient to be treated and standardized comparisons of the shade tabs and the natural tooth structures in order to give the technician more information than the usual A2 or A1 written on a piece of paper.

## Introduction - Shade taking

The evolution in digital photography and the possibility of

taking pictures and evaluating them immediately as well as almost instantaneous access of the information by someone located off-site in the same city or even another country, we have a great resource available that can help us achieve the right shade of our indirect restorations. Standardized high quality photographs are also an advantage when the shade is taken for a direct restoration - for example a direct veneer or a class IV.

In this case a picture can really help the clinician identify the opalescent areas and the halo effect of the adjacent tooth, before re-doing the restoration (Figure 1).

Dental shade taking at the dental lab or in the dental practice can be frustrating as most dentists do not really know how to use the shade guide when they finish their undergraduate studies. In particular, if work has to be redone, because the clinician does not know what was done incorrectly wrong or how to obtain the right shade. Dental shade guides are used

by dentists, dental assistants and dental laboratory technicians to communicate proper tooth color, translucency, and brightness.

However, many variables come into play no matter what system you decide to use. Before even starting to think about shade taking; you need to answer an extremely simple and obvious question: are you using exactly the same shade system as the lab? There are many shade taking systems available, with variations in the shades between different manufacturers, even though the concept may be the same. They are also manufactured from different materials with different optical properties. For example, some labs are familiar with the Chromascope system, most of the dentists with the A-D shade guide, while the younger generation of dentists learned with the 3D master shade guide. (Figure 2)

The role of a shade guide is to help standardize the perception and so facilitate the communication in order to match

the shade of the natural teeth with the required restoration.

Shade guides are not a perfect representation of what is actually seen but are close enough to identify a range of tooth colors. Eyes are still the best tool for identifying and communicating the correct dental shade. Tooth color can be referred to as being an A1 or A2, or between a B2 and B3 when describing the respective tooth closest to the one being restored. It is always best to get the patient to the dental lab and have a custom shade taken, if possible, particularly for the more difficult cases. However, in most of the cases this is not possible, due to unwillingness of the patient to spend time going to the lab, or the location of the lab not being in close proximity.

The use of shade guides should be used in conjunction with digital photography. If no direct light is projected to the mouth and the shade tabs, the main light source will be the flash of the camera, which has always the same temperature (between 5500° and 6000° K) and can be used by the dentist in the clinic and the technician in the lab. When pictures are taken under different light conditions, the variations between the same shades can be considerable.

(Figures 3 - 5) A good photo for both the dentist and the lab technician can be emailed so that they are both looking at the tooth color under the same conditions. When the technician compares the color of the restoration with the shade guide, he can take a picture that will create an image to be used as a comparison under the same light conditions as the natural teeth in the image sent by the clinician. (Figure 6)

Due to the flash of the camera, the technician can then whether the restorations look similar to the original shade tab sent by the clinician. (Figure 6, Veneers by CDT Juergen Seger, Liechtenstein)

## Tooth Color Basics

Color has two basic characteristics: Hue and Chroma. Natural tooth color also displays these

same characteristics. Hue can be defined as the actual color such, as yellow or gray. Chroma is the intensity of that color and is sometimes called saturation. Hue and Chroma are typically represented by a shade guide in terms of which color comes closest to the actual tooth being measured. For example, shade guides will have a range of A1 to A4 or B1 to B4, plus C and D shades. (Figure 17c) Value is the brightness of a tooth. It is therefore given a separate classification than color when communicating shade. Teeth also exhibit translucency and can be measured by how much light can pass through different sections of a tooth. Shade taking problems arise because most natural teeth are not an exact match to a shade guide, nor do shade guides adequately express tooth translucency and value. In many cases, when it is decided that a tooth has a certain shade, the Hue and the Chroma are communicated to the lab, but never the value and this is where the problems arise. Very few crowns are accepted if the value is incorrect, while moderate inaccuracies in chroma and hue may go unnoticed. For this reason the shade taking protocol needs to be based on this information being communicated to the lab in the most accurate way possible.

Before the shade is taken conventionally or a picture is taken for the same purpose, several factors need to be controlled:

1. If patient is wearing bright colored clothing, drape him or her with a neutral colored cover.
2. Have patient remove lipstick and other make-up, as well as eyewear.
3. Teeth must have been cleaned.
4. The shade taking should be done at the beginning of the appointment, so that teeth are moist (the patient must lick their teeth constantly to keep them moist) and your eyes fresh.
5. The operatory light should be turned off or pointed in another direction. It must not focus on the patient.

> Page 7

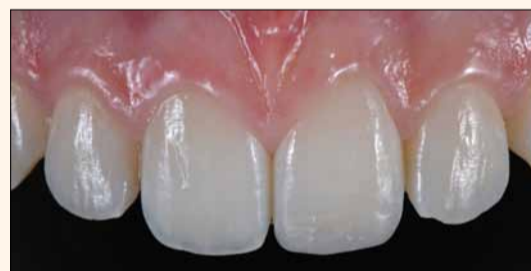

Figure 1: This picture will help the clinician to understand the challenge of reproducing the opalescent areas and the halo effect at the incisal third.

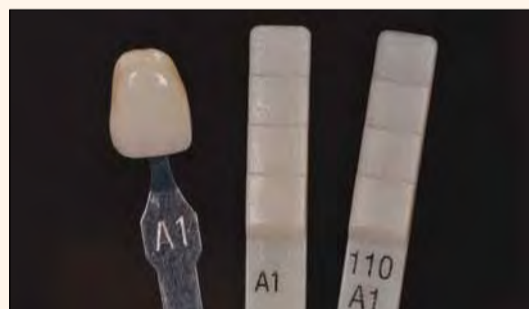
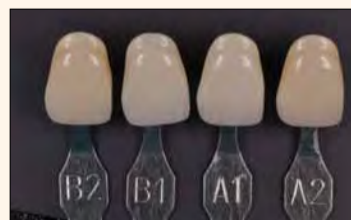
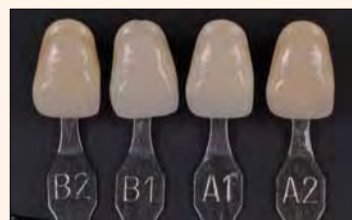
Figure 2: Example of different shade guides showing the same shade. The differences are obvious.



Figures 3 - 5: Different appearance of the shade tabs under different light conditions.

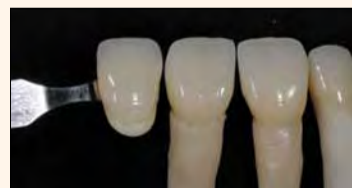
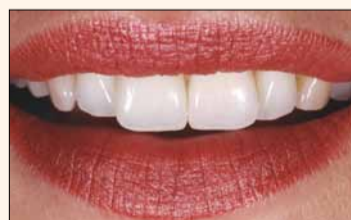
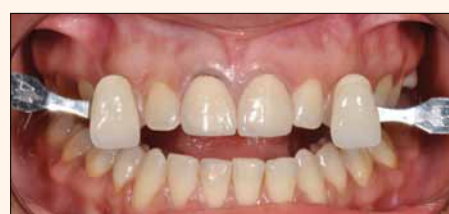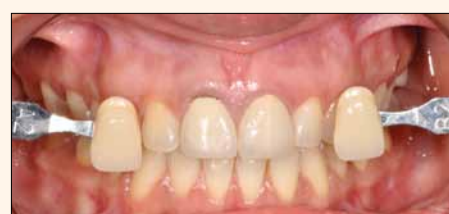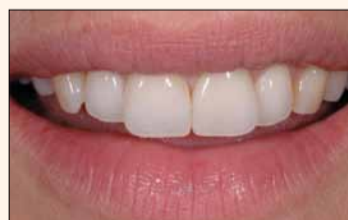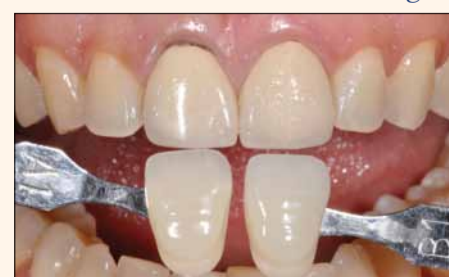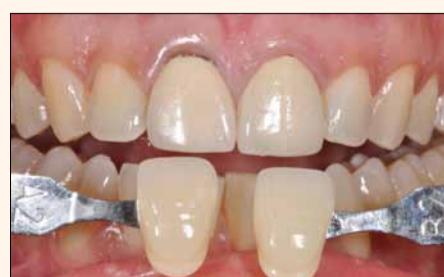Figure 6: The technician should always check the final appearance of the restorations with the use of the natural die material shade guide in order to come to the optimum result.



Figures 7 and 8: Mayor differences in the appearance of the same veneers teeth 11 and 21, due to the use or lack of lipstick. (Thanks for the pictures to CDT Juergen Seger, Liechtenstein)



Figures 9 and 10: Overview pictures with different shade tabs.



Figures 11 and 12: Close-up pictures with different shade tabs.

6. The room light conditions should have a temperature of 5500-6500° K. (when pictures are taken, these parameters are no longer relevant, because the light of the flash will prevail).  
7. Obtain value levels by squinting.  
8. Women are far less likely to be color blind than men, so it is a good idea to have your as-

sistant assist in shade taking decisions (assuming that the assistant is a woman and not color blind)

In Part 1 of this article, the necessary equipment and accessories for adequate intraoral pictures was discussed. Please refer to it for the necessary information if you are planning to purchase adequate equipment.

Once the patient is ready, place the shade tabs in front of the anterior teeth, before starting the treatment itself. The same applies for pictures with lips. It is important to repeat the same protocol intraorally, as well as extraorally, because of the large influence of the reds in shade taking. (Figures 7-8) In addition to the points presented before, the following should be considered initially when photographs are taken: (Figures 9 - 13)

1. Avoid the large reflection areas of the metal parts of the shade guide as they reduce the detail of the pictures
2. Take pictures using two different shade tabs
3. The surface of the shade tab must be at exactly the same level of the buccal surface of the teeth, as even minor discrepancies can make a tooth look darker or brighter due to the power of the flash)
4. The incisal edge of the tabs should be at roughly 1mm dis-

tance from the natural teeth, or as close as possible, without touching each other.

5. Take pictures with and without contrasters. This is especially relevant in young teeth with opalescent areas and clear halo effects.

6. In cases where an all-ceramic restoration is planned, the shade of the stump should also be given to the lab, using a special shade guide, such as the natural die material shade guide of the IPS e.max system (Ivoclar Vivadent, Liechtenstein).

7. Consider taking some pictures in black and white. A black and white photograph will help show the value of the shade tab in relation to the patient's tooth. (Figure 14)

Clinical case

A 27-year-old female patient came to our office unsatisfied with the appearance of her 2 anterior pfm crowns (Figure 15). The value of both crowns clearly did not match the other teeth and her smile line unfortunately also showed the discolored cervical part of tooth 11 (Figure 16).

An overview picture of the stump shade was taken with a reference (Figure 17a). This reference should ideally be the natural die material A - D shade guide (Figure 17d). Both shade guides, the natural die material guide and the A-D shade guide have some similarities, for example, as a rule of thumb an ND2 looks quite similar to an A2 (Figure 17b). Obviously, the natural die material shade guide has shades that are dark, since its purpose is to correlate to artificially discolored stumps and not to recreate natural shades as the A-D shade guide (Figures 17c and 17d). Internal

bleaching of the stump was then performed with 35% hydrogen peroxide (Figure 18) in 2 sessions of 20 minutes each. Figure 19 shows the final result after the composite build-up with Excite DSC and Multicore flow (Ivoclar Vivadent, Liechtenstein). An impression was taken and sent to the lab. The cast was scanned and an IPS e.max Cad LT block was milled (Figure 20). The appearance of the crowns is always checked with the natural die material stumps in order to get the correct value and chroma (Figures 21 and 22). Finally, contacts and final integration of the crowns were checked in the solid cast (Figure 23, laboratory work done by CDT Volker Brosch, Germany). A retraction cord was placed prior to bonding the crowns (Figure 24). The stumps are etched with phosphoric acid (Figure 25) and Excite DSC was applied (Figure 26). Variolink N (base and catalyst, translucent shade) were mixed and applied to the crowns (Figure 27 and 28).

After 4 weeks a natural integration of the crowns with the right hue, value, chroma and effects can be seen in Figure 29.

Acknowledgements

The author would like to thank CDT Juergen Seger and Volker Brosch for their valuable technical work presented in this article.

Editorial note:

References are available from the author.<sup>[1]</sup>

Contact Information

Contact Publisher for author's information if needed.

mCME SELF INSTRUCTION PROGRAM

CAPP together with Dental Tribune provides the opportunity with its mCME- Self Instruction Program a quick and simple way to meet your continuing education needs. mCME offers you the flexibility to work at your own pace through the material from any location at any time. The content is international, drawn from the upper echelon of dental medicine, but also presents a regional outlook in terms of perspective and subject matter.

Membership:

Yearly membership subscription for mCME: 600 AED  
One Time article newspaper subscription: 200 AED per issue.  
After the payment, you will receive your membership number and Allowing you to start the program.

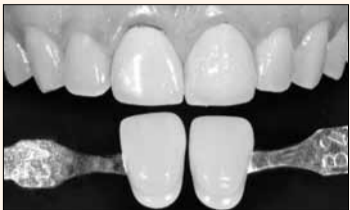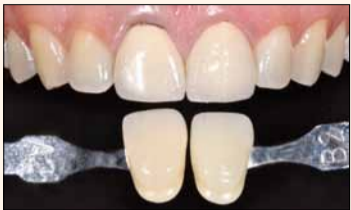Completion of mCME

- mCME participants are required to read the continuing medical education (CME) articles published in each issue.
- Each article offers 2 CME Credit and are followed by a quiz Questionnaire online, which is available on <http://www.cappmea.com/mCME/questionnaires.html>.
- Each quiz has to be returned to [events@cappmea.com](mailto:events@cappmea.com) or faxed to: +97143686883 in three months from the publication date.
- A minimum passing score of 80% must be achieved in order to claim credit.
- No more than two answered questions can be submitted at the same time
- Validity of the article - 3 months
- Validity of the subscription - 1 year
- Collection of Credit hours: You will receive the summary report with Certificate, maximum one month after the expiry date of your membership. For single subscription certificates and summary reports will be sent one month after the publication of the article.

The answers and critiques published herein have been checked carefully and represent authoritative opinions about the questions concerned.

Articles are available on [www.cappmea.com](http://www.cappmea.com) after the publication. For more information please contact [events@cappmea.com](mailto:events@cappmea.com) or +971 4 3616174

FOR INTERACTION WITH THE WRITERS FIND THE CONTACT DETAILS AT THE END OF EACH ARTICLE.



Figures 13 and 14: Colored and black and white picture.

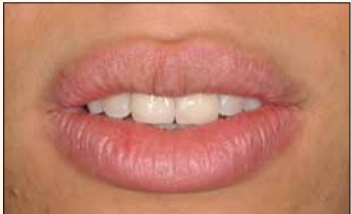

Figure 15: Unhappy patient with unsatisfactory crowns.

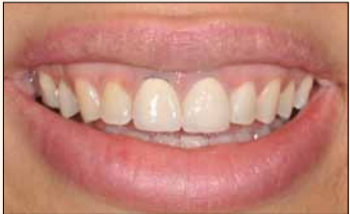
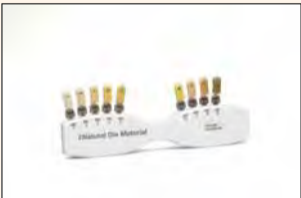
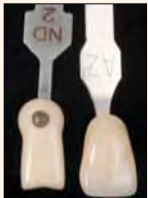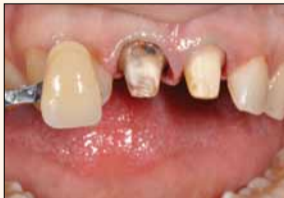Figure 16: The smile is high, situation that makes the metal margin of the PFM crown obvious.



Figures 17a-17d: The stump shade is shown compared with a shade tab. Ideally the natural die material shade guide should be used. As an example A2 looks similar to ND2.

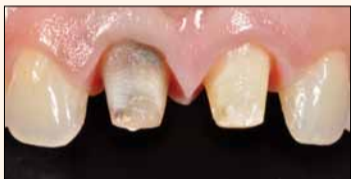

Figure 18: Discolored stump.

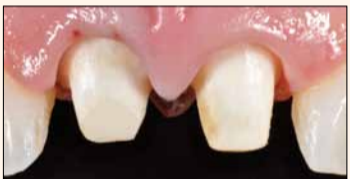

Figure 19: Situation after internal bleaching and composite build up.

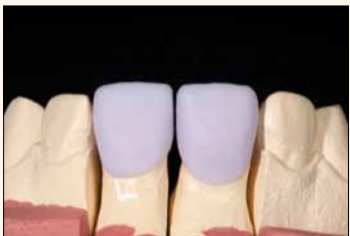

Figure 20: IPS e.max CAD crowns after milling with the MC XL (Sirona) unit. The copings need to be crystallized in order to get the final shade.



Figure 21: Layering steps. The shade is compared with the natural die material stumps.



Figure 22: Final appearance of the crowns placed on top of the natural die material stumps, which has the same shade than the dentin-composite stumps in the patient's mouth.

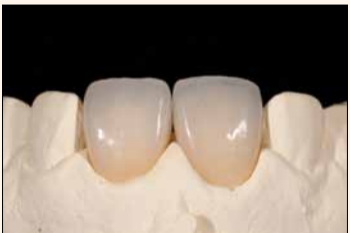

Figure 23: Proximal contact and integration control in the model.

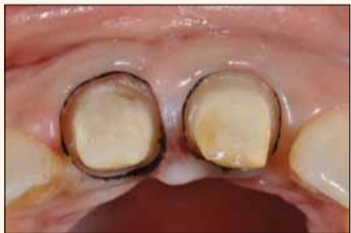

Figure 24: A retraction cord was placed prior etching.

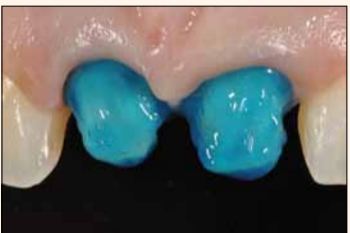


Figure 25: Etching with phosphoric acid.

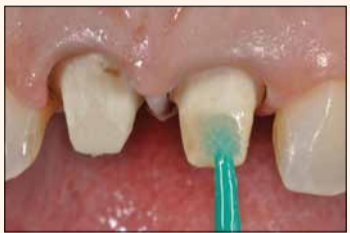

Figure 26: Bonding with Excite DSC.

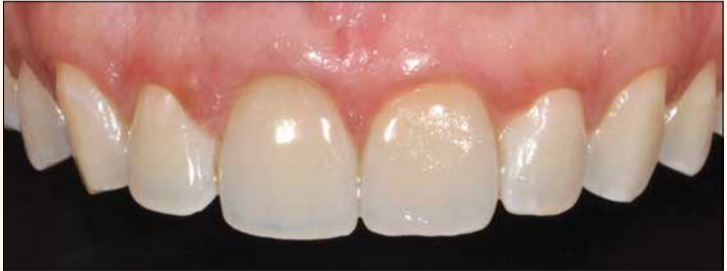
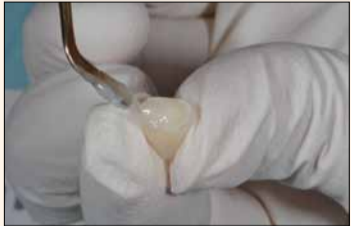
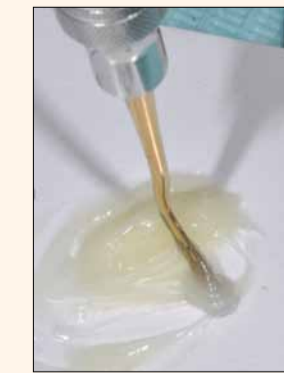Figure 29: Final result after 2 weeks.



Figures 27 and 28: Mixing and application of Variolink N (Ivoclar Vivadent).

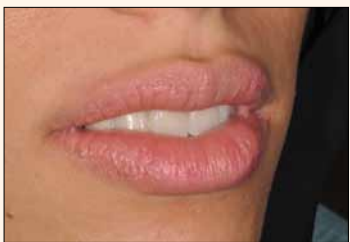

Figure 30: The value of the restorations match the one from the natural teeth.

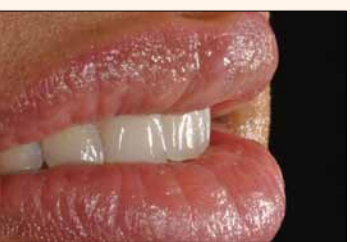

Figure 31: Natural integrated crowns.

# The diode laser as an electrosurgery replacement



*mCME articles in Dental Tribune have been approved by:  
HAAD as having educational content for 2 CME Credit Hours  
DHA awarded this program for 2 CPD Credit Points*

**ADA CERP®** | Continuing Education Recognition Program

Centre for Advanced Professional Practices (CAPP) is an ADA CERP Recognized Provider. ADA CERP is a service of the American Dental Association to assist dental professionals in identifying quality providers of continuing dental education. ADA CERP does not approve or endorse individual courses or instructors, nor does it imply acceptance of credit hours by boards of dentistry.

*CAPP designates this activity for 2 CE credits.*

By Glenn A. van As, BSc, DMD

In 2008, Dr. Gordon Christensen wrote an article in LJADA comparing the soft tissue cutting abilities of diode lasers to those of electrosurgery (radiosurgery) units.<sup>1</sup> In comparing these two technologies against each other, he found that both dental lasers and the less expensive electrosurgery units have advantages and disadvantages, and he summarized with several key points:

1. Although there was considerable overlap in their uses and both technologies were effective, Christensen found that diode lasers were able to be used around metal (amalgam and gold) as well as with dental implants.

2. He stated that lasers did not harm dental hard tissues (bone) or soft tissues (pulp), and that the clinician could use the laser with less anesthetic, and finally he mentioned that lasers were antimicrobial (antibacterial).

3. The acceptance and use of lasers, especially the diode laser, was increasing in dentistry, and that lasers attract patients because of their recognized and accepted role within the field of medicine (LASIK eye surgery).

4. Electrosurgery units were "far less expensive than the least expensive diode lasers" and he questioned whether "the advantages of the diode laser were significant enough to compensate for the additional cost."

There are two basic types of electrosurgical units that can be purchased in dentistry:

- Monopolar, in which a single electrode exists and the current travels from the unit down a single wire to the surgical site. The patient must be grounded with a pad placed behind the patient's

back (a part of the procedure that many patients may question). Heat is produced when the electrode contacts the tissue, and due to pain that is produced, anesthetic must be used.

- Bipolar, in which two electrodes are placed in very close proximity to each other. Bipolar units are more expensive than diode lasers and the electrical current flows from one electrode to the other, thus eliminating the need for a grounding pad. Bipolar units, because of the two wires, create less of a precise cut than the monopolar or diode laser.

Although electrosurgical units are inexpensive, require no safety glasses and can remove large amounts of tissue quickly, diode lasers have become much more common in dental operatories in the four years since Christensen's article was published. The primary reasons for their increased popularity are that diode lasers have a small footprint, are reliable and durable lasers, and are portable. Where a few short years ago, diode lasers could cost in the range of \$10,000 to \$15,000, they are now cost effective and can be purchased for less than \$2,500.

## Advantages of the diode laser over electrosurgery

### Ability to work around metals intraorally

Diode lasers in the range of 810–1,064 nm are well absorbed

in hemoglobin, melanin (pigment) and to some degree water (Fig. 1). These mid infrared dental wavelengths in the absorption spectrum offer the dental clinician the ability to ablate soft tissues precisely while controlling hemostasis, providing the clinician with an excellent view of the surgical site with a reduced reliance on sutures. Diode lasers have features that make them attractive as mentioned earlier, but they also have several advantages in function over electrosurgical units<sup>2</sup> (Table 1).

Perhaps the greatest benefit of these lasers is that they allow the clinician to work safely around metals. The literature has shown that monopolar electrosurge units can accidentally

create catastrophic results when touching metal intraorally. Published reports have shown that contact for very short periods of time with the electrode of a monopolar electrosurgical unit can cause both pulpal and periodontal problems,<sup>3</sup> bone loss,<sup>4</sup> severe intraoral burns,<sup>5</sup> arcing, and that within three seconds of exposure to a dental implant electrosurgical unit can cause failure of osseointegration and loss of an implant.<sup>6,7</sup>

In clinical practice, with today's emphasis on the more esthetically pleasing composite resins and newer porcelains, there are still many metallic materials used intraorally, including cast partial denture frameworks, gold, amalgam, orthodontic brackets and semi-precious alloys.

Diode lasers, unlike their electrosurgical counterparts, show little interaction with metallic objects used intraorally. It is important to remember that due to the laser's ability to reflect off mirrored surfaces and potentially cause eye damage, that all members of the dental team as well as the patient must wear laser safety glasses for eye protection if they are within the nominal ocular hazard zone (NOHZ) during laser operation. This zone is most often between 3 and 7 feet, but some diodes can have extended NOHZ ranges of 40 feet.

Orthodontic patients will often exhibit gingival hyperplasia when in brackets that can make it difficult to work on them. This overgrowth of tissue can be due to poor oral hygiene, space-closing mechanics, excess cement or a combination of factors. The diode laser can be used for gingivectomies to safely remove and recontour the excess tissue and healing can be remarkable in a very short period of time (Figs. 2–4).

## Ability to work around dental implants safely

Various laser wavelengths that are available today can offer the clinician who needs to expose an implant during second stage surgery an alternative to traditional methodologies. The ability of the diode laser to ablate tissue, at times without the need for local anesthetic, while controlling hemostasis, provides the clinician a great view of the surgical site.

In addition, the diode wavelength, like all laser wavelengths, provides for decontamination of the implant site through its antibacterial actions. Bacterial reduction with the diode laser can lead to an almost sterile operative field (98 percent reduction of pathogenic bacteria). Finally, there is

a growing body of evidence that suggests that lasers used at lower energy settings can have a biostimulatory effect on tissue, which in turn can reduce postoperative discomfort, improve healing and shorten healing times while even improving early osseointegration.<sup>8–12</sup>

As an aside, there have been clinicians who routinely use monopolar electrosurgery units to expose implants. It is imperative to realize that although more expensive bipolar (two electrodes) electrosurgery units can be used safely around implants, that the more commonly purchased single electrode (monopolar) units may damage the implant surface and can cause complete loss of osseointegration with resulting implant failure with contact times as short as three seconds.<sup>13,14</sup> Lasers, in contrast, can be used safely with tremendous coagulation and a reduction in pain postoperatively for the patient<sup>15</sup> (Figs. 5,6).

Diode lasers are also useful when it comes time to seat the final abutment and restoration. Tissue management around dental implant restorations can be difficult, be it for the initial cementation or, even worse, if an implant-restored crown comes loose. Tissue quickly slumps onto the abutment, and subgingival margins can be almost impossible to retrieve with traditional methodologies. The laser can truly be a "life-saver" for these situations where soft tissue must be safely and quickly removed to allow for ideal cementation of the implant retained crowns onto the abutments (Figs. 7–12).

## Reduced need for anesthetic

Monopolar electrosurgery units do not have the ability to be used routinely without local anesthetic. In contrast, diode lasers can often be used either with low wattages or in pulsed modes to remove minor to moderate amounts of soft tissue with only topical anesthetics. Although at times this may not seem significant to the clinician, there are many instances where soft tissue acts as a barrier to ideal restorative treatment, and if local anesthetic can be eliminated it becomes a big selling point to patients.

Many patients are looking for alternatives to local anesthetic, and when the occasion allows for the procedure to be completed without the patient being numb, the overwhelming majority of patients are grateful for this. Situations such as laser gingival

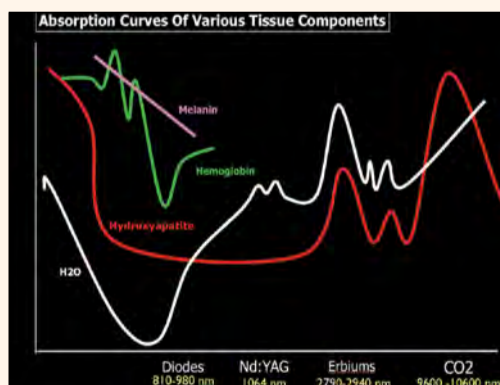


Figure 1: Absorption curve of various tissue components shows diode lasers to be well absorbed in melanin (pigment), hemoglobin and to some degree water. (Images/Provided by Glenn A. van As, BSc, DMD)

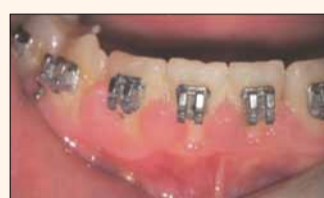

Figure 2: Gingival hyperplasia around orthodontic appliances.

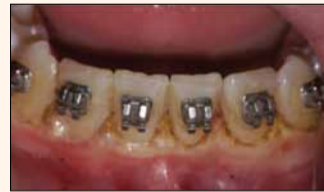

Figure 3: Immediate post-op after diode laser gingivectomy completed.

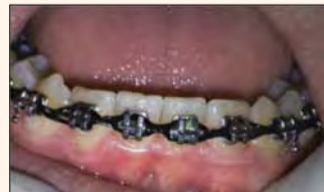

Figure 4: Eight-day healing of soft tissue around brackets.

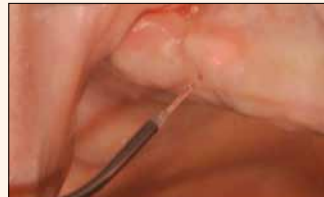

Figure 5: Diode laser for second-stage implant uncover in edentulous maxilla.

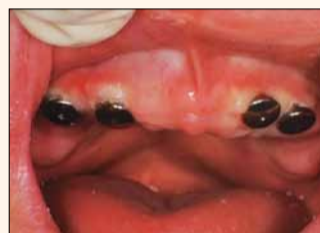

Figure 6: Four healing cuffs in place in maxilla immediately after uncover with the diode laser.

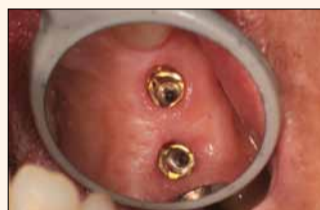

Figure 7: Replace select implant fixtures for upper right premolars.

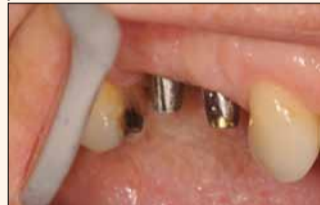

Figure 8: Abutments in place for both teeth.

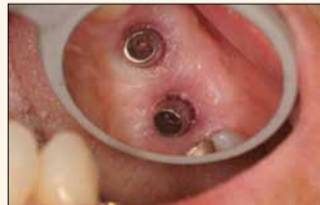

Figure 9: Soft tissue on margins preventing full seating of crowns.

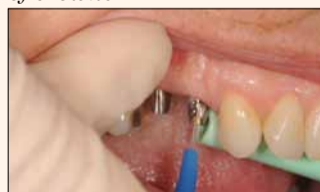

Figure 10: Picasso Lite diode laser removing tissue on abutment margins.

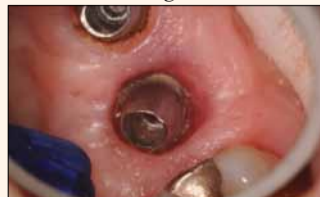

Figure 11: Note tissue off the margins of abutments after diode use.

Diode Laser vs Electrosurgery		
Feature	Electrosurgery	Diode Lasers
Work around Metals	No; causes sparks, pulp death etc.	Yes and safe.
Pacemakers	No cannot be used	Yes can be used
Anesthetic	Local Anesthetic needed	Sometimes topical only
Antibacterial	No antibacterial qualities	Yes kills bacteria.
Lateral Thermal damage	Can cause recession when used.	Less Likely to cause recession.
Uses	Good for large tissue removal.	Multiple uses as seen today.

Table 1: Comparison of diode laser versus monopolar electrosurgery units.

&lt; Page 8

crown troughing for tissue management around endodontically treated teeth, exposure of partially erupted canines for orthodontic brackets and gingivectomies around moderately sized Class V lesions in geriatric patients are all situations where the author has been able to routinely and consistently complete soft tissue ablation with only a stronger topical anesthetic. In fact, the literature has shown that a variety of soft-tissue procedures (even frenectomies) can be completed with only topical anesthetic<sup>16-18</sup> (Figs. 13-16).

#### Ability to do gingivectomies and crown troughing with less recession

White et al. have mentioned that laser gingivectomies are the most common soft-tissue procedure done with diode lasers,<sup>19</sup> and when combined with esthetic porcelain restorations, the simple recontouring of tissue can take a good case and make it great.<sup>20-24</sup>

A key difference from electro-surgery ablation of soft tissue is that alterations to the symmetry of the soft-tissue contours in the maxillary anterior teeth can be safely and precisely completed on the same day as the preparation and impressions of these teeth. The risk of recession and expo-

sure of margins can be far less with a diode laser than with other techniques, particularly when adequate magnification (e.g., 4.0X loupes) and cautious settings (0.6-0.9 w continuous wave) are used for the recontouring.

When biologic width is respected, and adequate attached and keratinized tissue exists, then judicious recontouring of the gingiva on the same day as the preparations can yield stunning results (Figs. 17-19).

The diode laser has become a popular technology as an alternative for tissue management compared to the traditional methodology of placing a single or double retraction cord in the sulcus. The diode laser can be used in almost all instances to produce gingival retraction as an alternative to cord with excellent results both in terms of gingival retraction and margin delineation for the laboratory.

Unlike electro-surgical units where recession can be an issue, as can postoperative pain, diode lasers offer the clinician the ability to precisely remove overhanging, inflamed tissue while creating a gingival trough that is not likely to cause damage to bone, cementum or pulp tissue like electro-surgical units can. In addition, there is research that suggests that the lateral thermal damage done with lasers is significantly lower than that with electro-surgery.<sup>25</sup>

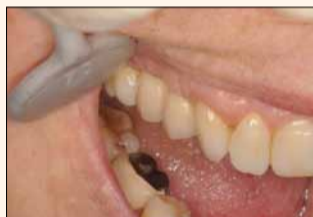

Figure 12: Final crowns cemented onto abutments without soft-tissue impingement.

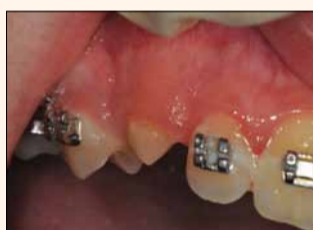

Figure 13: Partially exposed canine requires orthodontic bracket.

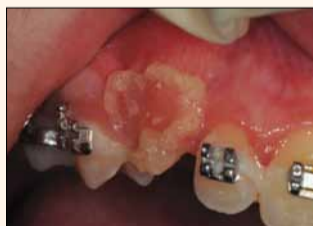

Figure 14: Topical gel placed on soft tissue prior to gingivectomy to uncover soft tissue.

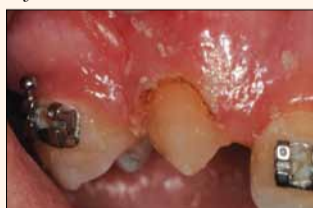

Figure 15: Pulsed mode at 1.4 w shows removal of attached tissue to expose canine.

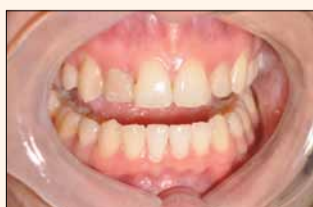

Figure 16: Brackets in place on both canines — immediate post-op view.

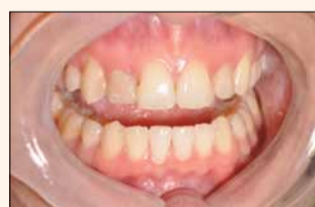

Figure 17: Pre-op prior to maxillary incisor veneers.

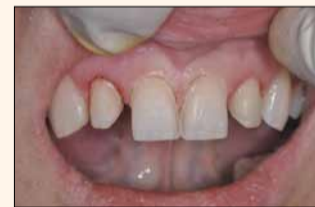

Figure 18: After recontouring of lateral incisors and laser crown troughing for tissue management prior to impressions.

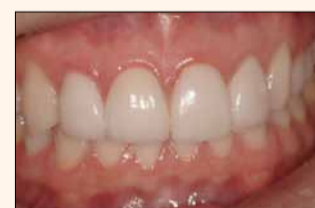

Figure 19: Immediate post-operative result for four Emax veneers.

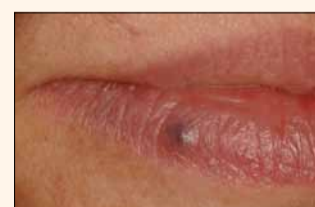

Figure 20: Pre-op view of venous lake on lower lip.

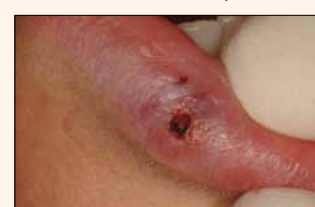

Figure 21: Immediate post-op appearance.

#### Ability to photocoagulate vascular lesions and treat oral lesions

One of the advantages of a diode laser is the ability to treat oral lesions, including: recurrent aphthous ulcers (RAU), venous lake lesions of the lips and herpetic lesions. Research has shown that lasers can be safely used to treat these lesions,<sup>26-28</sup> and in addition it is possible that if caught early during the prodromal stage that herpetic lesions can be aborted or significantly reduced in terms of length of time they are present.<sup>29</sup> In addition, it has been the author's experience that, once treated with the laser, the lesions are often less likely to reappear in the same area. In fact some evidence suggests that herpetic lesions treated in the early stages with the diode laser can cut the healing time in half and create a remission period that is twice as long before it reoccurs.<sup>30,31</sup>

Vascular lesions called venous lakes or hemangiomas can occur on soft tissue areas including the upper and lower lips, buccal mucosa and palate. These lesions can be difficult to treat with traditional methods where significant bleeding may occur. The diode wavelengths are rapidly absorbed by hemoglobin and therefore can be used to coagulate and eradicate these esthetically undesirable purplish lesions often with only topical anesthetic. Literature has shown that the diode can be used in almost 100 percent of cases to eliminate these lesions, most often in only a single session lasting only a couple of minutes<sup>32-35</sup> (Figs. 20-22).

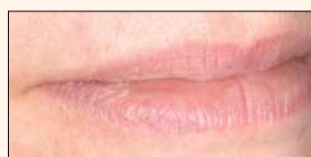

Figure 22: Two-week healing of lesion on lip is complete.

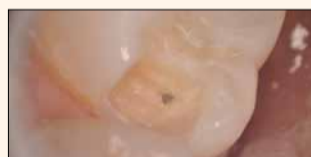

Figure 23: Diode direct pulp cap to lower bacteria count on MO cavity preparation.

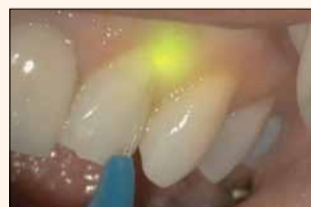

Figure 24: Diode laser in gingival sulcus lowering bacteria count (image of diode pulse captured with video camera on operating microscope — typically the image is not visible to the human eye).

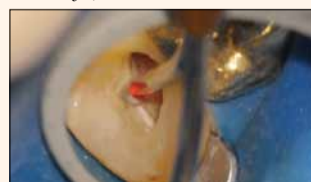

Figure 25: Diode laser used to reduce bacterial counts inside a DB canal of upper right second molar after completion of instrumentation and prior to obturation of the canals.

#### Anti-bacterial capabilities of lasers

Many articles in the literature have demonstrated the tremendous ability of all lasers with respect to the reduction of bacterial and even fungal infections.<sup>36-43</sup> The excellent antibacterial capabilities make lasers effective and desirable in many areas in the oral cavity where the risk of postoperative infection may be reduced. Electro-surgical units do not typically possess the same ability to provide bacterial reduction as lasers do. Particular interest is now occurring with the role of lasers in endodontic, periodontic and peri-implantitis cases where there is need to reduce bacterial loads without such a great reliance on antibiotics.

Although more research is needed on how the bactericidal capabilities of the diode laser might be beneficial in these areas, there is no debating that all lasers can help healing through decreasing the risk of infection through laser light alone (Figs. 23-25). In addition, growing research has demonstrated that the risk of high bacterial loads in periodontal pockets and in particular in endodontic situations may be reduced by lasers.

This latest research has implications for improving traditional methodologies locally where used, and in helping to reduce the potential greater systemic health risks generally. The role of lasers continues to be researched today, but present research has shown that diode lasers can be used safely within root canals with minimal fear of developing iatrogenic complications when conservative settings are used.<sup>44-48</sup>

#### Conclusion

The diode laser has become the "soft-tissue handpiece" in many dental offices. The advantages of being able to work around metals including dental implants, a reduced need for anesthetic, a reduced risk of recession post-operatively, the ability to reduce bacteria, and to use the diode to photocoagulate vascular lesions have all provided dentists with a new alternative for soft-tissue surgery.

Lasers have two added benefits in that they do not require a pad to be placed under the patient for grounding, and they can be used safely with pacemakers. Diode lasers have found their place in dentistry. Once considered an application looking for a purpose, these small, cost-effective and reliable lasers have discovered their niche as the new go to solution for many soft tissue problems in our daily dental practices.

#### References

1. Christensen GJ. Soft-tissue cutting with laser versus electro-surgery. J Am Dent Assoc. 2008 Jul;139(7):981-984.
2. van As G, The Diode Laser as an Electro-surgery Replacement. Dentaltown. June 2010. pgs. 56-64.

Full list of references is available from the publisher. [DOI](#)

#### Contact Information

For more information you can contact Dr. Glenn A. van As on: [glennvanas@me.com](mailto:glennvanas@me.com).

#### mCME SELF INSTRUCTION PROGRAM

CAPP together with Dental Tribune provides the opportunity with its mCME-Self Instruction Program a quick and simple way to meet your continuing education needs. mCME offers you the flexibility to work at your own pace through the material from any location at any time. The content is international, drawn from the upper echelon of dental medicine, but also presents a regional outlook in terms of perspective and subject matter.

#### Membership:

Yearly membership subscription for mCME: 600 AED  
One Time article newspaper subscription: 200 AED per issue.  
After the payment, you will receive your membership number and allowing you to start the program.

#### Completion of mCME

- mCME participants are required to read the continuing medical education (CME) articles published in each issue.
- Each article offers 2 CME Credit and are followed by a quiz Questionnaire online, which is available on <http://www.cappmea.com/mCME/questionnaires.html>.
- Each quiz has to be returned to [events@cappmea.com](mailto:events@cappmea.com) or faxed to: +97143686883 in three months from the publication date.
- A minimum passing score of 80% must be achieved in order to claim credit.
- No more than two answered questions can be submitted at the same time
- Validity of the article - 3 months
- Validity of the subscription - 1 year
- Collection of Credit hours: You will receive the summary report with Certificate, maximum one month after the expiry date of your membership. For single subscription certificates and summary reports will be sent one month after the publication of the article.

The answers and critiques published herein have been checked carefully and represent authoritative opinions about the questions concerned.

Articles are available on [www.cappmea.com](http://www.cappmea.com) after the publication. For more information please contact [events@cappmea.com](mailto:events@cappmea.com) or +971 4 3616174

FOR INTERACTION WITH THE WRITERS FIND THE CONTACT DETAILS AT THE END OF EACH ARTICLE.