

today

25
26
27



South Korea in focus

For the first time in the history of the EAO meeting, clinical experts from a country outside Europe will jointly participate in a special parallel guest country session organised by the EAO in partnership with the Korean Academy of Osseointegration.

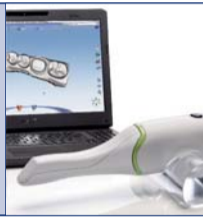»Page 2



Cost–benefit and affordability

Patients' financial situation imposes a significant barrier to treatment choice. Although dental implants have become a mass product, the price does not reflect normal economic trends in price reduction.

»Page 6



New products in focus

The 23rd Annual Scientific Meeting of the European Association of Osseointegration is an excellent opportunity to see state-of-the-art technologies in the field of dental implantology.

»Page 12

Still lots to see and discover at EAO 2014

Annual scientific meeting of the European Association of Osseointegration continues today

■ Reduced diameter or length of implants are just two of the topics, which will be discussed this morning when the annual scientific meeting of the European Association of Osseointegration continues here at the Auditorium Parco Della Musica in Rome. Until Saturday, over 30 speakers from Italy and abroad will

also present on risk factors, soft tissue recession and bone augmentation dilemmas, among other topics. As a first, there will be a special parallel guest country session this afternoon organised by the Korean Academy of Osseointegration in Seoul. It will present an impressive line-up of clinical experts from one

of the largest markets for dental implant rehabilitation in Asia.

Visitors are also invited to attend tomorrow's Award Ceremony which is going to honour submission in basic, surgically related and prosthetically oriented clinical research in implant dentistry.

According to latest estimates of the EAO, approximately 2,500 professionals are expected to attend this year's congress in Rome, which is being held for the 23rd time. While the number of expected visitors is most likely to remain steady compared to the last two editions in Denmark and Ireland, participation at the commercial exhibition has increased with over 90 companies and dental institutions to showcase their latest products and solutions this year. On display are new implants, biomaterials and digital treatment solutions, with some of them to be available to European dentists for the first time. Visitors can also learn more about these products during a number of corporate-sponsored satellite symposia and hands-on workshops to take place during all three congress days. ◀

More information about the meeting, scientific sessions and industry exhibition is available on the EAO

congress website at www.eao-congress.com. The association also offers an application for mobile devices and tablet computers that is aimed at giving visitors quick access to congress-related information. Daily news updates, interviews and product reviews from the show floor are available on the Dental Tribune website at www.dental-tribune.com. The newsfeed can also be accessed by scanning the QR code below.



© pippa west/Shutterstock.com

AD

Restoring happiness


Reliable solutions and partnership for restoring happiness — because it matters.

www.dentsplyimplants.com

USX-1409 © 2014 DENTSPLY. All rights reserved

Far East meets Europe in Rome

Clinicians from South Korea to present clinical innovations in dental implantology at parallel guest country session today



Crowded street in Seoul, the capital of South Korea. The country has now the highest rate of dental implants per capita in the world. (Photo TungCheung/Shutterstock)

AD

Dental Tribune International The World's Largest News and Educational Network in Dentistry

www.dental-tribune.com

dti] Dental
Tribune
International



■ For the first time in the history of the EAO meeting, clinical experts from a country outside Europe will jointly participate in a special parallel guest country session organised by the EAO in partnership with the Korean Academy of Osseointegration. As part of this year's scientific congress programme, clinicians and educators from dental schools in South Korea will present on a wide range of implant-related topics including computer-guided flapless implant surgery or surgical intervention in case of peri-implantitis.

According to Prof. Bu-Kyu Lee, professor of Oral and Maxillofacial Surgery at Asan Medical Center in Seoul and director of International Affairs of the Korean Association of Oral and Maxillofacial Surgeons, the session will not only discuss innovative methods and clinical techniques but also provide a comprehensive insight into the state of dental implantology in the Western Asian country.

"Expectations have been high since the EAO accepted the proposal by our Chairman Dr Je-Uk Park to host a parallel session at the 2014 congress in Rome," he told *today international* in an interview. "I am sure that attendants will enjoy the knowledge that our experts, under the motto 'Cutting edge of implant dentistry', will bring to the table."

Lee said that, while implantology in South Korea was considered inferior compared to Western Standards not long ago, the specialty has taken a big leap forward in recent years.

According to Lee, eight speakers will present during the session today which will also commemorate the recent 10th anniversary of the Korean Academy of Osseointegration. It will commence today right after the meeting of the General Assembly at 13:15.

Dental implants have come a long way in South Korea since they were introduced to the country four decades ago. Back then, US and European products wholly dominated the still young market. Now, with 225 implants per 10,000 people, the country has one of the highest implants per capita rates in the world, ranking after Germany and Israel. According to a report published by the Korean Health Industry Development Institute, the regional market exceeded US\$320 million in 2013. That year, forty South Korean companies manufactured approx. 12 million dental implants. Later, in June, the Korean National Health Insurance Corporation announced that it would expand the coverage of dental implants in patients aged 70 and older beginning in 2015, and those aged 65 and older in 2016; domestic competition is thus expected to increase even further.

The market saturation has recently forced many manufacturers to increasingly pursue sales markets overseas. Owing to their price advantage, implants "Made in Korea" have started to gain more market share overseas. In the Asia Pacific, a recent report by the Millennium Research Group (MRG), a market intelligence provider in Canada, has predicted that manufacturers from South Korea could dominate dental implant markets in that region as early as 2016. By that time, the total regional market is expected to exceed US\$800 million.

While exports to Western countries have remained relatively slow, South Korean manufacturers like OSSTEM already rival established implant providers such as Straumann or Zimmer Dental in Asian countries like Pakistan, Malaysia and Hong Kong. Other significant market players in the region include DIO Implants, a company partly owned by DENTSPLY, as well as MegaGen and Shinhung.

Implants from Korea are also catching up in terms of clinical data, the report stated, a fact that will make them increasingly adoptable for implant specialists in that region. Manufacturers now offer seminars focusing on basic and advanced implant placement training and the advancement of restoration skills to dentists. Having recognised the increasing financial limitations provided by dental implants, a growing number of South Korean dentists has also taken part in seminar programmes that focus on how to remain competitive. This led to an increase in the number of dentists who are able to perform implant surgery procedures. Demand for implants has been also driven by a new trend among South Korean dentists to promote aesthetic treatment through dental implants. ◀



Prof. Bu-Kyo Lee

"Most of what we know about implantology today has its roots in developments that began in Europe decades ago," he said. "Now we have been given the opportunity to give something back by presenting clinical knowledge and methods which have been developed in our country and could benefit implantology worldwide."

"It is a honour to have been invited by the EAO ahead of other important markets such as Japan or the US. We hope that the presentations will be up to par with what attendees expect in terms of content and clinical skills," he said Lee added.



More than solid – Roxolid®.
Reducing invasiveness.



Differentiate your practice by using Roxolid® Implants. Thanks to their outstanding mechanical and biological properties Roxolid® Implants are designed to offer:

- More treatment options with smaller implants
- Preserve bone and reduce invasive grafting procedures
- Increase patient acceptance with less invasive procedures

60 YEARS

 **straumann**
simply doing more

Scientific programme of the 2014 annual scientific congress of the European Association of Osseointegration

Friday, 26 September

08:45–10:15

Oral communication – Basic research

Implantologists of tomorrow – Reduced n. and dimension of implants

- Augmentation prior to implant placement
Fouad Khouri
- Reduced diameter implants
Bilal Al Nawas
- Reduced length implants
Daniel Thoma
- Reduced number of implants
Bjarni Pjetrusson

Extracting teeth in modern dentistry: Change in paradigm?

- What happens after tooth extraction and what do I need to know?
Daniele Botticelli
- Why I do not like to perform Alveolar ridge preservation and why I let it heal spontaneously?
Stefan Fickl
- Why I like to perform Alveolar ridge preservation?
Fabio Vignoletti
- Expert discussion

Oral communication – Clinical research - Surgically related

10:15–10:30

Congress Ceremony

10:45–12:15

Prosthetic alternatives

- All ceramic restorations or low precious alloys
Christophe Hämmerle
- What overdenture type?
Jocelyn Feine
- CAD cam technology where are we?
Joerg Strub
- Complications of FDPs how do we prevent?
Dean Morton

12:15–13:15

General Assembly

13:15–14:45

Oral communication – Prosthodontically oriented (part 1)

Implantologists of tomorrow – When do we need to submerge?

- Influence of hardware and insertion protocol on hard and soft tissue healing
Ryo Jimbo
- Advantages of submerged approach in the aesthetic zone
Jan Cosyn
- Indications and limitations to the non-submerged approach
Robert Haase

Full arch restorations: several options or only one protocol?

- How many implants for a fixed restoration?
Luca Francetti
- Treatment planning for the reconstruction of the Atrophic maxilla
Matteo Chiapasco
- Individualized prosthetic solution for each edentulous patient
German Gallucci
- Rational prosthetic options for the edentulous case
Nitzan Bichacho
- Quality of life aspect
Pernilla Larsson Gran

Oral communication – Basic research

13:15–16:45

Korean Session

Korean Session

Opening remarks

Smart dental implant placement

- Upgrade of Computer Guided Flapless Implant Surgery
B.H. Choi
- Smart implant placement & Computer-guided dentistry
R. Leesungbok

Novel approaches for alveolar bone regeneration

- Tooth-derived bone graft material: Demineralized dentin matrix
Y.K. Kim
- Recent advances in application of rhBMP-2 for bone regeneration
E.W. Jung

Towards natural beauty in implant prosthodontics

- Long term study of alumina touched zirconia abutments in implant restorations
J.S. Han
- Esthetic approaches to various ridges in anterior maxilla
J.S. Lee

Comprehensive management of complications following dental implant

- Innovative solution devices for various implant complications
J.Y. Kim
- Back to basics: Surgical intervention for Periimplantitis
B.D. Ham

Closing remarks

15:00–16:30

Oral communication – Clinical research – Prosthodontically oriented (part 2)

Oral communication – Clinical research – surgically related

15:15–16:45

Evaluation of aesthetics and functional long term results

- Objective evaluation of aesthetic outcome: different methods
Rudolf Furhauser
- Is stable long term aesthetic outcome achievable?
Urs Belser
- Could we reduce biologic long term complications of implant supported restorations?
Anne-Marie Roos Jansaker
- A comparison of smooth and micro-rough titanium surface: are we on the right track?
Maurizio Tonetti

Practice management session

- Economical and demographic situation in European dentistry
Juan Carlos Llodra
- Leadership and productive teams in dentistry
Elisabeth Kalendarian
- The management vision: Total success in dentistry?
Primitivo Roig jorner
- Efficient communication within the team and with the patient for the ideal treatment outcome
Galip Gurel

Saturday, 27 September

08:00–10:45

Risk factors in implant dentistry: how to prevent implant failures

- Implants and systemic diseases: current trends
Carlo Maiorana
- How to prevent surgical complications in oral implantology
Alessandro Rossi

- How to prevent implant aesthetic failures
Matteo Capelli

08:45–10:15

Reducing treatment time: Is it always a must?

- *Tiziano Testori, Paolo Casentini, Dennis Tarnow*

Oral communication – Poster Presentations

Bone augmentation dilemmas

- Prosthetic compensation to avoid augmentation procedures
Eric Van Dooren
- When do we need autogenous bone
Andreas Stavropoulos
- Current indications to resorbable and non resorbable membranes in GBR
Mario Beretta
- Vertical ridge augmentation: limits and indications and long term results
Franck Renouard, Massimo Simion

What do we need for our patient: When do we need implants and what are the health and social implications?

- What else than implants?
Alberto Fonzar
- Cost benefit of tooth replacement
Hugo De Bruyn
- Implants in the elderly population with reduced financial income
Frauke Müller

12:15–15:15

Esthetic and functional rehabilitation of the periodontally compromised tooth/dentition: the contribution of periodontal tissue engineering and biomimetic reconstructions.

- The expanding limits of periodontal regeneration in changing tooth prognosis
Pierpaolo Cortellini

- Modern perio-prosthetic approaches to the complex rehabilitation of the periodontally compromised patient
Paolo Francesco Manicone, Luca Landi

- The role of periodontal plastic surgery in enabling ideal esthetics in the complex restorative case
Francesco Cairo

- Prosthetic reconstruction of the natural dentition and the interdental papilla
Emanuele Risciotti

13:00–13:15

Award Ceremony

13:15–15:15

Soft tissue recessions around implants: Prevention and treatment


- Risk indicators and prevention of mucosal recessions
Hom-Lay Wang
- Surgical treatment of mucosal recessions at implants
Giovanni Zucchelli
- Prosthetic compensation of mucosal recessions at implants
David Schneider
- Management of soft tissue recessions at peri-implantitis sites
Jürgen Becker

15:15–15:20

Closing Ceremony

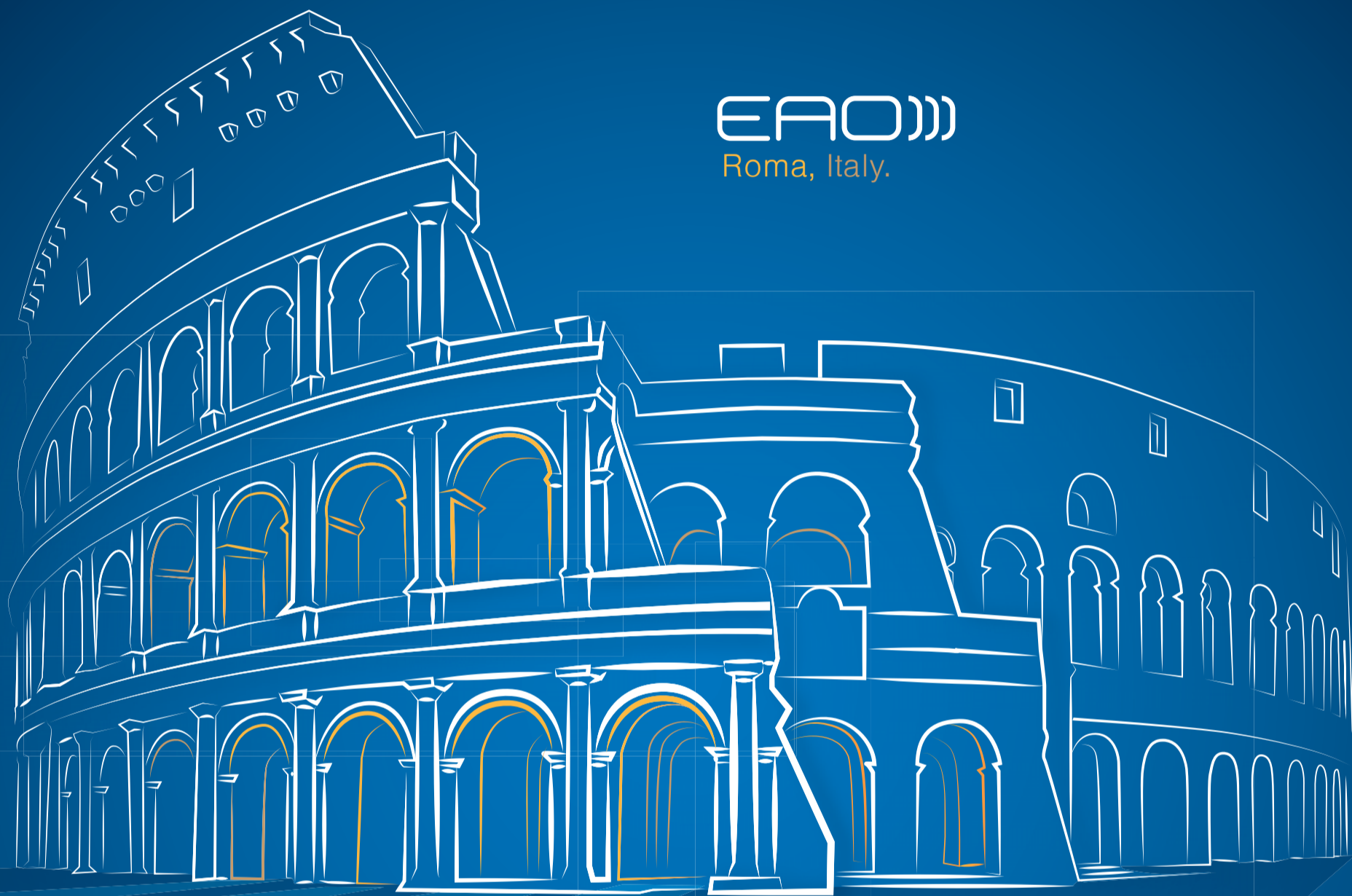Presentation dates and topics are subject to change. Last update was 4 September, 2014.





EAO)))

Roma, Italy.



Discover more about our innovative products, please visit us at:

Booth #G15

PREDICTABILITY & QUALITY! MAKE IT SIMPLE

As Gold Sponsors, MIS is proud to invite you to join us at the EAO Annual Scientific Congress in Rome, Italy, Sept. 25th - 27th. We offer you a unique opportunity to experience first-hand how "Simplicity, Predictability & Quality to Achieve Clinical Results" is built-in to MIS Implant products and procedures. Learn about MIS Implants - visit our site: mis-implants.com

mis[®]



Cost–benefit and affordability of dental implant restorations

By Prof. Hugo de Bruyn, Belgium

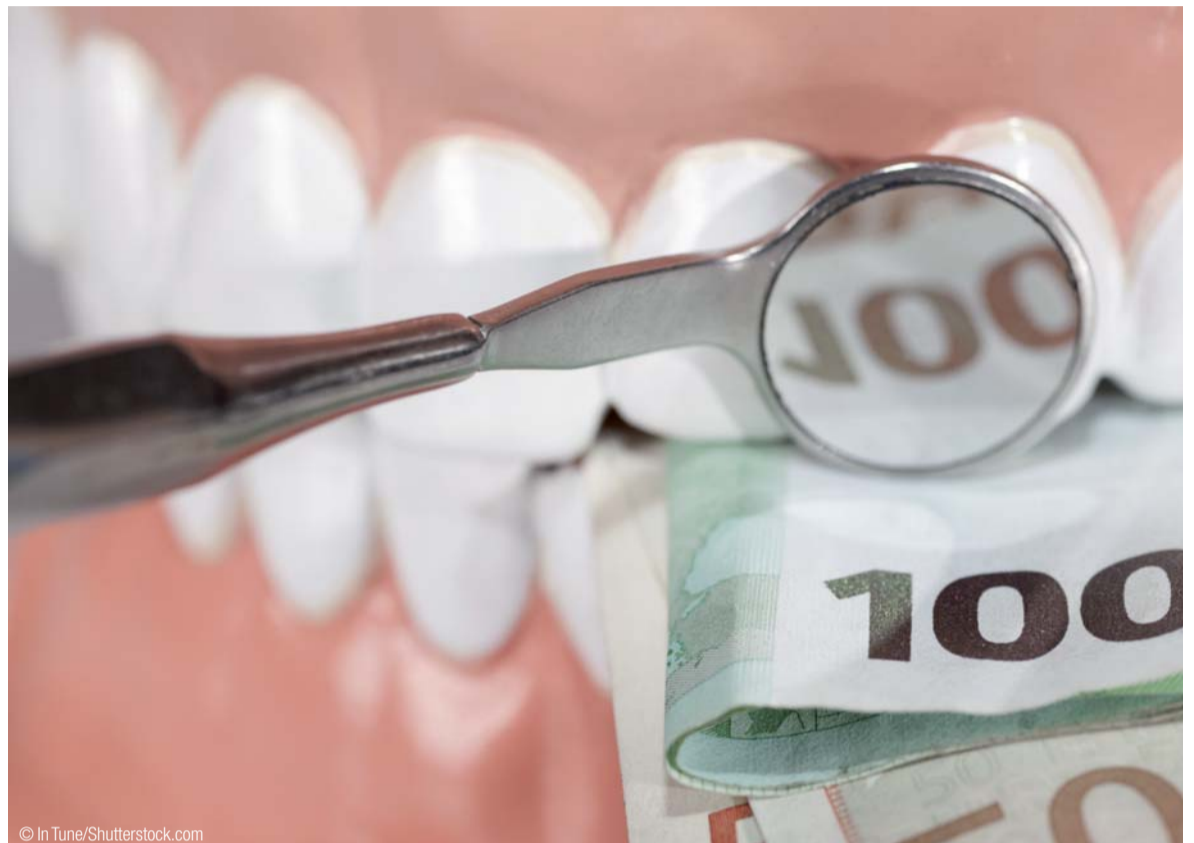■ Nowadays, dental implants are well established in daily practice and are well known and accepted by the public. They allow anchorage of removable and fixed dental prostheses in a predictable way. The efforts of scientists in collaboration with the implant industry have led to continuous improvement in clinical outcomes owing to the modification of implant surfaces, implant design and prosthetic connections. Together with a better understanding of biology, these developments yield fewer implant failures despite the usage of implants in compromised or at-risk patients.

In their consensus reports, the European Association for Osseointegration stressed the need for additional research in the field of patient-centred treatment outcomes, including the economic impact of implant restorative treatments.¹ Patient-centred outcomes consider a number of parameters that are not always objectively measurable, in contrast to implant survival, bone loss, peri-implant health and incidence of complication, for example. Patient-centred outcome variables include patient satisfaction with a given treatment, improved masticatory ability and aesthetics, the absence of speech problems and the subjective evaluation

of oral health-related quality of life.

In light of a growing interest in health economics, greater attention is also being given to the cost–benefit of tooth replacements. In economics, cost–benefit analysis compares the cost of making a product or delivering a service to the direct benefit to the individual or the society, including the revenue the product or service will generate in the long term. Applied to dental or medical care, this analysis would have to consider resource expenditure relative to potential medical benefits, such as longer survival, reduced pain or morbidity, and greater comfort. Such an analysis would seek to determine the best choice considering limited resources, and it would weigh the possibility of undesirable outcomes and side-effects against the potential of a positive treatment outcome.

A cost–benefit analysis would consider these aspects together with the costs involved in terms of chair time, patient-related time, handling complications, and satisfying patients' expectations and preferences. It has become a part of the process of determining necessity in delivery of qualitative care and it brings the patient to the cen-



© In Tune/Shutterstock.com

tre of decision-making. In dental science, these aspects are largely uncovered.

In the context of implant treatment, it is well established that edentulousness and wearing of a complete denture have a number of negative physiological, functional and psychosocial effects. These influence oral function and aesthetics, as well as satisfaction, self-esteem, body image and quality of life.² Consequently, improving the retention of a denture by fixation on two to four implants or the fixation of a fixed complete dental prosthesis on four to six implants has a tremendous effect on oral health-related quality of life. However, adaptation to tooth loss varies individually and many patients cope very well with fewer teeth and do not always desire replacements, let alone dental implants.

In Europe, the demand for tooth replacement is increasingly based upon normative and theoretical grounds and not always on patient-specific assessment. Clinicians are often stuck in dogmatic, non-evidence-based thinking. Often, they impose their personal view concerning the suggested treatment option. Some examples to illustrate this are favouring long implants and bone grafting instead of short implants, believing that the more implants the better, favouring overdentures on connected implants, believing that ceramics are better than acrylic teeth, and regarding aesthetics as being of sole importance.

Long-term clinical studies demonstrate that a single implant is the best option for a missing tooth. It has a greater initial cost, but has a survival rate of above

95% and can be considered more cost-effective than a three-unit conventional bridge.³ Studies have also found that implant-retained overdentures are worth the price given the increase in quality of life and treatment satisfaction. Furthermore, when patients' resources are limited, the two-implant solution is a better option from a cost–benefit perspective than a fixed dental prosthesis on four to six implants.

Unfortunately, patients' financial situation imposes a significant barrier to treatment choice. Although dental implants have become a mass product, the price does not reflect normal economic trends in price reduction. On the contrary, prices rise yearly. The high-tech evolution of 3-D radiographic analysis, the use of stereolithographic guided surgery, the need for individualised aesthetics, and the increased use of additional regenerative procedures have all further increased the total cost. Although these techniques offer the ability to facilitate surgery and enhance aesthetics, the cost aspect is seldom taken into account.

One can question whether this does not lead to exclusive treatments for the happy few. In Europe alone, every year close to one million patients become completely edentulous. It is unlikely that they can afford dental implants. Research in Austria has found that the average person considers implants too expensive and blames the dentist for the high price.⁴ Additionally, 59% of the patients expected a lifetime longevity. A previous study showed that 23% of the patients would not opt for implants at all.⁵ Another study assessing treatment advice given after tooth extraction by Flemish general den-

tists in Ghent demonstrated that replacement was not recommended in 42% of cases. Of the remaining cases, 54% opted for a removable appliance and only one-fifth received advice for a single implant crown. It appeared that highly educated patients were more likely to receive a single implant, probably on grounds of financial affordability. Hence, despite evidence that a single implant is the best, cost-effective way to replace a missing tooth, it is seldom advised. It is obvious that other patients' and clinicians' arguments prevail in the decision-making process.⁶

Given the current economic situation, dental health care expenditure will probably slow down or even be reduced. With budget cuts and savings deemed necessary in the EU for the coming decade, an insecure situation or the perception thereof by many patients will require difficult choices. In many countries, national health or private insurance seldom reimburses patients for implant prostheses, leading to large groups of patients requiring replacements but being without the means to pay for them. The remaining patients can afford dental implants, but have high and often unrealistic expectations regarding the device and are very critical.

It is a challenge for clinicians to deal with these economic factors and offer good treatment to as many patients as is feasible. The clinician should advise the patient which treatment option is preferable based on individual risk assessment, but the patient's preferences, including financial affordability, and the long-term cost–benefit aspects are gaining importance and cannot be neglected. ◀



Prof. Hugo de Bruyn is Chairman of the Department of Periodontology and Oral Implantology at Ghent University Hospital in Belgium. On Saturday, he will be presenting a paper on cost-effectiveness as part of the EAO 2014 scientific programme. A complete list of references is available from the publisher.

CONNECTDENTAL: OPEN DIGITAL SOLUTIONS



Digital Impression and Workflow Solutions:

Henry Schein offers full digital seamless and easy to use workflow solutions for dental practices and dental laboratories under the **ConnectDental Brand** through its specialist teams. These teams of digital systems ConnectDental Specialists provide professional and individually tailored product and service solutions built on an open platform.

Working with Henry Schein gives you following assurances:

- Professional advice through a personalized and workflow oriented approach supported by a team of Henry Schein ConnectDental specialists.
- Complete workflow management between practice and laboratory providing data transfer, interfaces and digital case management solutions.
- Implementation of your bespoke solution: Installation of network solutions, conebeam CBCT scanning, implant and prosthetic offerings, open digital impression scanning, chairside and laboratory side CAD/CAM systems, appropriate consumables and technical services and support.

Physiological healing patterns: What clinicians need to know about tooth extractions

By Dr Daniele Botticelli, Italy



Dr Daniele Botticelli is head of the oral surgery division at the Ariminum Research & Dental Education Center in Rimini in Italy. On Friday morning, he will be presenting a paper on tooth extraction as part of the scientific programme of this year's EAO congress in Rome.

After a tooth has been extracted, a series of processes are set in motion that ultimately results in the healing of the alveolus. As demonstrated in animal^{1,2} and human studies,^{3,4} intra-alveolus healing usually starts with the formation of a coagulum in the alveolus immediately after the tooth has been extracted. This clot is then progressively replaced by a provisional matrix, which functions as a scaffold for the woven bone that will form from the lateral walls and the bottom of the alveolus to fill the extraction socket eventually. Subsequently, the immature bone becomes mature alveolar bone.

In this time, intra-alveolus processes continue. Extra-alveolus healing occurs concomitantly and will result in vertical and horizontal resorption of the walls of the extraction sockets, a process that is more pronounced at the buccal than at the lingual aspects.^{5,6}

A recent systematic review on post-extraction alveolar dimensional changes in hard and soft tissue in humans⁷ reported a horizontal dimensional loss of 29-63% and a vertical dimensional loss of 11-22% six months after tooth extraction. Moreover, it reported that the reduction of alveolar crest dimensions was faster during the first six months of healing and continued after that. In a clinical study, the width of the alveolar crest at the buccal and lingual aspects was measured in edentulous sites and compared with the dentate contralateral sites in 149 cast models.⁵ A reduction of the alveolar crest of about 3.5 to 3.6 mm at the buccal

aspect and 1.7 to 2.0 mm at the lingual aspect was observed. Another study found a total reduction of the width of the alveolar crest of about 30% after 3 months and of 50% after 12 months.⁸

When an implant is placed immediately into an extraction socket, the physiological healing patterns of the alveolus are different from those described above. In order to better understand these processes, it is important to mention two processes that have been proposed as explanations for osseointegration, namely distance and contact osteogenesis.^{9,10} While new bone is formed on the surfaces of the native bone in distance osteogenesis and

the bone will come into contact with the implant surface as a result, new bone forms first on the implant surface in contact osteogenesis.

An experiment was conducted on animals to test these processes¹¹ by preparing cylindrical defects in the alveolar bone and implants (smaller in dimension than that of the defects and with a moderately rough surface) placed and stabilised by devices to guarantee their stability despite the absence of primary contacts with the native bone. After implant placement, gaps of ≥ 0.7 mm were obtained between the implant surface and the bony walls. After three months of healing, very little osseointegration was observed at the defect sites (0.3-5.3%) compared with the control sites (46.1%), in which implants were placed in full contact with the native bone (Fig. 1). Moreover, the defects were found to be filled with newly formed bone, which, however, did not reach the implant surface along its entire length. A space of 0.4-0.5 mm in width between the front of the new bone and the implant surface was observed, occupied by connective tissue that surrounded almost the entire body of the implant. Proper osseointegration may be difficult to achieve when there is no primary contact with the native bone.

In order to study this supposition, a series of experiments on animals were conducted.^{12,13} Recipient implant sites of 10 mm in depth were prepared in the alveolar crest according to the usual protocol. The marginal 5 mm of the sites was subsequently widened with a drill so that a marginal gap of 5 mm in depth and 1.25 mm in width was obtained between the rough surface implant and the bony walls after implant placement. All of the experimental sites were covered with collagen membranes.

The fully submerged and histological outcomes were evaluated after

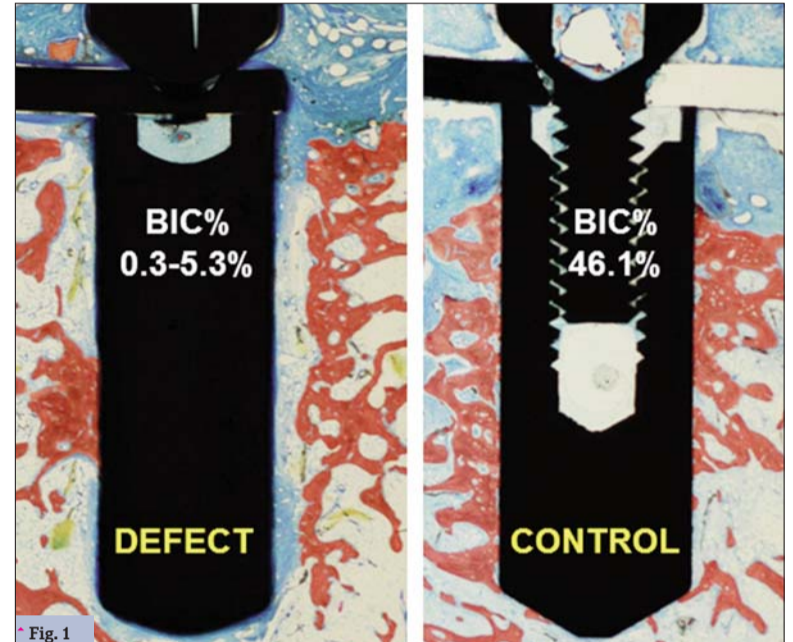


Fig. 1

one, two and four months. It was observed that the defects had filled with newly formed bone after one month (Fig. 2). However, the bone was separated from the implant surface by a 0.4 mm-wide layer of connective tissue, similar to that described in the previously mentioned study.¹¹ Only in the apical 1.8 mm of the defects was new bone integrated on to the implant surface, leaving the coronal 3.2 mm occupied by connective tissue attached to the implant surface.

After two months, 1 mm more was gained coronally, leaving a remaining defect of 1.9 mm. After four months, bone healing was finally complete (Fig. 2).

Similar patterns of healing have been described for implants placed immediately into extraction sockets,^{14,15} demonstrating again that bone formation originated from the lateral bony walls, rapidly filling the defect. Osseointegration on the surface, however, started apically within the defect from the site of contact between the implant and the native bone, and took a longer time to complete (three to four months) compared with the physiological healing of an extraction socket (one month).

Another important factor to be considered is osteoconduction,¹⁰ which can be defined as the process during which bone grows on to a surface.¹⁶ It is a well established that moderately rough surfaces provide higher osteoconductivity and induce a higher degree of osseointegration compared with turned surfaces.¹⁷ While this difference in osteoconductivity may have limited clinical significance,¹⁸ more attention should be paid to marginal defects present at implant placement. In fact, experimental studies have demonstrated incomplete healing of marginal defects with implants with turned surfaces.^{19,20} This may be related to the lower osteoconductive potential and capacity of turned surfaces to maintain this property over time compared with rough surfaces. This may be relevant when implants with a turned surface are placed into extraction sockets or placed at the same surgical stage of sinus floor elevation, for example.

Editorial note: A complete list of references is available from the publisher.

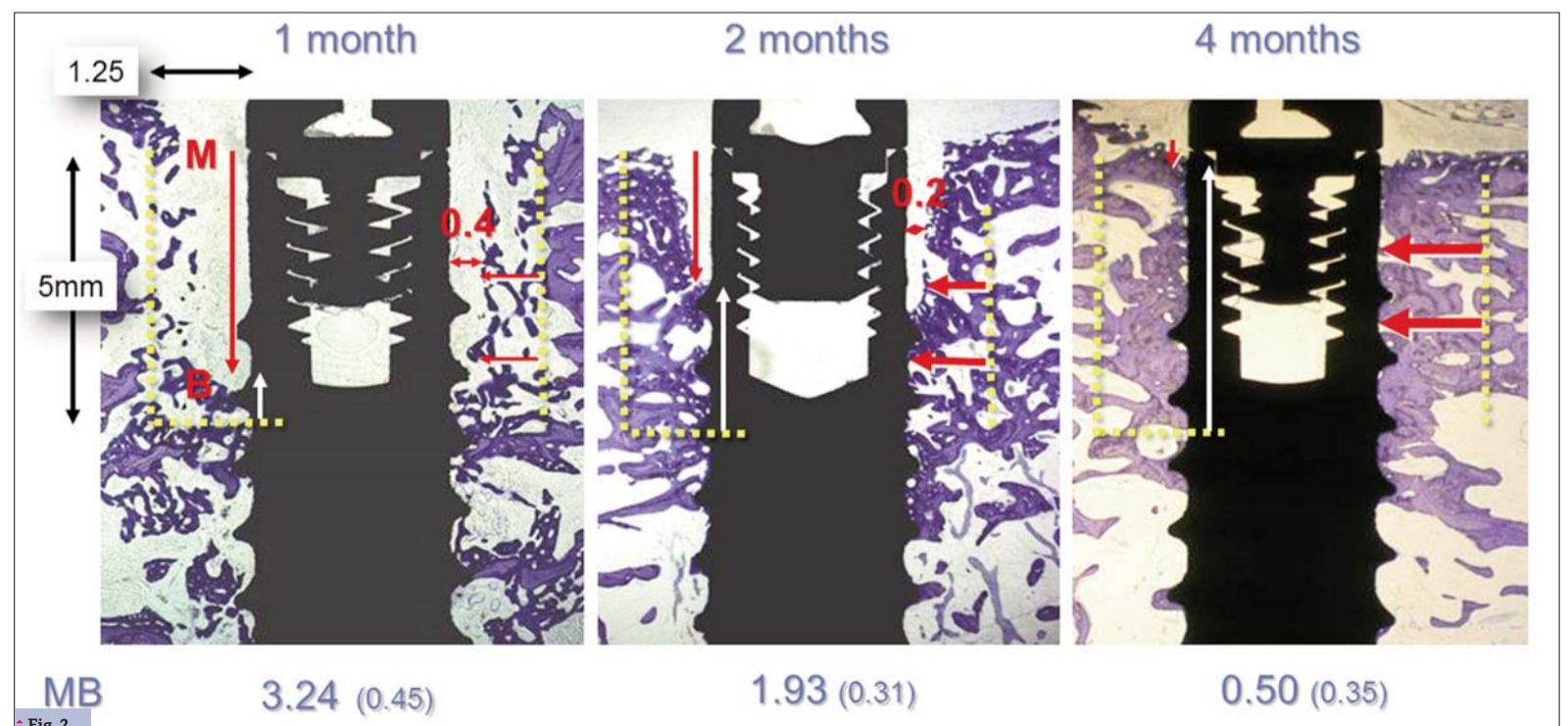


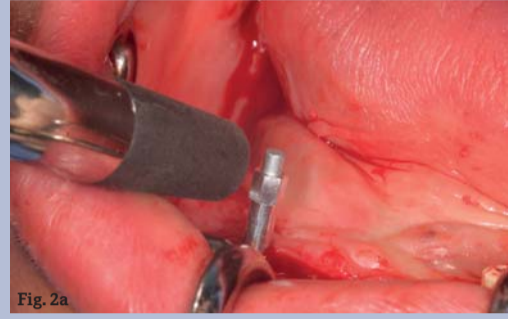

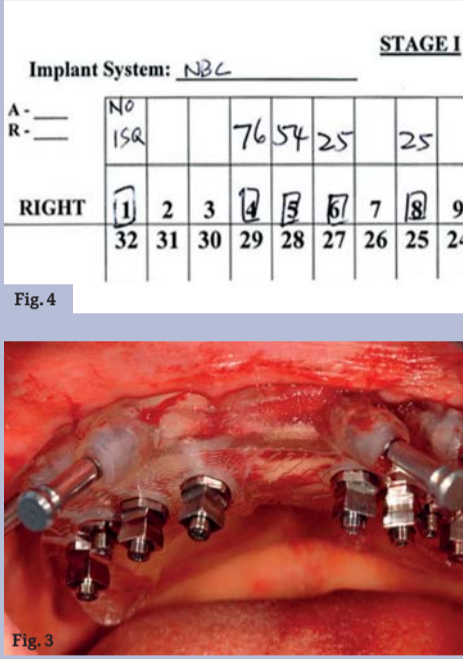
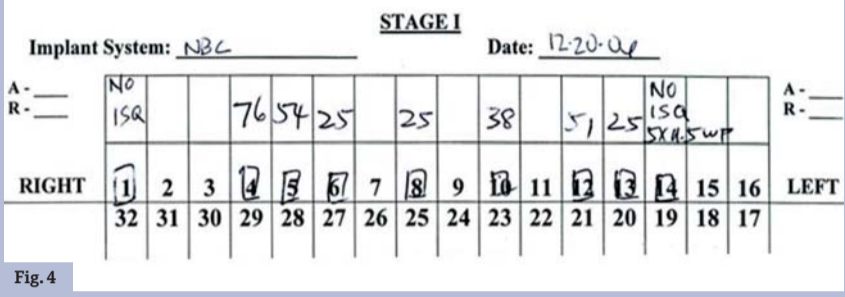


Fig. 2

The implant stability quotient

What it is and how to use it can be used in implant dentistry to improve clinical outcomes

By Prof. Peter K. Moy, USA

A- / R-	No	1	2	3	4	5	6	7	8	9	10	11	12	13	14	15	16	A- / R-
	ISQ				76	54	25		25		38		51	25				
RIGHT		32	31	30	29	28	27	26	25	24	23	22	21	20	19	18	17	LEFT

Fig. 4

• Figs. 1a & b: Smart peg attached to implant and the Osstell unit.
 • Figs 2a & b: ISQ reading of this implant with a value of 84 indicating a very stable implant.
 • Fig. 3: Implants placed using "guided surgical template" and flapless surgery (Nobel Biocare).
 • Fig. 4: Initial ISQ measurements on implants just placed indicating "initial stability". The posterior implants had sufficiently high ISQ values to permit immediate loading protocol. The lower ISQ values with anterior implants will be assisted by the splinting effect and cross arch stabilization with a full fixed prosthesis.

■ The use of dental implants to replace missing teeth has become a routine treatment modality for patients missing teeth. With the acceptance of this form of treatment, patient demands have increased for sooner completion of their treatment and long-term predictability. The clinician must be able to meet the demands from their patients for quicker loading protocols and higher predictability. Unfortunately, with quicker loading protocols, this introduces some uncertainty whether an implant may take prosthetic loading or if it is still undergoing Osseointegration and

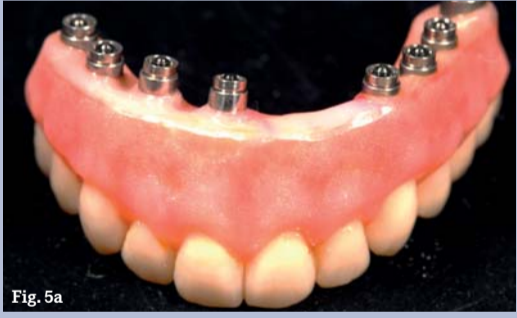


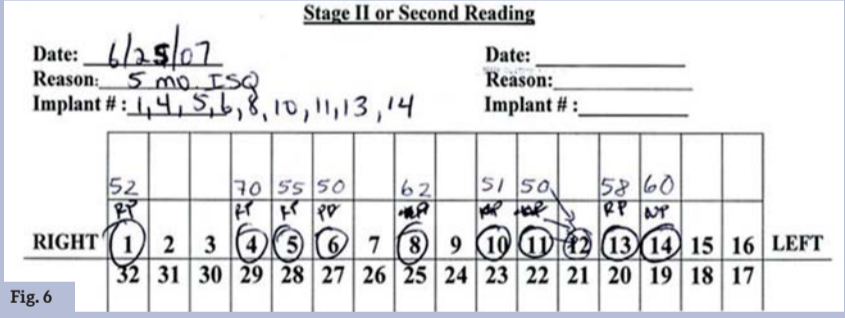
at risk for failure if loading forces are applied to the healing implant.¹ The Osstell Resonance Frequency Analyzer (RFA) unit is a device that measures the resonance frequency of a rod (SmartPeg) connected to the implant. Dependent on the value of the resonance frequency, the Osstell calculates a number (Implant Stability Quotient or ISQ, Fig. 2) indicating how stable the implant is. The higher the number, the more stable the implant. The advancements and improvements made to the Osstell

unit have made it possible for the clinician to determine the primary stability established at the time of implant placement by using the Osstell.² Once the initial stability of an implant (ISQ) is measured this baseline reading can be used to compare additional and successive ISQ measurements enabling the clinician to determine how the biologic process of Osseointegration is progressing.³ This method of assessing implant stability can provide the clinician with information that can be used to determine that the implant is ready to take prosthetic loading and more impor-


tantly, the implant will provide long-term support for a definitive prosthesis. (Figs. 3-8) There are several advantages to comparing successive ISQ measurements to a baseline initial recording. These advantages include permitting the clinician to determine proper healing protocol for an implant that was placed⁴ (delayed, early or immediate loading), determine when the implant⁵, when an implant may be losing integration or the implant failing to integrate. The use of Osstell and obtaining successive ISQ measurements

in implant dentistry is well documented. There are well over six hundred articles published in refereed journals (available at www.osstell.com) that illustrate the science and benefits behind the use of ISQ measurements. This is one data-generating device that an implant dentist must have and use on a daily basis to ensure optimising clinical outcomes of implant treatment for their patients. Editorial note: A complete list of references is available from the publisher.

• Figs. 5a - c: Decision made to immediately deliver a provisional fixed prosthesis based on the initial ISQ readings. The provisional prosthesis was fabricated prior to the guided surgical procedure. Clinical view of the prosthesis immediately after Stage I surgery. The panoramic X-ray showing the provisional prosthesis completely seated onto implants. (Note: The Pterygoid implant was placed to permit support of a distally extended definitive prosthesis but was not used to support the provisional prosthesis.)
 • Fig. 6: A second ISQ measurement taken of all implants at 5 months post insertion indicating all implants are in different phases of osseointegration.
 • Fig. 7: Third ISQ measurements indicating all implants have reached a steady state (note all readings were the same or higher than previous) and the definitive prosthesis should be delivered.
 • Figs. 8a - c: Definitive fixed prosthesis, radiographic confirmation that prosthesis is completely seated and clinical view.

A- / R-	1	2	3	4	5	6	7	8	9	10	11	12	13	14	15	16	A- / R-
	52			70	55	50		62		51	50		58	60			
RIGHT	32	31	30	29	28	27	26	25	24	23	22	21	20	19	18	17	LEFT



A- / R-	1	2	3	4	5	6	7	8	9	10	11	12	13	14	15	16	A- / R-
	60			68	60	53		60		55		53	59	60			
RIGHT	32	31	30	29	28	27	26	25	24	23	22	21	20	19	18	17	LEFT

