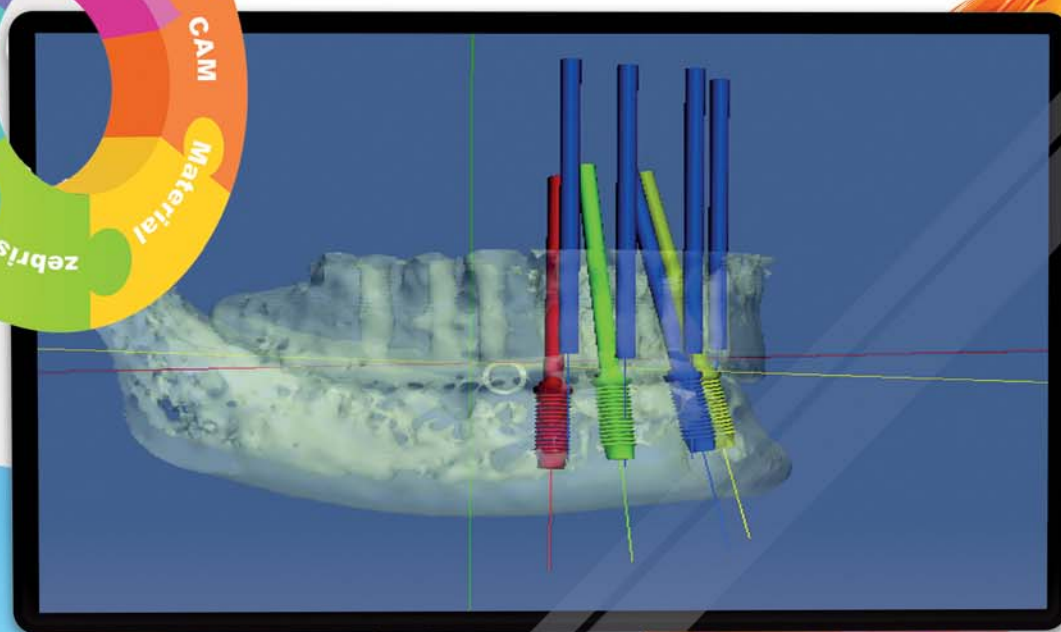
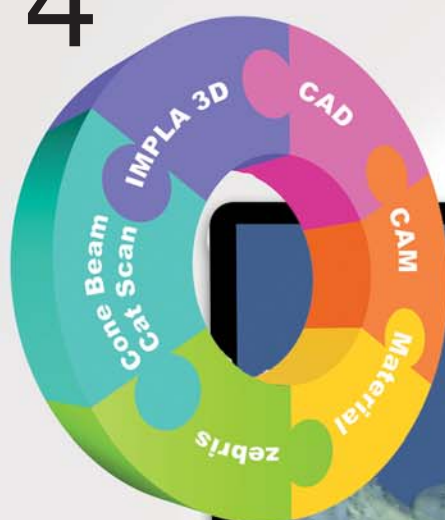


# implants

international magazine of oral implantology

4<sup>2011</sup>



## | clinical study

Flapless implant surgery and its effect on peri-implant soft tissue

## | case study

New concepts in computer-guided implantology

## | meetings

Implantology in Cologne



# More options, same original body.

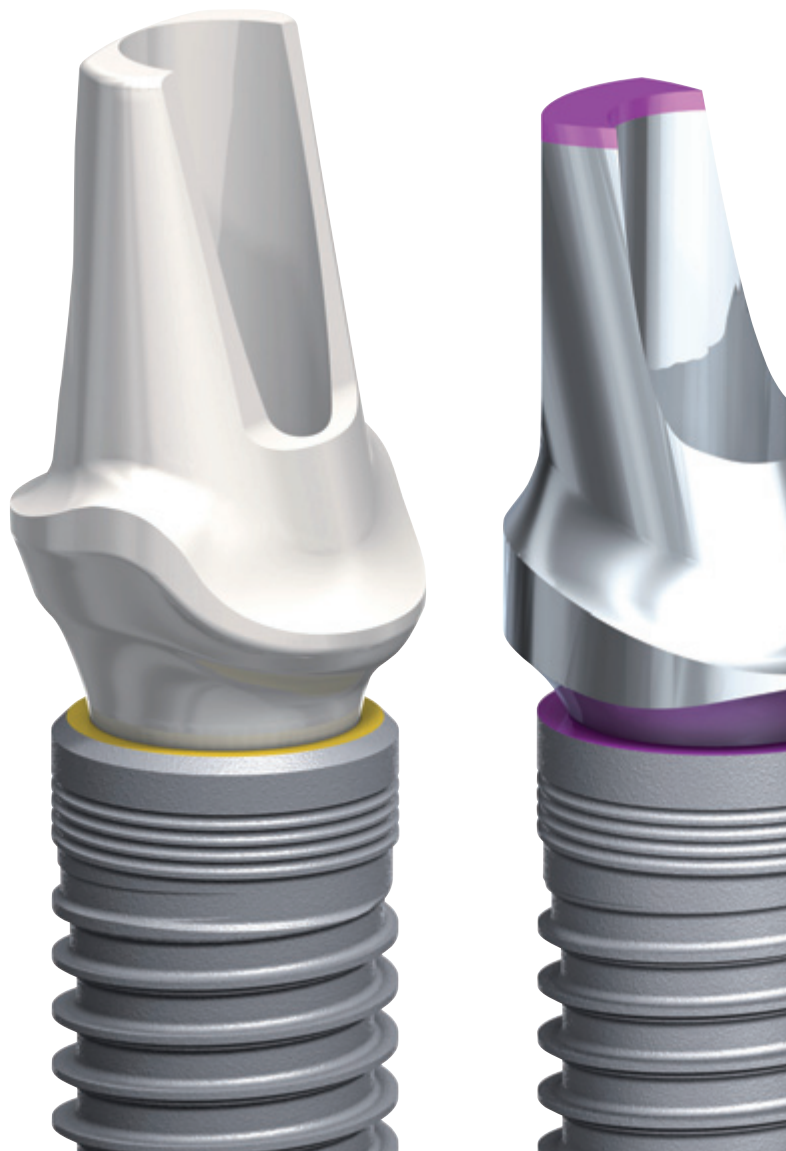
Two new connections  
to choose from.

Designed to maximize  
soft tissue volume.

Established and clinically  
proven tapered implant body.

NEW

With platform  
shift and conical  
connection



**They're called NobelReplace Conical Connection and NobelReplace Platform Shift.** Broaden your restorative options while keeping the benefits of the clinically proven NobelReplace Tapered implant, such as color-coded components and standardized step-by-step drill protocol for ease-of-use and predictable outcomes. Developed for restorations in the esthetic region, NobelReplace Conical

Connection combines platform shifting with a strong sealed connection, whereas NobelReplace Platform Shift offers platform shifting on the internal tri-channel connection with its unrivalled tactile feel. After 45 years as a dental innovator we have the experience to bring you future-proof and reliable technologies for effective patient treatment. **Their smile, your skill, our solutions.**



Visit [nobelbiocare.com/replaceccps](http://nobelbiocare.com/replaceccps)



# What **should** and what **must** be done?



Dr Georg Bach

**Certainly many readers must have chuckled** when they read the main topic of the podium discussion of DGZI's 41<sup>st</sup> International Annual Congress, which has now concluded. Not only did the city of Cologne show its nicest and most hospitable sides, but the congress itself also pleased and satisfied our members, friends, and guests from abroad. The congress' two training days packed with information, its attractive dental exhibition and its thorough and perfect organization (for which we kindly give our thanks to the Oemus Media AG Team) will surely leave lasting and positive impressions on all participants. There was a good deal of enthusiastic debate, controversial discussions, and even a fight or two in Cologne!

The latter of course took place only in the typically friendly and collegial DGZI manner. The podium discussion in particular highlighted many recent different developments in implantology, some of the possibilities relating to those developments and the existing differences in qualification, knowledge and opinions.

Neither DGZI nor the audience have succumbed to the temptation to commit completely and exclusively to one or another philosophy. As is so often the case in life—the happy medium is best choice.

## What should and what must be done?

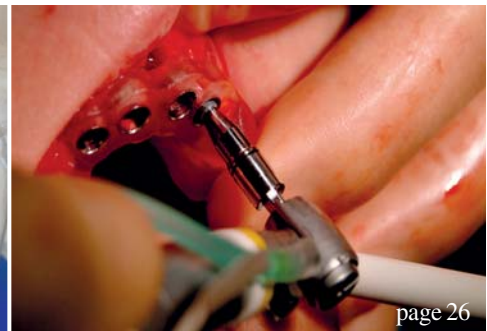
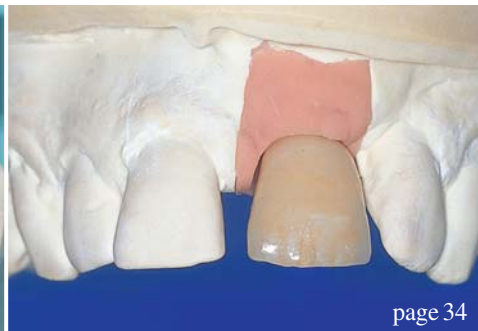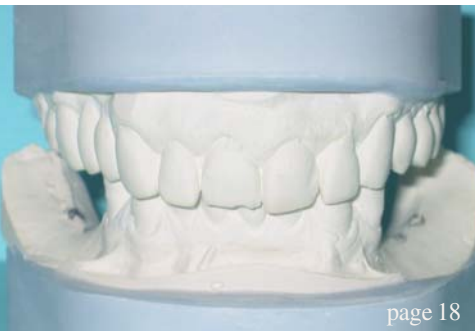In the end, and whatever you decide to do, it will be up to you, dear readers and friends. You have to take your decisions according to your expertise, your experience and your skills!

We hope that our congress was of some (ideally even much) help in your important decision making. We also hope to have reduced the existing inhibition levels with regard to new techniques and possibilities, because one can only take a decision and balance between "digital" and/or "conventional" treatments when looking at the issues neutrally.

At this point, I would like to cite Prof. Dr. Dr. Frank and say that, "Digital implantology is not the future—digital implantology is today!"

With this in mind, I wish you a happy reading of our up-to-date Implantology Journals.

Dr Georg Bach  
Course instructor for DGZI continuing education



## | editorial

- 03 What **should** and what **must** be **done**?  
| Dr Georg Bach

## | clinical study

- 06 **Flapless implant surgery** and its effect  
on **peri-implant soft tissue**  
| Dr Kai Höckl *et al.*
- 18 Consideration of an **uncommon approach**  
in the atrophied posterior zone  
| Dr Maen Aburas *et al.*

## | case study

- 26 **New concepts** in computer-guided implantology  
| Dr Gian Luigi Telara

## | user report

- 34 Second implantation after **implant fracture**  
| Dr Michael Hopp *et al.*
- 38 Use of **tilted implants** in the **treatment** of the edentulous  
posterior maxilla  
| Prof Gregor-Georg Zafiropoulos

## | education

- 40 Fascination of **Laser Dentistry**

## | meetings

- 42 **Implantology** in Cologne  
| Jürgen Isbaner
- 44 **20<sup>th</sup> Annual Congress of the EAO**  
| Daniel Zimmermann
- 49 **International events 2012**

## | news

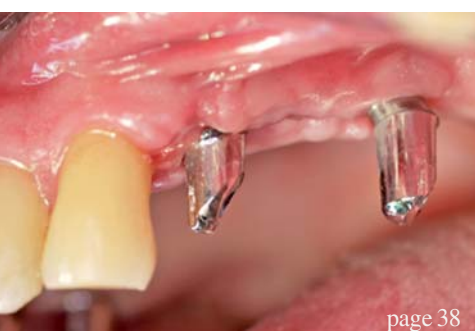- 46 **Manufacturer News**

## | about the publisher

- 50 | imprint

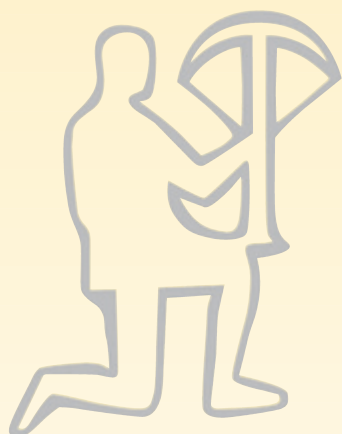


Cover image "Complete Digital Workflow" courtesy of  
Schütz Dental, [www.schuetz-dental.com](http://www.schuetz-dental.com)  
Artwork by Sarah Fuhrmann, Oemus Media AG.





# IMPLA™ Implants - simply safe



## IMPLA™ Dual Surface

- ideal for compact bone
- optimised for gingiva-level insertion




## IMPLA™ Micro Retention

- optimised for soft bone and sinus elevation
- ideal for primary stability




## IMPLA™ Mini Implant

- ball or conical attachment
- minimally invasive
- easy to insert




## IMPLA™ Cylindrical

- no additional thread cutting necessary
- integrated platform switching



## IMPLA™ 3D Navigation



## IMPLA™ surgery box

The all-round box



For more information visit our homepage  
**www.schuetz-dental.com**  
or request our catalog!

# Flapless implant surgery and its effect on peri-implant soft tissue

## A prospective longitudinal clinical study

**Authors**\_Dr Kai Höckl, Prof Peter Stoll, Dr Georg Bach, Prof Wolfgang Bähr & Verena Stoll, Germany

### \_Abstract

#### *Background and aim*

Minimally invasive implant insertion may offer the reduction of peri-implant inflammation, pocket depth and crestal bone loss, as well as minimisation of post-surgical complications. The goal of the present study was to clinically investigate the soft-tissue response and to compare the outcome obtained with flapless, placed implants of three different manufacturers.

#### *Materials and methods*

In this clinical study, 346 implants inserted in 115 patients between January 2001 and February 2009 were examined. A total of 337 two-piece titanium (235 Straumann and 102 Thommen) and nine one-piece zirconium-dioxide implants (Z-Systems) were used. The patient sample included seven smokers, two patients with diabetes mellitus, seven patients

with bleeding disorders and one patient undergoing intravenous bisphosphonate therapy. Regular clinical examination of stability and peri-implant soft-tissue status was performed one, two, three, four and 16 weeks after implant insertion.

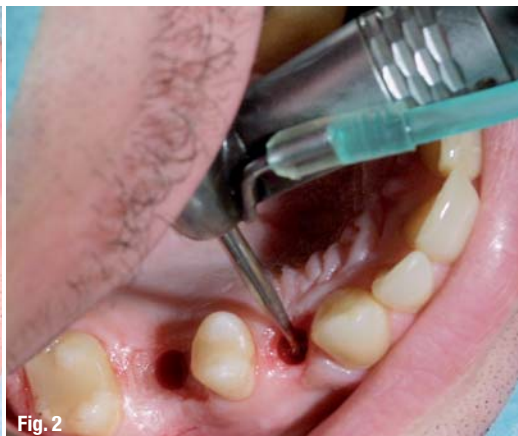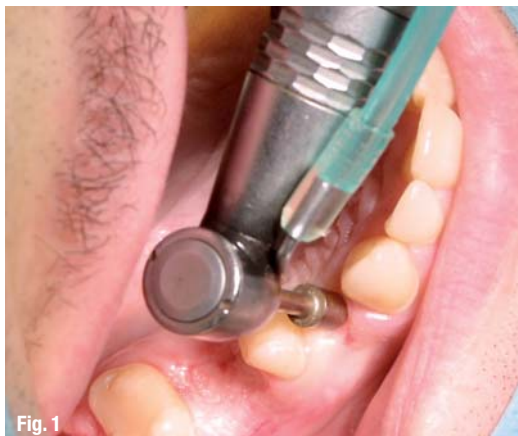All implants were loaded for at least 12 months with either fixed or removable prosthetic restorations. Attachment level, bleeding on probing (BOP), secretion, plaque and keratinised gingiva were documented.

#### *Results*

After loading, one of the 347 implants was lost. The survival rate of the Straumann implants ( $n = 235$ ) was 99.6%, that of the Thommen implants ( $n = 102$ ) was 100% and that of the Z-Systems implants ( $n = 9$ ) was 100%. Thus, the general survival rate was 99.9% after a mean follow-up period of three years and eight months.

**Fig. 1** \_Tissue punch to expose the alveolar crest.

**Fig. 2** \_Start of the drill sequence with the rose drill.



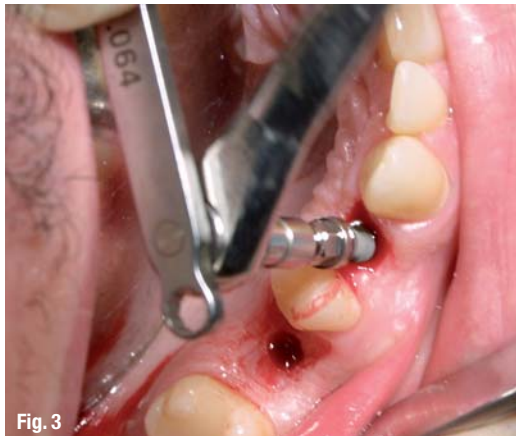
banal  
implants

CHEAPLY IMPLANTS  
BETTER IMPLANTS  
AS IHDE DENTAL

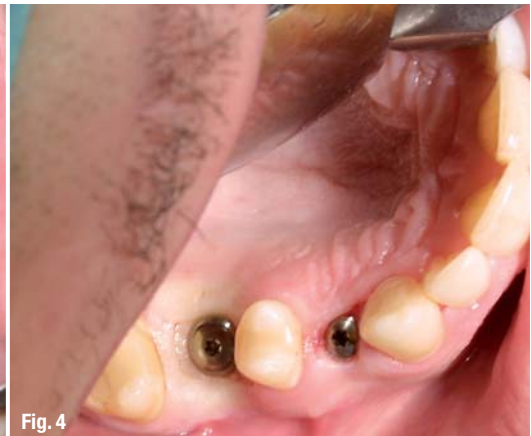

SAY IT TO ALL!

[www.banal-implants.de](http://www.banal-implants.de)



**Fig. 3** \_ Flapless implant insertion.



**Fig. 4** \_ Immediately after implant insertion.

A positive bleeding score (BOP) was found at 106 of the 346 implant sites (30.63%). A significant difference was documented between Straumann implants, where bleeding occurred only in 14.9%, and Thommen implants, where a positive bleeding score was found in 38.2%.

No differences between the three implant types were found in terms of probing depth (PD). The mean PD was 2.4 mm irrespective of the implant design. Bleeding score was significantly higher for those implants without keratinised mucosa. Of the Straumann implants, 161 were surrounded by a band of keratinised tissue, as were 74 Thommen implants. Only 38 Straumann (26.4%) and 22 Thommen (30.6%) implants showed positive BOP. Eight of the nine Z-Systems implants were placed in keratinised mucosa and none of them showed any signs of inflammation.

#### *Conclusions and clinical implications*

The results presented in this article demonstrate that healthy peri-implant soft tissue can be obtained following minimally invasive surgery and transgingivally placed implants. Flapless implant insertion shows a success rate comparable to conventional implant surgery. The results of this study prove that flapless implant surgery is a predictable procedure. In addition, our findings lead to the conclusion that a band of keratinised gingival tissue around implants minimises soft-tissue bleeding.

#### **\_ Introduction**

In conventional implant surgery, more or less extensive flaps are created to expose the surgical field. Since the beginnings of implantology, the technique has been gradually modified and refined to the one- or two-stage procedures most frequently used today. Despite these modifications, the surgical process has remained remarkably constant. After exposure of the jaw bone by preparing a mucoperiosteal flap, the implant is inserted into a cavity cre-

ated by careful bone drilling. Thereafter, the covering soft tissue is sutured to its previous place (Adell *et al.* 1985).

Initial bone loss seems to be caused by interrupted blood supply that follows removal of the periosteum (Ramfjord & Costich 1968; Wood *et al.* 1972; Kleinheinz *et al.* 2005). Flapless procedures utilise only a small soft-tissue punch to expose the alveolar crest (Fig. 1). The size of the surgical field corresponds therefore to the implant diameter.

The term "minimally invasive" or "flapless" implant surgery describes an alternative procedure to conventional incision and flap preparation (Figs. 2–4; Sclar 2007). In addition, this atraumatic approach allows good preservation of the anatomically important gingival and periodontal structures (Al-Ansari & Morris 1998; Zetz & Quereshey 2000; Kan *et al.* 2000). Flapless surgery is becoming increasingly popular and patient acceptance of this procedure is very high. The limited surgical trauma minimises: (a) intra-operative bleeding; (b) surgical time; (c) risk of infection; and (d) post-surgical complaints such as swelling and pain related to the surgical trauma. In many cases, second-stage surgery, i.e. measures to expose the implant shoulder, can be avoided (Stoll 2008). Flapless surgery may help to avoid significant bone loss. The tissue punch used has a diameter similar to that of the inserted implant. Animal studies have demonstrated the importance of the punch diameter. A punch diameter that is minimally smaller than the implant diameter had a positive effect on healing (Lee *et al.* 2009).

It is well known that conventional surgical procedures using titanium screw implants result in very successful long-term survival rates of 94 to 99% (Adell *et al.* 1985; Behneke *et al.* 2000; Cochran *et al.* 2002; Roos-Jansaker *et al.* 2006). This longitudinal study aimed to determine whether flapless, i.e. transgingival, minimally invasive, implant placement can lead to a success rate comparable to con-



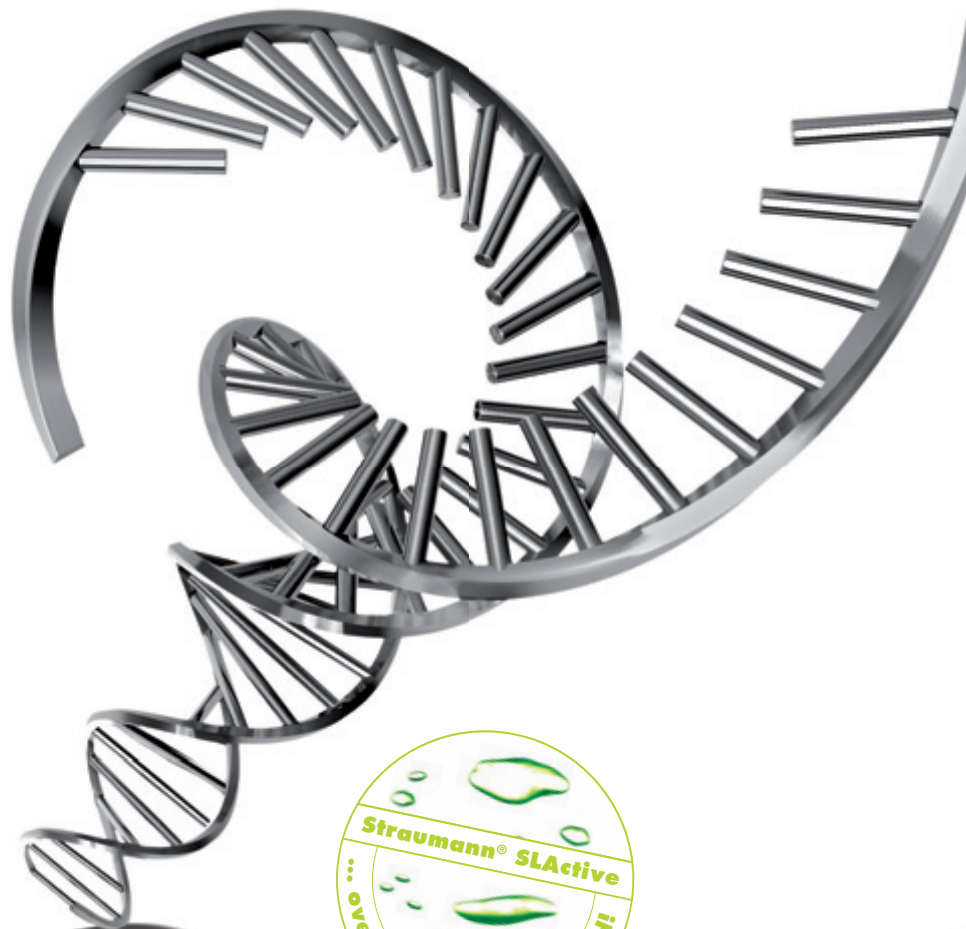


**ROXOLID®**

## THE NEW "DNA" OF IMPLANT MATERIALS

**ROXOLID®** – Exclusively designed to meet the needs of dental implantologists.

Roxolid® offers ■ Confidence when placing small diameter implants ■ Flexibility of having more treatment options ■ Designed to increase patients' acceptance of implant treatment



Please contact us at **+41 (0)61 965 11 11**. More information on **[www.straumann.com](http://www.straumann.com)**

COMMITTED TO  
**SIMPLY DOING MORE**  
FOR DENTAL PROFESSIONALS