

CAD/CAM

international magazine of digital dentistry

3²⁰¹¹



e.max[®] CAD
LT A1 / C14
ivoclar
vivadent

| **case report**

Simple and efficient crown fabrication with an advanced CAD/CAM system

| **clinical technique**

TRIPOD—A new protocol for immediate loading of complete implant-supported prostheses

| **practice management**

Connectivity in the dental world

IPS e.max[®]

**“SUCH A SIMPLE
SYSTEM.
SO MANY
OPTIONS.”**

Christian Coachman, Dentist, Ceramist, Brazil.

Regardless of the indication, IPS e.max offers a suitable all-ceramic solution: from thin veneers to 12-unit bridges – without compromising esthetics.

all ceramic
all you need



www.ivoclarvivadent.com

Ivoclar Vivadent AG

Bendererstr. 2 | FL-9494 Schaan | Principality of Liechtenstein | Tel.: +423 / 235 35 35 | Fax: +423 / 235 33 60

ivoclar
vivadent[®]
passion vision innovation

Dear Reader,

_Dentistry goes is digital! Today, digital dental technology is part of the everyday dental practice just like drills, X-rays and rubber dams. The rapid developments of recent years have resulted in increased precision and enormous time and cost savings for patients, dentists and dental technicians.

But how do YOU keep up with the latest developments? How do you wish to be educated on the latest trends and how do you find out about what educators—dental schools, companies, associations, etc.—are offering?

CAD/CAM offers you the overview! The magazine is committed to accompanying the current developments by informing its readers about the latest treatment concepts and technologies and how these can be integrated into today's practice for the benefit of everyone involved—the patients and the dental professionals.

CAD/CAM strives to serve as a platform for information exchange. To further support and promote this, we have created a new rubric—**digital platforms**—that will be introduced in the first issue of 2012. Here, dental schools, companies, associations, societies and continuing education providers are invited to announce their course schedules. We will also include course schedules on our website www.dental-tribune.com and link to the online course registration forms via QR codes in the magazine.

I would like to encourage everyone—dentists, dental technicians and industry—to participate in this exchange.

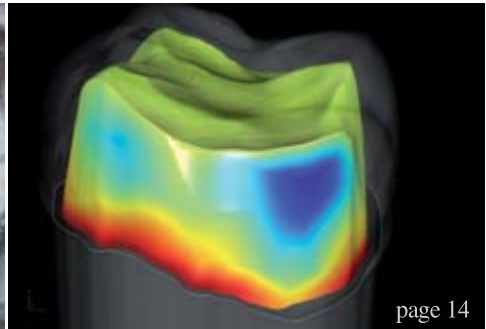
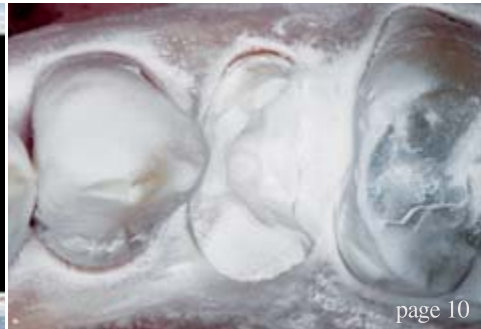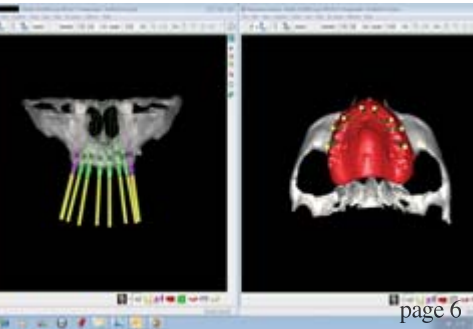
Yours sincerely,



Vera Baptist
Product Manager



Vera Baptist



| editorial

03 **Dear Reader**
| Vera Baptist, Product Manager

| case report

06 **Immediate restoration** in the fully edentulous maxilla region
| Dr Max J. Cohen

10 **Simple and efficient** crown fabrication with an advanced CAD/CAM system
| Dr Brian Buehler

| news

14 Researchers develop **software to improve attachment for dental crowns**

| clinical technique

16 **TRIPOD**—A new protocol for immediate loading of complete implant-supported prostheses
| Dr Jean-Nicolas Hasson *et al.*

| practice management

22 **Connectivity in the dental world**
| Shane Hebel

26 **The passive income** practice
| Dr Phillip Palmer

| special

28 **If you are smart enough to be a dentist, you are smart enough to be interesting**
| Dr Paul Homoly

| feature

34 **The Nordic masters** of dentistry
| Daniel Zimmermann

| industry news

36 **CAMLOG Congress** to be hosted in Lucerne
| CAMLOG


38 **Innovation Days** at Sirona
| Sirona

| meetings

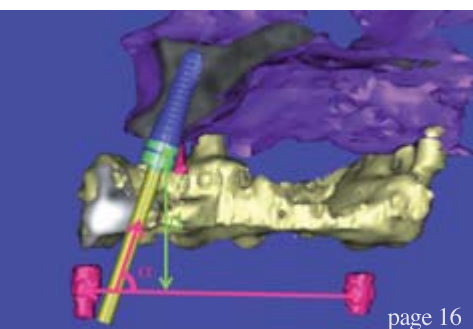
40 **International Events**

| about the publisher

41 | submission guidelines
42 | imprint



Cover image courtesy of Ivoclar Vivadent.





CEREC. Made to inspire.

NEW

CEREC SW 4.0



For many years CEREC has been inspiring users worldwide. Often dentists, who were initially skeptical about CAD/CAM technology, become its most enthusiastic practitioners. And not only users are inspired. State-of-the-art treatment during a single appointment is a totally new experience for patients. Word of this spreads fast and it soon becomes the flagship of the dental practice. For dentists the defining feature of CEREC has always been greater job satisfaction. Now this has been further enhanced with the entirely new intuitive software 4.0. Discover for yourself the unique - and inspirational - potential CEREC offers. **Enjoy every day. With Sirona.**

www.sirona.com/cerec-inspired

Immediate restoration in the fully edentulous maxilla region

Author_ Dr Max J. Cohen, USA

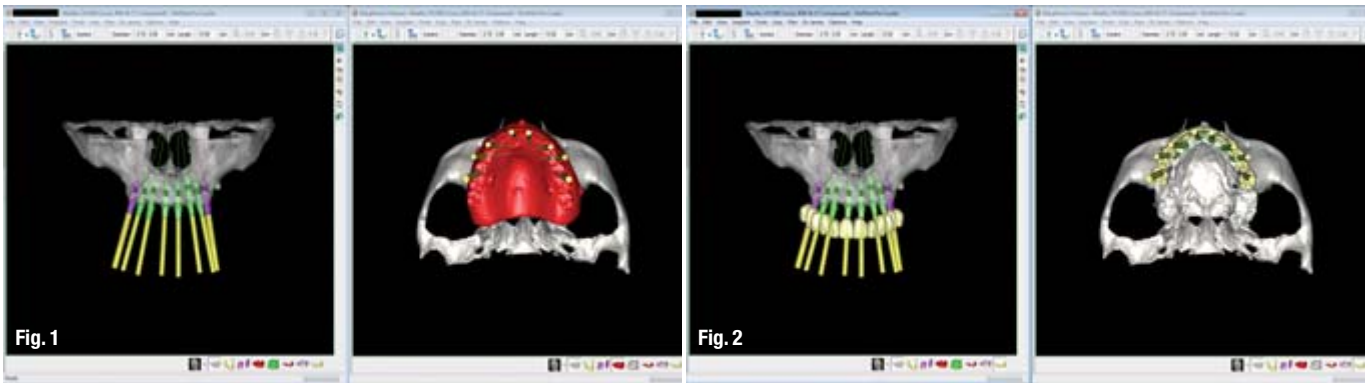


Fig. 1_ Pre-op SimPlant planning showing the scan prosthesis.

Fig. 2_ Pre-op SimPlant planning showing Virtual Teeth.

Fig. 3_ Immediate Smile model with analogues inserted.

Fig. 4_ Immediate Smile denture used to mount case.

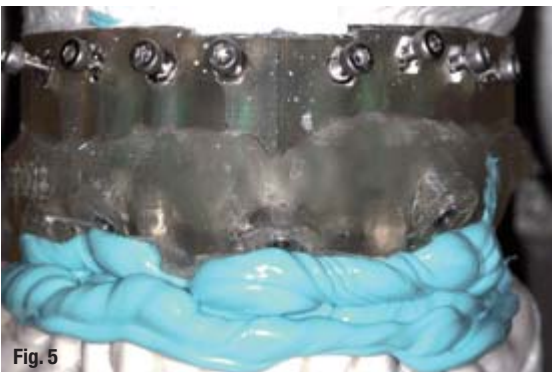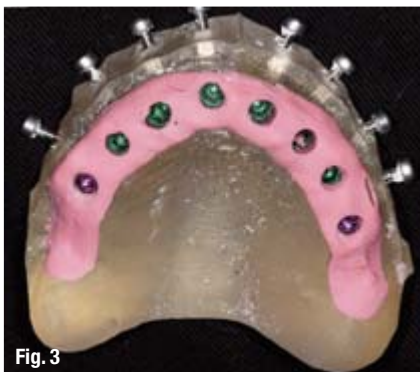Fig. 5_ SurgiGuide orientation and registration on articulator.

_This clinical case required optimal implant placement based upon a restoratively driven treatment plan and guided surgery. To achieve this goal, we made use of CT scans, SimPlant (Materialise Dental) planning software, the new Zimmer Guided Surgery Instrumentation and the new Immediate Smile model (Materialise Dental). The patient was a 49-year-old female in good health, completely edentulous in the maxilla and wore a complete upper denture. On the lower, she wore an implant-retained over-denture.

The planning phase for the case began with a CT scan utilising the i-Cat and the Dual Scan protocol

(Materialise Dental). The patient's existing denture was transformed into a scan prosthesis by gluing eight Dual Scan Markers onto the surface. A radiolucent bite index was made to secure the prosthesis in the correct position.

The patient was first scanned in the i-Cat 17-19 while wearing the scan prosthesis and the bite index. In a second scan, the scan prosthesis was scanned alone. The resulting CT data was loaded into SimPlant, and the scan prosthesis was superimposed upon the study using the SimPlant Dual Scan wizard (Figs. 1a & b).



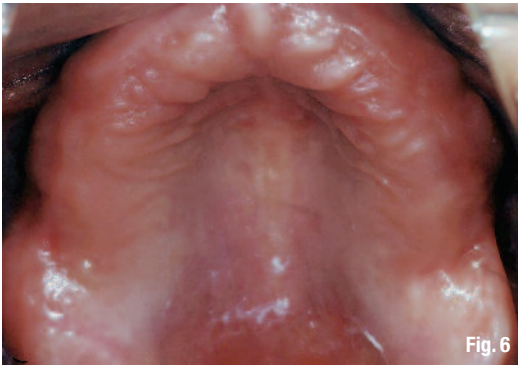

Fig. 6

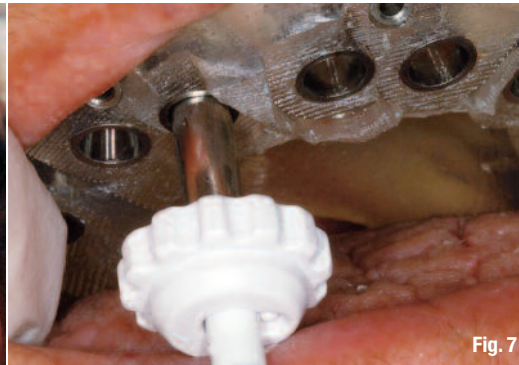


Fig. 7

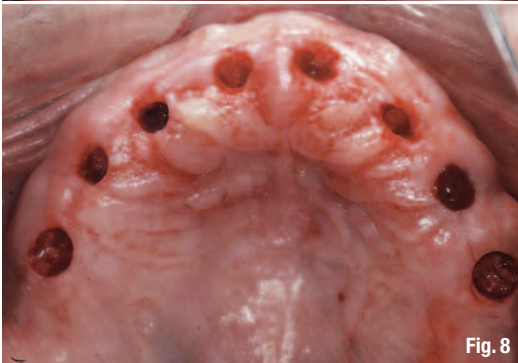


Fig. 8

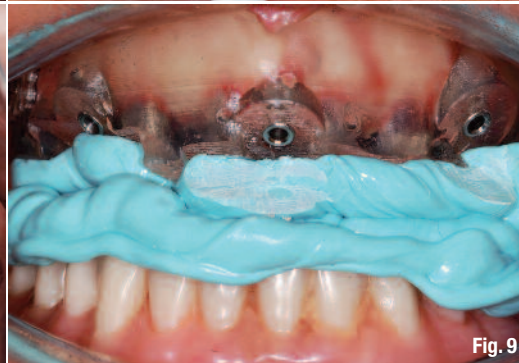

Fig. 9

Fig. 6_Pre-op occlusal view of the maxilla.

Fig. 7_Tissue punch.

Fig. 8_View of the punched maxilla after tissue removal.

Fig. 9_SurgiGuide orientation in the patient's mouth.

Using SimPlant, the optimum implant positions were determined, based upon available bone, a minimum of 3 mm between implants, and the design of the final restoration (Figs. 2a & b). The resulting treatment plan was submitted to Materialise Dental for fabrication of a SurgiGuide and an Immediate Smile model.

I received the Immediate Smile model, which contained a duplicate of the scan prosthesis, a bone model with a silicone soft tissue, and a mucosa-supported SurgiGuide. The bone model came with eight openings corresponding to each of the eight implant positions as designed in the SimPlant plan and corresponding exactly in size to the dimensions of Zimmer analogues.

The bone model came with a screw fixation system, which allowed me to recover the analogues. The silicone soft tissue on the model also corresponded to realistic soft tissue. I also received writ-

ten drilling instructions and a prolongation report detailing the depth and size of each osteotomy.

Zimmer analogues were placed in the Immediate Smile model (Fig. 3). The duplicate of the scan prosthesis was used to mount the bone model with the soft tissue on an articulator (Fig. 4), giving correct orientation and vertical dimension. This made it possible to fabricate a provisional that would be used for immediate loading following implant placement.

The mounted model was then used to create an orientation jig for the SurgiGuide (Fig. 5). The jig assured that the SurgiGuide was positioned in the mouth exactly the same way as the scan prosthesis had been positioned in the mouth. This is a very important step for a mucosa-supported SurgiGuide because of the flexibility of the soft tissue (mucosa). Both the duplicate of the prosthesis and SurgiGuide fit perfectly onto the Immediate Smile model, al-

Figs. 10 & 11_Creating guided osteotomies.

Fig. 12_Occlusal view of the implants and abutments. Note the healing heads on the two implants with sinus lifts.

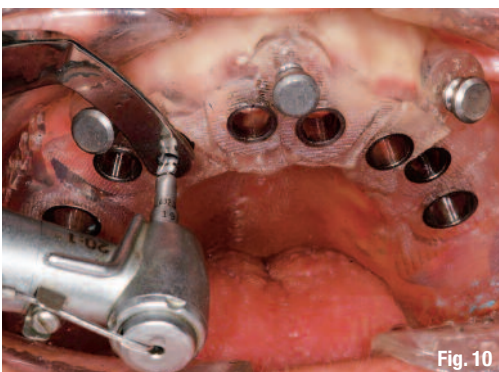

Fig. 10




Fig. 11

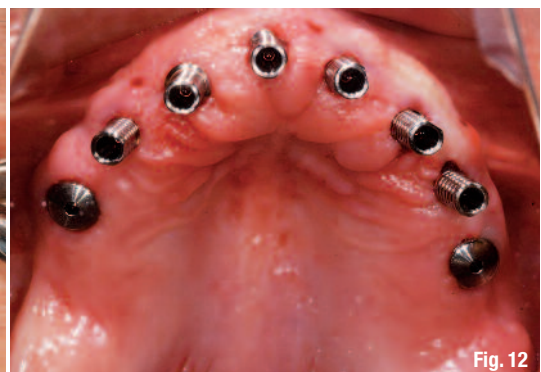

Fig. 12

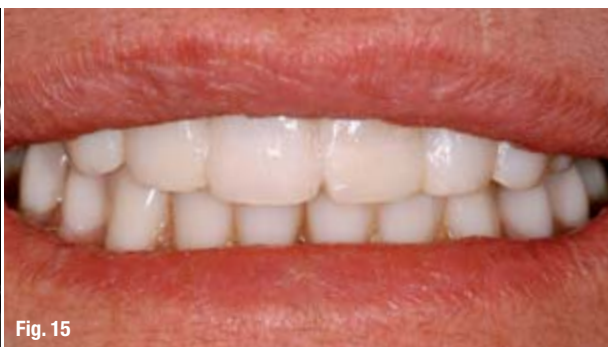
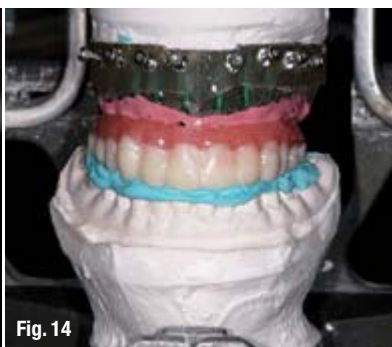
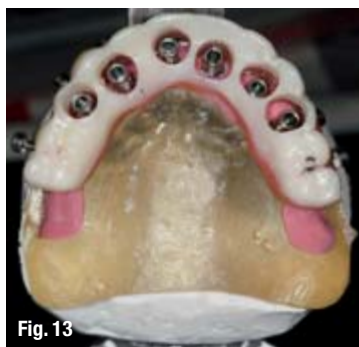Fig. 13 Provisional hollowed out to fit over the temporary abutments.

Fig. 14 Provisional with bite registration for alignment in mouth.

Fig. 15 Completed screw-retained provisional.

lowing for fabrication of an accurate orientation jig on an articulator.

The surgical guide was placed in the patient's mouth, and the tissue was punched utilising a tissue punch (Figs. 6–8). Then, the surgical guide was again oriented in the patient's mouth with the orientation jig created on the articulator and stabilised with three

I decided to immediately load only the six implants that did not involve the sinus cavity. Therefore, healing heads were placed on implants #3 and 14, and non-engaging titanium temporary cylinders were placed on #5, 6, 8, 9, 11 and 12 (Fig. 12). The provisional, which the laboratory fabricated, was attached to the titanium cylinders using cold cure acrylic, thus creating a screw-retained provisional (Figs. 13 & 14).

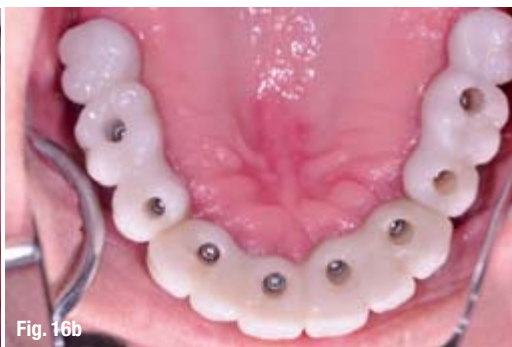
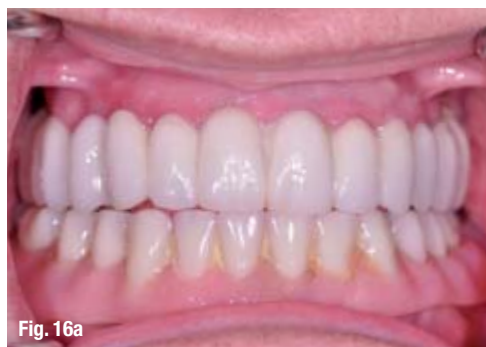
Fig. 16a

Fig. 16b

Figs. 16a & b Final restoration.

SurgiGuide fixation screws (Fig. 9). Utilising the Zimmer Guided Surgery Instrumentation and Guided Surgery drills, all eight osteotomies were created and completed using minimally invasive flapless surgery (Figs. 10 & 11). The Zimmer guide is a SAFE system, accurately providing for depth and size.

The right and left molar (teeth #3 and 14) osteotomies were created short of the maxillary sinus. Then, using the new Sinus Crestal Approach Kit (Zimmer), I extended these two osteotomies into the left and right maxillary sinuses.

Fig. 17 Post-op CT scan.

Alloplastic bone (Puros, Zimmer) was placed into the sinus cavity through the osteotomy and spread using the paddle-shaped spreading bur. Then, all eight implants were placed. Each had initial stability exceeding 35 Ncm.

A post-operative CT scan showed how accurately the eight implants had been placed in the bone using a mucosa-supported SurgiGuide with orientation jig (made on the Immediate Smile model; Figs. 16a, b & 17). The accuracy and success of this case were achieved through CT scanning, SimPlant planning with restorative model overlay, the Zimmer Guided Surgery Instrumentation and the Immediate Smile model. The surgical guide allowed for minimally invasive surgery and greatly reduced surgery time. The Immediate Smile model also reduced chair time by allowing for fabrication of the temporaries well in advance of surgery. The final restoration for this case is a milled zirconia, screw retained appliance.

Acknowledgement

Laboratory procedures and photographs were provided by Dr Marcelo Silva.

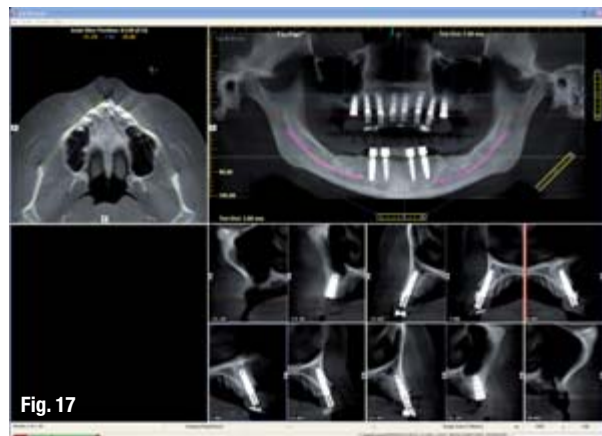

Fig. 17

<u>contact</u>	CAD/CAM
	<p>Dr Max J. Cohen 4700 Chamblee Dunwoody Road Dunwoody, GA 30338 USA</p> <p>MaxJCohen@hotmail.com www.DrMaxCohen.com</p>

Dental Tribune for iPad – Your weekly news selection

Our editors select the best articles and videos from around the world for you every week. Create your personal edition in your preferred language.

ipad.dental-tribune.com

