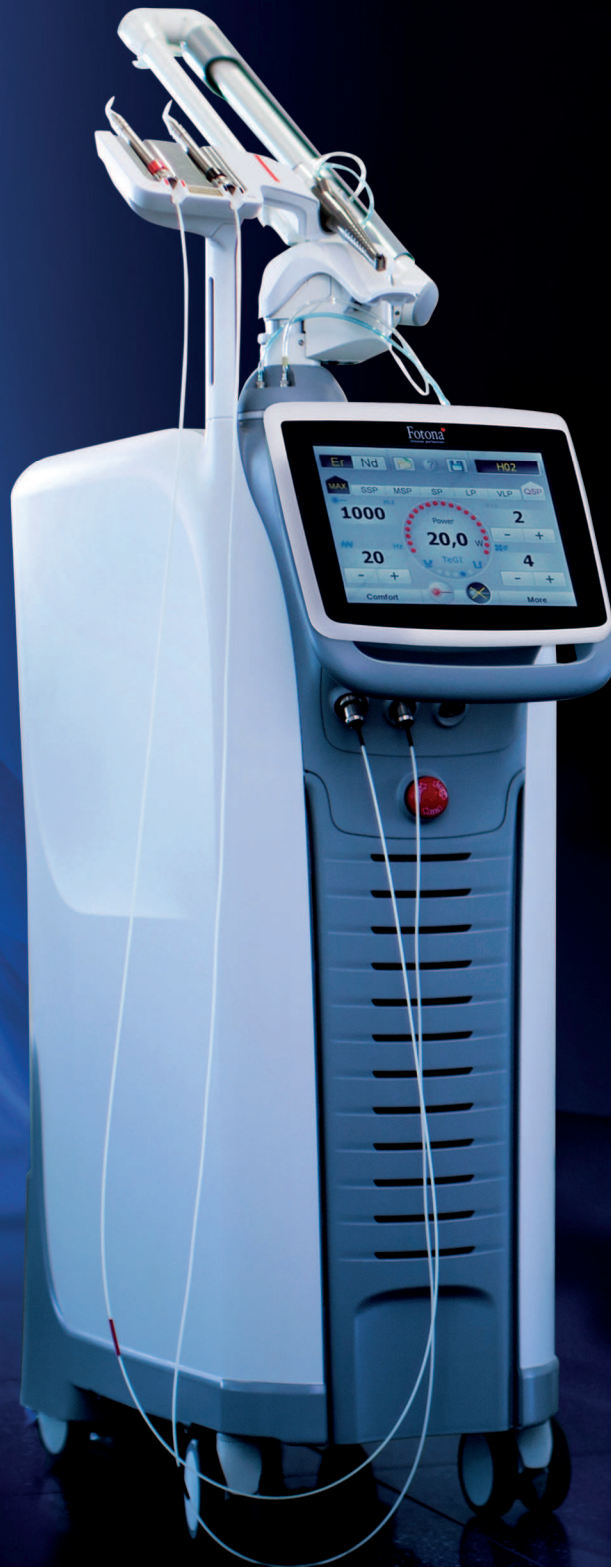

laser



international magazine of laser dentistry

4²⁰¹⁶



research

Blue light laser-assisted
crown lengthening

research

Thermal damage behaviour
dental pulp stem cells

case report

Haemostasis in oral soft
tissue and extraction socket





Master of Science (M.Sc.) in Laser in Dentistry

Next Start: **16th October 2017** | Aachen, Germany | 4 semesters



Become part of the International Dental Elite

- Create new economic potential for your practice
- Two year career-accompanying postgraduate programme at the University of Excellence RWTH Aachen
- Combination of lectures, skill training sessions, live ops, tutorials, and practical workshops
- Internationally accepted and accredited by the German Government, the European Union, the Washington Accord and the Bologna Process
- Science-based and practice-orientated on highest national and international level
- Increased patient satisfaction: minimal contact reduced vibration and pain

**RWTH INTERNATIONAL
ACADEMY
AACHEN UNIVERSITY**

RWTH International Academy
Kackertstraße 10 | 52072 Aachen | Germany
phone +49 241 80 23543 | fax +49 241 80 92525
info@academy.rwth-aachen.de
www.academy.rwth-aachen.de

AALZ

Aachen Dental Laser Center

AALZ GmbH
Pauwelsstraße 17 | 52074 Aachen | Germany
phone +49241 47 57 13 10 | fax +49 241 47 57 13 29
info@aalz.de
www.aalz.de



PROFESSIONAL EDUCATION PROGRAMMES

Your contact for more information: Leon Vanweersch • vanweersch@aalz.de - www.aalz.de



Prof. Dr Norbert Gutknecht

Review & outlook

Dear colleagues,
Dear laser society members,
Dear friends of laser technology,

With this year's last issue of *laser* international magazine of laser dentistry, I would like give a brief summary of the most important events in 2016. Without a doubt, this year's highlight was the WFLD World Congress in Japan with Prof. Kenjy Yoshida as the scientific head. Both scientists from various colleagues and laser users from the dental practice met here in order to discuss the latest research results, therapy concepts and practical experiences.

What took the international stage in Japan was transferred to many smaller venues in various countries around the world. All these events illustrated how new wavelengths have been introduced to dentistry and, moreover, how the already established lasers systems can be applied in new therapeutic fields.

With respect to 2017, I am looking forward to seeing which technical innovations from the field of laser technology will be introduced to the market at IDS (International Dental Show, Cologne, Germany).

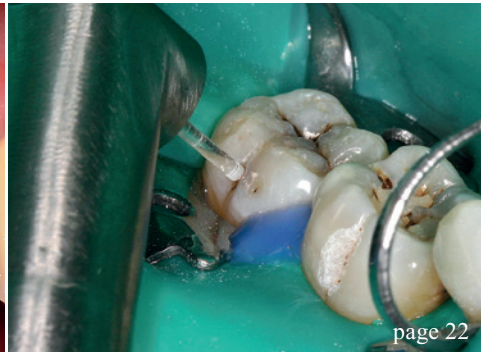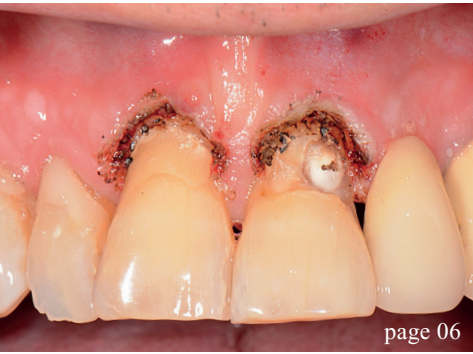In the meantime, the old year will come to an end and a new year is going to start, which is why I would like to send you my best wishes for 2017.

In addition, I would like wish all readers of *laser* international magazine of laser dentistry celebrating Christmas peaceful and blessed Christmas Holidays.

Yours,

A handwritten signature in black ink, appearing to read 'N. Gutknecht'. The signature is fluid and cursive, written in a professional style.

Prof. Dr Norbert Gutknecht



| editorial

- 03 Review & **outlook**
Prof. Dr Norbert Gutknecht

| research

- 06 **Blue light** laser-assisted crown lengthening in **restorative dentistry**
Prof. Dr Matthias Frentzen *et al.*
- 10 **Thermal** damage behaviour of **human dental** pulp stem cells
Prof. Dr Karsten König & Dr Anton Kasenbacher

| case report

- 16 A variety of **photocoagulation** techniques
Sajee Sattayut *et al.*

| industry

- 22 Er:YAG **caries** treatment according to **minimally invasive** therapy
Swietlana Kozaczuk & Kinga Grzech-Leśniak
- 26 An **all-rounder** with three wavelengths
Dr Talat Qadri

| practice management

- 30 Eleven **tips for success** in your dental clinic
Dr Anna Maria Yiannikos
- 32 **Lasers** as an **asset** in both daily **practice** and **marketing**
Dr Imneet Madan

| events

- 36 **25th International Annual DGL Congress**
Dr Georg Bach

| news


- 40 **manufacturer news**
- 41 **news** international

| DGL

- 43 **Rückblick & Ausblick**
Prof. Dr. Norbert Gutknecht
- 44 **Abstracts zur 25. Internationalen Jahrestagung der DGL**

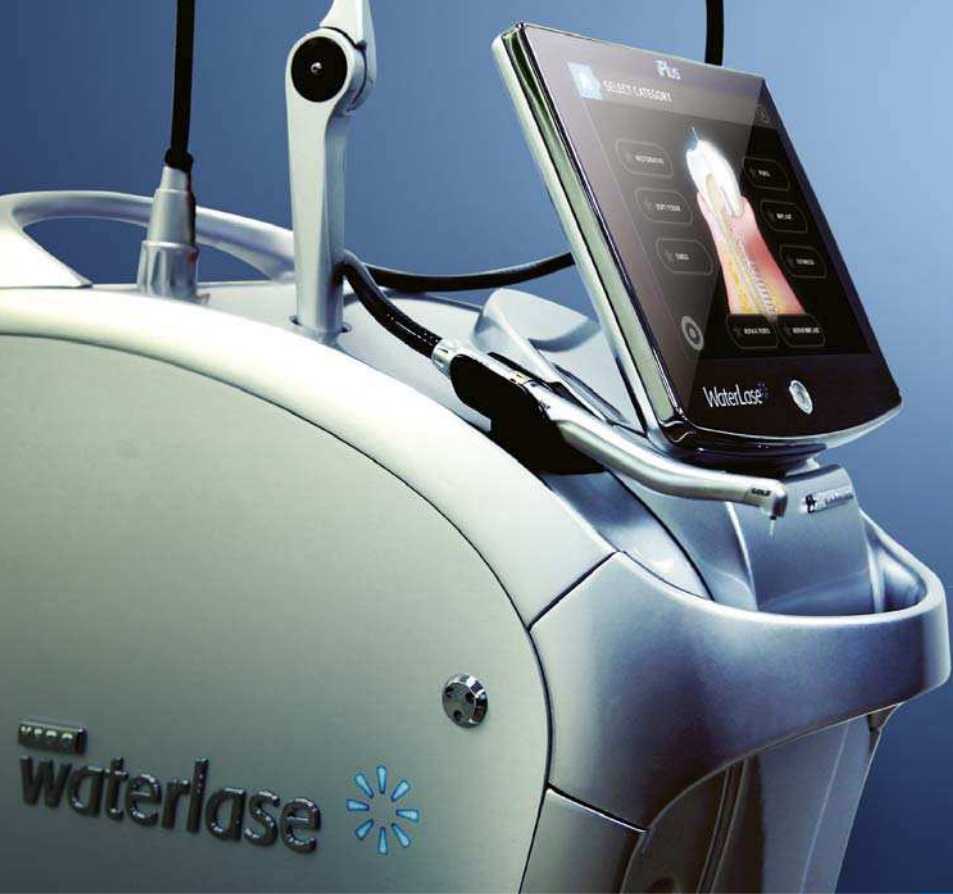| about the publisher

- 50 Imprint



Cover image courtesy of Henry Schein Dental
www.henryschein-dental.de
Original Background: © keren-seg/Shutterstock.com

Trade Up to Waterlase iPlus and Epic 10



Limited time offer!
Trade in your old diode or all-tissue laser
towards a Waterlase iPlus or Epic 10.*

SURGERY, WHITENING AND PAIN RELIEF ...ALL AT YOUR FINGERTIPS

- ✦ Faster treatment and healing
- ✦ Easy to use
- ✦ Exceptional value and ROI
- ✦ Clinical versatility for complete patient care
- ✦ Portable for easy transport
- ✦ ComfortPulse™ modes for the ultimate patient comfort

Epic™



THE WORLD'S MOST TRUSTED ALL-TISSUE LASER

- ✦ Cut Hard-Tissue 250% Faster with Less Sensitivity¹
- ✦ World's first turnkey apps to assist in the management of periodontitis and peri-implantitis
- ✦ Unrivalled versatility, providing unmatched results in treatment outcomes and outstanding ROI
- ✦ Open a new world of clinical capabilities with the most intuitive and easy-to-use graphic user interface
- ✦ SureFire™ Delivery System, ergonomically designed for enhanced flexibility, increased precision, and maximum uptime
- ✦ ComfortPulse™ modes for the ultimate patient comfort

WaterlaseiPlus*™**



BIOLASE

biolase.com

Contact your BIOLASE Authorised Distributor to learn how you can upgrade your practice to Waterlase or Epic Dentistry. Visit go.biolase.com/contact

© 2016 BIOLASE, Inc. All rights reserved.

*Trade-in programme available for a limited time. Epic 10 availability will vary by country. ¹ Data on file.

Blue light laser-assisted crown lengthening in restorative dentistry

Authors: Dr Philipp Skora, Dr Dominik Kraus, PD Dr Jörg Meister & Prof. Dr Matthias Frentzen, Germany

Abstract

Basic investigations of the laser-tissue interaction of a new type of laser device with a wavelength of 445 nm—the blue light spectrum—promise considerable advantages in comparison with infrared laser systems due to the known optical parameters of oral soft tissue. The procedure for a comprehensive laser-based gingivectomy before restorative treatment using this new type of laser is presented in the following case report. Due to the outstanding haemostasis with the blue light laser, both gingivectomy and adhesive filling treatment were possible in only one session. The follow-up examination showed the rapid healing of the wound with no complications and with no post-operative gingival recession. The treatment led to a very good aesthetic result at a moderate effort.

Figs. 1a–e: X-rays of the upper jaw.—Subgingival carious lesions at 11 and 21.

Introduction

Blue light-emitting diode lasers present an innovative alternative to the already established diode laser systems with wavelengths within the infrared spectrum. Due to the strong absorption of blue laser light in oral soft tissue¹, the cutting capacity is improved when comparable laser parameters are used. Blue light lasers have very powerful coagulation effects that enable blood-free work.² In addition, the high antimicrobial effect of blue light has been demonstrated in many fundamental studies.^{3,4} Due to these specific characteristics, blue light lasers are extremely suitable for corrective periodontal surgery in terms of gingivectomies. In contrast to electrosurgery, laser-assisted plastic-aesthetic periodontal surgical procedures do not cause problems of electro-magnetic interactions that could in turn present a contraindication in the

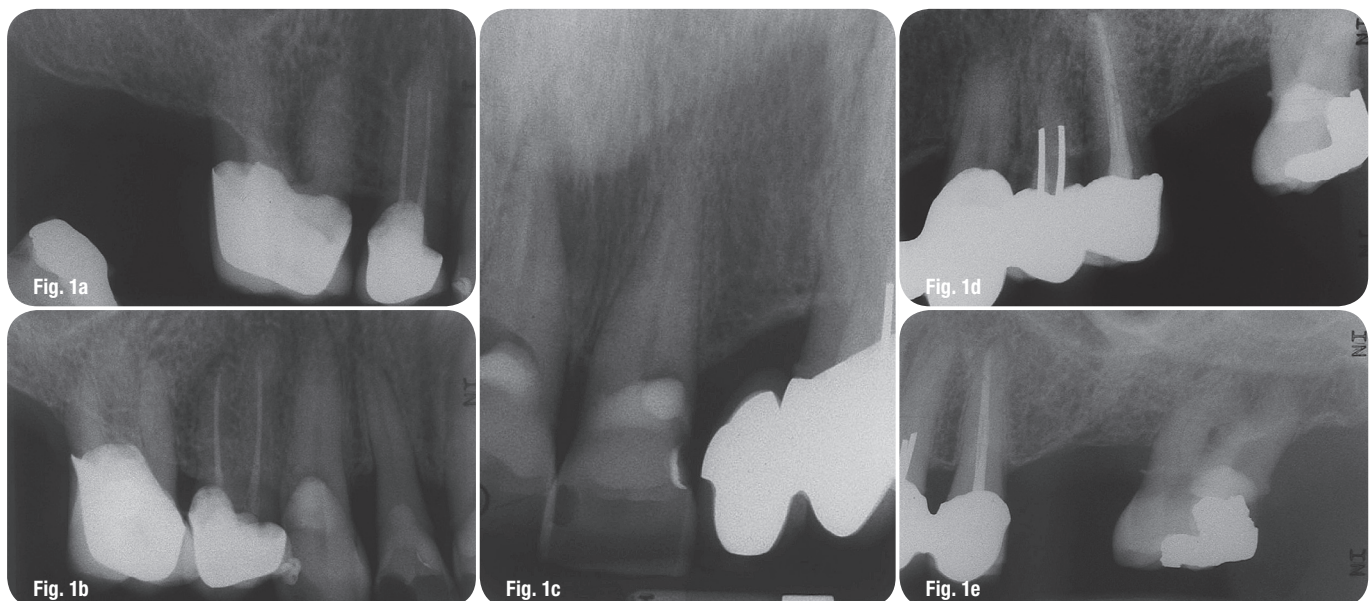

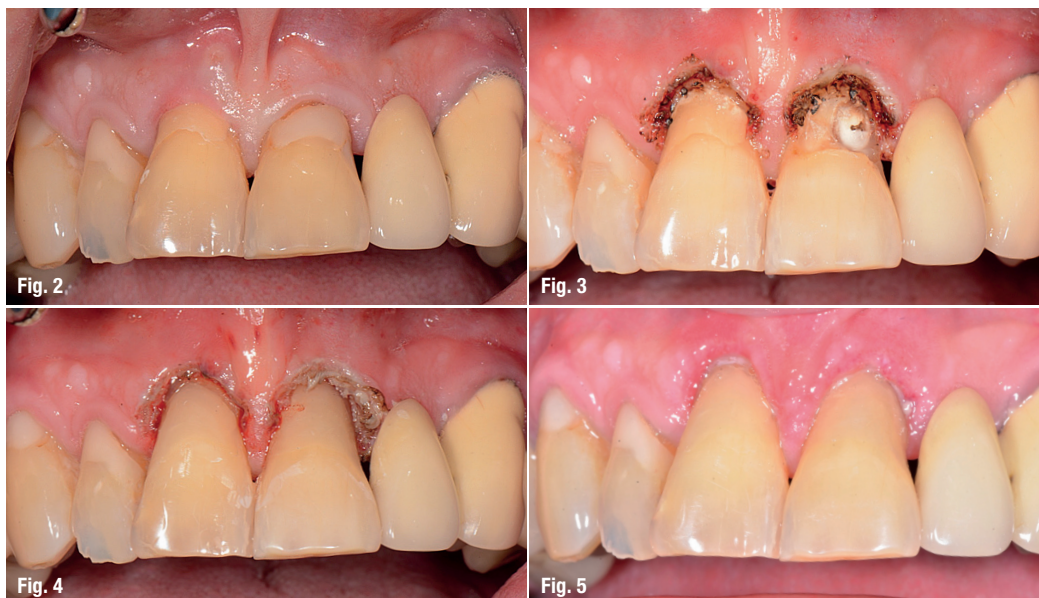


Fig. 2: Pre-operative situs.

Fig. 3: OP-situs after laser surgery (gingivectomy).

Fig. 4: Situation after adhesive composite restoration following laser surgery.

Fig. 5: Post-operative recall after 7 days.

case of patients with symptoms of cardiac disease. In the case of multimorbid patients who are frequently prescribed anticoagulants, the danger of secondary haemorrhage can be minimised. In addition, in these cases, a bloodless surgical field can be created ad hoc, so that moisture-sensitive restorative measures (adhesive dentistry) can be carried out.

In general, for multi-morbid patients it is important that restorative procedures can be carried out in a short time and that the use of anaesthetics should be reduced to a minimum. Excision wounds should heal in a short time period. A dry environment is advantageous, in particular when a dental rubber dam cannot be used.

In case of extended subgingival loss of dental hard tissue, e.g. as a result of carious defects, it is always necessary to enable a visual inspection of the preparation margin before the restoration can be placed. Furthermore, a bloodless, clean, and dry adhesive surface must be guaranteed before application of restorative material. Here, laser-assisted procedures provide a fundamental advantage in comparison to classical surgical procedures. Adequate haemostasis after soft tissue excision with the scalpel, scalers and cuvettes is often not achievable by styptics.

This case study presents a treatment protocol for restorative and endodontic treatment of patients with extensive subgingival carious lesions in the anterior tooth area.

Case report

A 72-year-old patient visited the Dental School of the University of Bonn to obtain a dental consultation regarding prostodontic aspects. The medical history was unremarkable. The patient did not suffer pain.

Among other things, insufficient composite restoration in the anterior tooth regions of the upper jaw were noticeable at the initial examination. In addition, subgingival probing showed defects in dental hard tissues at 11 and 21. For tooth 11, a fistula and an apical radiolucency were found in the vestibular marginal area in the X-ray image (Figs. 1a–e). Teeth 12 and 21 reacted positively to a sensitivity test, in contrast to tooth 11. The probing depths of the teeth 11 and 21 were 4–5 mm.

The treatment plan was explained thoroughly to the patient. In the first session, tooth 11 was trepanated as part of an emergency procedure. After exposure of the root canal, it was rinsed with NaOCl and calcium hydroxide was applied. Ahead of this emergency endodontic procedure, the carious lesions on 11 and 21 were excavated incompletely and treated temporarily with glass ionomer cement.

The patient came for further treatment five days later. The fistula on 11 had closed, clinical symptoms were no longer present (Fig. 2). After an infiltration anaesthesia (1.8 ml UDS), the subgingival carious defects in teeth 11 and 21 were visualised in a gingivectomy (Fig. 3). For both teeth, approximately 4 mm of soft tissue had to be removed to expose the affected area. The gingivectomy was carried out using a 445 nm diode laser (Sirona K-Laser blu, Sirona, Bensheim, Germany) with a power output of 1.5 W in cw mode and an application tip with a diameter of 320 μ m. This device is a pre-serial model equivalent to SIROLaser Blue (Sirona, Bensheim). The resection was carried out in six minutes. The surgical procedure was performed with no pain. After finishing the gingival excision, the surgical field was bloodless and dry (Fig. 3), so that the temporary fillings at 11 and 21 could be removed and the caries completely excavated under visual control. The defects were treated with adhesive

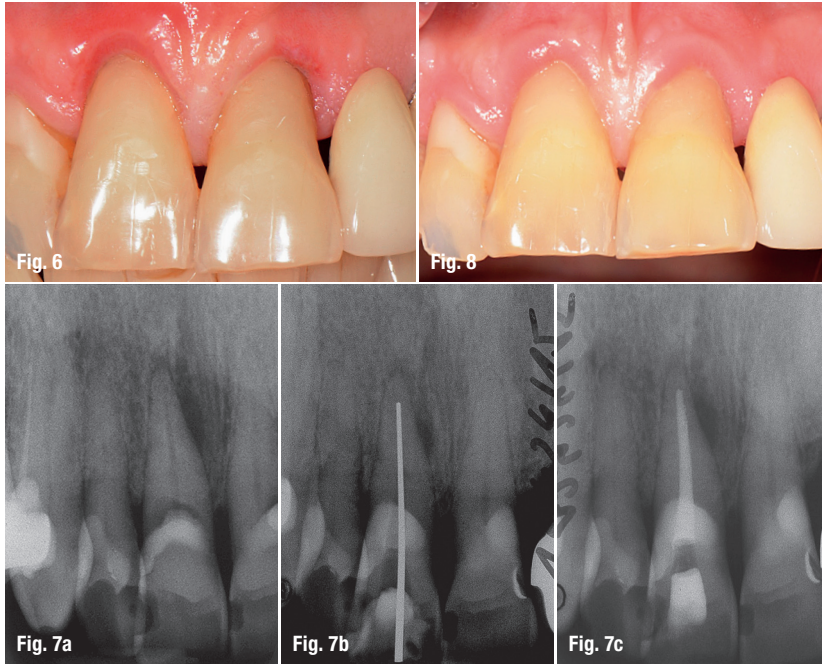


Fig. 6: Follow-up inspection after 14 days.

Figs. 7a–c: X-rays documentation of the endodontic treatment of 11.

Fig. 8: Post-operative recall after 3 months.—Healthy gums and aesthetic restoration of the carious lesions at 11 and 21.

restorations with a composite material in a multi-layer technique (Herculite®; A3,5). Figure 4 shows the situation after the restoration had been completed, including finishing and polishing of the aesthetically complex restoration. After laser treatment, haemostatic measures were no longer necessary for all subsequent treatment steps. In the post-operative recall after seven days (Fig. 5), the patient reported that there was no post-operative pain. After the procedure, the patient did not find it necessary to use the analgetics that had been made available.

After 14 days (Fig. 6), the excision wounds had healed to a very great extent. There was still slight redness in the marginal area. No swelling occurred in the entire post-operative phase. At this time, endodontic treatment was also performed for the devitalised tooth 11. After preparation and sealing of the root canal, the trepanation cavity was closed using a composite material (Figs. 7a–c). Three months after the operative procedure, the endodontic treatment of tooth 11 resulted in no further clinical symptoms. In the treated

area, the probing depth was 1.5 mm. No bleeding was found during probing. No further recession of the gingival margin was found after the primary healing, approximately two weeks after treatment or at the follow-up inspection after three months. Gingival colour and surface texture (gingival stippling) corresponded to a healthy appearance (Fig. 8). To ensure long-term good oral hygiene and to prevent approximal gingival recession at 11/21 in a further step a frenectomy (laser-assisted) should be performed.

Discussion

The presented treatment protocol for laser-assisted gingivectomy enabled the badly destroyed teeth 11 and 21 to be restored in an aesthetically satisfactory manner. Due to the safe procedure and the drying of the surgical field after laser-assisted excision, adhesive fillings were placed in the same session and exhibited no discolouration in the marginal zone, even after three months. This indicates a good bonding between the restorative material and the dentin. There was only little discomfort for the 72-year-old patient which derived from this complex therapy. After an emergency treatment, definitive rehabilitation, including adhesive restorations and endodontics, was carried out in two sessions. The patient did not report any discomfort related to the laser treatment. The patient's aesthetic appearance in the anterior teeth of the upper jaw was restored with moderate means. This treatment procedure improves the patient's compliance, because it allows the patient to partake in a systematic care and treatment concept, which enables the continuation of additional necessary treatment measures.

contact

Prof. Dr Matthias Frentzen
 Welschnonnenstraße 17
 53111 Bonn, Germany
 Tel.: +49 228 287-22470
 frentzen@uni-bonn.de

Author details



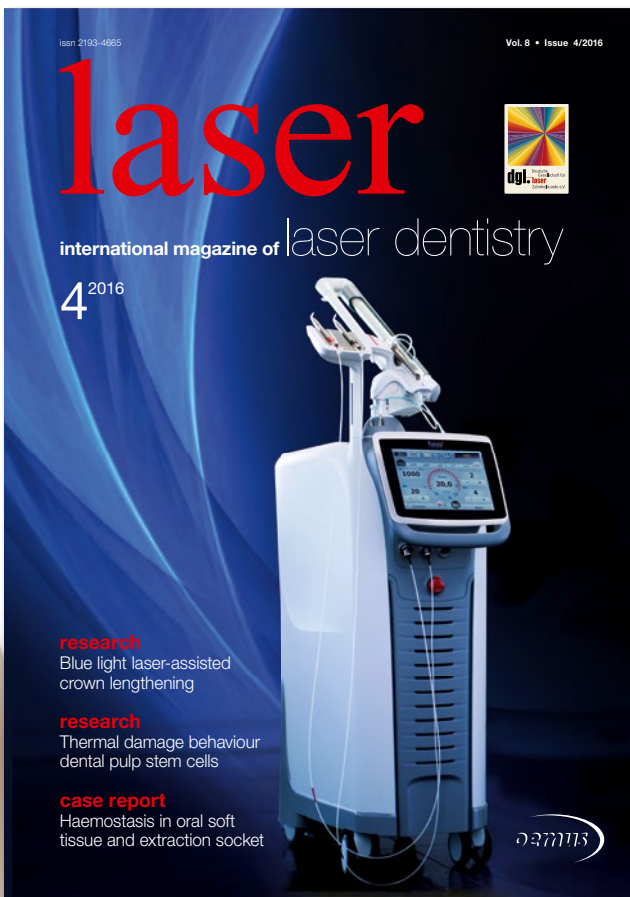
Kurz & bündig

Grundlegende Untersuchungen zur Lasergewebeinteraktion eines neuen Lasertherapiegerätetyps mit einer Wellenlänge von 445 nm – blaues Farbspektrum – versprechen aufgrund der bekannten optischen Parameter orale Weichgewebe nachhaltige Vorteile gegenüber infraroten Lasersystemen. Im Rahmen eines Fallberichts wird das Vorgehen bei umfassenden laserbasierten Gingivektomien vor restaurativer Therapie mit diesem neuem Lasertyp vorgestellt. Gingivektomie und adhäsive Füllungstherapie waren in einer Sitzung aufgrund der hervorragenden Blutstillung mit dem Blaulichtlaser möglich. Die Nachkontrolle zeigte eine schnelle Ausheilung der Wunde ohne Komplikationen und ohne postoperative Gingivaretraktion. Die Therapie führte bei moderatem Aufwand zu einem sehr guten ästhetischen Ergebnis.



Publish your expertise!

Become an author for **laser**—international magazine of laser dentistry



Please contact:

Georg Isbaner · Editorial manager
g.isbaner@oemus-media.de