

implants

international magazine of oral implantology

4²⁰¹³



| research

A new technique for the preparation of the implant site through PES

| overview

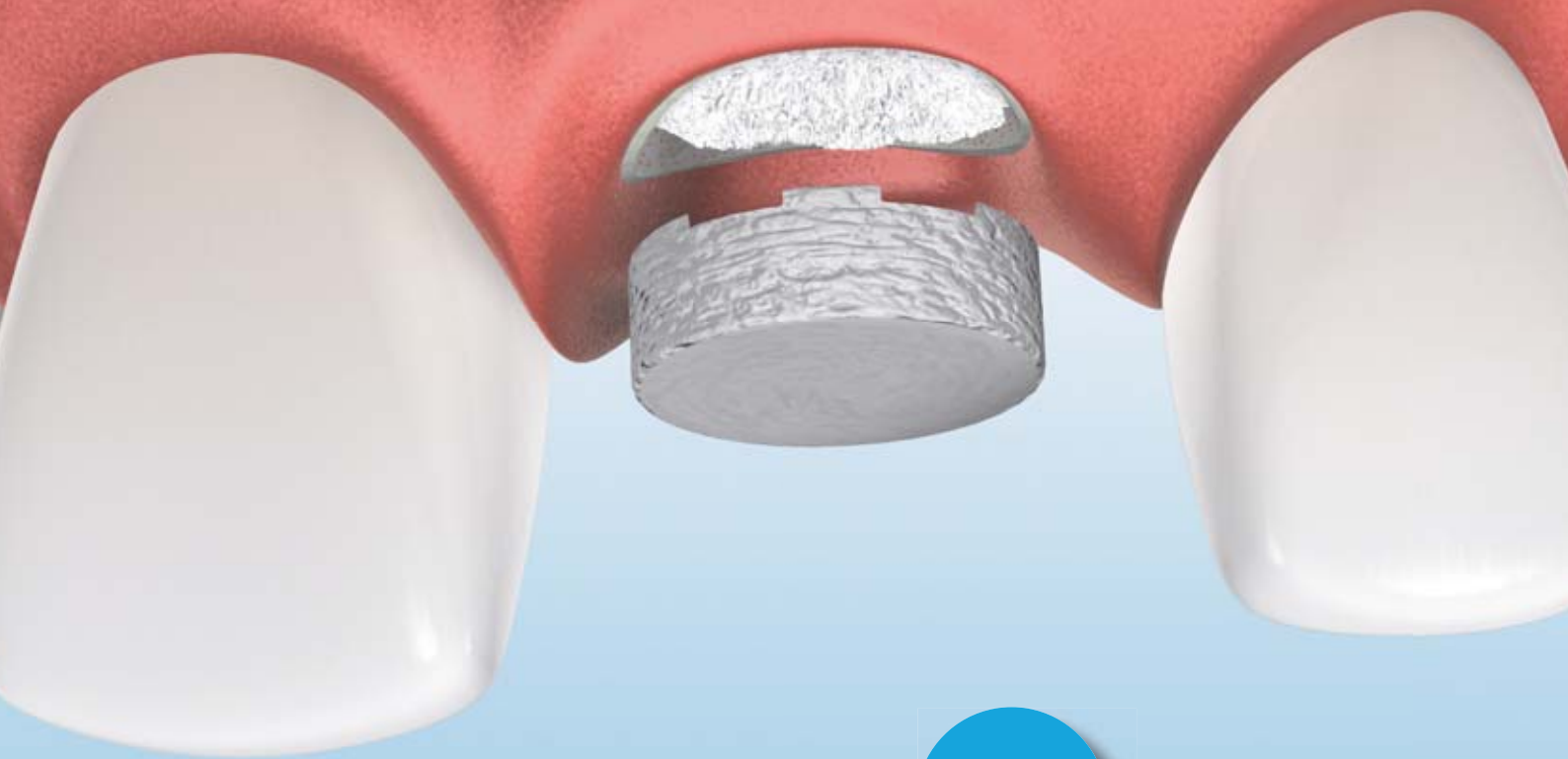Vertical bone augmentation procedures — Part I

| Industry report

Extensive implant-supported restoration in generalised aggressive periodontitis

Geistlich Mucograft® Seal

Minimise invasion, maximise soft-tissue outcome



Benefits at a glance

- > minimal invasion^{1,2}
- > less morbidity²
- > good wound healing¹⁻³
- > easy to use²
- > unlimited availability²
- > good tissue integration^{2,3}
- > constant quality²
- > natural color and texture match^{2,3}
- > reduced surgical chair time²

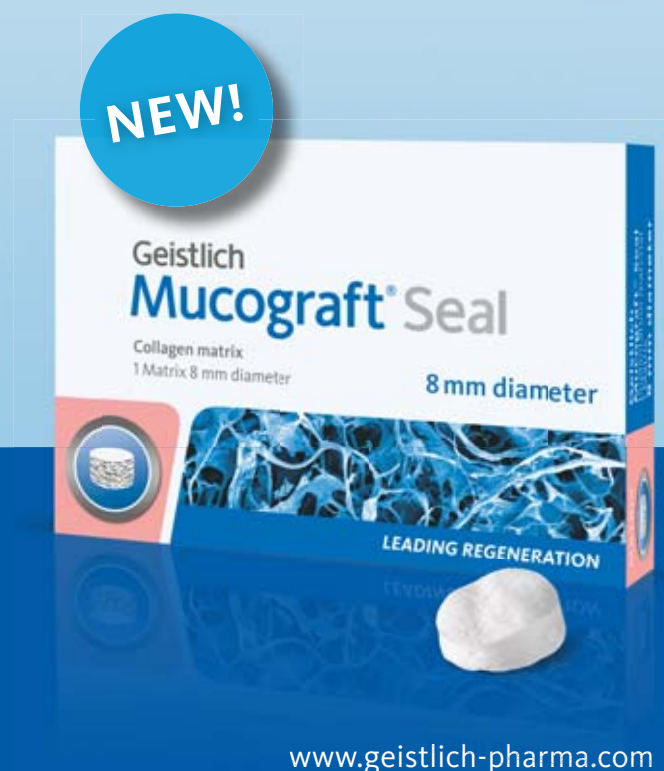

Higher patient satisfaction

¹ Jung R. E. et al., JCP 2013

² Geistlich Mucograft® Seal Advisory Board Report, 2013.
Data on file, Geistlich Pharma AG, Wolhusen, Switzerland

³ Thoma D. et al., JCP 2012



Dear colleagues,



Prof. Dr Heiner Weber

As recently selected President of the DGZI, it is important to me to welcome you all and to gain your trust and assistance in this journey ahead of us. From my previous honorary executive positions, I am convinced that the executive board of a society has to establish a close contact with its members and, moreover, that this contact has to be re-established continuously.

While some dental societies do not admit non-academic members but nevertheless representing major important professions contributing essentially to our common goal of optimal patient care, I will definitely and consequently continue and enhance the idea of DGZI (German Association of Dental Implantology) of implantology as a team approach including dental technicians and dental hygienists.

Our new era of knowledge transfer which has been introduced recently by the DGZI via e-learning is an advancement from which both international and local residents can benefit. Likewise, the establishment of forums and podiums for scientific discussions by gathering speakers and participants from all over the world must be further promoted by the DGZI.

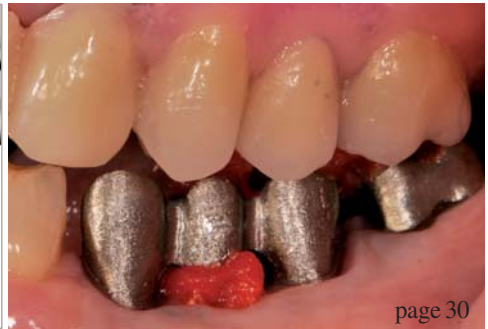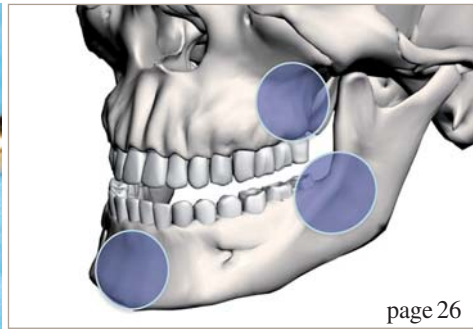
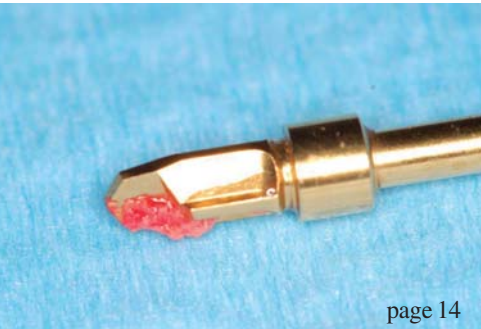In addition, I would like to contribute my personal scientific and practical experience in this special disciplines as well as my international contacts to ensure the DGZI's future success. This encompasses possible congress topics, potential speakers as well as the expansion of international network, building especially on my close contacts to China and the Russian speaking countries. Based on the fact that a prosperous, successful future of any kind of human society is founded on well educated, trained young generations, the DGZI must invest in dental students and other related professional apprentices.

Not only in our clinical professional science, but also in industry, sports etc. it is a well-known fact that only a team can achieve highest levels of success and recognition. Team leaders do need team players, thus, I am happy to be in the "orchestra" of DGZI. The board as well as its members provide all the support being needed and possible for promoting our special discipline of implantology—and, thus, continuously strive for our patient's sake.

With this in mind, I would like to ask all of you to contribute to our aims and endeavours. Thanking you in advance for your support, I remain with best regards,

Prof. Dr Heiner Weber

(Medical Director University of Tuebingen, President of the DGZI, Guest Professor of Beijing University, School of Stomatology/China, and Kyung Hee University, Seoul/Korea)



| editorial

03 **Dear colleagues**
| Prof. Dr Heiner Weber

| research

06 **Retromolar bone grafts prior to implant placement—Part II**
| Andreas Sakkas *et al.*

14 **A new technique for the preparation of the implant site**
| Dr Mauro Labanca *et al.*

22 **Ridge augmentation for an atrophied posterior mandible—Part III**
| Dr Omar Soliman *et al.*

| overview

26 **Vertical bone augmentation procedures—Part I**
| Prof. Dr Dr Florian G. Draenert *et al.*

| case report

30 **A revision of an unaesthetic reconstruction**
| Dental Campus

| industry report

34 **Extensive implant-supported restoration in generalised aggressive periodontitis**
| Dr Dr Philipp Plugmann

38 **Immediate implant placement with the NNC implant**
| Joachim S. Hermann

| news

42 **Manufacturer News**

48 **News**

| meetings

45 **Practice-oriented implantology at the DGZI Annual Congress**

46 **22nd Annual Scientific Meeting of the EAO**

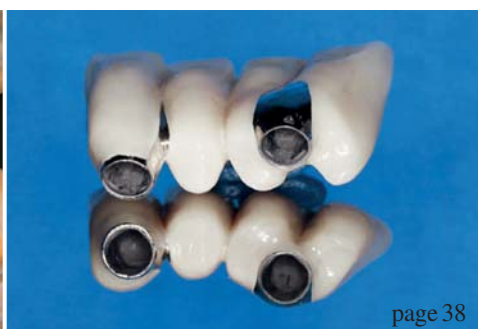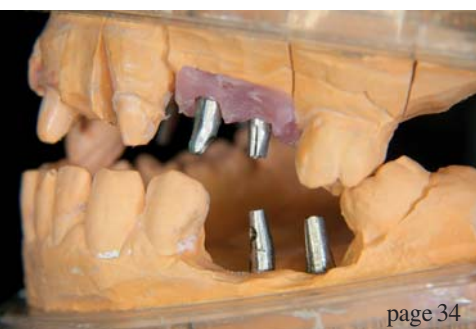
47 **Schütz Dental and DGZI host “Implantology and Anatomy”**

| about the publisher

50 | imprint



Cover image courtesy of DENTAURUM GmbH & Co. KG
www.dentaurum.de
Original Background: ©Hluboki Dzianis
Artwork by Sarah Fuhrmann, OEMUS MEDIA AG.





5TH INTERNATIONAL

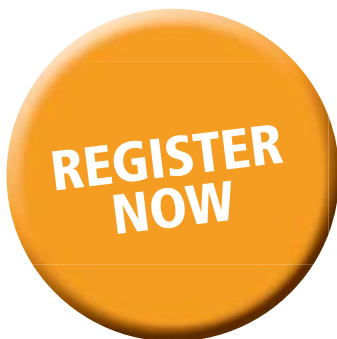CAMLOG CONGRESS

JUNE 26TH THROUGH 28TH, 2014

VALENCIA, SPAIN



CONGRESS OF THE YEAR



First things first: registration possible as of now. More facts: a first-class program, renowned speakers, extraordinary workshops, an atmospheric party, and a fascinating location! Do not hesitate to register, workshops will be booked up, fast. We are looking forward to you!

THE EVER EVOLVING WORLD OF IMPLANT DENTISTRY

camlogfoundation

More information and registration:
www.camlogcongress.com



Retromolar bone grafts prior to implant placement

Outcomes and complications—Part II

Authors Andreas Sakkas, Carsten Winter, Frank Wilde & Alexander Schramm, Germany

Introduction

The dental rehabilitation of partially or totally edentulous patients with oral implants has become common practice with reliable long-term results.¹ However, unfavourable local conditions of the alveolar ridge due to atrophy, periodontal disease, trauma sequel, malformation or neoplasia may cause insufficient bone volume, which may complicate the therapy of the masticatory function with dental implants.² When alveolar ridges lack the appropriate bone volume, additional surgical reconstructive procedures are required. This article concludes Part I (implants 3/2013) with results, an extensive discussion and the conclusion.

Results

One hundred and four retromolar bone graft procedures were performed in 86 patients, 77 men and nine women, with a mean age of 37.9 (range 20.2–58.4 ±10.78 years). Of the 86 patients receiving grafts, 29 were smokers (Fig. 1). Seven patients were pre-diag-

nosed with general-advanced periodontitis, which was successfully treated before bone grafting and one patient with diabetes mellitus Type II.

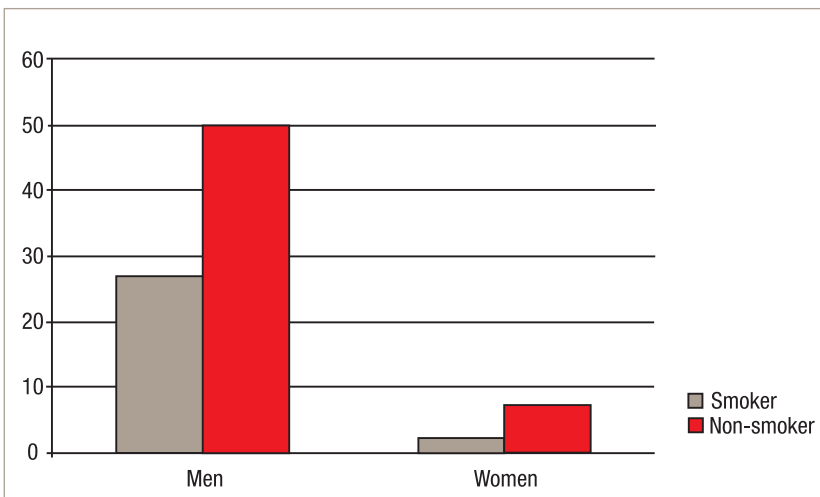
Twenty-two procedures involved the maxilla and 82 the mandible. Also, fifteen patients were treated multiply in different alveolar sites. Regarding the alveolar crest situation, 32 cases were recorded as free-end situation, 27 as multiple teeth gap and 39 as single teeth gap. These as well as the intraoral area separation are presented in Table 4. In ten patients, two bone blocks were harvested in one single augmentation position.

Of the 104 onlay bone grafts, 81 (77.8%) were defined absolutely successful and 23 (22.2%) had minor adverse effects, such as incision-line dehiscence, swelling or wound infection with pus exit, or temporary paraesthesia. Only eight grafts (7.6%) in seven patients were defined as failures (i.e. graft exposure and screw mobilization). Of all the areas with complications, 15 were defined in the donor site, 23 in the recipient area and in four patients experienced complications in both donor and recipient site.

Regarding postoperative swelling following the bone grafting procedure, most of the patients suffered a minimal facial deformity lasting not longer than three days. Swelling was otherwise an expected complication after surgery. At two weeks after the operation, none of the 86 patients reported persistent pain. There was no significant association between periodontitis and complications ($p=0.43$) (Fig. 2). There was also no relation between complications or failure rates of the recipient site and jaw areas ($p=0.21$) (Fig. 3).

No major complications were observed regard to donor sites. One patient developed a wound infection with exit pus, and two patients developed an abscess, which had to be opened surgically in local anaesthesia.

Fig. 1 Separation of the patients in men and women, according smoking habit.



No incision-line dehiscence occurred in the donor site areas. Eleven patients mentioned sensory deficits in the lower lip and mental foramen area and three of them experienced altered sensation in the mental and lower lip area as well as in the tongue. None of the patients experienced altered sensation localised in the region of the buccal nerve terminal branch. The incidence of temporary mental nerve paraesthesia was 10.5% (11/104). At the time of implant insertion, there were no reports of symptoms other than the persistence of altered sensation in two patients who had reported paraesthesia during suture removal. One of the patients experienced postoperative bleeding and was treated with local haemostasis (Tab. 5). A relation between smoking or medical history and complications of the donor site is not possible, because these incidents are usually caused iatrogenically.

In the ten patients who underwent impacted third molar tooth extractions combined with bone harvesting, a temporary paraesthesia or wound infection were observed in six of them. In the recipient sites, the frequency of complications was higher than in donor sites. Except the minor complications such as wound infection with pus exit or incision-line opening, graft exposure and screw mobilization as well as combinations of them (Tab. 6). In Figure 4, some complications in recipient sites are presented.

Seven (31.8%) of them were observed in smokers and 15 (68.2%) in nonsmokers in a total of 22 bone grafts. The temporary paraesthesia on the recipient site observed by one patient was not taken in consideration. Figure 6 presents the separation of the postoperative complications both of the donor and recipient site according to smoking. Statistic significance between smoking and complications was to be considered ($p = 0.009$). In one diabetic patient, loss of bone particles

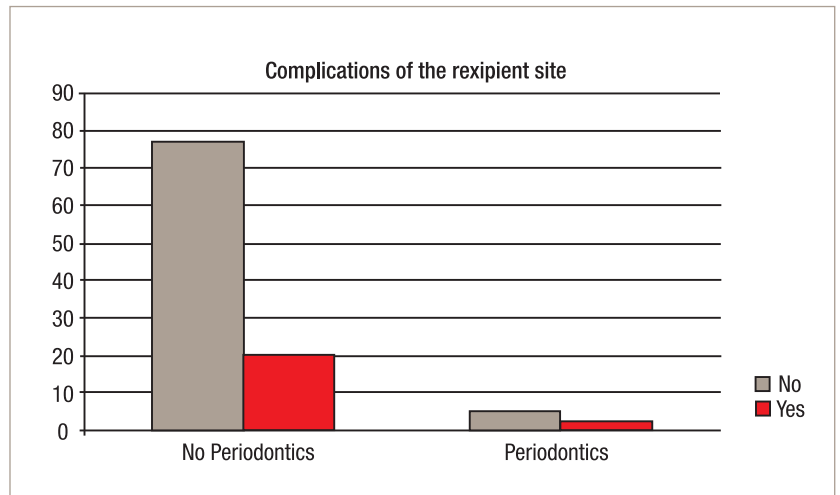


Fig. 2 Association between periodontitis and complications of the recipient site.

after infection was observed and no implantation was realizable. Wound infection and graft exposure were also observed in two patients with preoperatively diagnosed general-advanced periodontitis. However, no association was found in this study between retromolar bone grafting complications and medical history, because of the low number of patients.

A great value was given to the management of the postoperative complications. Minor effects were treated conservatively with mouth rinse included chlorhexamid and antibiotics either orally or intravenously. Patients with abscess had to be treated surgically and were also covered with antibiotics. By graft exposure, the bone sequestrers were removed and the bone block was refreshed, while the wound was closed with a buccal fat pad under antibiotic cover. By patients with screw mobilization, healing was uneventful after the removal of the screw. In eight (7.6%) of the cases, the bone graft was totally exposed combined with wound infection and exit of pus. The surgical removal of the graft was

Table 1 Complications associated with retromolar bone grafts.

Complications	Etiology	Prevention	Management
Infection, membrane contamination	Microbial contamination	Antibiotics and aseptic surgical procedure	Remove infection source, systemic antibiotics and antimicrobial mouth rinse
Incision line opening, membrane exposure, wound dehiscence, perforation of mucosa	Tension-free closure not achieved	Achieve tension-free primary closure	systemic antibiotics and antiseptic mouth rinse
Nerve dysfunction	Damage to infra-alveolar nerve		Know the anatomy, wait and sometimes palliative treatment may be needed
Graft mobilization	Inadequate fixation (insufficient screws, screw loosening)	Secure fixation screws, use >1 screw, ensure no-mobility and no dead space principle	Remove and regraft at later time
Loss of bone graft particles	Primary closure not achieved	Achieve tension-free primary closure, use of membrane	Do nothing and allow for proper healing

Autors	No. of patients	Reported complications
Girdler & Hosseini 1992	12	Temporary lingual paraesthesia
Raghoobar et al. 1996	7	none
Von Arx et al. 1996	4	none
Misch 1997	19	Incision dehiscence
Schlegel et al. 1998	5	none
Von Arx et al. 1998	13	Hypoaesthesia n. V3, massive postop. bleeding
Cordaro et al. 2002	15	Bone resorption
Clavero 2003	24	Hypoaesthesia n. V3
Schwartz-Arad 2005	10	Graft exposure, Hypoaesthesia n. V3
Schwartz-Arad 2005	18	Incision dehiscence, Graft exposure, Hypoaesthesia n. V3

39 in the maxilla and 116 in the mandible. All these implants were placed using the CoDiagnostiX® (IVS Solutions AG) program for guided surgery. All the implants were integrated at the abutment connection. To date (mean of six months after prosthetic loading) all the implants were successful, according to the Albrektsson criteria.⁶² In eight of the cases (7.6%), implant installation was not possible due to insufficient bone after augmentation procedures. Despite the complications, a significantly higher loss of bone grafts was not found. After the prosthetic rehabilitation, the oral function was completely re-established in all patients.

Discussion

The use of endosseous implants may be limited by insufficient quality and quantity of available bone. Several grafting procedures have been described to create sufficient volume of bone for implant placement.³³ Autogenous grafts still remain the "gold standard" in reconstructive surgeries due to their osteoinductive, osteoconductive, and osteogenic potential, essential for bone morphogenesis.³⁴⁻³⁵ Serra e Silva et al. conclude that autogenous bone grafts are the best option compared with allografts and xenografts due to its properties and constitute a viable form of treatment for patients with alveolar bone loss.³⁶ The placement of implants into healed bone grafts as a secondary procedure is similar to their use in jaws that have not been grafted.³⁷

Several studies have reported on harvesting of grafts from the retromolar region.^{13, 20, 22, 24, 26, 28} However, the number of complications is discordant when the different trials are compared. This seems to be because none of the studies is prospective and based on objective tests for the function of inferior alveolar and lingual nerves. Advantages of retromolar bone grafts are the use of local anaesthesia instead of general anaesthesia, no need to stay in hospital postoperatively, less morbidity at the donor sites, and lower costs.^{38, 39} A disadvantage is the small volumes of bone offered.

Performing ridge augmentation and implant placement as two-stage surgery is still said to be more successful than the single-stage procedure.^{31, 40} A healing period for mandibular grafts of four months has been recommended.^{5, 13, 31} There is experimental evidence that grafts from membranous bone show less resorption than endochondral bone due to early revascularization, better potential for incorporation in the maxillofacial region because of a biochemical similarity in the protocollagen, and the inductive capacity is greater because of a higher concentration of bone morphogenetic proteins and growth factors. The early revascularization seems to explain the good maintenance of volume of the retromolar graft.⁴¹ However, a major disadvantage of retromolar grafts remains. Only a confined amount of bone can be harvested from this donor

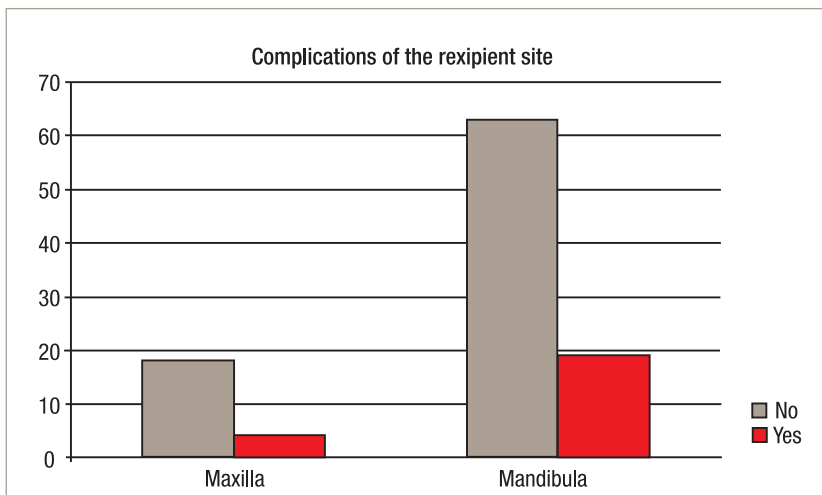
Table 2 Review of the literature on harvesting of retromolar bone grafts.

then inevitable. The wound healing was subsequently uneventful, but there was not enough bone for insertion of implants. A second augmentation procedure was then performed in only two cases. The patients with temporary paraesthesia by the suture removal always had control appointments until the healing of their nerve dysfunction (Tab. 7).

Bone resorption was easily visible on removing the osteosynthesis screws since the heads of the screws were always 1 to 2 mm above the grafted bone. On re-opening, the shape of the grafted block was rarely visible in most of the cases. Of the 104 bone reconstructions, 19 (18.2%) required simultaneous augmentation at the time of dental implant placement.

The average healing period after bone harvesting was 125.8 days or 4.49 months, ranged from 91–276±66.23 days. 155 dental implants were placed,

Fig. 3 Association between jaw and complications of the recipient site.



site. It has been described that the volume is half of what can be achieved from the mandibular symphysis.¹³ The dense structure of cortical portion of the grafts offers the benefit of improved implant stability during placement and healing and may even improve interfacial stress transmission on implant loading.^{5,30,42}

The aim of this study was to report clinical results of alveolar ridge augmentation in partially edentulous patients prior to implant placement, using bone blocks from the retromolar region and firmly secured to the recipient site with osteosynthesis screws with the use of barrier membranes. The clinical indication for the procedure was the lack of sufficient alveolar bone, a situation that could interfere with the correct placement of implants of the desired length.

In this retrospective study, the data reported were readily collected from the authors after the postoperative phase. The sample studied was small and the augmented sites differed in location and type of defect. In the absence of a control group, the statistical significance of the means calculated was not tested. A new surgical devise with piezoelectric ultrasonic generator (Mectron, Deutschland Vertriebs GmbH) recently developed, offers an alternative way of safely removing hard tissue without damaging soft tissue and is a useful tool of harvesting procedures from the ramus.

Barrier membranes have been used to achieve alveolar ridge augmentation in implant surgery in a staged approach, or at the same time as implant placement.^{6,10,43} The use of barrier membranes in combination with particulate grafts and implants to augment the alveolar ridge and obtain ideal positioning of implants is reported to be an effective procedure in both humans and experimental animals.^{6,31,44} The use of barrier membranes over particulate bone grafts seems to reduce the tendency for bone graft to be reabsorbed during the healing phase. It must be pointed out that the tendency of bone grafts to resorb during the healing phase also occurs if the graft is protected by a membrane and no complications arise.⁶ However, the use of barrier membranes generally may be followed by soft tissue dehiscence, membrane exposure and plaque colonization and, in very few cases, by the need to remove the barrier. This complication jeopardizes the whole procedure.⁴⁵⁻⁴⁶ According to Buser et al (1996), if a staged approach is used, complications involving membrane exposure, suture dehiscence and loss of the graft are minimal.⁶

Fixation of an onlay graft to the recipient site can influence the revascularization of a graft.⁴⁷ A loose graft may become nonunioned and encapsulated. Fixation screws for the onlay graft should be tightened to ensure close adaptation. Infection is usually a consequence of poor aseptic control of the surgical field. Rinsing with

Etiology	N
Caries/Periodontitis	97
Trauma	3
Hypodonty	4
Total	104

Table 3 Etiology of tooth lost.

Alveolar ridge Situation/ jaw	Maxilla	Mandibula	Summary
Free-end situation	7	30	37
Multiple teeth gap	12	16	28
Single tooth gap	3	36	39
Summary	22	82	104

Type of complication	N
Wound infection with pus	1
Swelling/abscess	2
Hypoesthesia N. mental	11
Hypoesthesia N. mental and lingual	3
Postoperative bleeding	1
Total	18

Table 4 Distribution of alveolar ridge situation and jaw separation prior to implant placement.

Table 5 Type and number of post-surgical complications in donor sites.

chlorhexidine before surgery is a preventive measure to reduce the risk of infection. Tension-free flap closure is essential so exposure of the membrane or fixation screws can be prevented.⁴⁸

The limits of the retromolar area are dictated by clinical access, as well as the coronoid process, molar teeth, and inferior alveolar canal. A rectangular piece of bone up to 4 mm in thickness may be harvested from the ramus. This morphology conforms especially well as a venner graft to gain additional ridge width.⁴⁹

A vestibular incision that extends well beyond the mucogingival junction creates easier access but produces more soft tissue bleeding and intraoral scar formation. Haemostatic materials are placed into areas of osseous bleeding, and postoperative pressure dressings reduce the development of haematoma formation, incision line dehiscence and infection. The use of glucocorticoids is helpful in reducing postoperative oedema.⁵⁰⁻⁵² The ramus graft patients appeared to have fewer difficulties in managing postoperative oedema and pain.

Pain is also reduced in the first day after surgery. No adverse effects for single dose or a negative effect on