

# implants

international magazine of oral implantology

2<sup>2013</sup>

## | Research

Ridge augmentation for an atrophied posterior mandible

## | Overview

Advantages of 3-D planning for implants

## | Case report

Implant-supported rehabilitation after radiation therapy



Geistlich  
**Bio-Gide®**

The Original leads  
to the top.

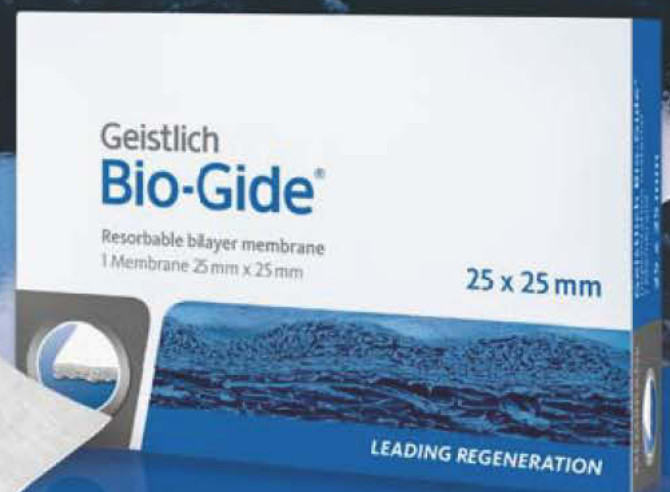2012

1996

Long-term  
results of  
12–14 years<sup>1</sup>

Geistlich Bio-Gide® –  
The Original

<sup>1</sup> Jung RE et al., Clin. Oral Implants Res. 2012; Jun 15 (Epub ahead of print)



[www.bio-gide.com](http://www.bio-gide.com)

# Practice-oriented implantology



Dr Rolf Vollmer

\_IDS 2013 has both met and exceeded any expectations implantologists could foster towards the world's leading international dental exhibition. With more than 15 million implants already inserted in Germany alone and over 800,000 implantations every year, implantology is a regular focal point at IDS and many implantologists are among the visitors.

As the oldest European society for implantology, DGZI (German Society of Oral Implantology) took its responsibility as an internationally active organisation for dental implantologists seriously and was present with its own booth. Specialists from around the world were welcome to learn more about the DGZI training programs and DGZI membership. The DGZI booth was also a meeting point for regular members both nationally and internationally. The DGZI executive board, among them DGZI President Prof. Dr Dr Frank Palm, Dr Roland Hille and Dr Rainer Valentin, were available for any requests throughout IDS, providing aspiring and long-term members, co-operation partners as well as the media with information on future events and activities of DGZI.

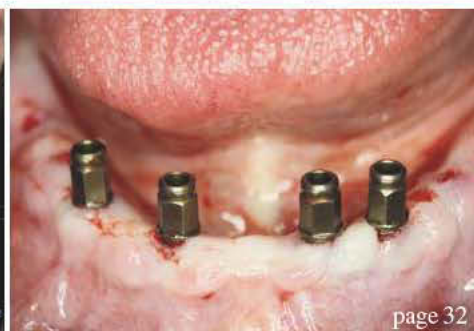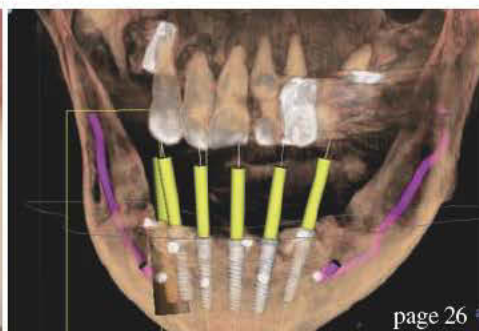
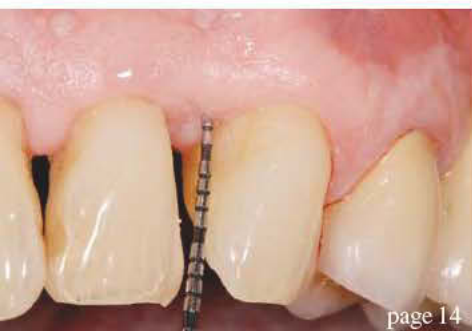One of the central topics was of course the 43<sup>rd</sup> DGZI International Congress from 3 to 5 October 2013 in Berlin. "Practice-Oriented Implantology" will be this year's headline of the traditional DGZI meeting led by Congress President Prof. Dr Dr Frank Palm and Scientific Director Dr Roland Hille. The DGZI International Congress has established itself as a meeting point for novice as well as highly experienced clinicians, presenting the latest scientific insights and evidence-based clinical observations on the current developments in this special field.

With this in mind, the DGZI executive board is happy to have promoted implantology successfully at IDS and strives to reflect DGZI's activities and international orientation again in this issue of *implants—international magazine of oral implantology*. Therefore, we hope you will enjoy reading the specialist articles on the following pages and will be glad to welcome specialists in implantology again in Berlin this fall!

Yours,

Dr Rolf Vollmer





## editorial

- 03 **Practice-oriented implantology**  
| Dr Rolf Vollmer

## research

- 06 **Ridge augmentation for an atrophied posterior mandible—Part II**  
| Dr Omar Soliman *et al.*
- 14 Periodontal **tissue repair** in the aesthetic zone  
| Giulio Rasperini *et al.*

## overview

- 18 **Bisphosphonate** therapy and **osteonecrosis** of the jaw  
| Johannes D. Bähr *et al.*
- 26 **Advantages of 3-D** planning for implants  
| Dr A. Grandoch *et al.*

## case report

- 32 **Implant-supported rehabilitation** after **radiation** therapy  
| Dr Umut Baysal *et al.*

## industry report

- 36 The **finesse** of the pink and the **power** of IPS e.max  
| Rafael Santrich *et al.*

## news

- 42 **Manufacturer** News
- 49 **News**

## meetings

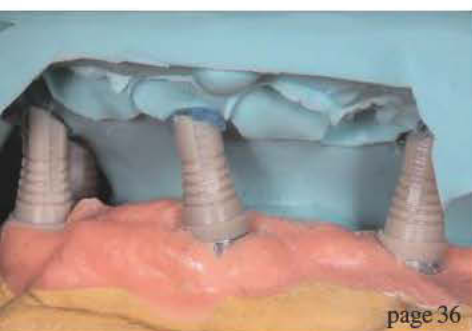- 45 **IDS 2013** sets new **records**  
| Koelnmesse GmbH
- 46 **IDS** Statements
- 48 **Osteology** celebrates its 10<sup>th</sup> anniversary!

## about the publisher

- 50 | imprint



Cover image courtesy of Degradable Solutions AG,  
[www.easy-graft.com](http://www.easy-graft.com)



# Legacy™ System

100% Compatible with Zimmer® Dental



Cover Screw Healing Collar

**Reality Check**  
Zimmer Customers

## Legacy™3 Implant

All-in-One Packaging includes implant, abutment, transfer, cover screw & healing collar €145



## Legacy™ Implant System Advantages:

Industry-Compatible Internal Hex

Prosthetic compatibility with Zimmer Dental Screw-Vent®, BioHorizons® & MIS implants

Surgical Compatibility with Tapered Screw-Vent®

No need to change surgical protocol or tools

Three Implant Designs & Packaging Options

Allows for selection based on price, packaging or thread design

**Legacy1:** €115 includes cover screw, healing collar & plastic carrier

**Legacy2:** €130 includes cover screw, healing collar & temporary abutment/transfer

**Legacy3:** €145 includes cover screw, healing collar & preparable abutment/transfer

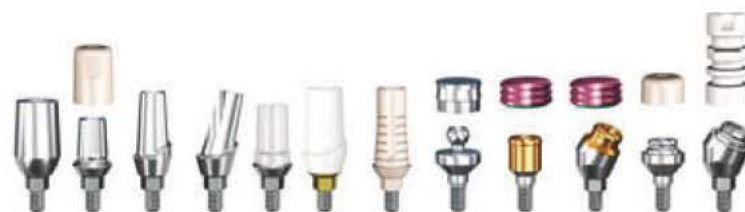Micro-Threads

Reduce crestal stress for improved initial stability

Widest Range of Dimensional Options

The entire Legacy system includes seven implant diameters

(3.2, 3.7, 4.2, 4.7, 5.2, 5.7, 7.0mm) & six implant lengths (6, 8, 10, 11.5, 13, 16mm)



Laboratory Abutment	Straight Snap-On	Straight Contoured	15° Angled Contoured	Gold/Plastic	Zirconia/Ti Abutment	Plastic Temporary Abutment	Ball Attachment	GPS™ Attachment	Angled GPS™ Attachment	Multiple-Unit w/Cap & Transfer	Multiple-Unit Straight	Multiple-Unit Angled
€60	€75	€75	€75	€90	€90	€30	€68	€90	€90	€75	€90	€90

## Legacy™1

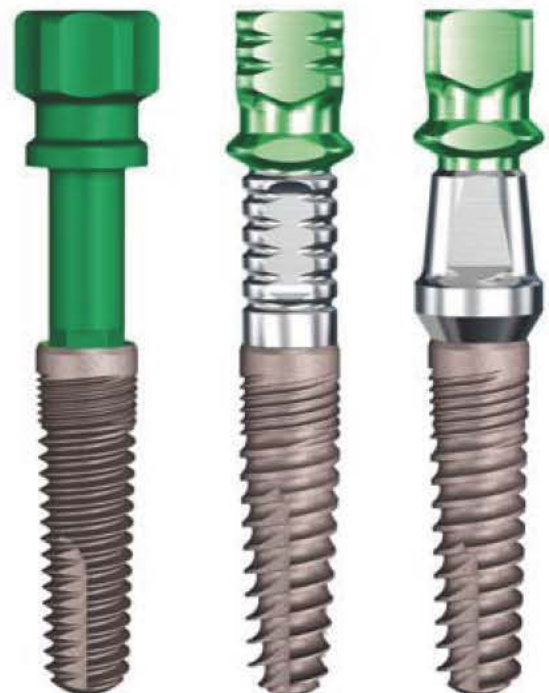Standard "V" Threads  
Matches Screw-Vent®

## Legacy™2

Spiral Threads  
for Increased Stability

## Legacy™3

Buttress Threads  
for Increased Surface





# Ridge augmentation for an atrophied posterior mandible—Part II

## NanoBone block **versus** allograft bone block

**Authors** Dr Omar Soliman, Prof. Dr Mohamed Nassar, Ass. Prof. Dr Mahmoud Shakal & Ass. Prof. Dr Eman Mohy El-din Megahed, Egypt

### \_Introduction

The aim of the present study was to compare the clinical outcome and radiographic bone changes in augmented ridges utilising a synthetic NanoBone block versus an allograft bone block, and to investigate histologically the success of a synthetic NanoBone block versus an allograft bone block for ridge augmentation.

*In the previous issue of implants: international magazine of oral implantology, the authors gave a detailed introduction to their topic and explained the materials*

Fig. 1\_Incision line opening in group A.

Fig. 2\_Partial graft exposure in group A.

Fig. 3\_Screw exposure.

Fig. 4\_Screw loss in group A.

Fig. 5\_Complete graft exposure in group A.

Fig. 6\_Inflammation in group A.

Fig. 7\_Inflammation in group A.

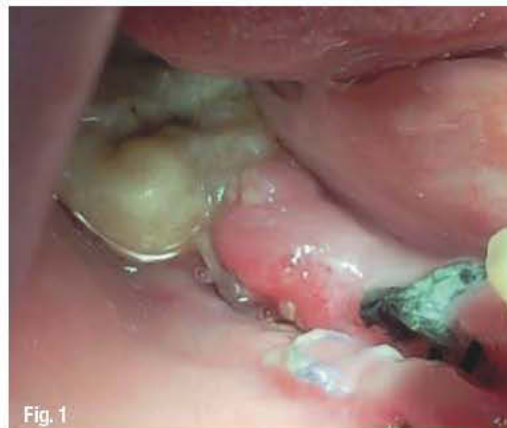

Fig. 1

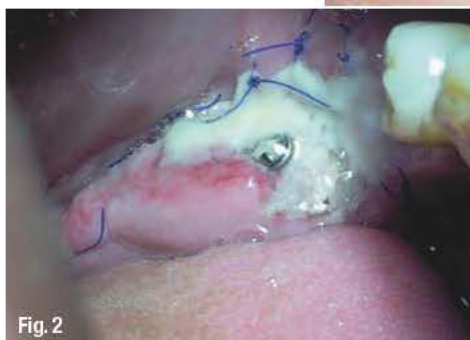

Fig. 2

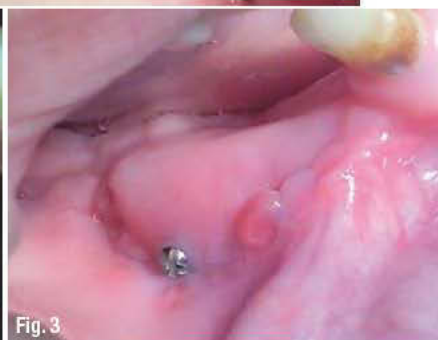

Fig. 3

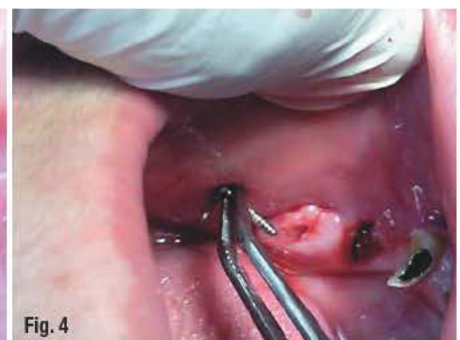

Fig. 4

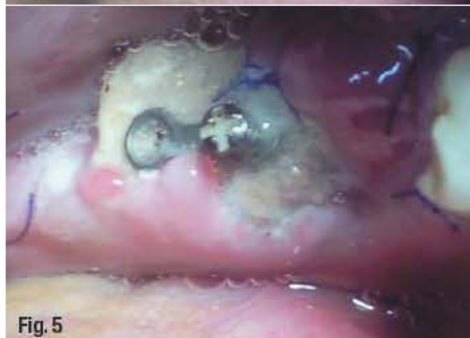

Fig. 5

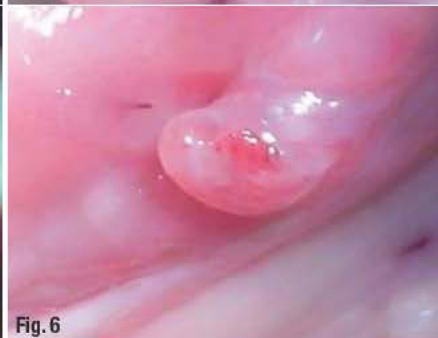

Fig. 6

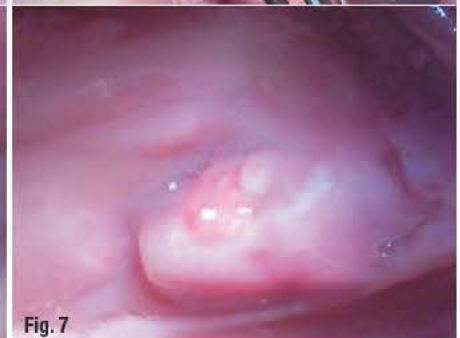
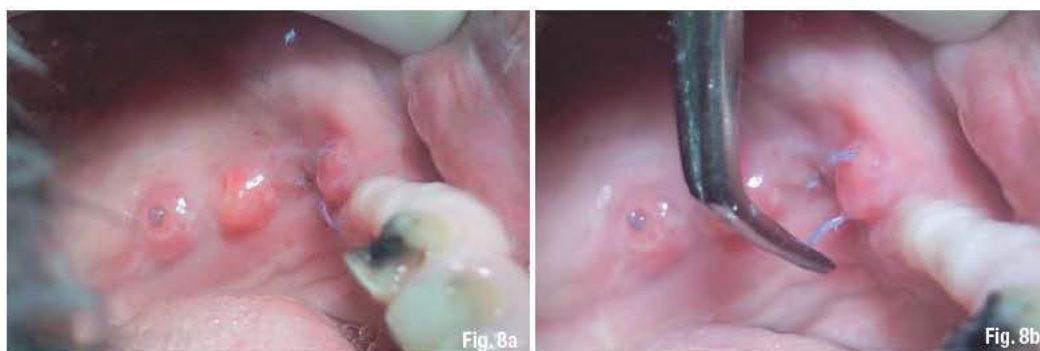
Fig. 7





**Figs. 8a & b** Inflammation in group B.

and methods used in their study. In this issue, their report is completed by the results of their investigations and an extensive discussion.

## Results

### Clinical results and complications

– Group A: During intra-operative procedures, NanoBone augmentation was associated with fracture of the NanoBone block during augmentation in one case because it was fragile and fractured easily. In the post-operative period, soft-tissue complications such as the incision line opening (one case, Fig. 1), a small perforation of the mucosa over the grafted bone (two cases, Fig. 7), and graft infection (one case, Fig. 6) occurred. In addition to partial graft exposure (Fig. 2), screw exposure (Fig. 3) and screw loss (Fig. 4), one block graft was completely exposed (30 days after surgery) and lost (Fig. 5). Treatment was initiated as soon as possible. Necrotic soft tissue was removed, and the NanoBone block was leveled with the soft tissue using a high-speed bur. The area was immediately and thoroughly irrigated with chlorhexidine. Patients were prescribed an additional week of oral antibiotics and instructed to apply chlorhexidine gel over the affected area twice a day, as well as to refrain from chewing on the grafted site until mucosal healing was complete.

– Group B: No intra-operative complications were present during the allograft augmentation. In addition, no post-operative complications were present after the ridge augmentation or at the time of the implant surgery, except for one case of infection (Figs. 8a & b).

– Both groups: The regenerated ridges healed uneventfully and no evidence of serious adverse local reactions, that is, foreign-body reaction, pain, dysaesthesia, inflammation was observed in any patient throughout the study.

### Bone-gain clinical measurements

Analytical data regarding the increase in alveolar bone height and width was obtained before and after ridge augmentation and at the time of implant place-

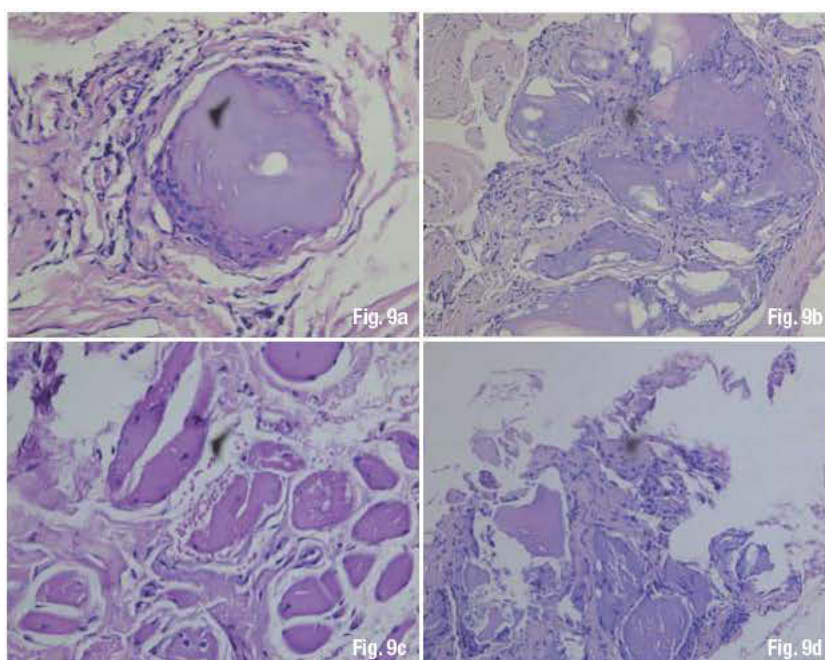
ment. The mean and standard deviation of the augmentation volume obtained were calculated (Table 1 & Fig. 12).

In group A, the amount of bone height gained was  $2.25 \pm 1.31$  mm ( $P < 0.001$ ) and bone-width gain was  $2.3 \pm 1.49$  mm ( $P < 0.002$ ), while the amount of bone height gained was  $0.75 \pm 0.97$  mm ( $P < 0.001$ ) and bone-width gain was  $0.45 \pm 0.55$  mm ( $P < 0.002$ ) in group B. In group A, the amount of bone-height loss was  $2.75 \pm 1.31$  mm ( $P < 0.024$ ) and bone-width loss was  $2.9 \pm 1.88$  mm ( $P < 0.037$ ), while the amount of bone-height loss was  $4.05 \pm 1.01$  mm ( $P < 0.024$ ) and bone-width loss was  $4.4 \pm 0.93$  mm ( $P < 0.037$ ) in group B.

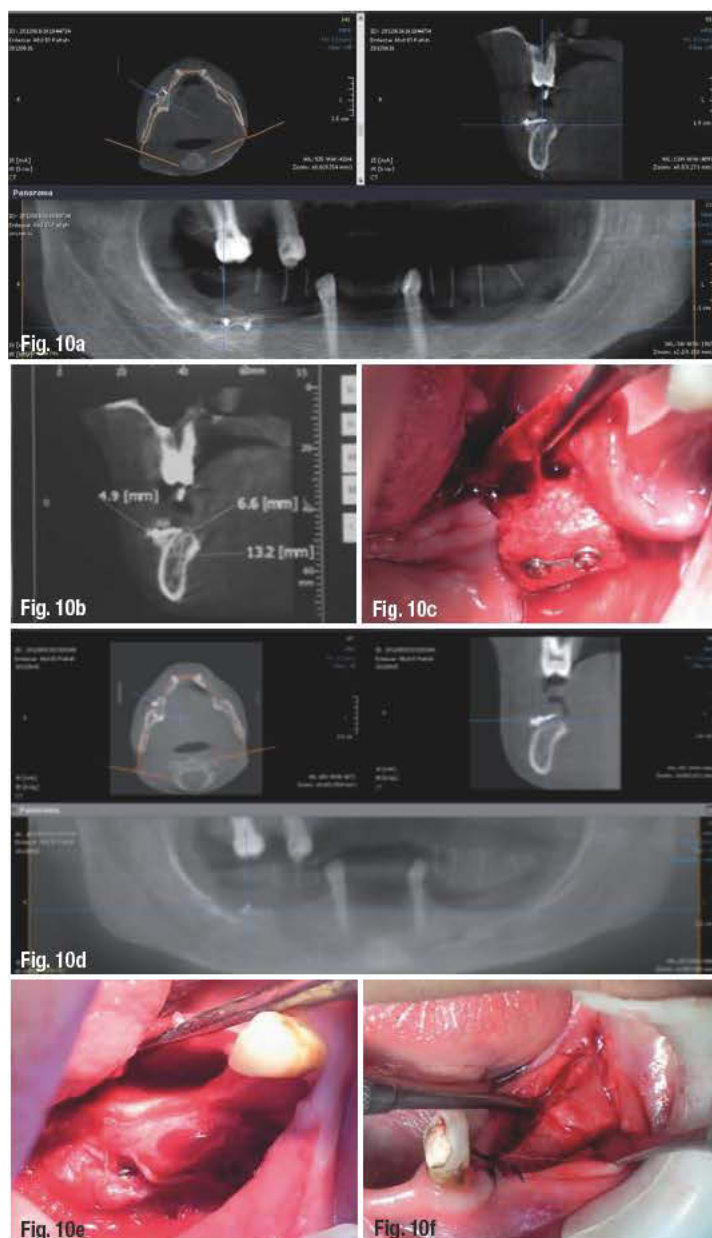
### CBCT evaluation (Figs. 10a, b & d)

It was surprising that Nanobone density was greater in group A after grafting. This was because of the presence of mineral in NanoBone, which acts as a scaffold, degrading progressively and being replaced by new bone. The new bone is premature with a low mineral density and is therefore not radiopaque after six months.

**Figs. 9a–d** Histological evaluation.







**Fig. 10a** CBCT immediately after ridge augmentation (Nanobone on the right side and Fisiograft on the left side)

**Fig. 10b** measurements of CBCT immediately after Nanobone ridge augmentation.

**Fig. 10c** Clinical view of Nanobone block fixation during augmentation procedures.

**Fig. 10d** CBCT six months after ridge augmentation (Nanobone in Rt side and Fisiograft in Lt side; NB. Nanobone graft not appears radiopaque in CBCT cross section).

**Fig. 10e** Clinical view of Nanobone graft six months after augmentation (at the time of implant placement).

**Fig. 10f** Clinical view of Fisiograft six months after augmentation (at the time of implant placement).

By comparing CBCT scans before and six months after the augmentation procedures (Figs. 10a, b & d), it was found that CBCT is not a suitable means of evaluation for ridge augmentation with either NanoBone or allograft bone blocks.

#### Histological results

Histological evaluation showed rapid incorporation of the NanoBone block graft at six months, as ev-

idenced by newly formed bone containing viable osteocytes.

## Discussion

Reconstruction of the posterior mandible is challenging since deficiency in bone and mucosa is required due to the deformity.<sup>27</sup> Unlike the maxillary sinuses, the alveolar ridge does not provide a natural cavity to contain particulate grafting material.<sup>28</sup> Therefore, the graft must have sufficient strength and rigidity to attach to the recipient site and 3-D stability to withstand muscular forces.<sup>29</sup> The availability of autogenous bone block grafts from intra-oral sites is often a limitation in treatment possibilities.<sup>30</sup> Among the alternatives to autogenous bone blocks are the synthetic NanoBone and allograft bone blocks. Studies have reported that allograft fresh-frozen bone may provide results equivalent to those achieved with autogenous bone grafts.<sup>30-33</sup> Currently, however, only insufficient evidence is available regarding treatment efficacy of allograft bone blocks, for example volumetric changes and remodelling/incorporation within the host bone, and the long-term survival rates of subsequently inserted implants,<sup>30</sup> and few studies have been conducted on the innovative NanoBone block.<sup>23</sup> The success of grafting procedures highly depends on primary soft-tissue closure, which warrants healing by primary intention and entails only marginal soft-tissue collagen formation and remodelling. In addition, it reduces postoperative discomfort and provides a significant step in predictable bone regeneration. Incision line opening is the most frequent postoperative complication in the initial healing phase of intraoral bone grafting.<sup>34</sup> It results in contamination or loss of the graft as well as a delay or abolition of the vascularisation and may halt bone growth.<sup>35</sup> The high frequency of incision line opening in bone block grafting is caused by the strain on the overlying tissue, which must cover larger quantities of bone. Furthermore, the local growth factor of the soft tissue is low under the reflected flaps which are positioned over a graft material or barrier membrane and not on the host bone.<sup>36</sup> In the present study, we used Kazanjian's vestibuloplasty instead of a crestal flap. Whether to make crestal or vestibular incisions during bone-block augmentation depends on the following factors. Vestibular incisions may be more advantageous than crestal incision because of better protection of the underlying grafted bone.<sup>22</sup> They are also claimed to increase the blood supply to the lingual flap from the floor of the mouth. In addition, the lingual flap is not completely dissected from the inner aspect of the mandible and helps maintain the vestibule. This decreases muscle tension, preventing movement on both sides of the wound, which prevents wound dehiscence and incision line opening.





# I AM A FAN

like most of my colleagues.

Dr. Leyli Behfar | Specialist in Oral Surgery

CAMLOG is my first choice when it comes to dental implants. With their high-precision implant systems, I find an answer for every indication. Implantations can be performed easily, efficiently and with excellent quality standards. CAMLOG is an inspiring partner in many ways – and that is getting around. [www.camlog.com](http://www.camlog.com)

a perfect fit™

camlog