

# DENTAL TRIBUNE

— The World's Dental Newspaper · Middle East & Africa Edition —

PUBLISHED IN DUBAI

March 2011

No. 3 VOL. 9



## News & Opinions

Coffee may cut stroke risk in women

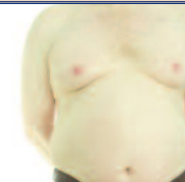▶ Page 4



## Media CME

Maintenance of periodontally compromised teeth

▶ Page 6



## Dental Cafe

Sharp rise in man Boob Surgery

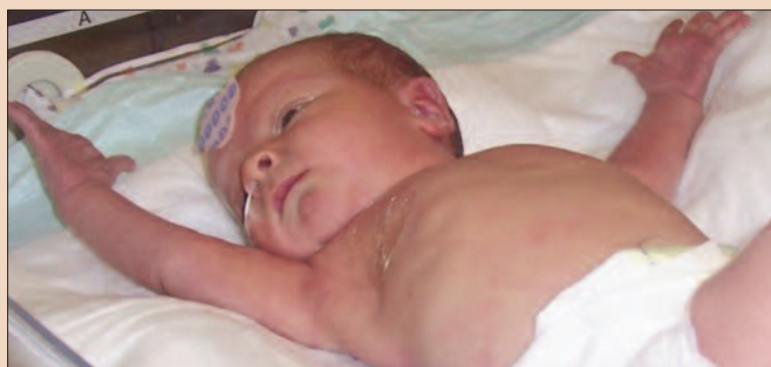▶ Page 11

## FDA: Migraine drug ups risk for oral birth defects

Johnson & Johnson's Topamax, are about 20 times more likely to have their infants develop cleft palate deformities than those who are not treated.

An epilepsy drug also used to help prevent migraines can increase the risk for oral birth defects in babies born to women taking the medication. The Food and Drug Administration said new data shows expecting mothers taking the drug, sold generically and as Johnson & Johnson's Topamax, are about 20 times more likely to have their infants develop cleft lips or cleft palate deformities than those who are not treated.

Officials called on doctors to warn their female patients of childbearing age who are taking the medicine about its risks since the defects occur in the first three months of pregnancy, before women may know they are expecting. FDA's Russell Katz, who heads the agency's Division of Neurology Products, said doctors should think carefully before prescribing the drug to women of childbearing age and "alternative medications that have a



lower risk of birth defects should be considered." The conditions can lead to multiple development issues because they can make it nearly impossible for babies to get adequate nutrition. They can be corrected with surgery, although sometimes several operations are needed.

The data showed cleft lips or palates occurred in 1.4 percent of babies exposed to Topamax or generic rivals compared to between 0.38 percent and 0.55 percent in infants whose mothers took other drugs for epilepsy, FDA said. The defect occurs in about 0.07 percent of infants whose mothers are not on any such medication.

In a statement, J&J said Topamax's label already notes the risks with pregnancy and "recommended cautious use in pregnant patients." It said it would work with the FDA to clarify the drug's use during pregnancy.

Topamax is expected to bring \$569 million in worldwide revenue for the diversified drug-maker in 2010, according to Thomson Reuters data. At its peak, the drug took in more than \$2.7 billion in 2008, before rivals arrived in 2009.

FDA issued the warning based on data collected from the North American Antiepileptic Drug Pregnancy Registry. [D](#)

## Dentists at risk for hearing loss

Everyone knows there are certain jobs that carry a risk for loss of hearing. Rock musicians come immediately to mind. So do construction workers who use jackhammers. And don't forget the people who use those yellow flashlights to direct planes at airports. According to a recent study, dentists can also consider themselves among those at risk for ear trouble.

Most individuals would not consider a dental office to be a

place where noise is a problem, but the federal Occupational Safety and Health Administration (OSHA) warns

that any workers exposed to noise levels in excess of 85 decibels are at risk.

The exposure to continuous high frequencies from a dental drill can degrade one's hearing. According to the experts, dental

→ [D](#) page 5



AD

## PROMEDICA

Highest quality made in Germany

- ▶ high quality glass ionomer cements
- ▶ first class composites
- ▶ innovative compomers
- ▶ modern bonding systems
- ▶ materials for long-term prophylaxis
- ▶ temporary solutions
- ▶ bleaching products...

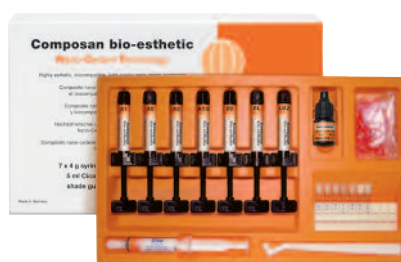All our products convince by

- ▶ excellent physical properties
- ▶ perfect aesthetical results

Meet us at  
several exhibitions -  
[www.promedica.de](http://www.promedica.de)

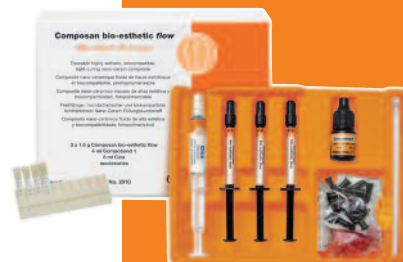

**Temporary crown and bridge material**  
• particular fracture and wear resistance  
• now available in 6 attractive shades

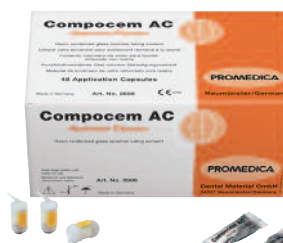

**Light-curing nano-ceram composite**  
• universal for all cavity classes  
• comfortable handling, easy modellation  
• highly esthetic and biocompatible

Nano-Ceram-Technology



• exact match of translucency and shade to the packable Composan bio-esthetic



**Resin-reinforced glass ionomer luting cement**  
• strong adhesion, very low film thickness  
• especially suited for zirconia-based pieces

**PROMEDICA Dental Material GmbH**

Tel. +49 43 21 / 5 41 73 · Fax +49 43 21 / 5 19 08

Internet: <http://www.promedica.de> · eMail: [info@promedica.de](mailto:info@promedica.de)

**PROMEDICA**



# Road accidents leading cause of facial trauma in UAE

The main cause of oral and facial trauma in the UAE is road traffic accidents. Contrary to many parts of the world where the incidence of injury from road traffic accidents has decreased, statistics show that road traffic accidents are still

the main cause of facial trauma. While seat belt use is increasingly prevalent in the UAE, the increase in facial trauma caused by road accidents may be attributed to the size of the car or the speed of the vehicles.

AD

### Editorial Board

Prof. Abdullah Al-Shammary, Restorative Dentistry, KSA  
 Prof. Hussain F. Al Huwaizi, Endodontics, Iraq  
 Prof. Samar Burgan, Oral Medicine, Jordan  
 Dr. Abdel Salam Al Askary, Implantology, Egypt

Dr. Talal Al-Harbi, Orthodontist, Qatar  
 Dr. Mohammed H. Al Jishi, Bahrain  
 Dr. Lara Bakaeen, Prosthodontist, Jordan  
 Dr. Aisha Sultan, Periodontist, UAE  
 Dr. Kamal Balaghi Mobin Aesthetics, Iran

### DENTAL TRIBUNE

The World's Dental Newspaper - Middle East & Africa Edition

### Published by Education Zone

in licence of Dental Tribune International GmbH

© 2011, Dental Tribune International GmbH. All rights reserved.

Dental Tribune makes every effort to report clinical information and manufacturer's product news accurately, but cannot assume responsibility for the validity of product claims, or for typographical errors. The publishers also do not assume responsibility for product names or claims, or statements made by advertisers. Opinions expressed by authors are their own and may not reflect those of Dental Tribune International.

President/CEO

Yasir Allawi  
 y.allawi@dental-tribune.ae

Director mCME:

Dr. D. Mollova  
 info@cappmea.com

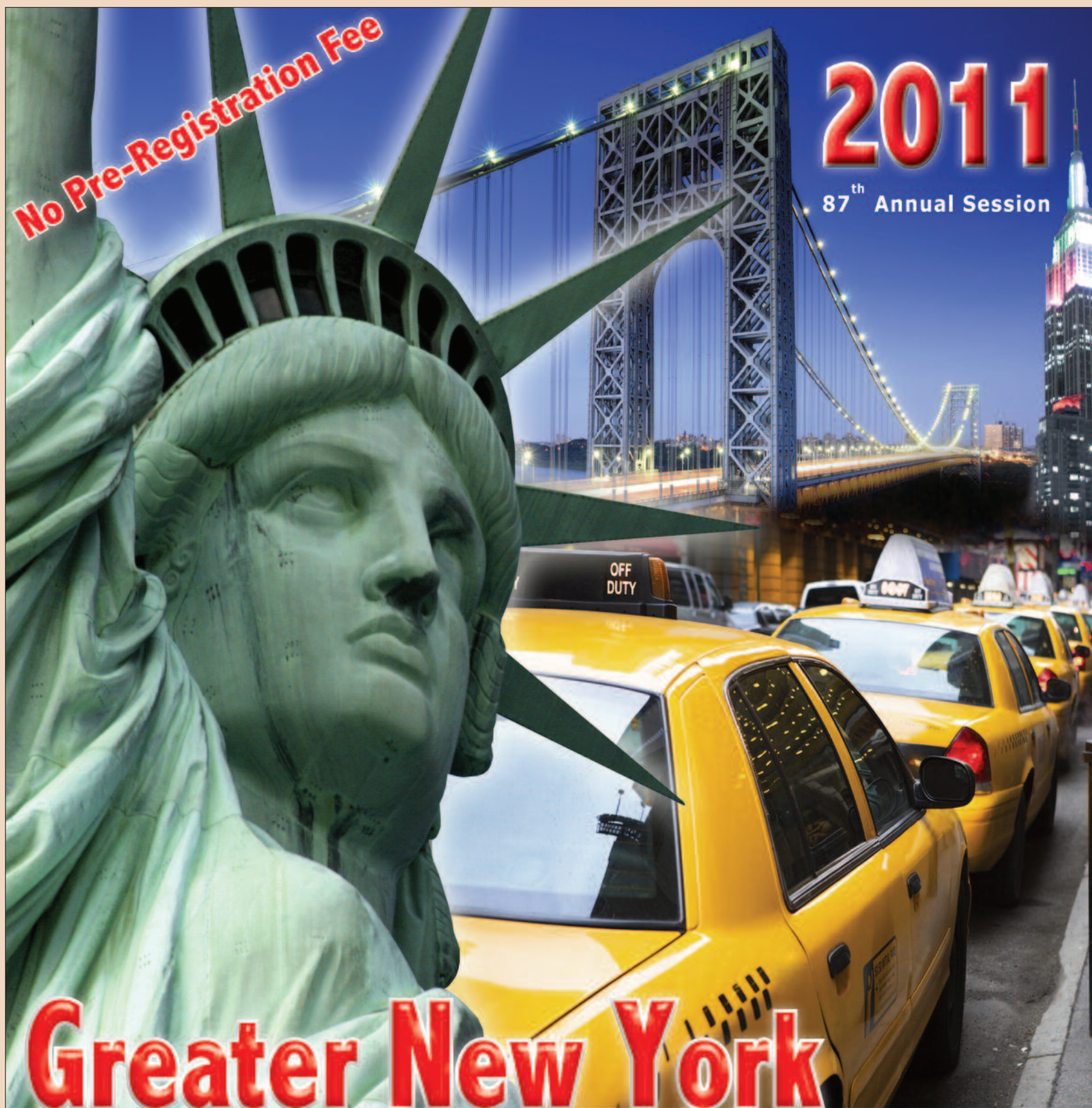
Marketing manager

Khawla Najib  
 khawla@dental-tribune.ae

Production manager

Hussain Alvi  
 dentalme@dental-tribune.ae

PO Box 214592, Dubai, UAE, Tel + 971 4 391 0257  
 Fax + 971 4 366 4512 www.dental-tribune.com



Incidentally, recent improvement in initial resuscitation procedures at the accident site has resulted in more trauma victims being rescued and brought to the hospital for treatment rather than perishing in the accident.

Oral and facial trauma, as well as updates in maxillofacial reconstruction, oral cancer, micro-neurosurgery, facial cosmetic and orthognathic surgery will be reviewed at the 2nd Oral and Maxillofacial Surgery Congress to be held at the Westin Dubai Mina Seyahi hotel in Dubai from 1 - 5 May 2011. Organised by Imedx in association with Arab Health, this year's meeting will provide a number of new features that explore the rapidly reshaping field of oral and maxillofacial surgery.

"A unique type of facial trauma is fall from heights" says Dr Khaled Ghandour, Head of Oral and Maxillofacial Surgery Department, Dubai Health Authority and speaker at the Oral and Maxillofacial Surgery Congress. "Although the figures from trauma caused from falls have gone down considerably since 2008 when construction was booming in the UAE, there are still an alarming number of patients seeking treatment for this type of injury."

"Treatment for facial trauma in the UAE is very advanced and with the high number of surgery cases treated annually, UAE is one of the leading treatment centres in the world," Dr Ghandour explains.

"Dubai's Rashid Hospital, which is one of four specialist trauma treatment centres in the UAE, will treat up to 400 facial trauma patients a year requiring surgery or less invasive emergency treatment."

Other conditions requiring oral and maxillofacial surgery are congenital and birth deformities such as a cleft pallet or cleft lip. This requires secondary and tertiary surgery and many years of intensive treatment to correct the condition. Tumors and oral facial pathology also make up a number of oral surgery cases in the UAE. [1]

Scientific Meeting:  
 Friday, November 25 -  
 Wednesday, November 30



Exhibits:  
 Sunday, November 27 -  
 Wednesday, November 30

The Largest Dental Meeting/Exhibition/Congress in the United States



# New option for missing teeth

For many years, people with chronic dental problems or missing teeth had limited options.

They could continue with the endless cycle and expense of root canals, crowns and other restorations; live with the chewing, speaking and comfort problems often associated with dentures; or pay the extremely high costs of dental implants.

Now Drs. Andrew Spector and Michael Migdal, practitioners in Haworth, N.J., who have long been at the forefront of dental implant technology, are one of a relative handful of dentists throughout the country (and the only ones in the New York metropolitan area) to offer patients the benefits of “permanent teeth” at

about half to one-third the cost of implants, and in a fraction of the time.

Hybridge™ — a hybrid bridge system — is a mix between a conventional fixed bridge and a denture. Unlike a conventional bridge made of metal and porcelain, the system uses a resin and titanium bridge restoration that replaces up to 12 teeth and is supported on five or six dental implants. It is not intended for people requiring single tooth implants, but rather sectional or complete mouth restoration.

The teeth look, feel and function just like healthy, natural teeth and last a lifetime.

As with conventional implants and unlike dentures, they



Dr. Andrew Spector



Dr. Michael Migdal

sit on implants rather than the gum line for greater comfort, allow people to eat and chew as they would with their own teeth, and stimulate the jawbone (thereby preventing the “caved in” look found in people with years of denture wearing).

While a fixed bridge or removable dentures works for cosmetic reasons, and allows the individual to eat and speak clearly, they also pose restrictions — fixed bridges require the filing down of healthy teeth, can weaken adjacent teeth and inhibit maintenance (e.g., you can't floss between them).

Meanwhile, removable dentures can slip, cause embarrassing clicking sounds and lead to bone loss around teeth they are hooked onto.

“The efficiency and precision of the fabrication with the Hybridge system allows us to keep the fee far lower than traditional implant treatment for those patients who need to replace an entire upper or lower archway,” said Spector, who has been at the forefront of dental implants for many years and taught implantology at NYU Dental School.

“While dental implants remain the ‘gold standard’ for patients replacing single teeth, the

cost makes them prohibitive for many who require full mouth or arch restoration, as many older people do.”

Patients for the Hybridge system tend to be older, according to the American Association of Oral and Maxillofacial Surgeons, and by age 74 more than one in four American adults have lost all their permanent teeth.

Yet, Spector said that he has also recommended Hybridge for patients who have lost their teeth as a result of early periodontal disease, traumatic injuries and eating disorders, such as bulimia, which cause tooth decay. **DT**

## Qatar set for new oral health strategy

Qatar's Supreme Council of Health (SCH) is creating a national oral health strategy.

The strategy is expected to be formulated after completing a nationwide survey on oral health among children and teenagers. Dental caries and periodontal diseases are the most prevalent

among schoolchildren and teenagers in the Gulf state.

The study, which will begin in the last quarter of this year, will help improve the existing oral health services and programmes in the country as well as assist to monitor the trends of oral and dental diseases in the country, SCH said. **DT**

## Two hospitals shut down in Riyadh

Two hospitals in the Saudi capital have been temporarily shut down by the Directorate General of Health Affairs due to violations related to equipment and professional staff, Saudi Gazette has reported.

The first hospital was closed down as it did not obtain a final license for operation and employed unlicensed medical staff, while the second facility had a shortage of equipment in a number of departments, the directorate said. **DT**

**DT** Page 1

professionals should use protective hearing devices.

Other professions that carry risk for hearing impairment are aviation, construction and anything that involves the use of firing guns, such as military and law enforcement careers.

According to the National Institute of Deafness, 36 million Americans suffer from hearing loss, and those exposed to loud and high-frequency noises are most at risk.

In most instances, individuals in the workplace do not test their

hearing until after damage occurs. Hearing aid technology can help after damage has already occurred, but professionals recommend hearing protection if working in an environment with exposure to loud sounds.

There are many businesses, such as The Tactical Hearing Co., that offer high-performance digital hearing enhancement and protection.

Tactical Hearing Co. uses the latest advanced technologies and offers affordable hearing devices that can be used in the industries of dentistry as well as construction, aviation, military and law enforcement, target shooting and hunting. **DT**

AD

## „One-for-all“

# ALPRO® BIB forte

High performance disinfection for instruments



**100 l at 1%**  
1 L

**CE 0123**

Aldehyde-free and phenol-free non-protein-fixing cleaning and disinfection of medical and dental instruments, rotating precision instruments and endoscopes.

Approved and recommended by:  
Acurata, Busch & Co., Dentsply Mallefer, Elma, Fujinon Corporation/Japan, Gebr. Brasseler (Komet), Henke-Sass, Wolf, Karl Storz, SS White and VDW.

- ◆ outstanding cleaning power
- ◆ very good material compatibility
- ◆ useful life working solution up to 7 days

**Effective against**

- ◆ bacteria incl. *M. terrae* and MRSA
- ◆ yeastical
- ◆ Viruses (HBV, HCV, HIV), Herpes simplex, Influenza (incl. H1N1, H5N1), BVDV, Vaccinia as well as non-enveloped Polio viruses
- ◆ Meets the CJD-prophylaxis standard according to the recommendation of Robert-Koch-Institute (pH>=10)
- ◆ complies with current German standard (VAH) methods with high organic load and European norms



**ALPRO MEDICAL**  
**Safe.Clean.ALPRO.**

ALPRO MEDICAL GMBH • Mooswiesenstr. 9 • 78112 St. Georgen • Germany  
☎ +49 7725 9392-0 📠 +49 7725 9392-91 🌐 www.alpro-medical.com 📧 info@alpro-medical.com

Instrument disinfection





## Coffee may cut stroke risk in women

More than one cup daily may reduce risk by 25%

Good news for women who like to start the day with a cup of coffee; scientists say it may significantly reduce your chances of having a stroke.

In a study published in the Journal of the American Heart Association (JAMA), Swedish researchers found that women who drank more than a cup of

coffee a day cut their risk of stroke by 22 to 25 per cent.

Stroke is a major cause of early death in the UK, along with heart disease and cancer.

The researchers looked at data from more than 34,000 women aged between 49 to 85 whose health had been tracked for around 10 years.

After taking into account other risk factors, such as smoking status, body mass index, history of diabetes, high blood pressure and alcohol, coffee consumption was linked to a statistically significant reduced risk of different types of stroke.

The benefit of drinking coffee was the same whether the women drank one to two or several cups of coffee each day.

The researchers said people should not change their coffee-drinking habits, but the study should ease the concerns of women.

"Some women have avoided consuming coffee because they have thought it is unhealthy," said study leader Dr Susanna Larson from the Karolinska Institute.

"In fact, increasing evidence indicates that moderate coffee consumption may decrease the risk of some diseases such as diabetes, liver cancer and possibly stroke."

She also said that drinking coffee may cut the risk of stroke by reducing inflammation and oxidative stress and improving insulin sensitivity.

Dr Sharlin Ahmed, research liaison officer at The Stroke Association, said; "We have known for some time that antioxidants found in certain foods and drink, including coffee, could help to reduce a person's stroke risk. This research provides further support to this theory.

"However, it's important to note that caffeine intake can also contribute to high blood pressure, the single biggest risk factor for stroke. We therefore recommend moderate to low-level consumption of coffee as part of a healthy balanced diet combined with regular exercise to help reduce your overall stroke risk." □

## Device lets patients rest from dental drill

Noise-cancelling technology could soon be available in dental practices. Clinicians from the Kings College in London in the UK said to have invented a device that blocks out the shrill sound generated by air turbines in modern dental handpieces, a main cause for anxiety among patients. □

# Dentalcare

## International Dental and Laboratory Equipment Exhibition

**14 - 16 April 2011**  
**Damascus Fairground, Syria**

**Book your space NOW**  
 to ensure a prime location!  
 Limited spaces available.

Call us on  
**+963 11 44 33 444**



arabian group  
 FOR EXHIBITIONS  
 AND CONFERENCES  
 المجموعة العربية  
 للمعارض والمؤتمرات

P.O. Box 2683  
 Damascus - Syria  
 T +963 11 4433444  
 F +963 11 4433666

arabiangroup@net.sy  
 www.arabiangroup.com  
 www.dentalcaresyria.com



# Protein Could Improve Dental Implants

Using a bone-creating protein to augment the maxillary sinus could improve dental implant success, according to Georgia Health Sciences University researchers.

Dental implants, screws that anchor permanent prosthetic teeth, won't work if the bone in which they are anchored is too thin. Bone-thinning is a common cause and consequence following tooth loss. The current favored solution is to supplement the area with bone grafts to stabilize the implant base. But that technique is problematic "primarily because it involves additional surgeries to harvest the bone," said Dr. Ulf M.E. Wikesjö, Interim Associate Dean for Research and Enterprise in the GHSU College of Dental Medicine.

In animal studies, he and his team at the GHSU Laboratory for Applied Periodontal & Craniofacial Regeneration found that im-

planting bone morphogenetic protein in the sinus more new bone will form within four weeks than using conventional bone grafting at the same site.

"We found that BMP induced superior bone quality over that following bone grafts, which improves the chances for successful

implants," Wikesjö said. "BMP is phenomenal, because it's a true, off-the-shelf product with ease of use that can produce real results, and it could be the new gold standard for this procedure."

According to the American Association of Oral and Maxillofacial Surgeons, 69 percent of

adults ages 35-44 have lost at least one tooth due to decay, disease or trauma, and 26 percent of adults have lost all permanent teeth by age 74. Before dental implants were available, the only options for replacing these missing teeth were dentures and dental bridges, both of which could lead to further bone loss. Implants provide patients with numerous benefits, including improved oral health, appearance, speech, convenience, durability and ability to eat. [\[1\]](#)



AD

## GSK and DENTSPLY cooperate in oral health

Daniel Zimmermann  
DTI

LONDON, UK/NEW YORK, USA/LEIPZIG, Germany: DENTSPLY has entered into a co-branding agreement with GlaxoSmithKline, a global health-care manufacturer based in the UK. According to a press note released in January, the deal will allow the US company to combine its NUPRO in-office prophylaxis range with Sensodyne, GSK's specialist toothpaste brand for patients suffering from dentine hypersensitivity. According to the companies, no exchange of cash or equity by either party is involved in the agreement.

NUPRO, which consists of prophylaxis and polishing pastes, is based on NovaMin, a technology acquired by GSK through a multi-million dollar purchase in 2009. The formula contains calcium sodium phosphosilicate, a synthetic mineral found to seal dentinal tubules, the main reason for hypersensitive teeth. GSK currently uses the same technology in its heavily marketed Sensodyne toothpaste brand.

Carlton Lawson, Vice-President of Sensodyne, GSK, said that by utilising both companies' brands and capabilities, his company aims to build awareness of the benefits of NovaMin and further consolidate its position as the leader in the over-the-counter oral health-care market.

According to the company, 90 per cent of its worldwide revenue is earned through toothpaste sales. The company also claims to have a global market share of almost 10 per cent. [\[1\]](#)



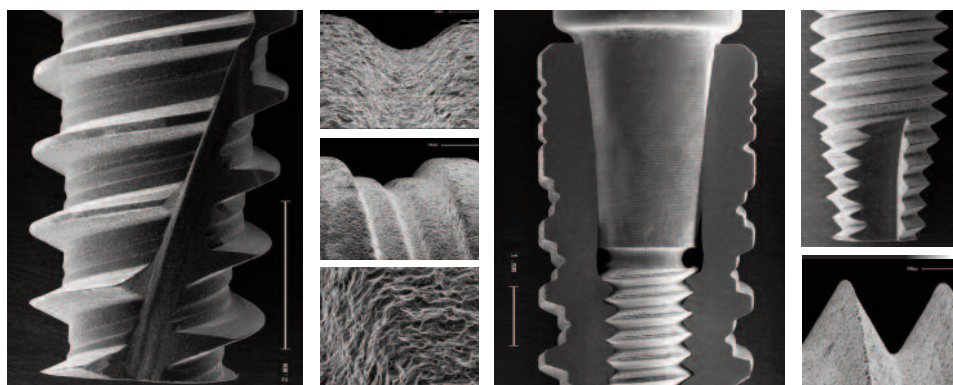
**DENTOFLEX**®

Implant System

*For more than 30 years, Dentoflex has been creating healthy and attractive smiles in Brazil, and is now growing all over the world.*

Dentoflex has been operating in the dental market for over three decades and doesn't stop reinventing itself. The company is moving in the right direction by aiming to develop on a daily basis, invest in the latest technology and expand into new horizons. Dentoflex has an ambition to break down and overcome any barriers and form strong relationships and alliances in countries worldwide.

## Treatment Surface



The Dentoflex's surface treatments includes aluminum oxide blasting, followed by acid passivation which combines texture and perfect porosity for an excellent biological effect, and as a result giving conditions for osseointegration and clinical success. The Dentoflex implants offer a more rougher surface of up to 300 times greater than a machined surface, stabilising bone-implant contact by up to six times.



BRANCH OFICCE: JAFZA VIEW - LOB 19 OFFICE 1301 - P.O. BOX 261901 - DUBAI - U.A.E  
TEL: +971 (0) 48855404 EXT: 304/305 - FAX: +971 (0) 48855405 MOB: +971 (0) 559250844  
[comex@dentoflex.com.br](mailto:comex@dentoflex.com.br) [www.dentoflex.com.br](http://www.dentoflex.com.br)





# Papillary squamous cell carcinoma of the hard palate

*Report of a rare case affecting the oral cavity*

(mCME articles in Dental Tribune (always page 6) has been approved by HAAD as having educational content acceptable for (Category 1) CME credit hours. Term of approval covers issues published within one year from the distribution date (September, 2010). This (Volume/Issue) has been approved by HAAD for 2 CME credit hours.

By Paul C. Lee, BA; Justin Olsen, BS; Joshua Adcox, BS and Parish P. Sedghizadeh, DDS, MS

Approximately one in three Americans will develop a malignancy in their lifetime.<sup>1</sup> The chances of developing certain malignancies increase with age and several contributing risk factors such as tobacco and alcohol use. Notwithstanding significant decreases in death rates from heart disease, cerebrovascular disease and infections over the previous 50 years for many forms of cancer, death rates remain essentially unchanged during that same time period.<sup>1</sup>

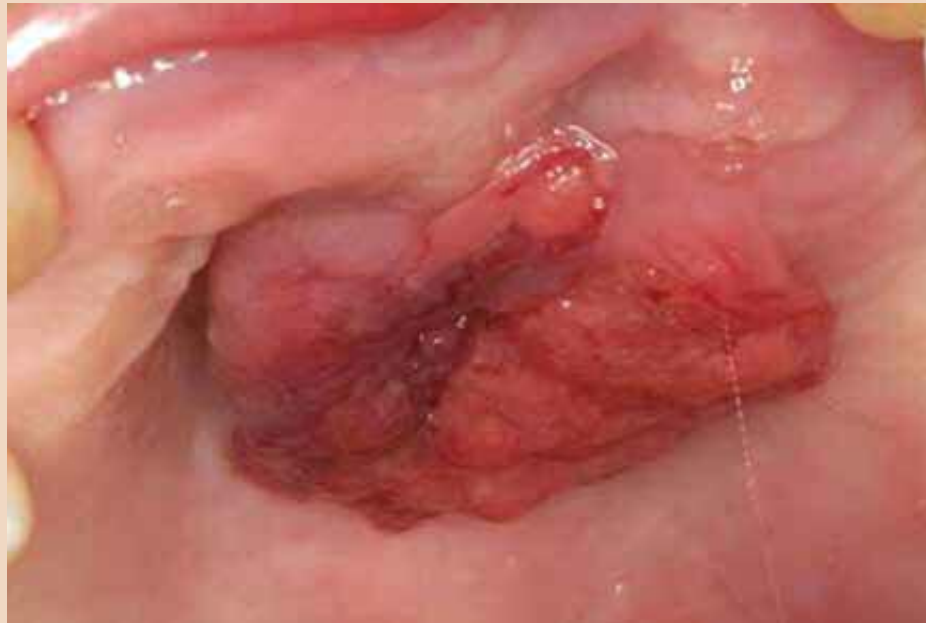Squamous cell carcinoma (SCC) is the most common malignant neoplasm affecting the head and neck. Mucosal cases account for more than 90 percent of all malignant neoplasms affecting oropharyngeal structures, with oral squamous cell carcinoma (OSCC) being the most common oral malignancy.<sup>2</sup>

Several variants of OSCC exist and histopathologic classifications for variants of OSCC include papillary, spindle cell, adenosquamous, and basaloid carcinoma; it is also possible to categorize types of OSCC based on clinical descriptors such as ulcerative, flat, polypoid and verrucoid.<sup>2</sup> OSCC variants can have different growth patterns, ranging from small mucosal thickenings to large masses, and can appear endophytic or exophytic.

These tumors are erythematous to white to tan, frequently feeling firm on palpation. Conventional OSCC is composed of variable degrees of squamous differentiation, with well-differentiated cells closely recapitulating normal squamous epithelium but demonstrating some degree of basement membrane violation by nests of tumor cells, to poorly differentiated cells with more anaplastic-like appearances.

As a result of its complex exophytic papillary architecture, the papillary variant of SCC can be a challenge to accurately diagnose and histologic assessment of underlying invasion can be very difficult.<sup>5</sup> Risk factors and pathogenesis for papillary SCC are unclear although human papilloma virus subtypes are thought to play a role in some cases.<sup>5</sup>

The purpose of this paper is to (a) present a rare case of papillary OSCC affecting the hard palate, and (b) describe the clinical and histologic features of this tumor in supporting the dentist's role in early detection.



*Fig. 1: Clinical image of the palate of a 63-year-old female showing an erythematous exophytic mass with a cauliflower-like or papillary surface architecture. (Photos/Provided by Paul Lee)*

## Case report

A 63-year-old female presented to the dental clinic at the Herman Ostrow School of Dentistry, University of Southern California with the chief complaint of a growth appearing on the roof of her mouth approximately two months prior to her presentation to our clinic. The patient's past medical history included type II diabetes mellitus controlled with

diet and exercise, and denial of any alcohol or tobacco use.

The remainder of her medical and social history was non-contributory; she was not taking any medications and a review of systems was unremarkable. Intraoral examination revealed a 3.5 cm exophytic mass in the anterior midline region of the hard palate (Fig. 1). The lesion appeared vascularized with

ill-defined borders and no evidence of ulceration or erosion.

The patient had mild sensitivity upon palpation of the lesion. No cervical or submandibular lymphadenopathy was observed during the extraoral examination of the head and neck. Panoramic radiography revealed no abnormalities of the palatal area.

The patient was informed that a biopsy must be taken to obtain a definitive diagnosis; informed consent was obtained for incisional biopsy with local anesthesia. During the administration of local anesthesia, the cortical bone under the tumor felt intact with the end of the needle. A representative wedge of tissue was removed and placed in 10 percent formalin for microscopic evaluation.

The biopsy site was cauterized to obtain postoperative hemostasis due to the high degree of vascularity. The biopsy site was closed with four 3.0 chromic gut interrupted sutures. Hemostasis was achieved, postoperative instructions were given and the patient's postoperative condition was good.

The gross examination of the specimen consisted of a soft, tan papillary and friable mass. The his-

## MEDIA CME Self-Instruction Program

Dental Tribune Middle East & Africa in collaboration with CAPP introduce to the market the new project mCME - Self Instruction Program.

mCME gives you the opportunity to have a quick and easy way to meet your continuing education needs. mCME offers you the flexibility to work at your own pace through the material from any location at any time. The content is international, drawn from the upper echelon of dental medicine, but also presents a regional outlook in terms of perspective and subject matter.

### How can professionals enroll?

They can either sign up for a one-year (10 exercises) by subscription for the magazine for one year (\$65) or pay (\$20) per article. After the payment, participants will receive their membership number and will be able to attend to the program.

### How to earn CME credits?

Once the reader attends the distance-learning program, he/she can earn credits in three easy steps:

1. Read the articles.
2. Take the exercises
3. Fill in the Questionnaire and Submit the answers by Fax (+971 4 36868883) or Email :[info@cappmea.com](mailto:info@cappmea.com)

After submission of the answers, (name and membership number must be included for processing) they will receive the Certificate with unique ID Number within 48 to 72hours.

Articles and Questionnaires will be available in the website after the publication.

[www.cappmea.com](http://www.cappmea.com)



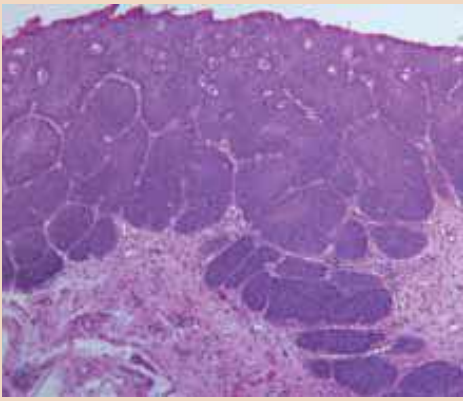


Fig. 2: Histopathologic evaluation demonstrates abnormal mucosa with a micropapillary surface morphology and marked maturational perturbations in association with acute and chronic inflammatory cells (H&E, 20x original magnification).

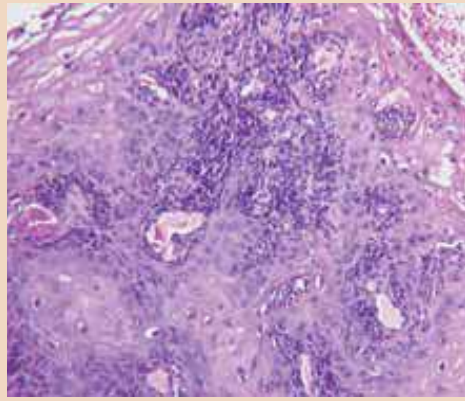


Fig. 3: Histopathologic evaluation reveals invasive islands and cords of malignant epithelium in addition to dyskeratosis and early keratin pearl formation (H&E, 20x original magnification).

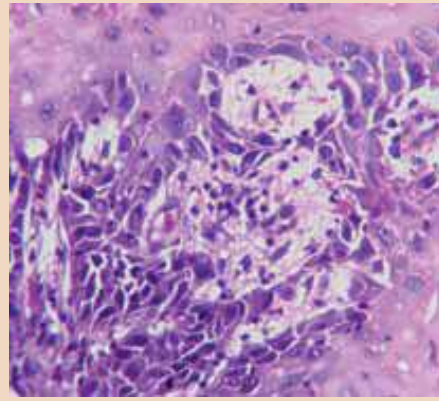


Fig. 4: Histopathologic evaluation of invasive cords of mucosa at high power magnification shows cellular and nuclear pleomorphism, hyperchromatism, acantholysis, dyskeratosis, prominent nucleoli and increased nuclear-to-cytoplasmic ratios (H&E, 40x original magnification).

topathologic evaluation revealed an exophytic, papillary proliferation of surface mucosa showing marked maturational perturbations. It included cellular and nuclear pleomorphism, prominent nucleoli, hyperchromatism, acantholysis, increased mitotic activity and abnormal mitotic figures, dyskeratosis and keratin pearls, and increased nuclear-to-cytoplasmic ratios.

Invasive cords and islands of malignant mucosa were visualized and the associated connective tissue contained an influx of acute and chronic inflammatory cells. To evaluate whether the inflammatory infiltrates observed in the cancerous tissue were in response to superimposed fungal infection (because organisms such as *Candida albicans* are common oral inhabitants), periodic-acid Schiff staining was conducted and determined to be negative with appropriate staining of control tissue.

The patient was referred to the head and neck oncology group at the University of Southern California, Los Angeles County Hospital and Keck School of Medicine. Clinical work-up for staging was performed and computerized tomography scans of the head, neck and chest were determined to be negative for metastatic disease; the lesion was staged at T2N0M0.

The patient underwent tumor resection with 1 cm margins and suprahyoid neck dissection, with no radiation or chemotherapy. Her postoperative course was uneventful, and histopathologic analysis confirmed a diagnosis of papillary OSCC.

The dissected lymph nodes showed no metastatic involvement, confirming that the surgical margins were tumor free. There was no clinical evidence of recurrence at 6-months follow-up.

#### Discussion

The typical presentation for OSCC can be either a symptomatic or asymptomatic mucosal ulcer. These superficial ulcers often progress into symptomatic or asymptomatic exophytic or endophytic nodules with eroded or ulcerated surfaces, and can progress to direct invasion of the deeper structures resulting in a firm,

non-movable mass.<sup>1</sup>

However, OSCC often begin as white or red plaques of surface mucosa, making early clinical detection possible. If a leukoplakic or erythroplakic lesion appears in the oral cavity and does not heal within a few weeks, biopsy is recommended for definitive diagnosis, which may represent levels of histologically normal tissue (e.g., keratosis) to atypia, dysplasia, carcinoma in situ or overt carcinoma.<sup>1</sup>

Papillary OSCC, such as the case presented here, is a variant of SCC as classified by the World Health Organization<sup>4</sup> and can present as either in situ or invasive lesions.<sup>5</sup> Male predominance exists in OSCC cases, and the sites most commonly affected in order of prevalence are the larynx, nasal cavity and oral cavity.<sup>2,5</sup>

The clinical appearance of papillary OSCC often mimics other variants such as verrucous carcinoma, which is included in a differential diagnosis until confirmation with microscopic examination and diagnosis.<sup>5</sup>

Microscopically, OSCC can show invasive and disorganized growth with the following: dyskeratosis, keratin pearls and intercellular bridges, increased nuclear-to-cytoplasmic ratios, nuclear chromatin irregularities, prominent eosinophilic nucleoli and increased mitotic figures with atypical formation. Perineural invasion can be seen in some lesions, presenting a positive correlation to metastatic potential.<sup>1</sup> In this case presentation, many of the aforementioned microscopic features of OSCC were evident without evidence of perineural invasion.

Early detection of OSCC, specifically stage I or II diagnosis, is usually associated with a favorable prognosis. Papillary OSCC in general has a 70 percent, five-year survival rate at any stage, and at T1 it carries a 100 percent survival rate<sup>6</sup> compared to other variants, such as basaloid (40 percent, two-year survival), adenosquamous (55 percent, two-year survival), and spindle cell (80 percent, five-year) carcinomas.<sup>2</sup> Most reported cases of papillary SCC exhibit a mean diameter of 1 to 1.5 cm<sup>2</sup>. Our patient presented with a relatively large lesion measuring

over 5 cm in diameter.

Dentists have a critical role in early identification of and effective care during OSCC progression from premalignant lesion to malignancy.<sup>7</sup> A study conducted to evaluate the effectiveness of dentists in the early detection, treatment and post-operative care of OSCC in a central European population revealed the following results: Dentists identified 72.5 percent of the tumors in the 608 patients they saw as malignant, while family physicians did

so in only 40.11 percent of their 406 patients. This difference was statistically significant ( $P < .001$ ).<sup>8</sup>

OSCC is a major public health problem that is not just limited to certain risk groups, such as those who smoke and drink as in this case report. Early detection and identification of OSCC is critical to patient treatment and survival. **□**

A complete list of references is available from the publisher

#### About the authors

Paul C. Lee, BA; Justin Olsen, BS; and Joshua Adcox, BS, are dental students at the Herman Ostrow School of Dentistry of USC, University of Southern California, Los Angeles. Parish P. Sedghizadeh, DDS, MS, is an assistant professor at the Herman Ostrow School of Dentistry of USC, University of Southern California, Los Angeles.

For correspondence:

Paul C. Lee  
925 West 34th Street, DEN 4110  
University of Southern California,  
School of Dentistry  
Los Angeles, Calif. 90089-0641  
E-mail: [chong.lee@usc.edu](mailto:chong.lee@usc.edu)

Accredited by Health Authority - Abu Dhabi

For more information: e-mail: [info@dental-tribune.ae](mailto:info@dental-tribune.ae),

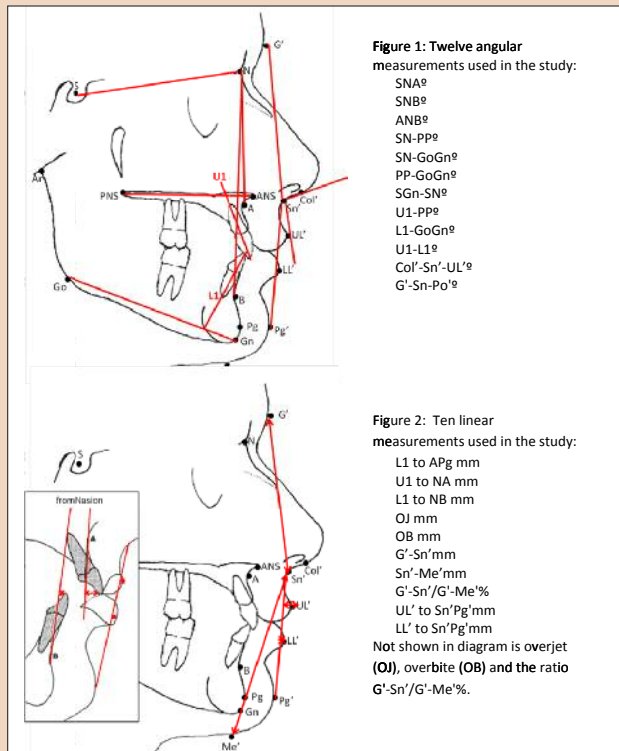
Tel: + 971 4 391 0257, Fax: + 971 4 366 4512 Mob: + 971 50 6625011



# Cephalometric Norms in an Adult Emirati Population with Class I Malocclusion

By: Tayseer Al Zain, DDS, MSD, and Donald J. Ferguson, DMD, MSD

Lateral cephalometric radiographs, are an important tool for orthodontic analysis in diagnosis, treatment planning and the monitoring of craniofacial growth. Cephalometric analysis supports the clinical examination and helps to identify the source of the problems in skeletal and/or dental relationships. Dentofacial problems are identified and the magnitude of problem is acknowledged, in part, by comparing patient cephalometric values to a standard or normal data base. Two well known and commonly used Caucasian normal data bases for comparison are from the Steiner (1952) and Eastman (MacAllister 1992) samples based upon Class I normal faces and occlusions. It is also essential to compare patients with different malocclusions to their specific population norms (Moyers 1988). Knowledge of the normal dentofacial patterns of adults belonging to var-



Measurement	Males (n=30)		Females (n=31)		T value	P value
	mean	SD	mean	SD		
SNA°	82.5	5.05	80.8	5.64	1.24	.221
SNB°	79.6	3.90	77.6	4.82	1.78	.080
ANB°	3.0	3.11	3.3	2.40	-.43	.673
SN-PP°	8.4	3.44	10.7	3.95	-2.43	.018*
SN-GoGn°	33.3	5.37	35.9	7.00	-1.64	.107
PP-GoGn°	24.8	4.57	25.2	7.03	-.22	.829
SGn-SN°	69.0	3.78	71.0	4.61	-1.78	.080
U1-PP°	116.3	5.34	116.3	6.17	.01	.994
L1-GoGn°	100.5	6.32	99.8	7.41	.39	.700
L1 to APg mm	5.8	2.53	5.3	2.98	.76	.450
U1 to NA mm	6.0	3.52	6.2	3.18	-.21	.831
L1 to NB mm	6.7	2.26	6.6	2.96	.04	.972
U1-L1°	118.4	9.45	118.7	10.51	-.15	.885
OJ mm	3.3	2.20	4.3	3.63	-1.34	.185
OB mm	.7	1.92	.8	2.25	-.22	.828
Col'-Sn'-UL°	121.6	11.97	116.4	9.58	1.88	.066
G'-Sn'-Po°	24.7	5.99	23.6	6.09	.67	.507
G'-Sn'mm	65.2	5.23	68.4	12.45	-1.30	.200
Sn'-Me'mm	64.4	6.40	64.7	11.09	-.13	.895
G'-Sn'/G'-Me'%	49.9	3.26	50.8	2.74	-1.16	.252
UL' to Sn'Pg'mm	2.4	1.90	2.8	1.83	-.85	.402
LL' to Sn'Pg'mm	4.0	1.92	4.0	2.64	.06	.956

Table 1: Descriptive normative lateral cephalometric statistics including means and standard deviations (SD) and probability (P) value for male and female subjects with sample size (n) indicated.

harmonious profile (as evidenced on the lateral cephalometric radiograph)  
 Class I molar relationship (as evidenced on the lateral cephalometric radiograph)  
 no history of trauma  
 no history of orthodontic treatment  
 permanent dentition only  
 no multiple missing teeth  
 UAE native (national) only (as evidenced by family name).

## Procedures

Patient files located at Abu Dhabi Dental Center were randomly inspected for the presence of lateral cephalometric radiographs and included in the sample based upon diagnostic quality and the selection criteria. The lateral cephalograms were then scanned into digital format using a 300 DPI scan setting.

Commonly used cephalometric hard and soft tissue landmarks and measurements were utilized in the study resulting in 12 angular (Figure 1) and 10 linear (Figure 2) measurements.

Dolphin Imaging System software package version 9 was used to perform the digital cephalometric analysis comprised of 12 angular (Figure 1) and 9 linear (Figure 2) measurements, and one ratio measurement.

Cephalometric analysis was repeated on five lateral head films in order to test for reliability. Analysis was repeated one and two weeks later on the same five cephalograms and the results of the three testing phases were statistically compared using the Dahlberg reliability formula. Intra-operator error ranged from 0.0 to 0.73 degrees for angular measurements and 0.0 to 0.43 millimeters for linear measurements, no differences were determined ( $p > .05$ ) and intra-operator reliability was deemed satisfactory.

## Statistical Analysis

Data was entered on an Excel spreadsheet then converted to SPSS format for data processing. The Student's t-test was used to determine significant differences between male and female measurement means. Significant differences were determined at the 95% probability level. A difference of 2 degree or 2 millimeters was considered clinically significant.

## RESULTS

The lateral cephalometric radiographs of Emirati nationals with Class I malocclusion were analyzed in order to establish a normative database representing the United Arab Emirates. Lateral cephalometric radiographs of 30 males with average age of 24.52 ± 6.09 years and 31 females averaging 23.57 ± 5.52 years were analyzed.

Twenty-two hard and soft tissue measurements comprised the cephalometric analysis. Only one measurement was determined to be statistically different between genders. The measurement SN-PP was significantly larger in the female group (10.74 ± 3.44 degrees) compared to males (8.43 ± 3.95 degrees,  $p = .018$ ). (Table 1)

ious ethnic and groups is certainly important for clinical purposes, but also research purposes as well.

Many studies related to cephalometric and profile norms have been published for subjects from America, Europe, and Japan, India, Iran, and China. There have also been several cephalometric normative studies focused on subjects from the Middle East including Saudi Arabia, Kuwait, Egypt, Syria, and Jordan. To date, there have been no cephalometric normative studies conducted on subjects from the United Arab Emirates.

Seven cephalometric normative studies that have been conducted based upon Arab subjects. In general, there is a consensus of literature indicating the Arab cephalometric pattern compared to the Caucasian cephalometric pattern is skeletally bimaxillary retrusive, dentally bimaxillary protrusive, more divergent palatal and mandibular planes, with longer anterior face height.

The aim of this study was to clarify the cephalometric features of Emirates adults with Class I malocclusion and to evaluate for gender differences. The null hypothesis tested was no differences in lateral cephalometric measurements as a function of gender.

## METHODS and MATERIALS

### Sample

The sample was selected, with permission, from Abu Dhabi Dental Center located on Abu Dhabi Island. All individuals selected were from a patient record pool representing Emirati nationals seeking orthodontic treatment. Diagnostic quality cephalometric radiographs of 61 subjects were chosen (30 male and 31 female) for evaluation based upon the following selection criteria:

age range between 18 and 35 years at the time of the cephalometric radiograph

AD



www.gIDedental.com

2011  
gIDE/UCLA  
1 YEAR MASTER PROGRAM  
IN ESTHETIC DENTISTRY

**EXPERT FACULTY**  
 DIDIER DIETSCHI, MAURO FRADEANI,  
 DANIEL EDELHOFF, STAVROS PELEKANOS,  
 PANOS BAZOS, ED MCLAREN,  
 SASCHA JOVANOVIC, PASCAL &  
 MICHEL MAGNE, BRIAN LESAGE & OTHERS...



gIDE GLOBAL INSTITUTE  
FOR DENTAL EDUCATION  
www.gidedental.com

**Register & More Information at:**  
**Contact in Athens:**  
 Lito Christophilopoulou  
 Tel.: +30 210 213 2084, +30 210 222 2637  
 E-mail: lito@omnipress.gr, omnipress@omnipress.gr  
 Web: www.omnicongresses.gr

**Contact in the US:**  
 Nena Puga  
 Tel.: +1 310 696 9025  
 E-mail: nena@gidedental.com  
 website: www.gidedental.com

Media Partner: dti

**SPONSORS**  
 ivoclar vivadent, W&H, collène whalldent

**ESTHETIC CURRICULUM**

**Program Chairs:**  
 Dr. Ed McLaren & Dr. Sascha Jovanovic

**Session Chairs:**  
 Dr. Didier Dietschi, Dr. Daniel Edelhoff, Dr. Mauro Fradeani

**SESSION I - FEBRUARY 18 - 21, 2011  
 IN ATHENS, GREECE**

DIRECT RESTORATIONS AND ADHESIVES  
 with DR. DIDIER DIETSCHI and others

**SESSION II - JUNE 24 - 27, 2011  
 IN ATHENS, GREECE**

INDIRECT RESTORATIONS, FULL CERAMIC  
 CROWNS AND VENEERS  
 with DR. DANIEL EDELHOFF and others

**SESSION III - OCTOBER 2 - 5, 2011  
 IN ATHENS, GREECE**

ALL CERAMIC RESTORATIONS AND  
 FIXED PROSTHODONTICS  
 with DR. MAURO FRADEANI & DR. STAVROS PELEKANOS

**SESSION IV - NOVEMBER 28 - DECEMBER 2, 2011  
 IN LOS ANGELES, CALIFORNIA**

GRADUATING WEEK AT UCLA  
 with DR. ED MCLAREN, SASCHA JOVANOVIC, BRIAN LESAGE  
 TODD SCHOENBAUM, PASCAL & MICHEL MAGNE

**PROGRAM FEATURES**

- CLASSROOM EDUCATION
- LIVE PATIENT TREATMENTS
- CASE PRESENTATIONS
- HANDS-ON
- 90 HOURS SELF-STUDY
- 217 HOURS CE
- 2 CERTIFICATES from gIDE and UCLA





DISCUSSION

The results revealed no gender differences between adult Emirati males and females in skeletal or dental relationship except for measurement SN-PP; females (10.7) subjects averaged a 2.5 degrees higher SN-PP measurement compared to males (8.4) subjects.

The cephalometric values from the Emirati study were compared to published Steiner (1952) and Eastman (MacAllister 1992) normative cephalometric values (Table 2). The comparison demonstrated similarity in antero-posterior cephalometric angular measurements with both normative values; no apparent differences were found in angles SNA, SNB, or ANB.

In contrast, measurements of the position of the dentition were dissimilar. Interincisal angle in the Emirati sample averaged 118.6 and was substantially less than the Steiner (127.0) and Eastman (134.0) values. The Emirati sample also had more proclined upper (116.5) incisor position compared to the Eastman value (108.0), and Emirati lower (100.1) incisors was substantially more proclined compared to both the Eastman (91.0) and the Steiner (95.0) values. The dentition was substantially more protrusive in the Emirati sample with U1-NA and L1-NB values more than 2 millimeters more anterior than the Steiner norms; Li-APog value for Emiratis was about 6 millimeters more protrusive than the Eastman value.

The findings of the present study are consistent with other published studies comparing Arab subjects with non-Arab samples. In Saudi samples, Sarhan (1988), Hassan (2005), and Al-Jasser (2003 & 2005) also found greater proclination and protrusion of incisors compared to a Caucasian sample. Behbehani (2006) found Kuwaitis had more proclination and protrusion of mandibular incisors. Handan (2001) found Jordanians 4 to 6 millimeters more protruded relative to A-Pog and described his Jordanian sample as more bi-maxillary protrusive. Bishara (1990) described his Egyptian boys as having a tendency toward bi-maxillary dental protrusion compared with Iowa boys; Egyptian girls had a relatively more convex profile and a tendency toward mandibular dental protrusion.

CONCLUSIONS

A sample of 61 adult Emirati nationals with Class I malocclusion were analyzed in order to establish and Emirati cephalometric norm. The sample was comprised of 30 males and 30 females with a mean age of about 24 years who had presented for orthodontic treatment at one of the two Abu Dhabi national dental centers. Ethnicity was validated based upon family name.

Dolphin Imaging software was used to perform the cephalometric analyses. Only one gender difference was demonstrated out of the 22 cephalometric analysis measurements used in the study; SN-PP mean for females (10.7) subjects averaged a 2.5 degree higher mean value than the males (8.4.) The cephalometric study results were compared to published norms from Steiner and Eastman.

Based upon the conditions of the present study, it may be concluded that adult Emirati males and females seeking orthodontic treatment with Class I malocclusion present similar cephalometric profiles with the exception that measurement SN-PP may be steeper in females than males. Moreover, Emiratis are likely to present greater incisor proclination and protrusion than Caucasians and may be generally considered as more bi-maxillary protrusive.

measurement	Emirati mean (n=61)	Steiner means (n=74)	Eastman mean (n=30)
SNA	81.7	82.0	81.0
SNB	78.6	80.0	78.0
ANB	3.1	2.0	3.0
U1-NA mm	6.1 mm	4mm	
L1-NB mm	6.6 mm	4mm	
SN-GoGn	34.6	31.7	
U1-L1	118.6	127.0	134.0
UJ-PP	116.3		108.0
L1-GoGn	100.1	93.0	91.0
Li-APog mm	5.5		-0.9

Table 2: A comparison of lateral cephalometric values for an Emirati sample with Class I malocclusion with both Steiner and Eastman normative values. Ten measurements are compared and includes means and sample size (n). Note that Emiratis are more bi-maxillary protrusive with incisors proclined and protrusive to a greater extent.

About the author

2005 - BDS,  
Ajman University, Abu Dhabi, UAE  
2010 - MSD in Orthodontics,  
Nicolas & Asp University College,  
Dubai, UAE  
2010 - Specialist Certificate in Orthodontics,  
Malmö University, Sweden



For further information about the article, you may contact Dr. Tayseer on: taalzain@gmail.com

كلية نيقولا وآسب الجامعية  
**NICOLAS & ASP UNIVERSITY COLLEGE**  
Dubai - Abu Dhabi

First Postgraduate Dental Institution in UAE

---

All Programs Accredited by UAE Ministry of Higher Education & Scientific Research

**Register NOW...**

**MASTER DEGREE IN ORTHODONTICS & MALMO UNIVERSITY SPECIALIST DEGREE**  
Full and Part Time

**MASTER DEGREE IN PEDIATRIC DENTISTRY**  
Swedish Recognition in Progress  
Full and Part Time

**NEW**  
**SPECIALITY CERTIFICATE IN ORTHODONTICS**  
Full and Part Time

**NEW**  
**SPECIALITY CERTIFICATE IN PEDIATRIC DENTISTRY**  
Full and Part Time

**MASTER DEGREE IN ENDODONTICS**  
Swedish Recognition in Progress  
Full and Part Time

**DIPLOMA IN ADVANCED EDUCATION IN GENERAL DENTISTRY**  
Fulfill Experience Requirements  
Full Time

**NEW**  
**SPECIALITY CERTIFICATE IN ENDODONTICS**  
Full and Part Time

**HIGH DIPLOMA IN ORAL IMPLANTOLOGY**  
Modular option Available  
Full and Part Time

**Abu Dhabi Headquarters**  
Admission Office:  
Al Nadi Al Seyahi  
Sheikh Omar Bin Zayed Al Nahyan

**Dubai Branch**  
Dubai Healthcare City  
Ibn Sina Building (No. 27)  
Block D, 3rd floor, Office 302  
Telephone: +971 4 3624787

Fax: +971 4 362 4793  
P.O. Box: 53382, Dubai, UAE  
Website: www.dubai-postgraduate.com  
Email: info@dubai-postgraduate.com