

# DENTAL TRIBUNE

—The World's Dental Newspaper • Middle East & Africa Edition—

PRINTED IN DUBAI

www.dental-tribune.me

NOVEMBER-DECEMBER 2013 | NO. 6, VOL. 2

## NEWS

LDA President Elie Azar Maalouf is elected as President of ADF

>Page 24

## MEDIA CME

Clinical indications for a composite-metal PFM restorative

>Page 8

## DIGITAL

Cranmore - Using CBCT 3D for excellence in patient care

>Page 10

## ENDO

FKG presents TotalFill, a revolutionary pre-mixed bioceramic sealer paste

>Page 17

## DTMEA becomes official media partner of LDA



President Elie Azar Maalouf with Mr. Rodny Abdallah, DTMEA, Dr. Walid Khattar, General Secretary LDA (Far left) and Dr. Daniel Kahale LDA board (far right)

By Dental Tribune Middle East

**B**eirut, Lebanon: Dental Tribune Middle East & Africa has become the official media partner of the Lebanese Dental Association. The agreement was signed between LDA President Elie Azar Maalouf and Rodny Abdallah of DTMEA in Lebanon last September 2013.

*"The Dental Tribune combined portfolio includes more than 100 trade publications that reach more than 650,000 dentists in more than 91 countries"*

Founded in 1949, the Lebanese Dental Association (LDA) represents the dentists in Lebanon. Every year, the LDA hosts the Beirut International Dental Meeting (BIDM), presenting the gamut of products and services available for the dental community in Lebanon. LDA recently signed

>Page 18

## BIDM 2013 attracts over 3,000 participants

By Dental Tribune Middle East

**B**eirut, Lebanon: The Lebanese Dental Association successfully held The 23rd Beirut International Dental Meeting (BIDM) 2013 on 25 to 28 September 2013 in conjunction with the 42nd Conference of the Arab Dental Federation in Lebanon.

dent Elie Azar Maalouf said "We are striving to meet all of your ambitions and expectations to reach a profession to be proud of". Several new projects were also launched in order to improve dentistry in Lebanon by the LDA.

The conference proved to be a vital platform for the participants to share their ideas,

In his opening speech, Presi-

>Page 18-19



Opening Ceremony at BIDM 2013

## DENTAL TRIBUNE

—The World's Dental Newspaper • Middle East & Africa Edition—

**Earn 20 CME credit hours per year  
with annual membership in the mCME Program**

**Quick and easy CME points**

- ✓ work at your own pace
- ✓ any location, any time

**Accreditation**  
**ADA CERP** | Continuing Education Recognition Program

For more information on Accredited Professional Practices (APP) is an ADA CERP Recognized Provider. ADA CERP is a service of the American Dental Association to assist dental professionals in identifying quality providers of continuing dental education. ADA CERP does not operate or endorse individual courses or instructors, nor does it imply endorsement of credit hours by the Board of Directors.

**REGISTER** at [www.cappmea.com/mCME/](http://www.cappmea.com/mCME/)

1. **READ** an article in DT

2. **ANSWER** the quiz

3. **SUBMITT** the quiz

Each DT CME article has 2 CME Credit

**Membership:**

- Take **one year membership** by subscribing for the newspaper: **600 AED**
- Take an article with **one newspaper subscription: 100 AED per issue.**

After the payment, you will receive your membership number and will be able to start the program.

**CAPP** FZ LLC | Office 1103 | Fortune Executive Tower | JLT | P.O. Box: 450355 | Dubai, UAE  
T: +971 4 3616174 | F: +971 4 3686883 | M: +971 50 2793711 | E: [events@cappmea.com](mailto:events@cappmea.com)  
[www.cappmea.com](http://www.cappmea.com)



# German quality at a low price: The T4 instrument family from Sirona

By Sirona

Salzburg, Austria: The new T4 product class instruments from Sirona give dentists and especially dental students high German quality that is particularly cost-efficient.

Instruments are an indispensable aspect of dentistry. It is therefore extremely important that dentists can fully rely on them. This is why Sirona now offers the German quality T4 class at a rather low price, making these products particularly interesting for dental students: They can acquire all of the important instruments they need for their studies in a student kit.

“This kit contains reliable and durable products at a very competitive price for students

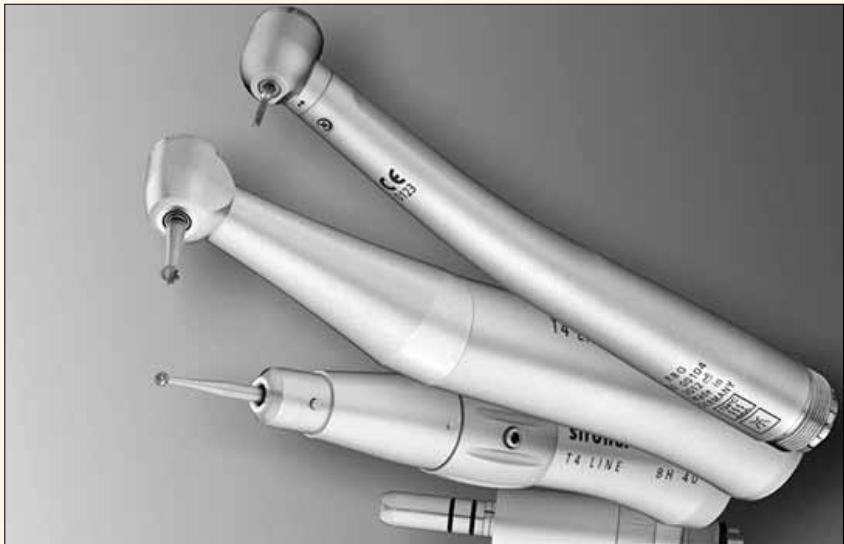or young people who want to set up their own businesses,” said Product Manager Eric Berndt. “The T4 products fulfill Sirona’s high quality requirements in terms of design as well as hygiene and ergonomics.”

In regards to the design and ergonomics of the T4 product line, Sirona has opted for proven quality: The instruments lie perfectly balanced in the dentist’s hand and are ergonomically shaped. The material is both non-slip and easy to clean. The instruments can be sterilized in an autoclave or cleaned and disinfected in a thermodisinfectant. The T4 products include a straight and contra-angle handpiece, the T4 Racer turbine and an air motor. The kit is available either with a Midwest 4-hole or Borden 2-hole connection and can be used

with all common treatment centers.

**T4 Racer turbine:**  
Exceptionally powerful

The T4 Basic turbines are fitted with ceramic ball bearings that are almost vibration-free and hard-wearing. With a pressure of 2.3 bar, they have an output of up to 17 W. The chrome-plated sleeves give the turbines a high-quality appearance. The sleeves of both instruments are made of stainless steel and are top class in terms of appearance and feel. With the handpiece, the so-called single heads for single use can be used for prophylaxis and polishing. **DT**



The T4 student kit contains all of the important instruments and an air motor at a great price.

# APDC

ASIA PACIFIC DENTAL CONGRESS 2014

17-19 June • Dubai, United Arab Emirates

## 36<sup>th</sup> Asia Pacific Dental Congress

17-19 June 2014 • Dubai, United Arab Emirates

*“Improving quality of life through better dental care”*

Organized by:

[www.apdentalcongress.org](http://www.apdentalcongress.org)

### International Imprint

Licensing by Dental Tribune International Group

Editor	Daniel Zimmermann newsroom@dental-tribune.com +49 341 48 474 107
Clinical Editor	Magda Wojtkiewicz
Online Editors	Yvonne Bachmann Claudia Duschek
Copy Editors	Sabrina Raaff Hans Motschmann
Publisher/President/CEO	Torsten Oemus
Director of Finance & Controlling	Dan Wunderlich
Business Development Manager	Claudia Salwiczek
Media Sales Managers	Matthias Diessner (Key Accounts) Melissa Brown (International) Peter Witteczek (Asia Pacific) Maria Kaiser (USA) Weridiana Mageswki (Latin America) Hélène Carpentier (Europe)
Marketing & Sales Services	Esther Wodarski
Accounting	Karen Hamatschek
Executive Producer	Gernot Meyer

Dental Tribune International  
Holbeinstr. 29, 04229 Leipzig, Germany  
Tel: +49 341 4 84 74 302 |  
Fax: +49 341 4 84 74 175  
www.dental-tribune.com  
info@dental-tribune.com

### Regional Offices

Asia Pacific  
Dental Tribune Asia Pacific Limited  
Room A, 20/F, Harvard Commercial Building,  
105-111 Thomson Road, Wanchai, Hong Kong  
Tel: +852 3113 6177 | Fax: +852 3113 6199

The Americas  
Tribune America, LLC  
116 West 23rd Street, Ste. 500, New York,  
N.Y. 10011, USA  
Tel: +1 212 244 7181 | Fax: +1 212 224 7185

### Dental Tribune Middle East & Africa Edition

### Editorial Board

Dr. Aisha Sultan Alsuwaidi, Director of Dental Services, MOH, UAE  
Dr. Nabeel Humood Alsabeeha, Consultant Prosthodontist, MOH, UAE  
Dr. Dobrina Mollova, MDS, UAE  
Dr. Munir Silwadi, Prosthodontist, UAE  
Dr. Khaled Abouseada, Consultant Orthodontist, KSA  
Dr. Rabih Abi Nader, Oral Surgeon and Implantologist, UAE  
Mr. Rodney Abdallah, CDT, Lebanon

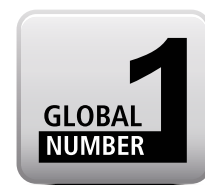CAPP Managing Director	Dr. Dobrina Mollova info@cappmea.com +971 50 42 43072
CAPP Business Development Manager	Tzvetan Deyanov deyanov@dental-tribune.com +971 55 11 28 581

Elegant design and easy handling are a winning combination.



## CEREC OMNICAM

### THE EVOLUTION OF SIMPLICITY



The new CEREC Omnicam combines powder-free ease of handling and natural color reproduction to provide an inspiring treatment experience. Discover the new simplicity of digital dentistry – exemplified by Sirona's premium camera portfolio: CEREC Omnicam and CEREC Bluecam. **Enjoy every day. With Sirona.**

**UNRIVALLED HANDLING ■ POWDER-FREE ■ SCANNING IN NATURAL COLOR**

Contact: SIRONA Dental Systems Ltd · Dr Amro Adel · Building 49, Suite 304  
Dubai Healthcare City · Telephone: + 971 4 375 2355 · E-Mail: amro.adel@sirona.com

**sirona.com**



The Dental Company

**sirona.**



# CPD Dubai to run multidisciplinary day



By Dental Tribune Middle East

**D**ubai, UAE: 29th November, 2013 will see CPD Dubai run a Multidisciplinary Updates Day with professors from the Dubai School of Dental Medicine (DSDM). The day will deliver short, punchy updates and bring together a number of renowned specialists from the fields of Oral Medicine, Orthodontics, Periodontology and Paediatric Dentistry.

The Dean of DSDM, Professor David Wray, will be presenting a lecture on 'Common Oral Medicine Problems Presenting in the Dental Practice'. Professor Wray commented, "Overall the day presents a fantastic opportunity for General Practitioners, specialists and students to hear from academics who specialise in these fields; and to come away with their knowledge refreshed, a better understanding of cases that present in their everyday practices and of the means to manage them."

Professor Wray, formerly President of the British Society of Oral Medicine, continues, "It will also be a fantastic opportunity for dentists practising in the region to meet some of our professors from the Dubai School of Dental Medicine, find out more about what we do here, the types of patients

we treat, who and what to refer. We are very much looking forward to meeting practitioners from the region."

Another of the specialists presenting on the day, Professor Athanasios Athanasiou, a renowned Orthodontist who was President of The World Federation of Orthodontists (W.F.O.) between 2005 and 2010, will be providing a lecture on the 'Diagnoses and Management of Temporomandibular Disorders'. When asked about his upcoming presentation, Professor Athanasiou commented, "There is a lot of misinformation given to dentists on this topic and by dentists to patients. It is an area about which dentists often feel they lack knowledge. I intend to give attendees a comprehensive overview of this range of disorders, the differing causes behind them




Professor Manal El-Halabi



Professor Athanasios E. Athanasiou



Professor David Wray



Professor Crawford Bain

and the evidential base for the different treatment modalities. I am sure attendees will leave feeling more confident about their examination, diagnosis and management of patients suffering Temporomandibular Joint Disorders."

Professor Crawford Bain, a specialist in Periodontics, Prosthodontics and Restorative Dentistry, with more than 30 years of experience, will be presenting 'Non-surgical Periodontics - More than Hygiene Phase Therapy' where amongst other things he will explain why practitioners should be focusing on 'cause related therapy', rather than 'hygiene phase therapy'.

The day will be rounded off by Professor Manal El Halabi, Professor of Paediatric Dentistry, talking about Molar Incisor Hypomineralisation, its causes and management. This is a topic that should be of great importance to dentists in the region where we have such a large school-age demographic. This is a condition that can sometimes be overlooked or misdiagnosed in everyday practice. It is one that practitioners report they are encountering more frequently and for which they are often seeking specialist help. Professor El Halabi's presentation should give attendees an improved understanding of the causes behind this condition, its prevalence and, most importantly, how best to manage affected teeth.

Managing Director of CPD Dubai, Nicolas Bell, said, "We have been extremely fortunate

that four of the teaching faculty as DSDM will be sharing some of their vast experience on the day. As well as some extremely worthwhile and important topics it should be a good opportunity for dentists in the region to put some faces to names and make contact with well renowned specialists in these fields."

The day takes place at The Address Hotel, Dubai Marina on November 29th. Prices include lunch, valet parking and refreshments throughout the day.

Presentations will be as follows:

Common Oral Medicine Problems Presenting in the Dental Practice - Diagnosis and Management

Diagnosis and Management of Temporomandibular Disorders

Non-surgical Periodontics

More than Hygiene Phase Therapy

Molar Incisor Hypomineralisation and Space Management in the Mixed Dentition **DT**

## Information

Tickets can be booked online at [www.cpd-dubai.com](http://www.cpd-dubai.com)

KaVo ARCTICA® CAD/CAM system

## Expect more of your CAD/CAM solution.

**NEW** KaVo ARCTICA® CAD/CAM-system - one system, many advantages.

The KaVo ARCTICA CAD/CAM system, meets all the technical and economic requirements for modern dental solutions, that are presumed in everyday practice and laboratory life.

- Maximum investment protection and future security, due to wide range of applications and extensive material options.
- Outstanding flexibility with maximum integration options.
- Maximum precision for all results, combined with easy handling.

[www.kavo.com/arctica](http://www.kavo.com/arctica)

**KaVo. Dental Excellence.**

KaVo Dental GmbH · Arjaan Tower 9th Floor · Dubai Media City, UAE · PO Box 71569 · Phone +971 4 433 21 86 · Fax +971 4 457 93 73 · Email: [info.mea@kavo.com](mailto:info.mea@kavo.com) · [www.kavo.com/mea](http://www.kavo.com/mea)



# EUROPEAN UNIVERSITY COLLEGE

(formerly NICOLAS & ASP UNIVERSITY COLLEGE)

## • MASTER DEGREE IN ORTHODONTICS •

IN COLLABORATION WITH MALMO UNIVERSITY IN SWEDEN



**Dr. Donald J. Ferguson**  
DMD, MSD  
Professor of Orthodontics  
Dean



**Dr. Ahmad M. Ismail**  
BDS, CES ortho, CES pedo, DUOA, DSO ortho  
Professor of Orthodontics  
Deputy Dean



**Dr. John C. Bennett**  
LDS D Orth, RCS Lond, FDS Edin  
Senior Orthodontic Advisor



**Dr. Anas H. Al Mulla**  
BDS, MSc, PhD  
Assistant Professor of Orthodontics



**Dr. Katerina Douma**  
DDS, MS, PhD  
Adjunct Assistant Professor of Orthodontics



**Dr. Dimitra Kardara**  
DDS, MS, PhD  
Adjunct Assistant Professor of Orthodontics



**Dr. Lana Dalbah**  
DDS, MS  
Adjunct Assistant Professor of Orthodontics



**Dr. Abdelhakim A. El-Gheriani**  
BDS, DMD, MSc, Cert Ortho  
Assistant Professor of Orthodontics

## • MASTER DEGREE IN PEDIATRIC DENTISTRY •



**Dr. Katerina Kavvadia**  
DDS, MDent.Sc, PhD  
Associate Professor of Pediatric Dentistry  
Director, Pediatric Dentistry Program



**Dr. Elias Berdouses**  
DDS, MSc  
Assistant Clinical Professor of Pediatric Dentistry



**Dr. Mark M. Roseman**  
BS, DDS, CAGS  
Clinical Director, Department of Pediatric Dentistry



**Dr. Dina S. Debaybo**  
DMD, MSD  
Assistant Clinical Professor of Pediatric Dentistry



**Prof. Monty Duggal**  
BDS, MDS, Cert. Paeds, FDSRCS, PhD  
FDS (Paeds) RCS (Eng) BS, DDS, CAGS  
Visiting Professor, Department of Pediatric Dentistry

- Accredited by The Ministry of Higher Education & Scientific Research (UAE)
- Teaching faculty from reputed American & European Universities
- Curriculum meets expectations of the Royal College of Surgeons of Edinburgh (RCSEd)
- Prepares applicants for MOrth Membership Examination by RCSEd
- Listed by the International Association of Universities (UNESCO)
- International students from Middle East, Asia, Africa and Europe

[info@dubaipostgraduate.com](mailto:info@dubaipostgraduate.com) | [www.euc.ac.ae](http://www.euc.ac.ae) | +9714 362 4787

Located in Dubai Healthcare City (DHCC), Dubai, UAE





# Endodontic retreatment and adhesive restoration of structurally compromised second premolar

*mCME articles in Dental Tribune have been approved by HAAD as having educational content for CME credit hours. This article has been approved for 2 CME credit hours.*

**ADA C-E-R-P®** Continuing Education Recognition Program

Centre for Advanced Professional Practices (CAPP) is an ADA CERP Recognized Provider. ADA CERP is a service of the American Dental Association to assist dental professionals in identifying quality providers of continuing dental education. ADA CERP does not approve or endorse individual courses or instructors, nor does it imply acceptance of credit hours by boards of dentistry.

CAPP designates this activity for 2 CE credits.

By Drs Stela Nicheva, Lyubomir St. Vangelov & Ivan Filipov Bulgaria

In light of the scientific literature concerning the outcome of the endodontic treatment, it doesn't sound inappropriate that the restoration of the endocoronal complex has to be completed by the endodontist.<sup>1</sup> In this context the following report presents a complete rehabilitation of a second premolar, including retreatment and definitive restoration.

Teeth that need retreatment are most often grossly decayed due to caries, fracture and/or previous restoration. The endodontic retreatment in such cases is a challenge concerning the isolation, overcoming different obstructions, perforation management (if they exist) and final restoration. The success rate for teeth that exhibit one or more technical problems, such as transportation, stripping, perforation or internal resorption, is reported to be 47 per cent.<sup>2</sup> Perforations have the most negative influence.<sup>3</sup>

One of the factors that influence the outcome following non-surgical retreatment is the final restoration. Though some authors question the importance of the coronal restoration for the longevity of endodontically treated teeth,<sup>4,5</sup> it is well accepted that the final restoration is as important for the outcome of the endodontic treatment as the quality of the treatment itself.<sup>6</sup> Still, restoration of endodontically treated teeth remains a controversial issue. In the context of the increasing relevance of biomimetics,<sup>7,8</sup> adhesively inserted indirect partial tooth-colored restorations are gaining more and more attention. The restoration or mimicking of the biomechanical, structural and aesthetic integrity of the teeth in a conservative manner is an advantage that must be used and preferred whenever possible. Still, these types of restorations are an underutilized restorative modality, particularly on endodontically treated teeth compared to crowns.<sup>9</sup> This may be because clinicians and dental technicians are more familiar with crown restorations, the results of which are predictable, and insecure about the adhesive protocol for bonded partial restorations.

Once the decision for tooth-coloured partial restoration is made, the operator must choose between two materials—composite or ceramics. The benefits of the former (less abrasiveness and brittleness, lower costs, easy to polish and repair, user friendly) encounter the strength, inertness and biocompatibility of the latter. While some studies indicate that ceramic and composite inlays provide similar fracture resistance on endodontically treated premolars,<sup>10</sup> other suggest that when cuspal coverage is required composite resin may be more beneficial in endodontically treated posterior teeth compared to ceramics pertaining to its greater survival rate, fatigue resistance and more favorable failures.<sup>11</sup> This can be explained with the more friendly stress distribution of composite resin onlays, confined above the cemento-enamel junction.<sup>12</sup>

The present report describes the microscopic retreatment and the definitive restoration of a grossly decayed perforated maxillary premolar. The reasons for the applied treatment are discussed.

## Case report

A 34-year-old male patient reported to the department of Operative Dentistry and Endodontics, complaining of symptoms from another tooth. The radiographic examination (Fig. 1) revealed inadequate endodontic treatment and perforation with radiolucent area at the apex of tooth 15. The tooth was endodontically treated four years ago.

Medical history was non-contributory. Probing was within normal limits. Local anesthesia with Ubistesine DS was administered. After the removal of the old restoration (Fig. 2) and cleaning up the decay, a pre-endodontic buildup was accomplished.

Undercuts were not removed but were blocked out with the composite resin. The operative field was isolated with retraction cord immersed in AICI3 and Matrix band (Fig. 3). While keeping the orifice and perforation open with gutta-percha points and Cavit, a total etch technique was performed. Enamel and dentin were covered with adhesive (Prime & Bond NT,

DENTSPLY) and polymerized for 10 seconds. Bulk-fill flowable composite was applied (SDR, DENTSPLY) and polymerized for 40 seconds in order to create a reservoir for the irrigants during endodontic retreatment (Fig. 4). After the removal of gutta-percha points and Cavit, the real canal (blue arrows) and the perforation (red arrow) were easily accessible (Fig. 5).

Since the artificial canal was previously obturated with a paste, cleaning with a combination of hand files, ultrasonics (Pro Ultra 5 and 6) and irrigation with citric acid was used. To confirm the effectiveness of the cleaning procedure, an intra-operative X-ray was done (Fig. 6). Because of the different angulation of the beam, it seems as if the perforation is on the level of the crestal bone, which is not the real case.

For cleaning and shaping of the real root canal, the following protocol was used:

1. Glide path was established using SS K-files 08, 10, and Path Files 013, 016, 019, (DENTSPLY Maillefer).
2. The upper two-thirds was prepared using S1 and S2 files from Pro Taper system (DENTSPLY Maillefer).
3. The apical third—20 (04) GTX file (DENTSPLY Maillefer).

Throughout the whole procedure, irrigation with Citric acid (40%, Cerkamed, Poland) and NaOCl (2%, Cerkamed, Poland) was used.

We preferred S1 and S2 files because of their ability to brush against the canal wall, which is very useful in cases with oval cross sections, where it is of paramount importance to clean all aspects of the root canal spaces. For the apical one third we choose landed GTX file, because the canal was very narrow and we wanted to eliminate the possibility to transport the apical foramen. Both artificial and true canal were obturated using warm vertical compaction of gutta-percha and MTA-based sealer (FillApex, Angelus, Brazil). On the post-op radiograph, the preparation and obturation seem short, but this was the reading we repeatedly got with our apex

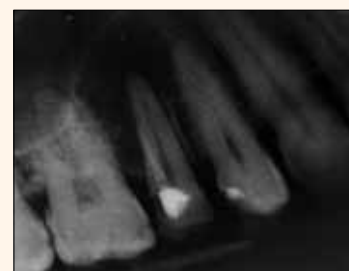

Fig. 1

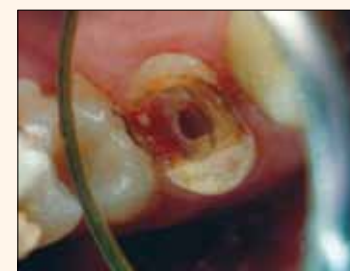

Fig. 2

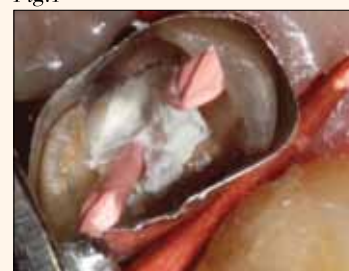

Fig. 3

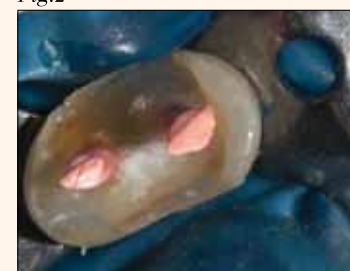

Fig. 4

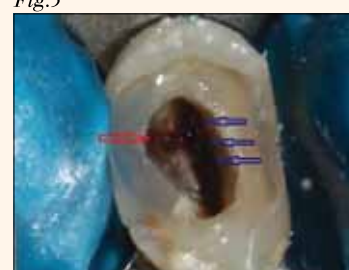

Fig. 5

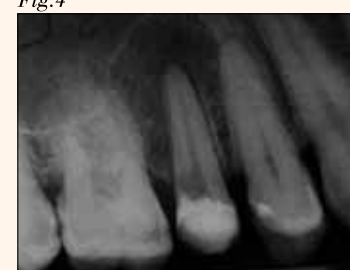

Fig. 6

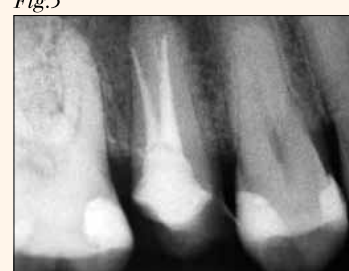

Fig. 7

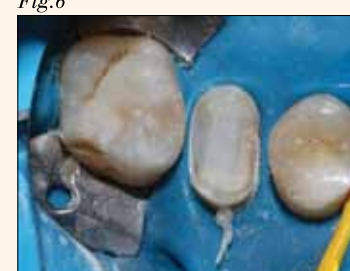

Fig. 8

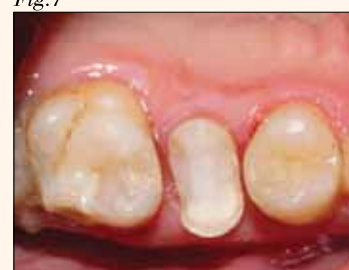

Fig. 9




Fig. 10

locator (RayPex5, VDW, Germany) (Fig. 7).

After the completion of the endodontic retreatment, the pre-endodontic buildup was left at place and the endodontic access was restored again with SDR, creating a core, on which an onlay preparation with diamond burs (Mani Inc.) was performed (Figs. 8 & 9). The enamel margins were exposed and unsupported enamel prisms were removed using fine-grit diamond points. The remaining tooth structure was prepared to reate a butt-joint with the restoration margins. Internal line angles were rounded and the walls provided 5- to 15-degree path of divergence. The proximal boxes preparations

extended to the existing composite, since they were located in the dentin.

The dimensions of the preparation provided at least 2mm interocclusal clearance, which could be verified on the impression. A condensable silicone impression was taken (Fig. 10). A custom made provisional restoration was created using direct technique and temporarily cemented with a non-eugenol luting agent (Temp-Bond NE) (Fig. 11). The fitting aspect of the restoration was sandblasted by the dental technician.

At the second appointment after assessment of the prepared restoration, removal of the provisional and cleaning



of the preparation the fit and aesthetics of the onlay were evaluated. Rubber dam was placed and the preparation was cleaned with acetone, etched with 37 per cent phosphoric acid for 15 seconds, rinsed and dried. The fitting aspect of the restoration was also cleaned with acetone prior to cementation. A dual-cure self-adhesive luting resin (SmartCem2, DENTSPLY) was applied to the walls of the preparation and the restoration was placed with firm pressure until fully seated. The excess cement was removed with an explorer, a #12 scalpel blade and dental floss in the interproximal area after five-second polymerization that brought the cement to a "rubbery" stage (Figs. 12 & 13). The restoration was covered with glycerin and finally cured for 60 seconds from each side (Figs. 14 & 15). The minimal occlusal adjustments were done with fine diamond burs under water coolant. Finishing and polishing were accomplished with the Enhance system (DENTSPLY) (Fig. 16).

Once finishing and polishing was done, a 37 percent phosphoric acid gel was applied for 15 seconds to clean the surface of the restoration and to acid etch the marginal enamel. After washing and drying, the nanofilled adhesive (Prime&BondNT, DENTSPLY) was applied and permitted to rest for 10 seconds to permeate the surface and margin fissures created by the finishing process. The adhesive was then thinned with air and polymerized for 40 seconds (Fig. 17). At the six-month recall, the tooth was asymptomatic and the patient was completely satisfied (Figs. 18,19).

#### Discussion

This case report demonstrates endodontic retreatment and composite onlay as definitive restoration for a compromised

tooth with minimal coronal tooth structure.

The two most important factors in terms of prognosis of treatment of perforations are the age of the lesion and degree of bacterial contamination.<sup>15</sup> In our case, the previous endodontic treatment was done four years ago. The long period of time is not favourable for the prognosis, but since the perforation is in the apical third the likelihood of bacterial contamination is low. After the patient has been informed, he chooses orthograde endodontic retreatment as a treatment modality.

The material of choice for perforation repair is MTA (mineral trioxide aggregate). Because of the small size and apical position of the lesion, we decided to treat it like a second canal and to obturate with gutta-percha and MTA based sealer. The absence of worsening of the periapical conditions in the six months post-op X-ray (Fig. 19) supports this approach, and the patient is still under observation.

Although still debatable, recent comprehensive meta-analysis by Gillen et al.<sup>6</sup> demonstrates that a well-fitting, bacteria-proof final restoration has the same importance for the long-term prognosis of the endodontically treated tooth as does the well-performed endodontic therapy. Besides the prevention of coronal microleakage, a key factor for the long-term survival of an endodontically retreated tooth appears to be the amount of remaining tooth substance,<sup>14</sup> which is determined by the dimensions of the final restoration. So an ideal treatment option for an endodontically retreated tooth seems to be adhesively bonded restoration that preserves as much of the tooth structure as possible.

An endodontically treated posterior tooth presenting with extensive decay is most frequently restored with a post and a crown. That is intelligible, because crowns are a well-established and known, clinically proven restorative modality, and still a considerable amount of research is being performed in this direction.<sup>15</sup> On the other hand, partial toothcoloured restorations are recognized as valuable alternatives to full coverage crowns, and questions are raised if intracanal posts are necessary at all for an endodontically treated tooth.

Since their introduction in 1980,<sup>16</sup> indirect laboratory processed composites are being continuously improved in their physical and mechanical properties. Now this restorative option offers adhesive, biomimetic approach far less aggressive than crowns and far less technique sensitive than ceramics.

Achieving a perfect marginal quality with composite onlays, when gingival margins are located in the dentin, continues to be critical even when new adhesive techniques and systems are used.<sup>17</sup> The application of a composite base underneath indirect composite restorations represents a feasible non-invasive alternative to surgical crown lengthening to relocate cavity margins from an intra-crevicular to a supra-gingival position. This also permits the placement of rubber dam for absolute isolation. Surgical crown lengthening may also compromise the periodontal tissue support of neighbouring teeth.<sup>18</sup> We did this relocation simultaneously with the pre-endodontic build up with SDR. This material has the intimate wetting ability of low viscosity composite and in the same time polymerization shrinkage stress similar to regular viscosity composite.

To simplify the procedures

for bonding indirect restorations, resin cements have been introduced recently that are promoted as self-adhesive—i.e., do not require a separate adhesive application step. Manufacturers claim that these cements are hydrophilic when mixed (acidic phase) but become hydrophobic (neutral pH) upon reaction with the tooth structure. The bond strengths to the tooth structure are questioned. In our case we decided to additionally etch the enamel margins of the preparation, although not recommended by the manufacturer, because the procedure is simple and, as Duarte et al.<sup>19</sup> and de Andrade et al.<sup>20</sup> demonstrated, improves the bond strength of the restoration.

We preferred condensation-type silicone impression material for its better ability to reproduce the surface characteristics of low viscosity resin reported by Takano et al.<sup>21</sup>

The surface and margins of the restoration were sealed with filled adhesive. This treatment improves the marginal adaptation,<sup>22</sup> and it could be demonstrated that adhesives are superior to specially designed resin coating materials.

*Editorial note: A complete list of references is available from the publisher. DT*

#### Contact Information

##### Stela Nicheva

DMD, graduated in dentistry from Medical University, Plovdiv, Bulgaria, in 2010. Currently she is taking a PhD position at the Department of Operative Dentistry and Endodontics, Faculty of Dental Medicine, Plovdiv, Bulgaria.

She may be contacted at [stelanicheva@gmail.com](mailto:stelanicheva@gmail.com).

##### Lyubomir Vangelov

DMD, is an assistant professor at Faculty of dental medicine, Department of Operative Dentistry and Endodontics, Plovdiv-Bulgaria.

Simultaneously he maintains his private practice in Dental Center "Avangard," limited to endodontics and esthetic restorations.

##### Ivan Filipov

DMD, PhD, is associate professor at Faculty of Dental Medicine, Department of Operative Dentistry and Endodontics, Plovdiv, Bulgaria, and maintains his private practice in Dental Center "Avangard."

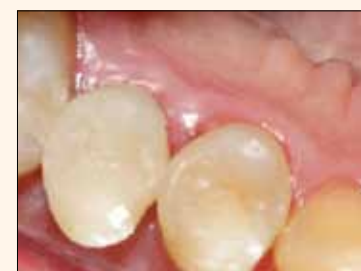

Fig.11

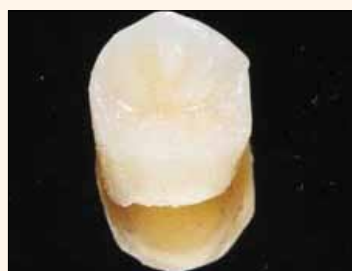

Fig.12

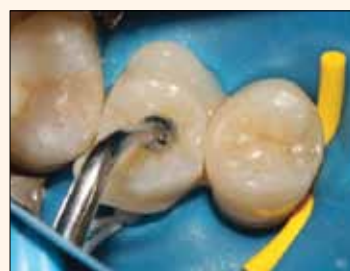

Fig.13

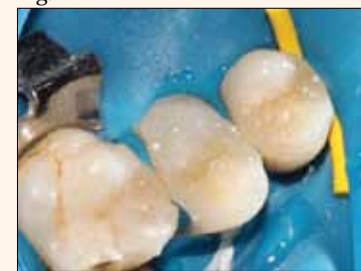

Fig.14



Fig.15

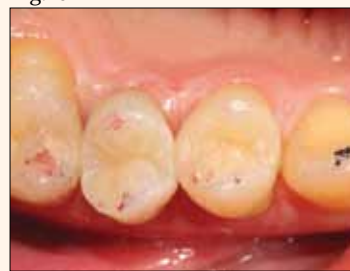

Fig.16

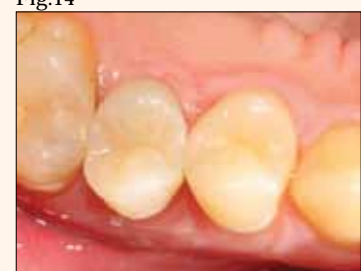

Fig.17

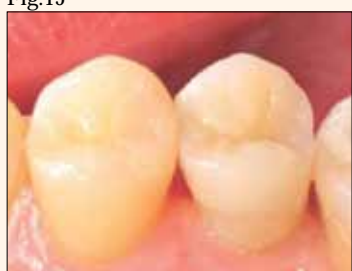

Fig.18

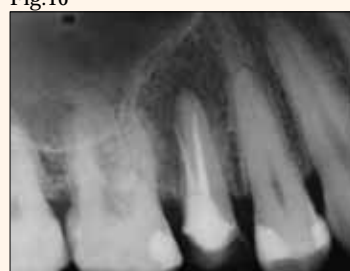

Fig.19

#### mCME SELF INSTRUCTION PROGRAM

CAPP with Dental Tribune with its mCME Self Instruction Program gives you the opportunity to have a quick and easy way to meet your continuing education needs. mCME offers you the flexibility to work at your own pace through the material from any location at any time. The content is international, drawn from the upper echelon of dental medicine, but also presents a regional outlook in terms of perspective and subject matter.

#### Membership:

Take membership for one year by subscription for the newspaper: 600 AED

Take article with one newspaper subscription: 100 AED per issue.

After the payment, you will receive your membership number and will be able to start the program.

#### Completion of mCME


- mCME participants are required to read a continuing medical education (CME) article in each issue.
- Each article offers 2 CME Credit and followed by quiz questioner, which is available in <http://www.cappmea.com/mCME/questionnaires.html>.
- Each quiz has to be return to [events@cappmea.com](mailto:events@cappmea.com) or fax to: +971436868883 in three months form the publication date
- A minimum passing score of 80% must be achieved in order to claim credit
- Not more than two answered questions can be submitted in the same time
- Validity of the article - three months
- Validity of the subscription - one year
- Collection of Credit hours: you will receive the summary report with Certificate maximum one month after expire date of your membership. For single subscription Certificate and summery report will be send one month after the publication of the article.

The answers and critiques published herein have been checked carefully and represent authoritative opinions about the questions concerned.

Articles are available in [www.cappmea.com](http://www.cappmea.com) after the publication. For more information please contact [events@cappmea.com](mailto:events@cappmea.com) or +971 4 3616174

**FOR INTERACTION WITH THE WRITERS FIND THE CONTACT DETAIL AT THE END OF EACH ARTICLE.**





# Clinical indications for a composite-metal PFM restorative

*mCME articles in Dental Tribune have been approved by HAAD as having educational content for CME credit hours. This article has been approved for 2 CME credit hours.*

**ADA C-E-R-P®** Continuing Education Recognition Program

Centre for Advanced Professional Practices (CAPP) is an ADA CERP Recognized Provider. ADA CERP is a service of the American Dental Association to assist dental professionals in identifying quality providers of continuing dental education. ADA CERP does not approve or endorse individual courses or instructors, nor does it imply acceptance of credit hours by boards of dentistry.

*CAPP designates this activity for 2 CE credits.*

By Barry F. McArdle, DMD

Although “metal-free” has become a mantra in some dental circles, even when it comes to indirect restorations, all-ceramics have their limitations. When parafunctional habits, wear of the existing dentition, the need for subgingival margin placement, masking of discolored tooth structure or the necessity of conventional cementability contraindicate the use of these newer dental materials, the traditional porcelain-fused-to-metal restoration is called for. It has, however, fallen out of favor with many practitioners primarily because of its cosmetic shortcomings in the esthetic zone.

An alternative to conventional PFMs has proven itself as a prime option under these circumstances, both functionally and cosmetically. Captek (Argen Corp., San Diego) is a composite metal, not an alloy, whose optical properties accurately mimic those of enamel’s underlying hard and soft tissues.<sup>1</sup> In the hands of a knowledgeable ceramist, ultimate vitality can be obtained by using this system (Figs. 1, 2), and the shade matching attained with this material is remarkable (Fig. 3).

In addition, Captek has demonstrated micromechanical interlocking as its primary mechanism of porcelain adherence<sup>2</sup>, which in my experience has resulted in the superior strength and fracture resistance that is often required in specific clinical situations. The Captek system uses a unique bonding mechanism (referred to as the Universal Porcelain Coupler or UCP) between the coping material and porcelain (or composite resin) that extends gold and platinum micro-filaments from the Captek surface. These micro extensions provide exceptional mechanical bond strength.

This system was developed because of Captek’s pure, high noble metal composition — and has the advantage of not producing any oxides, a byproduct of the traditional PFM bond — which therefore requires a different method of bonding to porcelain. This Captek bonding process eliminates the conventional grey oxide layer created during adhesion with other PFMs and surpasses it in its bond

strength. This creates a tenacious bond between the Captek coping and porcelain (or composite resin).<sup>3</sup> The elasticity of this micromechanical interlocking diminishes ceramometal stresses caused by coefficient of expansion differences that often account for porcelain cracking and chipping.

The UCP on Captek copings provides a color backdrop for the final restoration that is the closest to natural tooth structure and resembles the color of dentin nearest to the pulp. These hues of gold and yellowish-orange provide the most natural color background for the porcelain as dentin has an inherently yellow-gold color with a vital pulp producing a warm red background.

Therefore, the Captek coping provides the perfect base for any type of veneering — porcelain, acrylic or composite — giving it a warmer and more organic tone.

The UCP’s light-scattering effect also contributes to the natural appearance of Captek crowns. Light reflecting from the coping through the porcelain is scattered by the extensions of the UCP layer, much like it is by natural tooth structure. Reflected light is fragmented and dispersed by natural tooth structure due to its enamel prisms and dentin tubuli just as it is by the UCP in Captek.

The Captek coping also exhibits an increased resistance to cyclic loading that derives from its unique three-layered structure (a lattice of gold that is strengthened with palladium and platinum), which provides a high degree of elasticity and resilience (Fig. 4).<sup>4</sup> Masticatory forces and everyday parafunction produce vibration and shocks that can harm porcelain and its underlying supporting structure, whether implant or natural tooth.

Unprotected porcelain may chip and crack during function. Captek protects its porcelain by absorbing masticatory and parafunctional impacts that advance from the point of contact inward. When a restored implant or natural tooth is exposed to these continuous impacts and vibrations, their structure is weakened and the periodontium can be affected. The inner and outer layers of Captek are each 25 microns thick, 97 percent gold and

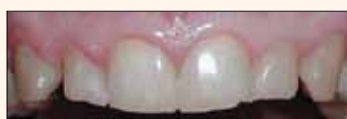

Fig.1 The patient’s worn, misaligned and discolored smile.



Fig.2 The old smile is transformed into a naturally balanced one using Captek crowns.

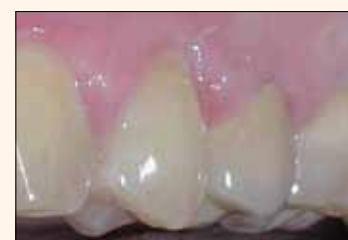

Fig.3 Shade matching with Captek and accurate clinical records is virtually perfect. The crown in this picture is on tooth #13.




Fig.4a, b A scanning electron micrograph shows the Universal Porcelain Coupler (UCP) interface.

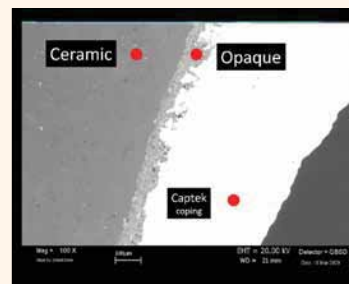


Fig.5 The first layer of metalembedded wax is put in place on the refractory die.

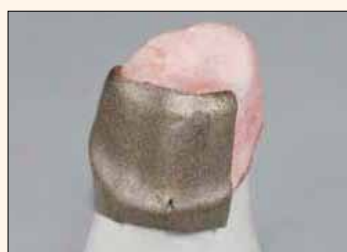

Fig.6 This layer is adapted intimately to the die surface.



Fig.7 The first layering adaptation is completed and is ready for the second.

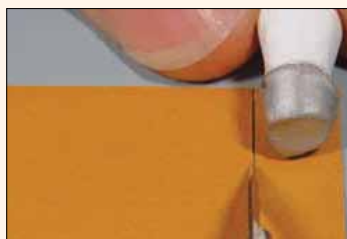

Fig.8 The second layer of metalembedded wax is put in place on the refractory die.



Fig.9 The second layering adaptation is completed and ready for firing.

3 percent silver. These layers are very forgiving and efficiently absorb the shocks and vibrations that can travel through the porcelain during routine function. This extraordinary shock-absorbing feature protects the layered porcelain, and it is particularly valuable for implant cases where no periodontal ligament cushioning exists.

What’s more, Captek affords an important alternative for situations of limited space, such as at the lower incisors. With its one-of-a-kind configuration, the Captek coping can be thinner than conventional metals, allowing the technician more latitude in porcelain design with conservative, minimal thickness restorations.

Even though the Captek coping is not cast, its extensively documented marginal integrity<sup>5</sup> and antibacterial qualities<sup>6</sup> make it an ideal restorative where subgingival margins are necessary, and I have found in many cases that these properties may afford the clinician more leeway in

relation to the biologic width. The coping is made directly on the die model, providing an exceedingly precise fit.

In the Captek protocol, a metal embedded wax is applied in steps directly to a refractory die for the design and construction of the final metal coping, resulting in a highly precise marginal adaptation (Figs. 5–10). Other PFM technologies employ indirect methods that can introduce inaccuracies and distortions to marginal integrity. Captek can also be burnished to further refine its marginal precision. The coping can be swedged before porcelain layering with different spacers to accomplish just the desired proximity to the tooth and spacing for cement thickness. Any crown and bridge cement can be used with Captek except those that must be light cured for best results. Captek maintains its accuracy through porcelain firing thanks to its internal reinforcing skeleton that resists warpage.

Research studies have found

a marginal precision after cementation of 14.5–18 microns in single crowns and bridgework.<sup>7</sup> Either chamfer or shoulder and bevel designs can be used with margins in metal or porcelain. When considering the use of this material, be certain to use a Captek-certified laboratory in order to realize its full benefits.

These unique properties are the result of years of extensive research that started in 1972 by two Israelis, Itzhak Shohar, DMD, MS and Aharon Whiteman, MDT. Together they have developed several different dental materials, such as RPS (reinforced porcelain system/Inzoma) and the Renaissance system, which have proven to be extremely biocompatible with outstanding esthetics in everyday dental practice. In the years between 1993 and 1996, their research into gold, palladium and platinum metallurgy yielded Captek, when this material was introduced to the international dental community.

In addition, during the following years, Shohar and Whiteman cultivated multiple improvements to the product, the most significant being Captek Nano, which was introduced in 2007. This version allows for the fabrication of longer span bridgework and adds implant-supported restorations to this material’s broad repertoire.

The elemental ratios have been altered in this process to reflect a composite metal content of 84 percent gold with the higher concentrations of 5.3 percent platinum and 7.2 percent palladium for even greater strength. This permits the varying coping thickness-



es of 0.28 mm for lengthier span bridge fabrication, 0.23 mm for routine restorations and even less than 0.2 mm for areas in the esthetic zone where maximal clearance for porcelain application may be needed.

Captek copings for bridge-work utilize a specialized soldering method that precludes the possibility of any casting distortion for a completely passive fit. At this time, close to 10 million Captek units have been placed in the United States alone.

## Uses

It is often the case that the location of previous restorations, cemental exposure or new carious lesions will mandate the placement of subgingival margins. It has also been my experience that because cariogenic oral bacteria are predominantly aerobic, and therefore do not have a significant presence in the subgingival environment, subgingival margin placement results in less recurrent decay. Due to the moisture inherent in situations such as these, a cementable restoration is essential, and of the new generation in metal-free products, only zirconia will fill that bill.

However, zirconia is among the least esthetic of the ceramics whereas Captek achieves clearly superior esthetic results intrinsically and, in clinical testing, is proven to encourage the most natural soft-tissue esthetics as well.<sup>8</sup> This quality is explained by the influence of the Captek coping's warm metal color and its aforementioned bacteriostatic properties, which contribute greatly to gingival health where other materials, even including semi-precious metal copings, can be problematic (Figs. 11, 12).

Bacteriostasis occurs due to significantly lower bacterial adhesion to Captek as compared with other crown and bridge materials or even natural tooth structure, and significantly reduces harmful bacteria in the gingival sulcus over time.<sup>6</sup> Because Captek is composed completely of precious metals, it will not react in the oral environment to cause oxide formations. This lack of oxides is a major advantage for all the Captek copings surrounding structures from the gingivae to porcelain. Oxides from a standard crown's margins can infiltrate the adjacent gingivae, causing discoloration, and in some instances, even an inflammatory reaction. The Captek coping will not induce inflammation in the proximate gingiva, connective tissue or alveolar bone in any way. Oxide formation on standard crown margins can make these surfaces rough, causing greater plaque accumulations that can eventually lead to gingivitis and may, in severe cases, advance to periodontitis. Captek's oxide-free sur-



Fig.10 The fired coping is now ready for finishing and porcelain application.

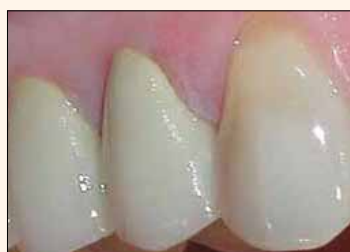

Fig.12 The same teeth 18 months after having been re-restored with Captek crowns show no sign of gingival irritation whatsoever.



Fig.14 The vitality of these Captek crowns is a rival for any metal-free units, and even their adjacent natural teeth.

face prevents the occurrence of such reactions.

In conventional crown systems, metals oxidize during porcelain firing, causing an overall grayish look at the margins. Over time in the oral environment, these standard metals continue to oxidize, further discoloring the marginal porcelain through dispersion of the oxide molecules. Captek metals will not oxidize in the oral cavity under any circumstances, thus preserving the original color of the restoration. Captek's composite metal structure also produces a micro-electrical bipolar stimulus that seems to progressively invigorate the tissue cells around it.<sup>9</sup> So gingivae are not only unaffected by Captek, but the product actually has a positive effect on these tissues.

Thus, there is comparatively less gingivitis and recession around a Captek crown than found around other ceramometal restorations. Consequently, Captek has become my material of choice for indirect restorations in the esthetic zone that demand subgingival margins.

As any dentist knows, endodontically treated teeth often discolor significantly after such procedures. It is also true that there are some implant cases where it is preferable to use a metal abutment, and in these instances the effect on gingival color can be decidedly negative.<sup>10</sup> The translucency of most metal-free restoratives will not allow for the full masking of this tooth discoloration or metal reflection, and cosmetic outcomes will be adversely affected when those materials are used under these circumstances.<sup>11</sup>

As a PFM restoration, Captek

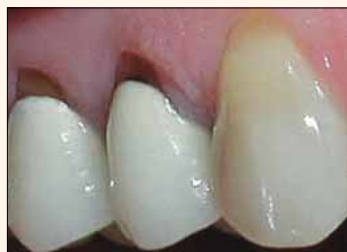

Fig.11 The gingivae at these premolars restored with porcelain-fused-to-semi-precious-metal copings are severely inflamed and have receded substantially after only 14 months.

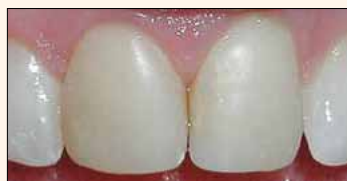

Fig.13 The composite facings on these central incisors are esthetically unacceptable.

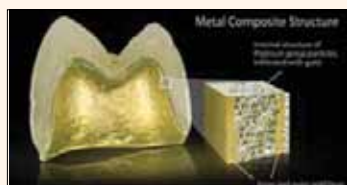

Fig.15 Clinical cross section of the Captek coping.

affords ultimate masking qualities, and its excellent esthetic results make it the prime choice in situations where masking abutment discoloration is of prime importance.

The longevity of large restorative cases is of major consequence to the treating dentist. Remakes due to functional failure are costly to the dentist not only economically, but in terms of his or her reputation as well. The greater strength of PFM restorations over their metal-free counterparts, even including zirconia units, is well documented in the literature.<sup>12</sup> In cases where occlusal or parafunctional matters are of a principal concern, ceramometal crowns will be the longest lasting.

Considering Captek's advanced cosmetic capabilities and strength characteristics, there is no disadvantage to going with PFM restorations in a smile design case that has wear issues, which could lead to potential failures if all-ceramics are used. It is on this last point that I am met with the most skepticism from colleagues during my lectures around the country. There are many practitioners who simply will not believe that a PFM restorative can match the vitality of an all-ceramic product.

I have found in my practical experience that all other things being equal (skill of the laboratory technician involved, quality of the clinical records provided, etc.), it is easier to fabricate a really life-like restoration from a metal-free material, but in the hands of a master ceramist, Captek restorations can achieve an organic realism that is virtually indistinguishable from nature (Figs.13, 14).

In fact, complex restorative cases blending Captek and

## mCME SELF INSTRUCTION PROGRAM

CAPP with Dental Tribune with its mCME- Self Instruction Program gives you the opportunity to have a quick and easy way to meet your continuing education needs. mCME offers you the flexibility to work at your own pace through the material from any location at any time. The content is international, drawn from the upper echelon of dental medicine, but also presents a regional outlook in terms of perspective and subject matter.

## Membership:

Take membership for one year by subscription for the newspaper: 600 AED

Take article with one newspaper subscription: 100 AED per issue.

After the payment, you will receive your membership number and will be able to start the program.

## Completion of mCME

- mCME participants are required to read a continuing medical education (CME) article in each issue.
- Each article offers 2 CME Credit and followed by quiz questioner, which is available in <http://www.cappmea.com/mCME/questionnaires.html>.
- Each quiz has to be return to [events@cappmea.com](mailto:events@cappmea.com) or fax to: +971436868883 in three months form the publication date
- A minimum passing score of 80% must be achieved in order to claim credit
- Not more then two answered questions can be submitted in the same time
- Validity of the article - three months
- Validity of the subscription - one year
- Collection of Credit hours: you will receive the summary report with Certificate maximum one month after expire date of your membership. For single subscription Certificate and summery report will be send one month after the publication of the article.

The answers and critiques published herein have been checked carefully and represent authoritative opinions about the questions concerned.

Articles are available in [www.cappmea.com](http://www.cappmea.com) after the publication. For more information please contact [events@cappmea.com](mailto:events@cappmea.com) or +971 4 5616174

**FOR INTERACTION WITH THE WRITERS FIND THE CONTACT DETAIL AT THE END OF EACH ARTICLE.**

all-ceramic units have been documented to realize a harmonious result.<sup>15</sup>

## Conclusion

Although all-ceramic restorations have been en vogue when it comes to transformational restorative cases in the esthetic zone for some time — even being taught as state-of-the-art in dental schools<sup>14</sup> — they are not the be-all or end-all when it comes to solving many common clinical situations.

The placement of all-ceramic restorations is much more technique sensitive than its ceramometal counterpart, and their long-term function, especially when all occlusal considerations have not been carefully accounted for, is questionable at best in comparison.<sup>15</sup>

There is a porcelain-fused-to-metal alternative that is stronger than the all-ceramic choices available, kinder to gingival tissues, more esthetic when seen through those tissues and every bit as natural looking when fabricated by a talented ceramist.

These attributes come from the design of Captek's unique composite metal coping (Fig. 15),<sup>16</sup> whose properties set it apart from all other PFMs in the 10 years that I have been using it.

If there are cases for which

you hesitate to use a metal-free restorative due to occlusal questions or where periodontal, abutment color or gingival factors are paramount, consider Captek. It will perform flawlessly under all these conditions while delivering cosmetic results that are unsurpassed by any other material when in the hands of a gifted laboratory technician. What more could you ask for?

The author would like to thank the Elite porcelain team at Arrowhead Dental Laboratory for their expertise in fabricating the Captek restorations shown in this article.

*Editorial note: A complete list of references is available from the publisher. DT*

## Contact Information

**Dr. Barry F. McArdle** graduated from Tufts in 1985 and maintains a private practice in Portsmouth, N.H. An expert reviewer for JADA, he has authored numerous articles in the peer-reviewed literature. McArdle is an alumnus of The Pankey Institute.

He co-founded the Seacoast Esthetic Dentistry Association in 2000 and his lecture series, Seacoast Dental Seminars, in 2005.

You may contact him at [drmcardle@seacoastdental-seminars.com](mailto:drmcardle@seacoastdental-seminars.com).