

# roots

international magazine of endodontology

3<sup>2013</sup>

## | CE article

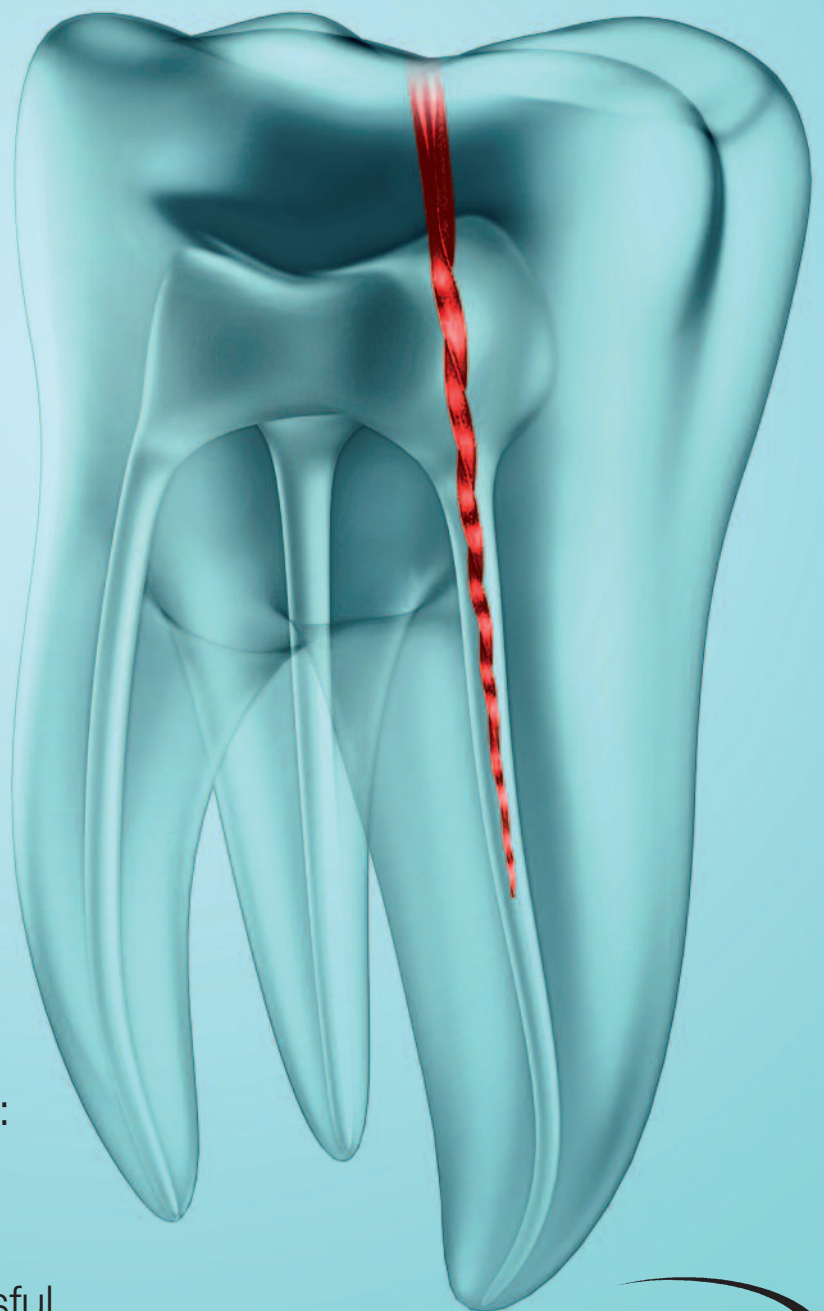
Endodontic retreatment and adhesive restoration of structurally compromised second premolar

## | research

*In vitro* analysis of efficiency and safety of a new motion for endodontic instrumentation: TF Adaptive

## | case report

Eight-year follow-up of successful intentional replantation



027113

## RECIPROCATE and SMILE



"My experience with RECIPROC® has been nothing short of amazing. This presents a paradigm shift in the way mechanical root canal preparation can be achieved to provide every practitioner a markedly better opportunity to produce consistent, predictable results. RECIPROC® provides the safest and easiest method for shaping the canals compared to any system. If this doesn't get you more excited about endodontics nothing will!"

Dr. Bjørn Besserman-Svendsen, Frederiksberg Copenhagen, Denmark



[www.vdw-dental.com](http://www.vdw-dental.com)



**RECIPROC®**  
*one file endo*

# Dear friends and colleagues,



Dr Hakki Sunay

**It is with great honour** and pleasure that I write the editorial for this year's third issue of the **roots** magazine. Throughout my career, I have always believed in the importance of collaboration between dental practitioners and specialists, and it is undeniable that dental journals offer an indispensable means of fostering interaction and communication between dental professionals. I also strongly feel that endodontic specialists should be continuously involved in collaborative activities, and the delivery of up-to-date information by means of journals is a very efficient means of sharing one's experience and knowledge. Endodontic specialists, and all other dental practitioners, should also be encouraged to participate in symposiums and conferences pertaining to the field and subscription to a specialty journal can be a very efficient means of creating and maintaining a scientifically based professional foundation.

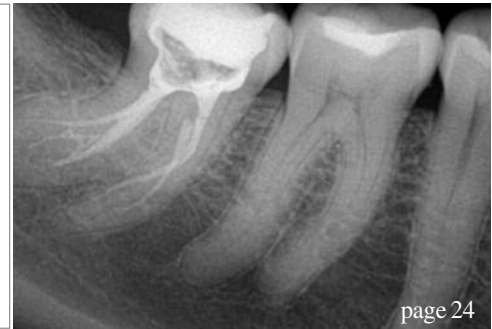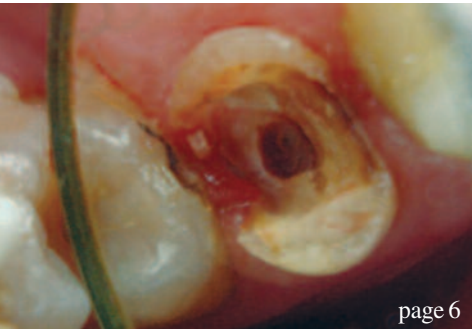It is amazing how rapidly the specialty of endodontics has developed and evolved, especially in the last decade, with new approaches and methodologies regularly being unveiled, as well as paradigm shifts that might alter our conventional methodologies through the introduction of innovative and productive devices. Instrumentation has always been a challenge for endodontists and we are living in an era in which rapid delivery of quality dental service is expected. New methodologies and instrumentation systems are continuously being launched to facilitate endodontic patients' comfort and to ease the practitioner's work. This issue of the magazine contains the most recent information concerning new shaping strategies; readers are introduced to new options and encouraged to make comparisons with their routine methodologies.

Imaging and magnification are considered very important steps in state-of-the-art endodontic care, and it is indisputable that one is enabled to perform sensitive procedures in endodontic treatment when good visualisation is rendered possible. You will find in this issue information on visual data and imaging that will enhance the quality of your endodontic treatments. Case reports are a good means of sharing one's experience with others, and through commentary on and analysis of unique cases dental practitioners can be provided with sufficient information on cases they might encounter in their practices. In this issue, in the belief that such information is very helpful for enhancing the vision of a dental practitioner, interesting cases with efficient treatment modalities and sufficient follow-up periods are presented.

Finally, the European Society of Endodontology congress is soon to be held in Lisbon in Portugal, and we are expecting to enjoy a lively scientific programme with mutual discussions, the exchange of ideas and the enhancement of existing knowledge. I wish all participants a pleasant and productive congress, and I hope that the upcoming event will serve as a successful means of supporting our endeavours in striving to offer the best service in our patients' best interest.

My best wishes to all readers and colleagues,

Dr Hakki Sunay  
Associate Professor, Faculty of Dentistry, Yeditepe University



## | editorial

- 03 **Dear friends and colleagues**  
| Dr Hakki Sunay

## | CE article

- 06 **Endodontic retreatment and adhesive restoration of structurally compromised second premolar**  
| Drs Stela Nicheva, Lyubomir St. Vangelov & Ivan Filipov, Bulgaria

## | research

- 12 **In vitro analysis of efficiency and safety of a new motion for endodontic instrumentation: TF Adaptive**  
| Prof. Gianluca Gambarini, Italy & Dr Gary Glassman, Canada

## | industry report

- 16 **MounceFiles: A safe, economical and efficient option for canal preparation**  
| Dr Rich Mounce, USA

## | technique

- 22 **Hands on with the new reciprocating motion file system**  
| Dr Thomas Jovicich, USA

## | case report

- 24 **Adapting to the anatomy, guided by the canal**  
| Dr Philippe Sleiman, Lebanon

- 28 **Eight-year follow-up of successful intentional replantation**  
| Dr Muhamad Abu-Hussein, Greece; Dr Sarafianou Aspasia, Greece; & Dr Abdulgani Azzaldeen, Israel

## | opinion

- 32 **Visual information and imaging technology in endodontics**  
| Prof. Hideaki Suda & Dr Toshihiko Yoshioka, Japan

## | industry news


- 34 **Produits Dentaires presents PD MTA White**  
| Produits Dentaires
- 34 **RECIPROC—also efficient in retreatment**  
| VDW
- 36 **Axis | SybronEndo: Rotary Meets Endo**  
| Perry Lowe, USA (Axis | SybronEndo)
- 38 **A new manufacturing process for new NiTi rotary files**  
| Dr Arnaud Stanurski, France (NEOLIX)

## | meetings

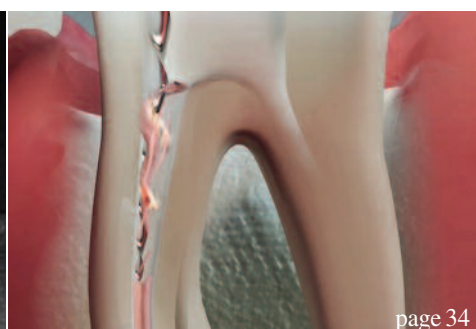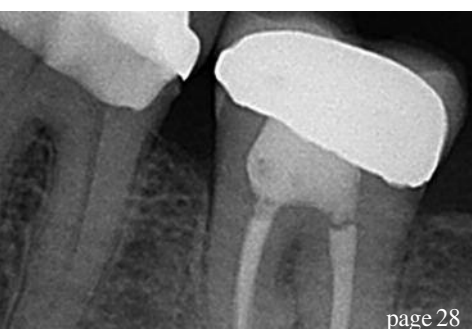- 40 **International Events**

## | about the publisher

- 41 | submission guidelines  
42 | imprint



Cover image courtesy of SybronEndo





# BE SAFE!

**neoniti** new nickel titanium rotary file is manufactured by Electric Discharge Machining (EDM) combined with an appropriate heat-treatment. This exclusive process allows **sharp cutting edges**, **built-in abrasive properties**, **variable changing profiles**, and **a progressive flexibility**.

Key advantages of **neoniti** are:

- no screwing in effect
- a high resistance to fatigue
- an effective removal of debris
- an enhanced cutting speed

**neoniti** is a *safe* rotary file, even in complex cases, and is appropriate for all practitioners.



NEOLIX SAS - 11, avenue Raoul Vadepiéd  
53600 Châtres-la-Forêt (France)  
Tel: +33-2-5374-5007 - Fax: +33-2-5368-2005  
Email: [neolix@neolix.eu](mailto:neolix@neolix.eu) - Web: [www.neolix.eu](http://www.neolix.eu)

NEOLIX   
Creative dental instruments

# Endodontic **retreatment** and **adhesive restoration** of structurally compromised second premolar

**Authors\_ Drs Stela Nicheva, Lyubomir St. Vangelov & Ivan Filipov, Bulgaria**

\_ce credit

roots



By reading this article and then taking a short online quiz, you can gain ADA CERP CE credits. To take the CE quiz, visit [www.dtstudyclub.com](http://www.dtstudyclub.com). The quiz is free for subscribers, who will be sent an access code. Please write [support@dtstudyclub.com](mailto:support@dtstudyclub.com) if you don't receive it. Non subscribers may take the quiz for a \$20 fee.

**\_In light of the scientific literature** concerning the outcome of the endodontic treatment, it doesn't sound inappropriate that the restoration of the endo-coronal complex has to be completed by the endodontist.<sup>1</sup> In this context the following report presents a complete rehabilitation of a second premolar, including retreatment and definitive restoration.

(Photos/Provided by  
Dr Stela Nicheva)

Teeth that need retreatment are most often grossly decayed due to caries, fracture and/or pre-

vious restoration. The endodontic retreatment in such cases is a challenge concerning the isolation, overcoming different obstructions, perforation management (if they exist) and final restoration. The success rate for teeth that exhibit one or more technical problems, such as transportation, stripping, perforation or internal resorption, is reported to be 47 per cent.<sup>2</sup> Perforations have the most negative influence.<sup>3</sup>

One of the factors that influence the outcome following non-surgical retreatment is the final restoration. Though some authors question the importance of the coronal restoration for the longevity of endodontically treated teeth,<sup>4,5</sup> it is well accepted that the final restoration is as important for the outcome of the endodontic treatment as the quality of the treatment itself.<sup>6</sup> Still, restoration of endodontically treated teeth remains a controversial issue. In the context of the increasing relevance of biomimetics,<sup>7,8</sup> adhesively inserted indirect partial tooth-colored restorations are gaining more and more attention. The restoration or mimicking of the biomechanical, structural and aesthetic in-

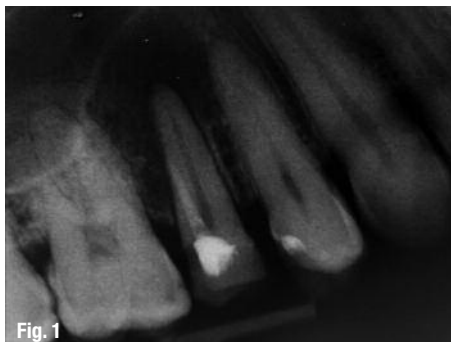


Fig. 1

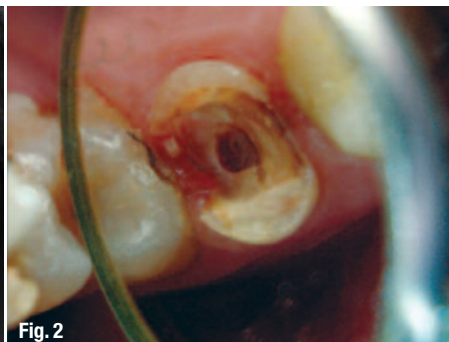

Fig. 2

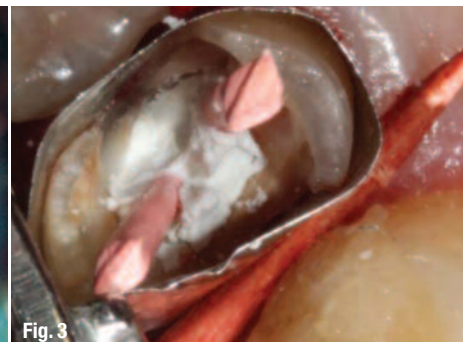


Fig. 3



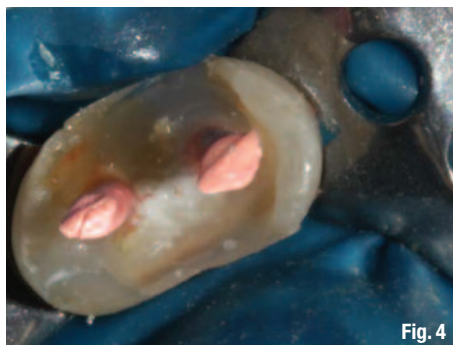

Fig. 4

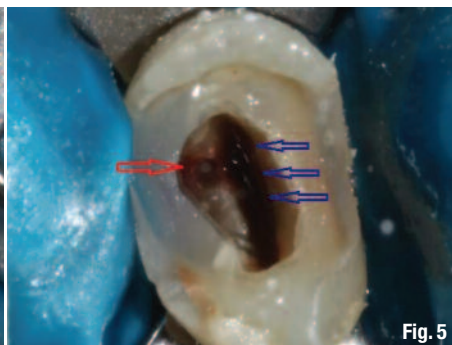

Fig. 5

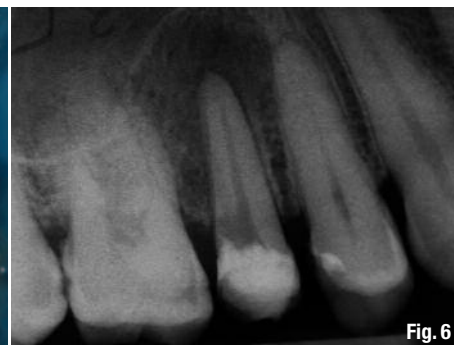

Fig. 6

tegrity of the teeth in a conservative manner is an advantage that must be used and preferred whenever possible. Still, these types of restorations are an underutilized restorative modality, particularly on endodontically treated teeth compared to crowns.<sup>9</sup> This may be because clinicians and dental technicians are more familiar with crown restorations, the results of which are predictable, and insecure about the adhesive protocol for bonded partial restorations.

Once the decision for tooth-coloured partial restoration is made, the operator must choose between two materials—composite or ceramics. The benefits of the former (less abrasiveness and brittleness, lower costs, easy to polish and repair, user friendly) encounter the strength, inertness and biocompatibility of the latter. While some studies indicate that ceramic and composite inlays provide similar fracture resistance on endodontically treated premolars,<sup>10</sup> other suggest that when cuspal coverage is required composite resin may be more beneficial in endodontically treated posterior teeth compared to ceramics pertaining to its greater survival rate, fatigue resistance and more favorable failures.<sup>11</sup> This can be explained with the more friendly stress distribution of composite resin onlays, confined above the cemento-enamel junction.<sup>12</sup>

The present report describes the microscopic retreatment and the definitive restoration of a grossly decayed perforated maxillary premolar. The reasons for the applied treatment are discussed.

## Case report

A 34-year-old male patient reported to the department of Operative Dentistry and Endodontics, complaining of symptoms from another tooth. The radiographic examination (Fig. 1) revealed inadequate endodontic treatment and perforation with radiolucent area at the apex of tooth 15. The tooth was endodontically treated four years ago.

Medical history was non-contributory. Probing was within normal limits. Local anesthesia with Ubistesine DS was administered. After the removal of the old restoration (Fig. 2) and cleaning up the decay, a pre-endodontic buildup was accomplished. Undercuts were not removed but were blocked out with the composite resin. The operative field was isolated with retraction cord immersed in  $\text{AlCl}_3$  and Matrix band (Fig. 3). While keeping the orifice and perforation open with gutta-percha points and Cavit, a total etch technique was performed. Enamel and dentin were covered with adhesive (Prime & Bond NT, DENTSPLY) and polymerized for 10 seconds. Bulk-fill flowable composite was applied (SDR, DENTSPLY) and polymerized for 40 seconds in order to create a reservoir for the irrigants during endodontic retreatment (Fig. 4). After the removal of gutta-percha points and Cavit, the real canal (blue arrows) and the perforation (red arrow) were easily accessible (Fig. 5).

Since the artificial canal was previously obturated with a paste, cleaning with a combination of hand files, ultrasonics (Pro Ultra 5 and 6) and irrigation with citric acid was used. To confirm the effectiveness of

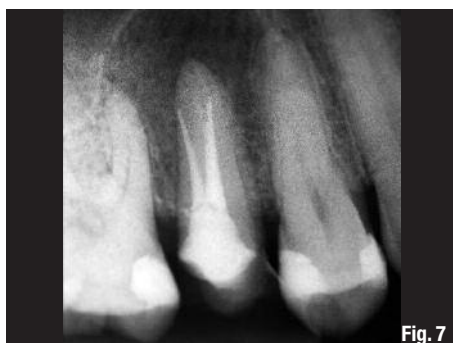

Fig. 7

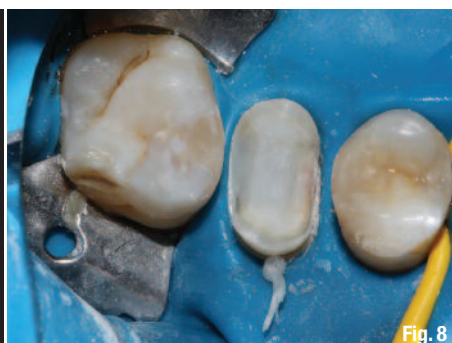

Fig. 8

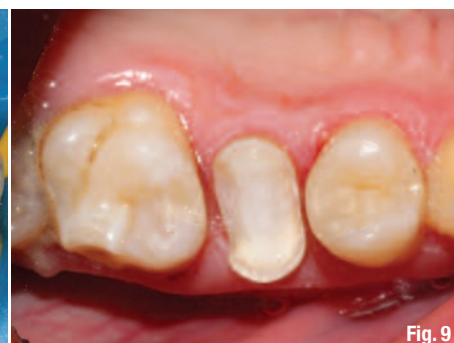

Fig. 9

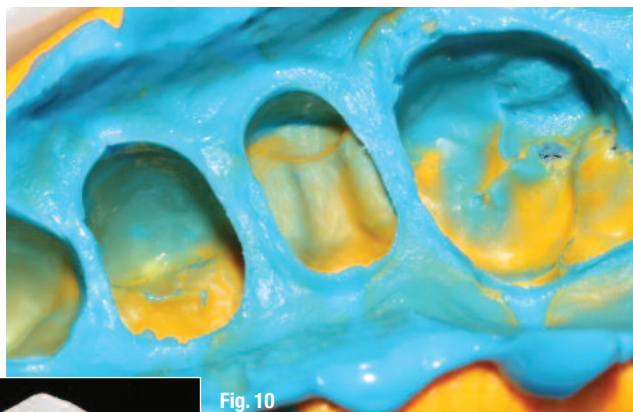


Fig. 10

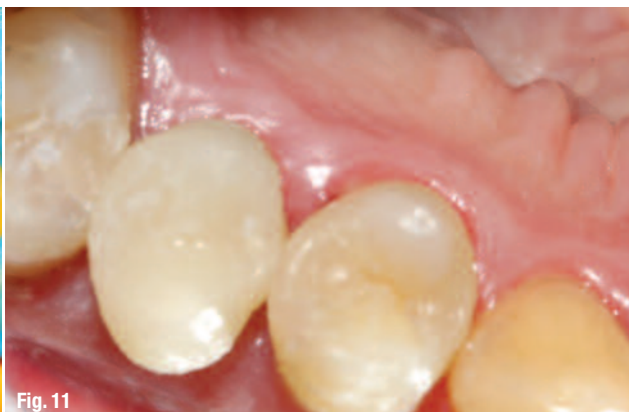

Fig. 11

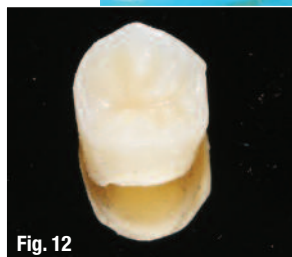

Fig. 12

the cleaning procedure, an intra-operative X-ray was done (Fig. 6). Because of the different angulation of the beam, it seems as if the perforation is on the level of the crestal bone, which is not the real case.

For cleaning and shaping of the real root canal, the following protocol was used:

1. Glide path was established using SS K-files 08, 10, and Path Files 013, 016, 019, (DENTSPLY Maillefer).
2. The upper two-thirds was prepared using S1 and S2 files from Pro Taper system (DENTSPLY Maillefer).
3. The apical third—20 (04) GTX file (DENTSPLY Maillefer).

Throughout the whole procedure, irrigation with Citric acid (40%, Cerkamed, Poland) and NaOCl (2%, Cerkamed, Poland) was used.

We preferred S1 and S2 files because of their ability to brush against the canal wall, which is very useful in cases with oval cross sections, where it is of paramount importance to clean all aspects of the root canal spaces. For the apical one third we choose landed GTX file, because the canal was very narrow and we wanted to eliminate the possibility to transport the apical foramen. Both artificial and true canal were obturated using warm vertical compaction of gutta-percha and MTA-based sealer (FillApex, Angelus, Brazil). On the post-op radiograph, the preparation and obturation seem short, but this was the reading we repeatedly got with our apex locator (RayPex5, VDW, Germany) (Fig. 7).

After the completion of the endodontic retreatment, the pre-endodontic buildup was left at place and the endodontic access was restored again with SDR, creating a core, on which an onlay preparation with diamond burs (Mani Inc.) was performed (Figs. 8 & 9). The enamel margins were exposed and unsupported enamel prisms were removed using fine-grit diamond points. The remaining tooth structure was prepared to create a butt-joint with the restoration margins. Internal line angles were rounded and the walls provided 5- to 15-degree path of divergence. The proximal boxes

preparations extended to the existing composite, since they were located in the dentin.

The dimensions of the preparation provided at least 2 mm interocclusal clearance, which could be verified on the impression. A condensable silicone impression was taken (Fig. 10). A custom made provisional restoration was created using direct technique and temporarily cemented with a non-eugenol luting agent (Temp-Bond NE) (Fig. 11). The fitting aspect of the restoration was sandblasted by the dental technician.

At the second appointment after assessment of the prepared restoration, removal of the provisional and cleaning of the preparation the fit and aesthetics of the onlay were evaluated. Rubber dam was placed and the preparation was cleaned with acetone, etched with 37 per cent phosphoric acid for 15 seconds, rinsed and dried. The fitting aspect of the restoration was also cleaned with acetone prior to cementation. A dual-cure self-adhesive luting resin (SmartCem2, DENTSPLY) was applied to the walls of the preparation and the restoration was placed with firm pressure until fully seated. The excess cement was removed with an explorer, a #12 scalpel blade and dental floss in the interproximal area after five-second polymerization that brought the cement to a "rubbery" stage (Figs. 12 & 13). The restoration was covered with glycerin and finally cured for 60 seconds from each side (Figs. 14 & 15). The minimal occlusal adjustments were done with fine diamond burs under water coolant. Finishing and polishing were accomplished with the Enhance system (DENTSPLY) (Fig. 16).

Once finishing and polishing was done, a 37 percent phosphoric acid gel was applied for 15 seconds to clean the surface of the restoration and to acid etch the marginal enamel. After washing and drying, the nanofilled adhesive (Prime&BondNT, DENTSPLY) was applied and permitted to rest for 10 seconds to permeate the surface and margin fissures created by the finishing process. The adhesive was then thinned with air and polymerized for 40 seconds (Fig. 17). At the six-month recall, the tooth was asymptomatic and the patient was completely satisfied (Figs. 18, 19).



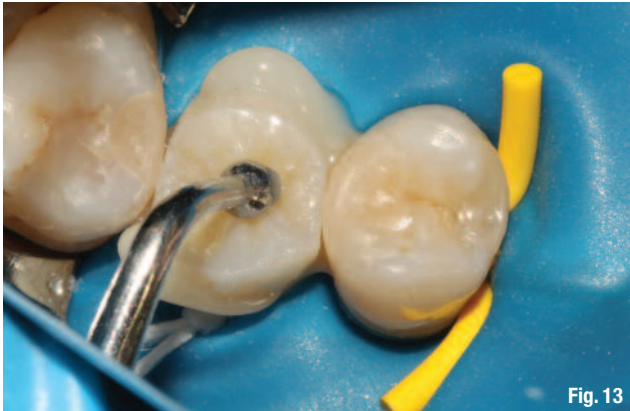

Fig. 13

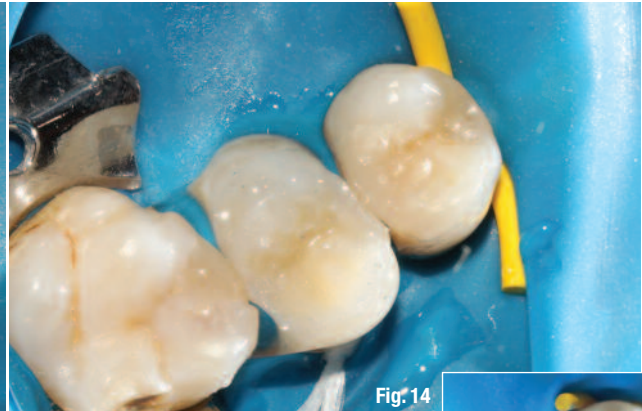


Fig. 14

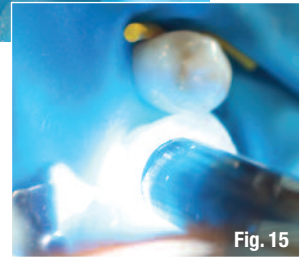


Fig. 15

## Discussion

This case report demonstrates endodontic retreatment and composite onlay as definitive restoration for a compromised tooth with minimal coronal tooth structure.

The two most important factors in terms of prognosis of treatment of perforations are the age of the lesion and degree of bacterial contamination.<sup>13</sup> In our case, the previous endodontic treatment was done four years ago. The long period of time is not favourable for the prognosis, but since the perforation is in the apical third the likelihood of bacterial contamination is low. After the patient has been informed, he chooses orthograde endodontic retreatment as a treatment modality.

The material of choice for perforation repair is MTA (mineral trioxide aggregate). Because of the small size and apical position of the lesion, we decided to treat it like a second canal and to obturate with gutta-percha and MTA based sealer. The absence of worsening of the periapical conditions in the six months post-op X-ray (Fig. 19) supports this approach, and the patient is still under observation.

Although still debatable, recent comprehensive meta-analysis by Gillen et al.<sup>6</sup> demonstrates that a

well-fitting, bacteria-proof final restoration has the same importance for the long-term prognosis of the endodontically treated tooth as does the well-performed endodontic therapy. Besides the prevention of coronal microleakage, a key factor for the long-term survival of an endodontically retreated tooth appears to be the amount of remaining tooth substance,<sup>14</sup> which is determined by the dimensions of the final restoration. So an ideal treatment option for an endodontically retreated tooth seems to be adhesively bonded restoration that preserves as much of the tooth structure as possible.

An endodontically treated posterior tooth presenting with extensive decay is most frequently restored with a post and a crown. That is intelligible, because crowns are a well-established and known, clinically proven restorative modality, and still a considerable amount of research is being performed in this direction.<sup>15</sup> On the other hand, partial tooth-coloured restorations are recognized as valuable alternatives to full coverage crowns, and questions are raised if intracanal posts are necessary at all for an endodontically treated tooth.

Since their introduction in 1980,<sup>16</sup> indirect laboratory processed composites are being continuously improved in their physical and mechanical properties. Now this restorative option offers ad-

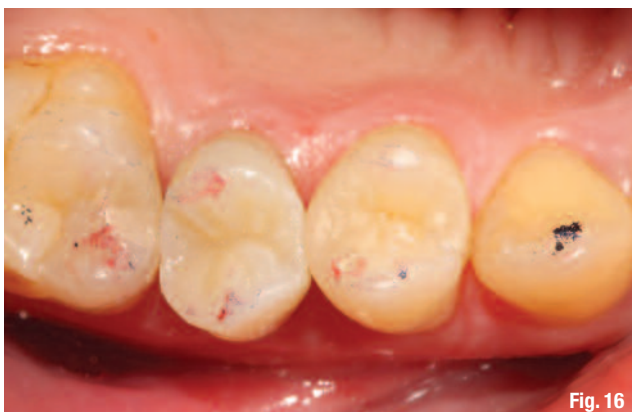

Fig. 16

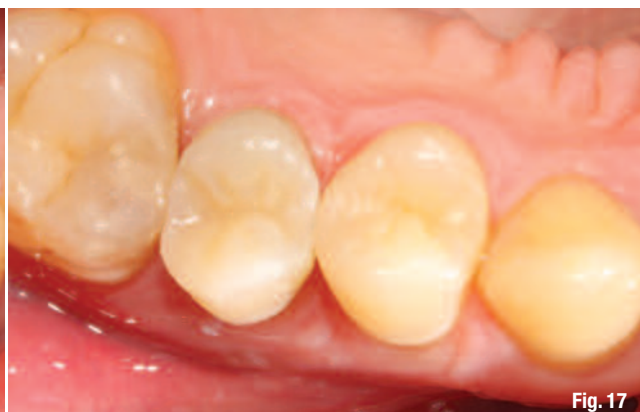

Fig. 17