issn 1616-7390

Vol. 3 • Issue 2/2009

cosmetic dentistry _ beauty & science

2 2009

_special
Orthodontic surgery and aesthetics

_industry report
Simplified digital impression-taking

_meetings
IDS review

THE ASIAN ACADEMY OF AESTHETIC DENTISTRY EST. 1990

SOUTH ASIAN ACADEMY OF AESTHETIC DENTISTRY SAAD 2005

dti] Dental Tribune International

BEAUTY – COMPOSE IT!

AMARIS

Highly aesthetic restorative

- Two simple steps
- Layers like in nature
- Brilliant results
- Now available in Gingiva shades

THE DENTAL ADVISOR ++++½

MADE IN GERMANY 100%

31st ASIA PACIFIC DENTAL CONGRESS 2009 HONG KONG

Please visit us at
Asia Pacific Dental Congress
Hong Kong · 07.-11.05.2009 · Stand AA06

VOCO THE DENTALISTS

VOCO GmbH · P.O. Box 767 · 27457 Cuxhaven · Germany · Tel. +49 (4721) 719-0 · Fax +49 (4721) 719-140 · www.voco.com

Dear Reader,

Dr So-Ran Kwon
Co-Editor-in-Chief

_**I sincerely appreciate the enthusiastic support** of our authors for the second edition of cosmetic **dentistry** . Since we began, we have striven to fulfil the needs of our valued readers, by providing innovative and informative articles on clinical techniques and new dental technologies. So far, we have received very positive and encouraging feedback from many supporters. We are certainly grateful to have established a well-suited and efficient team in such a short time.

Cosmetic and implant dentistry have without a doubt become of central interest, attracting the interest of many dentists worldwide. At many important academic seminars or conventions, the main theme is directly or indirectly related to these two specialities. This trend is expected to be even more pronounced in the future. Dental education, from undergraduate programmes to graduate programmes and continuing education courses, exhibits a continual shift towards cosmetic and implant dentistry.

The number of patients in need of cosmetic and implant procedures is steadily increasing. I have personally witnessed this boom in Europe, Asia and the US during my international lectures and have been informed of it through regular feedback from dentists and dental hygienists. If we are to satisfy our patients' needs, additional skills and knowledge are essential.

In this edition, you will find solutions for quality and cosmetic restorations on natural teeth and implants. Our industry reports introduce innovative materials and devices that will make your clinical work not only more precise, but also much easier. I am confident that the more knowledge we have on cosmetic dentistry, the greater our success in our dental practices will be.

I hope you will enjoy this edition of cosmetic **dentistry**, and look forward to receiving your valuable feedback!

Sincerely yours,

Dr So-Ran Kwon
Co-Editor-in-Chief
President Korean Bleaching Society
Seoul, Korea

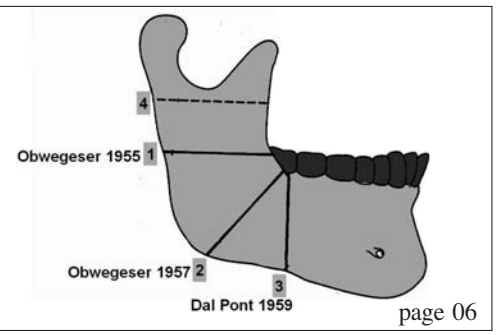

page 06

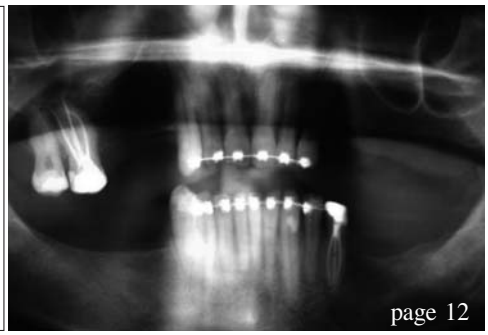
page 12

page 22

editorial

03 Dear Reader
_ So-Ran Kwon, Co-Editor-in-Chief

special

06 Orthodontic surgery and aesthetics
_ Nezar Watted et al.

case study

12 Fixed prosthodontic management of a mutilated dentition: A team approach
_ Helena Lee & Ansgar Cheng

clinical technique

18 Replacement of a faulty posterior restoration
_ Sushil Koirala

industry report

22 Simplified digital impression-taking
_ Helmut Götte

26 The new NobelProcera system for clinical success: The next level of CAD/CAM dentistry
_ Hans Geiselhöringer & Stefan Holst

32 Aesthetics with all-ceramics and tooth whitening
_ Marcus Striegel

36 Learning and applying the Natural Layering Concept
_ Didier Dietschi

industry news

44 Amaris Gingiva — A beautiful smile, naturally

meetings

46 IDS flourishes despite economic trouble
_ Daniel Zimmermann

48 Cosmetic events

about the publisher

49 _submissions
50 _imprint

Cover image courtesy of coltène whaledent.

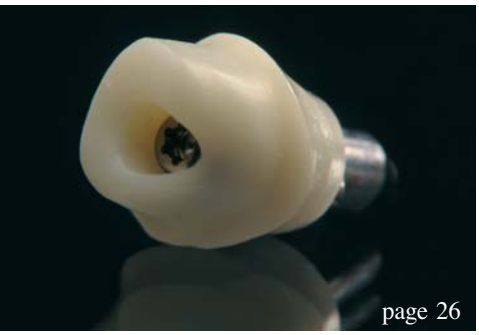
page 26

page 32

page 46

Partner in
Direct Cosmetic Restoration

- Precise Tooth Preparation
- Contouring & Finishing

New Kit in Town!

For more details, please contact your nearest dealer TODAY!

SHOFU INC.
SINGAPORE BRANCH 10 Science Park Road, #03-12 The Alpha Science Park II, Singapore 117684
Tel (65) 6377 2722 Fax (65) 6377 1121 eMail *mailbx@shofu.com.sg* website *www.shofu.com.sg*

Orthodontic surgery and aesthetics

Author_ Prof Nezar Watted, Prof Josip Bill, Dr Ori Blanc & Dr Benjamin Schlomi, Germany & Israel

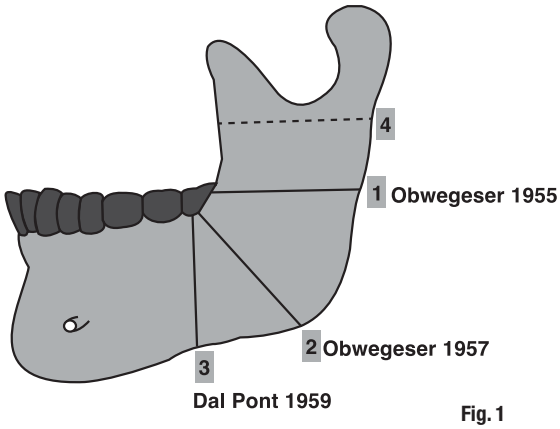

Fig. 1

Fig. 1_Diagrammatic representation of the osterotomy lines on the outer (continuous line) and the inner compacta (dashed line) of the mandible; 4 = inner saw cut above the *N. mandibularis*.

Figs. 2a & b_Lateral view of the 25-year-old male patient, showing lower facial retrusion diagonally forward. The frontal view shows the right-sided deviation due to the laterognathia. The upper-lip vermillion is relatively weakly developed (b).

_Orthodontic treatment generally follows aesthetic, functional, and prophylactic objectives, where individual aspects of isolated cases are accorded varying importance as they arise. Increasing aesthetic expectations and awareness of modern dental treatment options disseminated by the media have resulted in increased interest and greater willingness of adults to consider orthodontic treatment. Aesthetic orthodontics is thus primarily adult orthodontics.

A peculiarity of orthodontic treatment in adults compared with paediatric or adolescent orthodontics is the age-associated involution of the connective tissues that leads to a reduction in cell density, thickening of the fibre bundles, delayed fibroblast proliferation, and reduced vascularisation. These are the causes of slower dental movement and delayed tissue and bone reactions. Absent sutural growth, the age of the periodontium, specific periodontal diagnoses, and tissue atrophy also make treatment in adults particularly challenging.

As a rule, aesthetically oriented adult orthodontics therefore has an interdisciplinary inclination. Occlusion, function and aesthetics are considered to be equivalent parameters in modern orthodontics and particularly here in combined orthodontic-maxillofacial surgical treatment.[32,33] This was achieved through optimisation of diagnostic tools and further development and increasing experience in orthopaedic surgery.[4]

Nowadays, treatment of adult patients with dental malposition and mastication impairment is one of the standard tasks of the orthodontist. If the discrepancies in spatial allocations of the upper and lower dentition are particularly pronounced and where the cause is primarily skeletal and not only dentoalveolar, conventional orthodontic therapy is limited and combined orthodontic-surgical therapy is indicated for remodelling of the jaw bases.

Treatment for a skeletal dysgnathia (Class III) using combined orthodontic-maxillofacial surgical correction is discussed in this article.

_Chronological development of maxillofacial surgery of the mandible

The first orthodontic-maxillofacial surgical procedure on the mandible described in the literature was that of the American surgeon Hullihen in 1848.[13] This procedure was a segmental osteotomy of the anterior

mandible (a posterior shift [retrusion] of a protruding mandibular alveolar process, following a burn injury). Towards the end of the 19th century, the method of orthodontic-maxillofacial surgical correction of dysgnathias by surgical retrusion or protrusion of the mandible was revisited. Jaboulay[14] described resection of the *Processus condylaris* and Blair[4], osteotomy on the *Corpus mandibulae*. The continuity resection in the horizontal branch by Blair was the first surgical prognathism procedure. The patient first visited the dentist Whipple in St. Louis in 1891 and was then referred to the then most renowned orthodontist Dr Edward Hartley Angle[2], who ultimately recommended the surgical procedure mentioned above.

Six years later, the procedure in this osteotomy on the *Corpus mandibulae* was also published by the Hamburg surgeon Floris.[11] Parallel with this development in the US, Von Auffenberg[3] in Europe conceived a step-by-step osteotomy for correcting a mandibular retrusion, which was performed by Von Eiselberg in 1901.

Figs. 3a–e_Clinical situation before the start of treatment.

Fig. 4_The cephalometric X-ray shows the disharmonious arrangement in the vertical axis. The lower face shows an approx. 60 per cent enlargement in relation to the upper face.

Fig. 3a

Fig. 3b

Fig. 3c

Fig. 3d

Fig. 3e

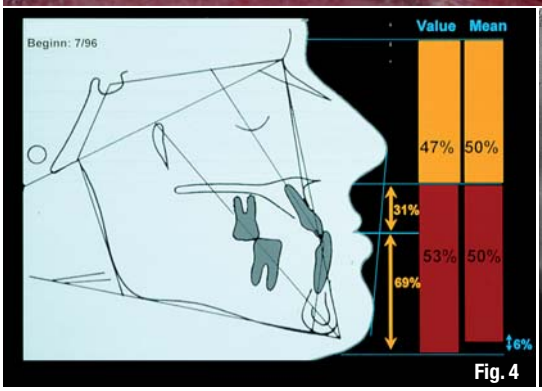

Fig. 4

Fig. 5

Fig. 5_Orthopantomographic image before the start of orthodontic treatment. An apical lucency at tooth 31. Pronounced maxillary-antrum expansion between teeth 25 and 27. Orthodontic closure of the gap is difficult.
Figs. 6a–c_Situation after orthodontic preparation for the surgical procedure.
Figs. 7a–e_Occlusion at the end of treatment; there is a neutral stable occlusion with physiological anterior bite in the sagittal and vertical axes and a correct midline (a–c). Monitoring images of the upper and lower jaws. A ceramic bridge was made in the lower jaw (d & e).

Fig. 6a

Fig. 6b

Fig. 6c

Fig. 7a

Fig. 7b

Fig. 7c

Fig. 7d

Fig. 7e

The era of orthodontic surgery in Europe began only after World War I. The experience gained there led to a substantial extension of the indications for orthodontic-maxillofacial surgical procedures, as well as to the transferral of this surgical technique to the area of elective procedures.[5,6,16–18,24] In the early 1920s, Bruhn and Lindemann set transversal osteotomy of the *Ramus mandibulae* as the standard method at the time for the surgical correction of mandibular prognathism. This method, which continued to have many adherents well into the 1960s, is today known as the Bruhn–Lindemann procedure.[1,6,25,45]

In 1935, Wassmund, who saw its drawbacks in a possible dislocation of the proximal segment by the muscles inserted there, described a modification of the Bruhn–Lindemann surgical technique.[26] In the early 1950s, a new era in orthodontic surgery of the mandible was begun with Kazanjian's resumption[12,15,23] of the technique of transverse, oblique severing of the ascending ramus, first performed by Perthes in 1922.[22] Shuchard modified this method in 1954 by enlarging the bony insertion surface, and in 1955 Obwegeser introduced sagittal splitting at the horizontal ramus of the mandible. He shifted the buccal osteotomy line

_contact cosmetic dentistry

Prof Nezar Watted
Wolfgangstraße 12
97980 Bad Mergentheim
Germany
E-mail:
nezar.watted@gmx.net

obliquely from the last molar to the posterior margin of the jaw angle.[19–21] In 1959, Dal Pont moved this buccal osteotomy line from the last molar to the inferior margin of the mandible.[8,9] Since then, this method of sagittal split at the mandible has been called *sagittal split* according to Obwegeser–Dal Pont (Fig. 1). Epker[10] developed the incomplete *sagittal split* into a routine method.

_Clinical case presentation

History and diagnosis

A 25-year-old patient presented on his own initiative. He complained of functional (impairment of mastication and jaw joint pain) and aesthetic impairment (sunken face with facial asymmetry). He had undergone orthodontic treatment between the ages of 8 and 15 and reported pain in the area of the anterior mandible.

The lateral image showed a retrusive lower face inclined forward with mid-facial hypoplasia—regio infraorbitale—a flat upper lip and an elongated lower face compared with the mid-face—47% : 53% instead of 50% : 50%[29] (Table I; Fig. 2a). Owing to the negative sagittal overjet, there was a positive lower lip step. The frontal image shows mandibular deviation (laterognathia) to the right, which can be traced to growth asymmetry in the jaw (Fig. 2b). In addition, there was a Class III dysgnathia angle with conspicuous mandibular midline deviation to the right, frontal and right lateral crossbite, anterior mandibular labial tilt, and a steep anterior mandible. Tooth 26 had been missing for some time (Figs. 3a–e). FRS analysis (Table I & II) clearly shows the strongly sagittal and relatively weak vertical dysgnathia both in the soft-tissue profile and in the skeletal region. The parameters indicated a mesiobasal jaw relationship and a growth pattern with an anterior course: the vertical grouping of the soft-tissue profile showed a disharmony between the mid-face and the lower face (G'-Sn : Sn-Me'; 47% : 53%). This was relatively weakly expressed in the bony structures (N-Sna:Sna-Me; 44% : 56%). In the region of the lower face there was also mild disharmony (Sn-Stm : Stm-Me'; 31% : 69%). Complementary assessment of the mandible showed that the area from the *subnasal-labral inferius* to the soft-tissue chin (Li-Me'), which should have been 1 : 0.9, was shifted in favour of the Li-Me' part (0.9 : 1; Fig. 4).The panoramic image showed a lucency of teeth 31 and 41. A root canal procedure followed by root apex resection was thus performed (Fig. 5).

_Therapeutic objectives and treatment planning

The objectives of this combined orthodontic-maxillofacial surgical treatment were:

1. the establishment of neutral, stable, and functional occlusion with physiological condylar positioning;
2. the optimisation of the facial aesthetics;
3. the optimisation of the dental aesthetics, considering the periodontal situation;
4. the assurance of the stability of the results achieved;
5. meeting the patient's expectations.

The improvement of the facial aesthetics not only in the sagittal axis in the region of the lower face (the mandibular region), but also in the region of the mid-face (hypoplasia) and in the transverse axis should be noted as specific treatment objectives. The change in the region of the mid-face was intended to affect the upper lip and the upper-lip vermillion. These treatment objectives were achieved by two procedures:

1. a dorsal extension of the mandible with lateral sweep to the left for correction of the sagittal and transverse defects, as well as occlusion and the soft-tissue profile;
2. bone augmentation in the mid-face for harmonisation of the face. It would not have been possible to achieve

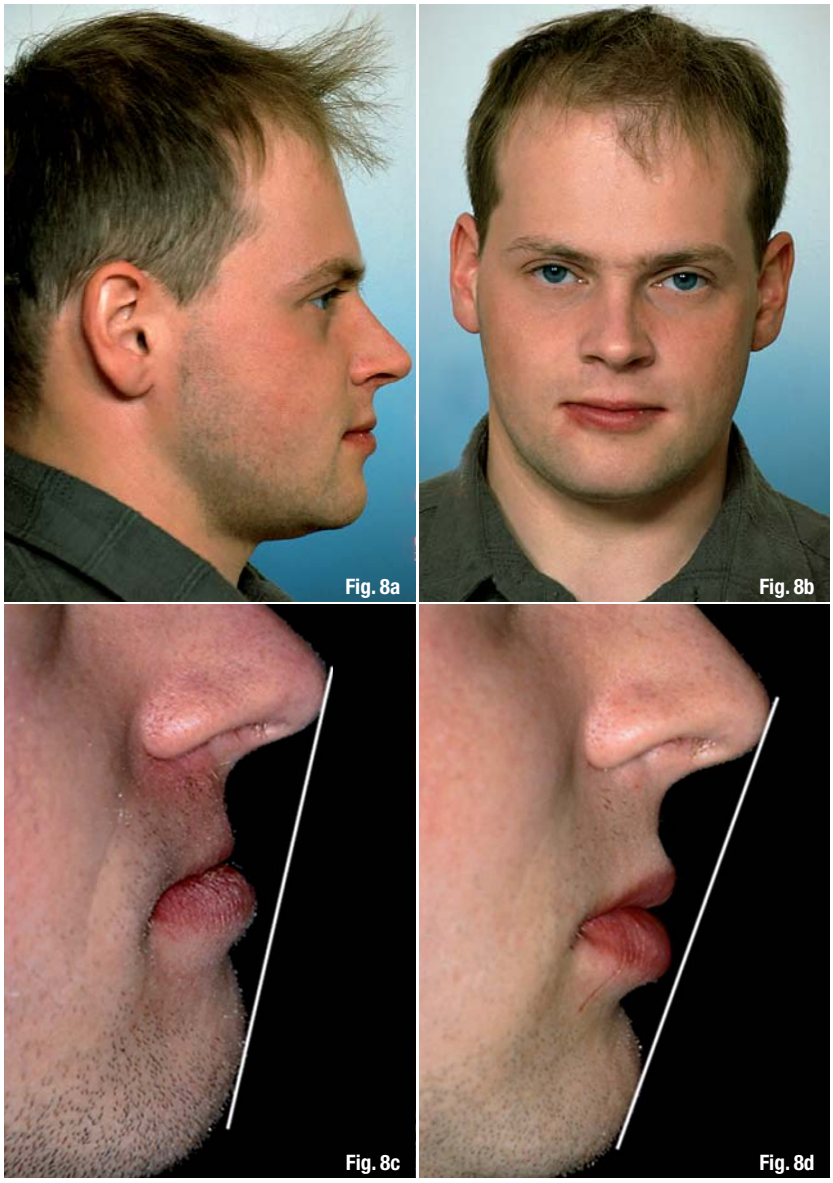

Figs. 8a–d_The extra-oral treatment results. The sagittal, vertical and transverse were corrected (a & b). Change in the oral profile: left pre-op, right post-op (c & d).