



**LAB TRIBUNE**


“Dental Technicians are more than just trained hands”

>Page 1B

**mCME**

“Bleach Cases From Dead white to Natural brights”

>Page 6



**DENTAL FACIAL**

6th Dental Facial Cosmetic Int'l Conference  
14-15 November 2014

Jumeirah Beach Hotel, Dubai



Turin with Mole Antonelliana and the Alps in the background.

## DTI publishers meet for tenth anniversary in Italy

By Dental Tribune International

**TURIN, Italy:** Over the last three days, Dental Tribune International (DTI) has held its tenth annual publishers' meeting. This year, the meeting drew over 50 licence partners from the US, Latin America, the Middle East and many other countries from all over the

world. Meeting attendees learnt about a number of new projects for the upcoming year and discussed strategic approaches for future development.

At the meeting, DTI CEO Torsten Oemus reviewed the impact of DTI's various print, online and

> Page 4

## Sirona presents “CEREC Desert Fest 2014”

By Sirona

The latest findings in digital dentistry, live demonstrations, and an exciting social program: Sirona and the Centre For Advanced Professional Practices (CAPP) invite you to the “CEREC Desert Fest” conference. The event held in Dubai from September 12-13 is aimed at potential CAD/CAM users and experienced CEREC users.

In front of breathtaking scenery at the Palace Downtown Dubai, Sirona presents the “CEREC Desert Fest” for the very first time. On September 12 and 13, dentists and dental technicians can share their experience with the most used CAD/CAM system with colleagues from all over the world. The

event features a number of expert presentations followed by panel discussions as well as live demonstrations of CEREC in various areas. Dr. Joachim Pfeiffer, Vice President CAD/CAM Systems and Chief Technology Officer at Sirona, says “this first-class event combines specialist knowledge with user experiences. We expect this interesting conference to contribute greatly to the further development of CEREC.”

The panel show focuses on presentations by experts on the use of CEREC. Dr. Todd Ehrlich, a master CEREC trainer who has been teaching dental CAD/CAM technology for a number of years, provides an

> Page 4



Fig. 1: Dubai's skyline and the spectacular Dubai Fountain – highlights of the visit to the largest city in the United Arab Emirates.

**NEWS**

Page 2

“The Ebola virus epidemic: A concern for dentistry?”

Page 26

“Crown for the queen of the jungle”

**ENDO TRIBUNE**

Page 18

“Empirical comparative study confirms thixotropic wound dressing for haemostasis”

**ORTHO TRIBUNE**

Page 20

“Pre-Align then Design”

Page 22

“Ormco Custom: It's all about profitability”

**LAB TRIBUNE**

Page 1B

“Dental Technicians are more than just trained hands”

Page 2B

“Milling and grinding in high definition (HD)”

**HYGIENE TRIBUNE**

Page 1C

“A Date for your - Diary Hygiene Day announcement “

Page 2C

“Developing Oral Care Products Imaging and Innovation”

# The Ebola virus epidemic: A concern for dentistry?

By Prof. L. Samaranayake

Twenty-two years ago, a seminal report from the Institute of Medicine (IOM) in the US, titled "Emerging Infections: Microbial Threats to Health in the United States", warned of the dangers of so-called newly emerging and re-emerging diseases. The concept of "emerging infectious diseases", introduced then by the IOM is now well entrenched, and to our chagrin we have witnessed many such diseases over the last two decades. These include variant Creutzfeldt-Jakob disease/bovine spongiform encephalopathy,

Roman and Persian writers documented the emergence of many new epidemics. In more recent times, the scientist Robert Boyle presciently observed in 1865 that "there are ever new forms of epidemic diseases appearing [...] among [them] the emergent variety of exotic and hurtful [...]". Arguably though, the most noteworthy relatively new emerging infectious disease with the greatest impact on the dental profession has been the human immunodeficiency virus and Aids. And now we have a severe epidemic of Ebola virus infection. It is back with a vengeance, this time in West Africa, with over

behaviour, including injectable drug abuse and sexual promiscuity. Societal occurrences, such as economic impoverishment, war and civil conflict, too are critical according to the IOM. The current outbreak of Ebola virus infection is a perfect storm created by a lethal combination of these factors, including rampant deforestation, poverty and the war-stricken situation in many African countries.

So how does Ebola spread? According to World Health Organization reports, Ebola virus disease (EVD) is introduced into the human population through

through saliva contamination. Infection in health care settings has been due to health care workers treating patients with suspected or confirmed EVD, especially when infection control precautions were not strictly practised. Reports indicate that those who recovered from the disease could transmit the virus through their semen for up to two months after recovery.

EVD is a severe acute illness characterised by the sudden onset of fever, intense weakness, muscle pain, headache and sore throat. This is followed by vomiting, diarrhoea, rash, impaired kidney and liver function, and both internal and external bleeding in some cases. Oral manifestations, such as acute gingival bleeding, have been reported. The mortality rate of EVD is very high and 50-90% of patients die owing to the profound systemic haemorrhage or its complications. The incubation period of EVD is 2 to 21 days.

Up to now, there have been no reported cases of transmission of EVD in any dental settings. However, the fact that it is transmitted through human secretions, which includes saliva, and that the incubation period could last up to 21 days implies that dental care workers in the endemic areas of the virus, such as West Africa and sub-Saharan Africa, may run the risk of acquiring the disease if strict standard infection control measures are not routinely followed.

In dentistry, we are constantly exposed to these emerging and re-emerging infectious threats and we cannot afford to let our guard down. Vigilance, awareness and good clinical practice with standard infection control at all times are fundamental to prevention, as yet-unimagined new diseases surely lie in wait. Although we have made spectacular technical and scientific advances since the release of the original IOM report some two decades ago, it appears that humans are still defenceless in the face of the relentless march of our microbe foes. drug-resistant tuberculosis. [D1](#)



A laboratory worker in the Democratic Republic of Congo does a test using a micropipette. Quick on-site laboratory diagnosis enable the World Health Organization response team to precisely diagnose new suspected Ebola patients within two to six hours. (Photograph courtesy of WHO/Christopher Black)

severe acute respiratory syndrome, and Middle East respiratory syndrome, and above all the pandemic of acquired immune deficiency syndrome (Aids), which has claimed millions of lives the world over. The re-emerging infectious diseases we have seen include diseases caused by methicillin-resistant Staphylococcus aureus, and multidrug-resistant and extensively

Interestingly, the concept of "emerging infectious diseases" is not new. Indeed ancient Greek,

580 cases and a 69% case fatality ratio at the time of writing. The culprit is the Zaire ebolavirus species, the most lethal Ebola virus known, with case fatality ratios up to 90%.

According to the IOM report, there are many reasons that new diseases emerge and re-emerge. These include health care advances with the attendant problems (e.g. transplantation, immunosuppression, antibiotic abuse, and contaminated blood and blood products) and human

close contact with the blood, secretions, organs or other bodily fluids of infected animals. Human-to-human transmission is through direct contact (through broken skin or mucous membranes) with the blood, secretions, organs or other bodily fluids, such as saliva, of infected people, and indirect contact with environments contaminated with such fluids. Transmission through the air has not been documented in the natural environment, nor have there been any case reports of transmission

## Malaysia provides dental records for MH17 investigation

By DT Asia Pacific

**PUTRAJAYA, Malaysia:** The Health Minister of Malaysia has confirmed that the dental records of all of the Malaysian victims of Malaysia Airlines Flight 17 have been collected and sent to the Netherlands for forensic identification. According to Datuk Seri Dr Subramaniam s/o K.V. Sathasivam his ministry has also provided DNA samples and fingerprints of the deceased passengers of the flight, which was bound for Kuala Lumpur on 17 July, to an Interpol disaster response team.

Forty-three Malaysian passengers, including 15 crew members, were on board the Boeing, which is believed to have been shot down by pro-Russian rebels over Donetsk in Ukraine three weeks ago. Since access to the crash site remains difficult owing to ongoing conflict in the region, only 70 coffins containing the remains of the victims have been collected and sent to the Netherlands so far, according to Subramaniam. He told the New Strait Times newspaper in Kuala Lumpur that the first results from the identification process,



International investigators survey the MH17 crash site, 5 August 2014. (Photograph courtesy of OSCE/Evgeniy Maloletka)

which is currently underway at a military facility in Heesum near Amsterdam, are expected to be available within the next two weeks.

A total of 298 passengers, most

of whom were of Dutch descent, were killed in the incident, which is still under investigation by international organisations, such as the Organization for Security and Co-operation in Europe. [D1](#)

### DENTAL TRIBUNE

The World's Dental Newspaper - Middle East & Africa Edition

#### GROUP EDITOR

Daniel Zimmermann  
newsroom@dental-tribune.com  
+49 341 48 474 107

#### CLINICAL EDITOR

Magda Wojtkiewicz

#### ONLINE EDITORS

Yvonne Bachmann  
Claudia Duschek

#### COPY EDITORS

Sabrina Raaff  
Hans Motschmann

#### PUBLISHER/PRESIDENT/CEO

Torsten Oemus

#### CHIEF FINANCIAL OFFICER

Dan Wunderlich

#### BUSINESS DEVELOPMENT MANAGER

Claudia Salwiczek

#### EVENT MANAGER

Lars Hoffmann

#### MARKETING SERVICES

Nadine Dehmel

#### SALES SERVICES

Nicole Andrä

#### EVENT SERVICES

Esther Wodarski

#### MEDIA SALES MANAGERS

Matthias Diessner (Key Accounts)  
Melissa Brown (International)  
Peter Witteczek (Asia Pacific)  
Maria Kaiser (North America)  
Weridiana Mageswki (Latin America)  
Hélène Carpentier (Europe)

#### ACCOUNTING

Karen Hamatschek  
Anja Maywald

#### EXECUTIVE PRODUCER

Gernot Meyer

#### DENTAL TRIBUNE INTERNATIONAL

Holbeinstr. 29, 04229 Leipzig, Germany  
Tel.: +49 341 48 474 502  
Fax: +49 341 48 474 175  
info@dental-tribune.com  
www.dental-tribune.com

#### REGIONAL OFFICES

##### ASIA PACIFIC

Dental Tribune Asia Pacific Ltd.  
Room A, 20/F, Harvard Commercial Building,  
105-111 Thomson Road, Wanchai, Hong Kong  
Tel.: +852 5115 6177  
Fax: +852 5115 6199

##### THE AMERICAS

Tribune America, LLC  
116 West 25rd Street, Ste. 500, New York, N.Y. 10011, USA  
Tel.: +1 212 244 7181  
Fax: +1 212 244 7185

#### DENTAL TRIBUNE MIDDLE EAST & AFRICA

#### EDITION EDITORIAL BOARD

Dr. Aisha Sultan Alsuwaidi, UAE  
Dr. Ninette Banday, UAE  
Dr. Nabeel Humood Alsabeeha, UAE  
Dr. Mohammad Al-Obaida, KSA  
Dr. Meshari F. Alotaibi, KSA  
Dr. Jasim M. Al-Saeedi, Oman  
Dr. Mohammed Sultan Al-Darwish  
Prof. Khaled Balto, KSA  
Dr. Dobrina Mollova, UAE  
Dr. Munir Silwadi, UAE  
Dr. Khaled Abouseada, KSA  
Aiham Farah, CDT  
Dr. Rabih Abi Nader, UAE  
Dr. George Sanoop, UAE  
Retty M. Mathew, UAE  
Rodny Abdallah, Lebanon  
Victoria Wilson, UK

#### PARTNERS

Emirates Dental Society  
Saudi Dental Society  
Lebanese Dental Society  
Qatar Dental Society  
Oman Dental Society

#### DIRECTOR OF mCME

Dr. Dobrina Mollova  
mollova@dental-tribune.me  
+971 50 42 45072

#### BUSINESS PARTNER | BDM

Tzvetan Deyanov  
deyanov@dental-tribune.me  
+971 55 11 28 581

#### DESIGNER

Kinga Romik  
k.romik@dental-tribune.me

14-15 NOVEMBER 2014  
JUMEIRAH BEACH HOTEL  
DUBAI UAE

# 6<sup>TH</sup> DENTAL - FACIAL COSMETIC INTERNATIONAL CONFERENCE

*Joint Meeting with*

# 3<sup>RD</sup> GLOBAL CONFERENCE OF AMERICAN ACADEMY OF IMPLANT DENTISTRY

ORGANIZED BY



**CAPP**



CO-ORGANIZED



MEDIA

**dt** Dental  
Tribune  
MEA

[www.dental-tribune.me](http://www.dental-tribune.me)

**ADA CERP** | Continuing Education  
Recognition Program

Course for dental practitioners in the field of Implant Dentistry  
ADA CERP is a program of the American Dental Association designed to provide  
a continuing education program for dental practitioners. ADA CERP does not ap-  
prove or endorse individual courses or instructors nor does it imply sponsorship of a course  
by any of its members.

[www.cappmea.com/aesthetic2014](http://www.cappmea.com/aesthetic2014)

&lt; Page 1



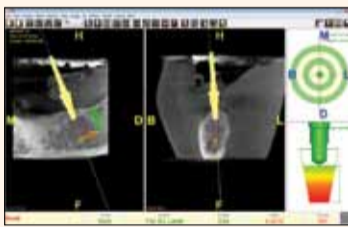
DTI held its tenth publishers' meeting in Turin. (Photograph: Daniel Zimmermann, DTI)

educational portfolio over the past decade. He pointed out that the company's educational offerings in particular have become an essential part of DTI's product portfolio. Besides its flagship

e-learning platform, the Dental Tribune Study Club, and customised campuses for important dental companies, such as Colgate, DTI provides continuing medical education through its

Tribune CME Clinical Masters programmes, which offer comprehensive training in aesthetic dentistry, orthodontics and implantology, among other fields of dentistry. To date, about 200 dental professionals have graduated from the programmes. Oemus also informed the attendees of a new partnership with the Brazilian Dental Association, the largest dental association in the world. Through this collaboration, DTI will provide dental education to a vast number of dental professionals in Brazil through a special DT Study Club from September this year. **DTI**

## Implant Real-time Imaging System (IRIS-100)



Implant Imaging System (IRIS-100)

By EPED

**I**mpant Real-time Imaging System (IRIS-100) features the utilization of optical tracking systems to visualize instantly the implant handpiece and drill with a CBCT image. With the aid of this intra-bone GPS function, users can see the position of the drill and data such as

bone quality, nerve, sinus location and more. This critical data can assist the implantologists to navigate and give real time guidance during implant surgery. Similar to a car navigation system, the system is set up to visualize the destination and helps to guide the preplanned placement of implants, avoiding dangerous areas, reducing risk and increasing the likelihood of successful implant surgery. **DTI**

## IDS 2015: Digital technology determines daily routine in modern dental practice

By Dental Tribune International

**C**OLOGNE, Germany: Digital dental procedures are increasingly becoming an essential part of the daily routine in the modern dental practice. They render patient management and treatment planning processes more economical and increase time efficiency. At the upcoming International Dental Show (IDS), digital technologies will thus form a core subject, with many exhibitors presenting their latest product solutions in the field.

At IDS 2015, the digital technology offerings available for dental practices will form a focal point for all visitors in the fields of dentistry and dental technology. The product ranges to be exhibited contribute to simplifying work-

flows and, as a result, to reducing treatment times. They create synergies with the digital range for dental laboratories, yielding positive implications for practice management and therapeutic procedures. That is why the state of the art in digital technology for

digital imaging devices, including CBCT and CT, which have been used alongside conventional radiographic techniques in recent years.

IDS 2015 will also give special attention to digital scanners, which

*"1,400 exhibitors from 46 countries have already confirmed their participation."*

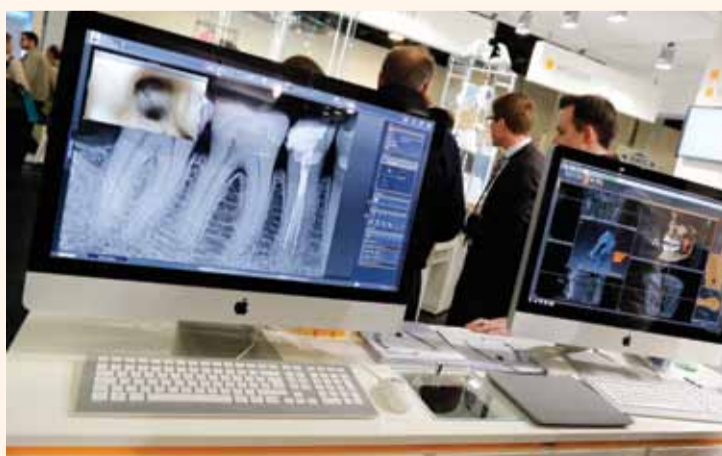dental practices will be a major topic at IDS 2015, said Dr Martin Rickert, Chairman of the Association of German Dental Manufacturers.

Products presented will include software for efficient patient management and integrated treatment planning, as well as

offer a wide range of advantages for patient-specific restorations and implant planning. In particular, intra-oral scanners will be in the spotlight, as they have contributed significantly to making prosthetic treatment workflows simpler and more precise.

Overall, both patients and dentists benefit from the use of digital technologies. They help shorten treatment time and reduce the number of work stages, and enable the dentist to immediately examine and explain preparations on screen. Furthermore, the data gained through digital procedures can be quickly processed in the dental practice and sent to dental laboratories.

The 36th IDS will take place from 10 to 14 March 2015 in Cologne. According to the latest figures provided by IDS organiser Koelnmesse, 1,400 exhibitors from 46 countries have already confirmed their participation. **DTI**



Many manufacturers will be exhibiting their latest innovations in digital dental technology at IDS 2015. (Photograph courtesy of Koelnmesse)

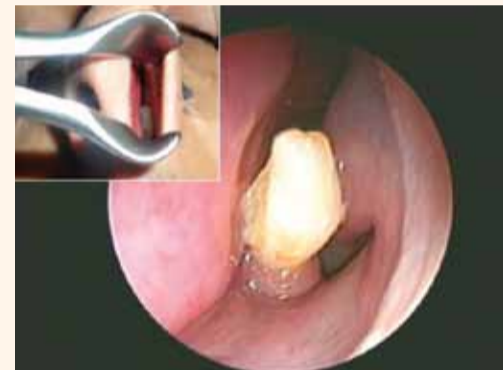## Supernumerary Tooth Grows in Man's Nose

By Dental Tribune International

**D**HAHRAN, Saudi Arabia: Surgeons in Saudi Arabia have found a white bony mass inside the nose of a 22-year-old. They said that the mass was an extra tooth growing in the young man's left nasal cavity. The patient had suffered from nosebleeds once or twice a month for the past three years, the doctors reported.

tion is poorly understood. "One theory is that there is a defect in the migration of neural crest derivatives destined to reach the jawbones. A more plausible explanation is multistep epithelial and mesenchymal interaction," the surgeons stated.

While supernumerary teeth are usually asymptomatic, patients may present with a variety of symptoms, including nasal obstruction, headache, nosebleed



Anterior rhinoscopy (upper left) and endoscopic view of the supernumerary tooth in the patient's nasal cavity. (Photograph: Al Dhaferei et al., American Journal of Case Reports, 2014)

The patient was admitted to King Fahd Military Medical Complex in Dhahran owing to recurrent nosebleeds and tonsillitis. Close examination of the man's nasal cavity found a 1 cm-long white cylindrical bony mass arising from the floor of the nose, according to the case report.

A consultant dentist made the diagnosis of intranasal eruption of a supernumerary tooth. The prevalence of such teeth is not known, as they usually remain asymptomatic in many patients and the mechanism of erup-

and external nasal deformities. They may be associated with conditions such as cleft palate. The surgeons further said that such teeth can be easily detected using nasal endoscopy, panoramic radiographs, and CT scans.

In the present case, the patient underwent endoscopic extraction of the supernumerary tooth with its surrounding granulation tissue under general anaesthesia. After three months, the area was completely healed and the patient did not experience further nosebleed. **DTI**

&lt; Page 1

overview of the use of CEREC for anterior teeth restorations. Dr. Bernd Reiss, President of the Association for Ceramics in Dentistry and President of the German Association for Computer-Aided Dentistry (DGCZ), traces the development of dental CAD/CAM technology over the past few decades and offers an outlook for the coming years. Dr. Josef Kunkela, an expert in prosthodontics and restorative dentistry, highlights some new approaches for anterior teeth restoration, which include Smile Design in the current CEREC software and the CEREC Connect software. His colleague Dr. Daniel Vasquez, who instructs CEREC trainers in South America among other things, explains the possibilities of the CEREC Omnicam in restorations. Finally, Professor Dr. Wael Att, President of the Prosthodontics Group of the International Association for Dental Research (IADR) and President of the Arabian Academy of Esthetic Dentistry (ARAED), ex-

plains what to consider for the rehabilitation of implants.

Additionally five table clinics will operate from 11 to 13 September in groups. Outstanding CEREC trainers will run a premiere extensive training for future and advanced CEREC users. Participants will have the opportunity to interact immediately and ask their personal questions of interest. The practical demonstrations will, at the same time, provide inspiration and other means of trouble shooting. The aforementioned doctors Todd Ehrlich, Daniel Vasquez and Josef Kunkela will be joined by certified inLab trainer Mohammad Al-Zu'bi from Canada and Dr. Munir Silwadi from the UAE. **DTI**

### Contact Information

Visit for more information:  
<http://cerectfest.cappmea.com>

CEREC Omnicam

# POWDER-FREE AND IN NATURAL COLOR.

Scanning with the new CEREC Omnicam combines powder-free ease of handling with natural color reproduction to provide an inspiring treatment experience for the patient. Discover the new simplicity of digital dentistry. **Enjoy every day. with Sirona.**



---

**Dubai Contact: Sirona Dental Sytsems Ltd, Dr Amro Adel, Building 49, Suite 304  
Dubai Healthcare City, Telephone: +971 4 375 2355, E-Mail: amro.adel@sirona.com**

Kuwait Contact: Sirona Dental systems GmbH, Dr. Mostafa Al. Khouly  
Office: +965 2 224 6063, Mobile: +965 9 800 2225

# Bleach Cases

## From dead white to natural bright



*mCME articles in Dental Tribune have been approved by:*

*HAAD as having educational content for 2 CME Credit Hours*

*DHA awarded this program for 2 CPD Credit Points*

**ADA CERP®** | Continuing Education Recognition Program

Centre for Advanced Professional Practices (CAPP) is an ADA CERP Recognized Provider. ADA CERP is a service of the American Dental Association to assist dental professionals in identifying quality providers of continuing dental education. ADA CERP does not approve or endorse individual courses or instructors, nor does it imply acceptance of credit hours by boards of dentistry.

*CAPP designates this activity for 2 CE credits.*

By Aiham Farah, Syria

Substituting the white opaque dentin ceramic material with a high brightness transparent effect is the secret of manipulating the 4 bleach shades (BL4, BL5, BL2, BL1), and the key factor to make them close to the natural-looking shades in our (A-D) shade guide. (Fig 1)

- The visual perception in which Opal Effect ceramic material appears to be radiating or reflecting light is called luminancy, and luminance is the intensity of light that generates what we see in dental ceramic as natural white. Why natural? Because it simulates the optical properties of the natural enamel of healthy tooth.

Our following case is a very good example of producing attractive natural-looking bleach shade.

### Case Presentation

A 45-year-old female presented to the clinic with an esthetic request, she desires a smile change. Apparently she was seeking a new look on multiple cosmetic aspects, and she chooses to start at the dental studio.

The dentist interviewed her and found out what category she is seeking (esthetic), and what was her major complain. He reported the followings; Major complain was a non-vital appearance of the current old restorations besides discoloration, which drew a pale smile on her face, and an inflammatory appearance of the surrounding gingiva. (Fig 2, Fig 3)

The patient was examined intraorally, and her dental history was recorded. The radiographic exam of the upper incisors revealed a good endodontic situation. Preliminary impressions were also taken to produce a study model. The dental lab technician presented to the clinic to evaluate the old veneers condition, and grasp the patient's needs and discuss her expectations from the whole treatment. Complete photos protocol was taken to the teeth, lips and face, those photos were crucial during the lab working steps.

### Treatment plan

The treatment plan included the following measurements; Removing the old veneers, re-prepping the incisors and the 4 upper premolars according to the general principles of all-ceramic veneers preparation, 0,6mm chamfer was created

equilingually and a 0.9mm buccal reduction was necessary to allow the veneers to mask from one hand and give the desired color from the other hand, final impression of the maxillary arch was made using addition silicon Virtual (IvoclarVivadent).

### Dental Laboratory procedure

#### The failure

According to the patient's desire of having bleach veneers, the brightest color of IPS e.max press ingot suitable for veneers fabrication (Low Translucency, LT BL1) is used, followed by delicate cut back and layering Transpa-Incisal powders from IPS e.max Ceram.

On the day of the try-in, patient showed up to the clinic, she was excited to see the new smile. When she looked at the mirror she felt the change. (Fig 5) All the measurements of esthetic smile, from teeth arrangement to lips dynamic appeared perfect on her face. The dental team members had different point



Fig 1. Bleach shade guide, (Ivoclarvivadent A-D shade guide)

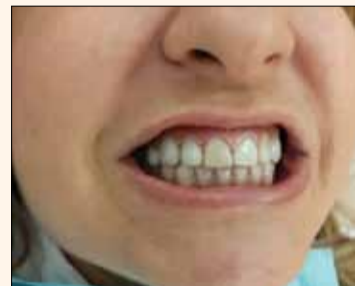

Fig 2. The pre-operative situation

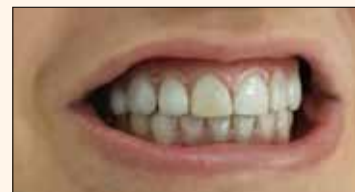

Fig 3. The pre-op situation reflecting the non-vital appearance of the old veneers and the surrounding gingiva

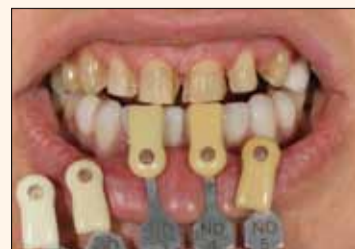

Fig 4. The degree of discoloration of the prepped dentin according to the ND shade guide

of view on the shade after taking few minutes to absorb the tried-in set. They all agreed that something still missing for the case to be esthetically pleasing, as if all the light rays coming from inside the veneers faded down after being placed on the prepped teeth (dentist stated in privacy). Soon we realized that the discoloration of the prepped dentin continued on darkening during the 10 days lab work process. So at the day of the try-

set with the bleach shade guide held into position were important to be reviewed to find out what to do and what to avoid in the new veneer set. (Fig 6) A black and white photo was important to define the matching level of brightness, and what bleach shade we reached. (Fig 7)

#### Ingot selection judgment

#### The Success

Priority number one was mask-

and incisal material and characterize with variety of brighter impulse colors from IPS e.max Ceram powders. Texturized Fig 9, glazed, then the final outcome shin was balanced by further manual polishing.

A comparison with the failed previous set; in order to make sure that I succeeded boosting the luminosity level was important after transferring the dentin background of the natural prep from the patient mouth to my



Fig 5. The patient checking her smile with the first set of veneers

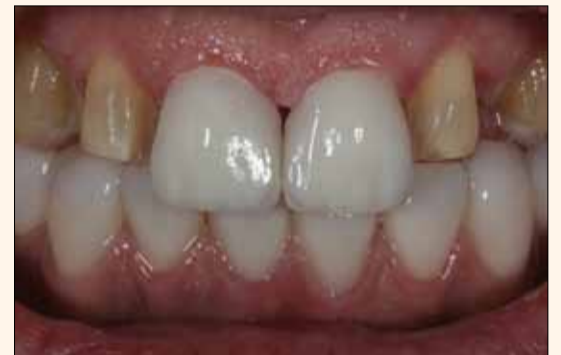

Fig 6. The non-vital appearance of the first set of veneers centrals on the day of Try-in

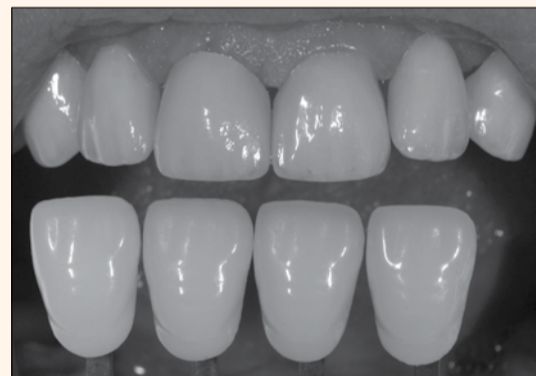

Fig 7. The low value of the first set of veneers compared to the bleach shade guide in a B&W photo

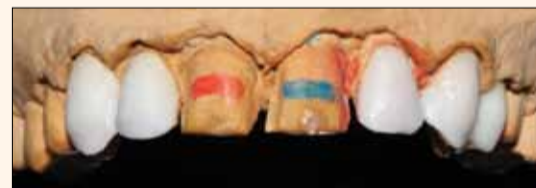

Fig 8a, 8b. Masking test of the MO0 ingot shells

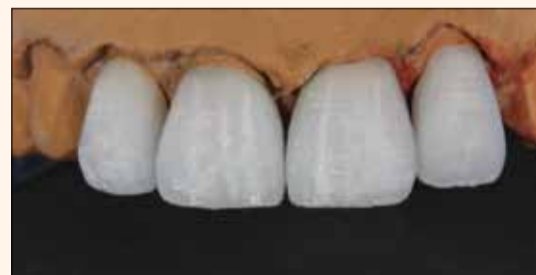
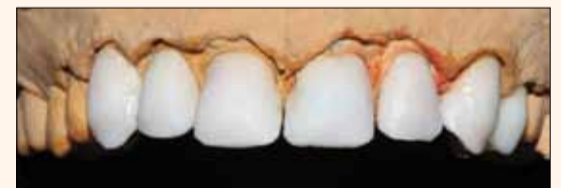
Fig 9. The texturized veneers on the control (non-segmented) model

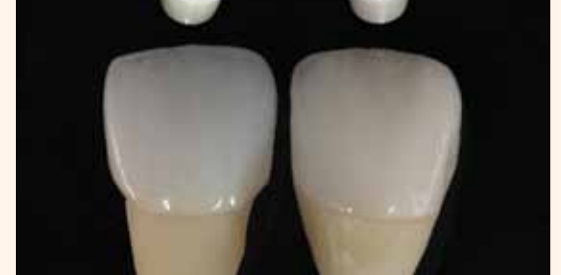

Fig 10. A comparison between the LT BL1 veneer and the MO0 veneer

in, it was ND4, noting that the one reported in the beginning was ND2. (Fig 4) It seems that those veneers lost luminosity after placing them on the prepped teeth, what indicated a bad influence on the final color. Nothing can be done at this moment to get those veneers back to life. A decision to repeat the case was simply taken, with no hesitation, photos of the tried-in

ing the discoloration and then; increasing the luminosity, though we choose the opacity ingot (Medium Opacity) MO0, to be pressed on a thickness of 0.5 mm, and before we proceed I had to double check the masking capability, so I drew two marks on the stone (red-blue) and check if they are visible through the MO0 shells (Fig 8a, 8b) then layered with dentin

bench through the IPS Natural die material ND4. (Fig 10)

### Cementation

Veneers were finally cemented with Bleach XL (only Base) Variolink-II resin cement (from Ivoclarvivadent), After they have been tried-in and all seating and

&lt; Page 6

esthetic parameters of fit have also been checked carefully, fine-grit diamond burs, finishing and polishing rubber heads (Optrafine Assortment, Ivoclar-Vivadent) were used to remove excess residual cement and to eliminate all occlusal interferences and to give natural glamor of ceramic surface shin. (Fig 11)

During the follow up appointment, a final checkup and modifications were made to eliminate all occlusal interference.

#### Relative translucency level

The level of translucency was kept minimal relatively to the patient age and shade whiteness chosen by her, as our priority was to mask and boost the brightness, and brightness and translucency contradict to a certain extent, though translucency

kept relatively minimal. (Fig 12)

#### Color restriction

What makes bleach cases more complicated is color restriction, as in our present patient case, she wants to keep the old lower veneers that she had before, and replace just the uppers with a brighter and more vital set of bleach veneers, so we are obligated here to keep a chromatic shade matching especially on the cervical part of the upper veneers with the lowers, and increase the level of brightness in the mid-third of the upper veneers than that of the lowers. (Fig 13)

#### Personality change

What we simply did was changing not just the patient smile literally, but changing the smile on her face emotionally, the feel-

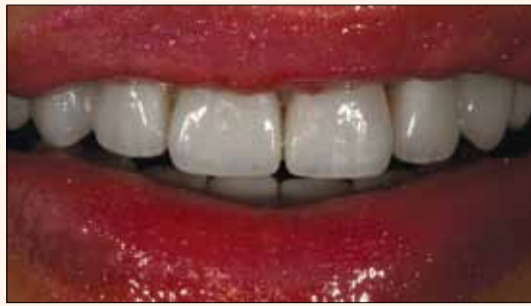

Fig 11a.11b. The glamor smile right after cementing the second set of veneers, and using the polishing rubber heads (Optrafine, Ivoclarvivadent)

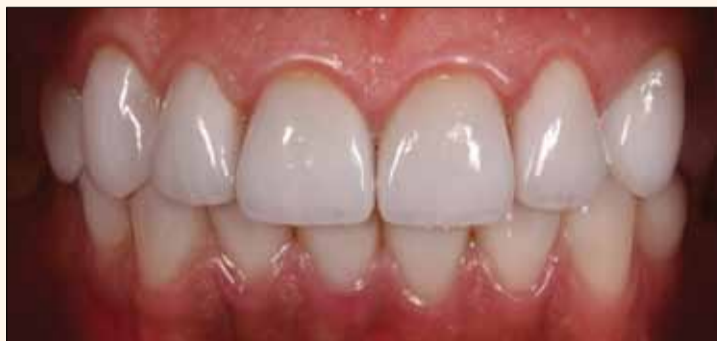
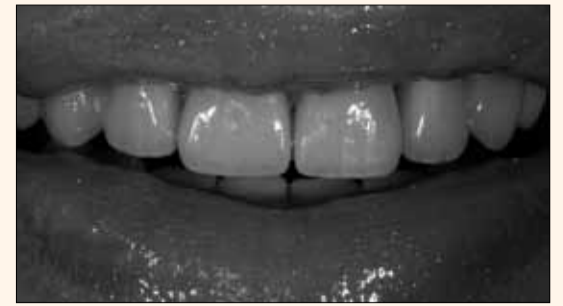
Fig 12. One month recall, Close-up front picture, showing the improvement in the interdental papilla and the relative translucency level with the lower set

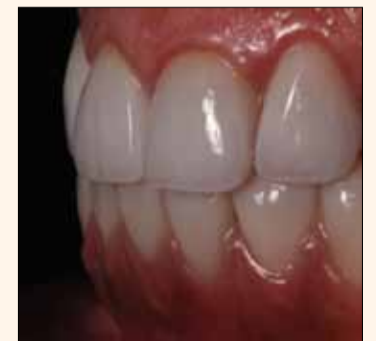

Fig 13. One month recall, Profile picture, showing the cervical chromatic color restriction



Fig 14. The change on our patient face from the time she showed up to the clinic, till one year recall visit

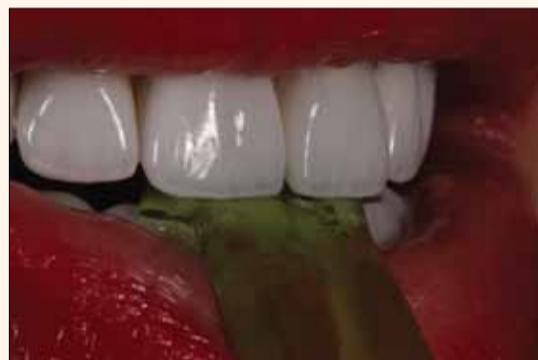

Fig 15. Bright mammons strips overlapping with translucent opal strips, all framed with halo effect

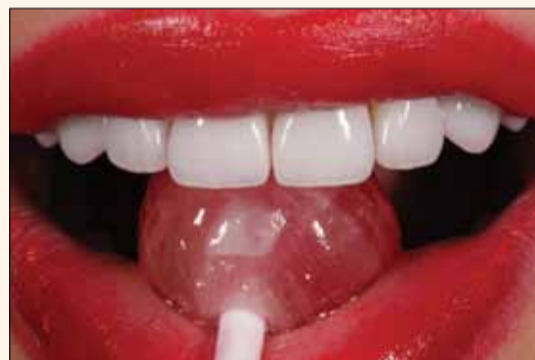

Fig 16. One of the artistic photos taken by Mr. Florin Stoboran, Romania, big thank to him

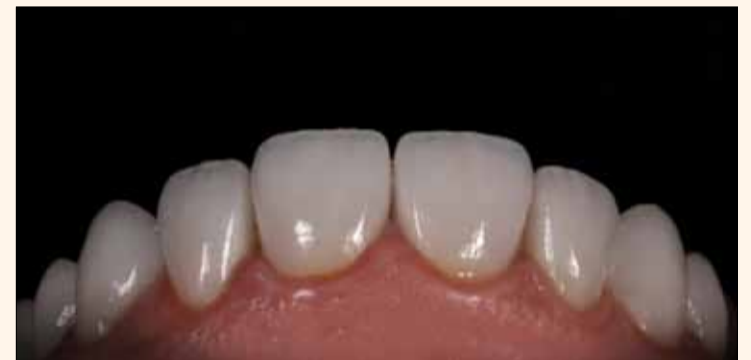

Fig 17. The front set of veneers with a black background contrastor

#### mCME SELF INSTRUCTION PROGRAM

CAPP together with Dental Tribune provides the opportunity with its mCME- Self Instruction Program a quick and simple way to meet your continuing education needs. mCME offers you the flexibility to work at your own pace through the material from any location at any time. The content is international, drawn from the upper echelon of dental medicine, but also presents a regional outlook in terms of perspective and subject matter.

#### Membership:

Yearly membership subscription for mCME: 600 AED  
One Time article newspaper subscription: 200 AED per issue.  
After the payment, you will receive your membership number and allowing you to start the program.

#### Completion of mCME

- mCME participants are required to read the continuing medical education (CME) articles published in each issue.
- Each article offers 2 CME Credit and are followed by a quiz Questionnaire online, which is available on <http://www.cappmea.com/mCME/questionnaires.html>.
- Each quiz has to be returned to [events@cappmea.com](mailto:events@cappmea.com) or faxed to: +97143686883 in three months from the publication date.
- A minimum passing score of 80% must be achieved in order to claim credit.
- No more than two answered questions can be submitted at the same time
- Validity of the article - 3 months
- Validity of the subscription - 1 year
- Collection of Credit hours: You will receive the summary report with Certificate, maximum one month after the expiry date of your membership. For single subscription certificates and summary reports will be sent one month after the publication of the article.

The answers and critiques published herein have been checked carefully and represent authoritative opinions about the questions concerned.

Articles are available on [www.cappmea.com](http://www.cappmea.com) after the publication. For more information please contact [events@cappmea.com](mailto:events@cappmea.com) or +971 4 3616174

FOR INTERACTION WITH THE WRITERS FIND THE CONTACT DETAILS AT THE END OF EACH ARTICLE.

ing that she can look younger pushed her to continue working on herself, and that appeared clearly on each follow up visit to the clinic she was making, one time skin was taken care off, the next time hair and make-up, then back again to the smile to contour it with a better frame of lips by using fillings. (Fig 14) So what we did is that we put her on the beginning of the cosmetic track, (A year after the dental treatment she looked one year younger) what dentist stated. So we contributed to change her life.

#### Dental Photo shooting

Our patient has a photogenic face and she didn't mind to be our model for a few photo shooting sessions, which encouraged us to take all possible poses that showed clearly the strength areas and talent in fabricating such cases, some snakes with different color contrast were used to show the optical properties of the translucent opal and bright Mamlone material used. Thanks to the expert Mr. Florin Stoboran from Romania who helped in the final photoshoot. (Fig 15, Fig 16, Fig 17)

#### Conclusion

A decision to repeat the veneers with a new brighter set of veneers was faithfully taken (after recognizing that a flawless set can be achieved if all obstacles

can be taken into considerations). The honest and ethical opinion of the dental teamwork (what we did was okay, but we can do better), even if the patient okayed the present outcome. This is what really takes the level of esthetic dentistry to the next level.

I would like to thank Dr. Duval Aloush for his faithful opinion and esthetic vision that played a big role in the successful outcome of this case. [\[1\]](#)


#### About the Author



Aiham Farah, Syria  
Certified Dental Technician by the National Board for Certification in USA (Dental Laboratory Technology) with a specialty of Dental Ceramic. And a member of the National Association of Dental Laboratory in USA, currently he is a material consultant and opinion leader for Ivoclarvivadent dental company for the Near East & Orient region since 2009, and MDT (Master Dental Technician) certified by the ICDE Ivoclarvivadent, Switzerland. He was a Teacher Lecturer at Alkalmoun University,

in Dental Technology division for graduate students in All-Ceramic Subject in Syria (2010, 2011). He had his private dental-lab practice "one-man-show cosmetic laboratory" in Syria (2005-2006/2009-2012) specialized in selective cosmetic cases, currently he is a lecturer in dental international conferences, speaks in esthetic dentistry about topics like (Ceramic material, Esthetic solutions in CAD/CAM, Dental teamwork, Psycho-morphology, Advanced cosmetic characterization etc), and a demonstrator in courses and workshops for dentists and dental technicians. He writes and publishes articles in local and international dental magazines like (Reflect, Dental Labor middle east, Dental News, Dental Tribune etc), in different teaching topics based on both theoretical researches and own practical experience, also he reviews and edits all the (Arabic language translations) of the IvoclarVivadent communication tools publications.

# Esthetic rehabilitation of posterior teeth using Bulk-Fill Composite



Figs 1 and 2. SEM of the filler composition and surface structure of Tetric N-Ceram Bulk Fill (magnification: 200x)

By Prof. Dr Masahi Miyazaki

In modern restorative dentistry, a strong emphasis is placed on preserving healthy tooth structure and achieving esthetic results. The use of direct composite restoratives can assist in meeting these demands.

Composite resins have become widely accepted in dentistry as direct placement restorative materials for posterior teeth. The advances made in adhesive technology as well as the improvement of the mechanical properties of composite resins (e.g. wear resistance) have contributed to this development. Nevertheless, the polymerization shrinkage and limited curing depth of composite resins continue to be a concern to the clinician. Polymerization shrinkage of composite restoratives has been associated with micro-leakage, de-bonding of the restoration as well as increased risk of secondary caries or postoperative sensitivity. To reduce the rate of polymerization shrinkage, incremental filling techniques have been recommended for many years. The reduced shrinkage per composite layer is believed to minimize the total volumetric shrinkage [1].

Even though incremental layering may be necessary to ensure adequate polymerization of the composite resin, there are also some disadvantages to this technique. For example, air entrapment between the different layers may occur.

Moreover, the fact that incremental placement requires considerable time may render the restorative procedure excessively long. The controversy among researchers and practitioners with regard to the appropriate placement technique, namely, incremental layering versus bulk placement, continues to persist.

In recent years, dental manufacturers have gone to considerable lengths to develop bulk-fill composites that demonstrate lower shrinkage stress during polymerization and offer much greater depth of cure. The goal behind these efforts has been to shorten the duration of the restorative procedure [2]. In the meantime, several posterior composites of this type have been launched on the market. What dentists need now is some sort of guideline for their application in concrete clinical situations.

## Advantages and limitations of direct composite resin restorations

A major advantage of adhesive composite restorations in posterior teeth is the possibility of preserving healthy tooth structure. Unlike indirect procedures, the direct restorative technique with composite requires only minimal removal of sound tooth structure. Preparation to gain access to the lesion is normally limited to the affected area. Nevertheless, the shape of the cavity should be adjusted to match the restorative material. Elimination of slightly undermined enamel is not always necessary because adhesive composite resin restorations may contribute to the stabilization of the remaining tooth structure.

As a result of the shrinkage stress that occurs during the light-curing of composite resin, there are restrictions with regard to the placement technique employed. Studies have shown that the magnitude of the stress generated is dependent on a combination of the material properties and characteristics of the prepared cavity. Contributing factors include the confinement conditions imposed on the composite, the volume of the restoration, the restorative tech-

niques used and the suitability of the bonding substrate.

When restoring cavities with a high C factor, the resultant stress puts the resin-tooth interface under increased tension because there is less free, non-bonded surface. An increase in the C factor is associated with potentially deleterious effects on the marginal integrity and the formation of gaps [3]. Alternatively, high bond strength may cause cusp deflection and cracking of the enamel.

## Methods of lowering the shrinkage stress

Polymerizing low-volume increments may minimize the resulting shrinkage stress and maximize double bond conversion of the monomers to a polymer. Compared with bulk-filling techniques, incremental filling produces lower shrinkage stress (up to a certain threshold thickness of the composite layer). Incremental placement techniques have the advantage of maximizing the polymerization

Apart from low residual stress and good adaptation, thorough polymerization of the composite resin is an important factor for restorative success. The main concern about the bulk-filling technique is whether the composite cures sufficiently in the deeper portions, as this is a prerequisite for any filling with acceptable physical and biological properties.

Recently, several so-called low-shrinkage stress materials have been launched on the market. The majority of them are more translucent than conventional composites. They feature a modified initiator system which allows them to be placed in increments of up to 4 mm thickness (bulk-filling technique), but still ensures a reliable cure with short irradiation times. Bulk-fill materials have been reported to demonstrate significantly less shrinkage stress than conventional posterior composite resins [6].

*Composite restoratives suitable for the bulk-filling technique need to fulfill certain requirements. Among other things, they should demonstrate low polymerization shrinkage and ensure a high depth of cure.*

of each increment because of the reduced attenuation of light through the smaller increments of material and better adaptation of the composite to the cavity walls [4]. Nevertheless, the value of incremental placement in reducing shrinkage stress has been repeatedly questioned [5]. The contradictory conclusions at which studies have arrived might be due to differing testing methods.

## Trouble-free restoration

In the restoration of teeth with composite resin, incremental layering is generally preferred because it reduces gap formation at the adhesive interface and the postoperative sensitivities associated with it. However, multiple layers of high-viscosity composite may be difficult to place. Recent studies have suggested that fewer increments and even bulk filling can be equally successful. However, the unavailability of suitable bulk-fill materials has discouraged clinicians from employing such techniques [7]. Today, various dental manufacturers have expanded their offering to include low-shrinkage composites, allowing clinicians to achieve reliable and predictable results with the bulk-filling technique.

Bulk-fill composites should offer high depth of cure. This is

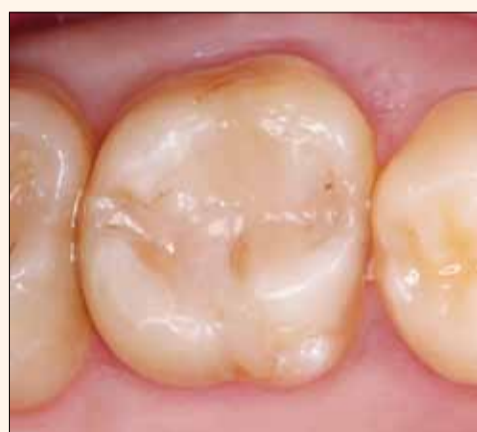

Fig. 3. Preoperative situation: The restoration of the upper posterior tooth shows a marginal fracture.

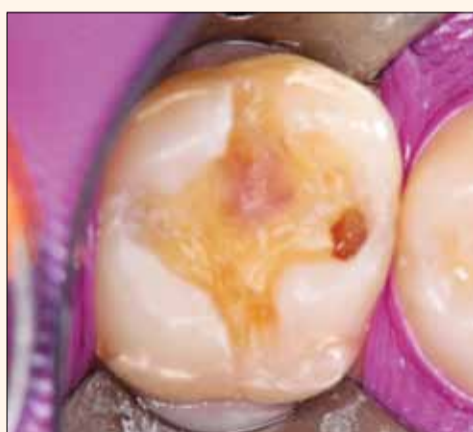

Fig. 4. After the rubber dam has been placed, the restoration as well as carious tissue are removed.

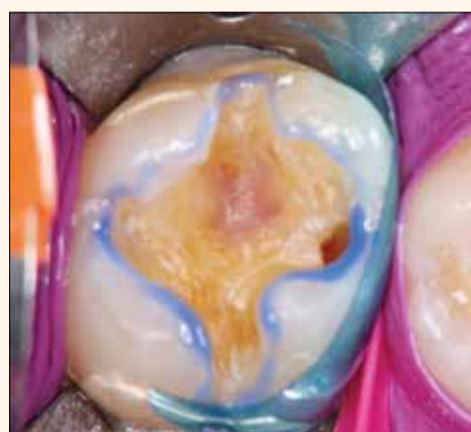
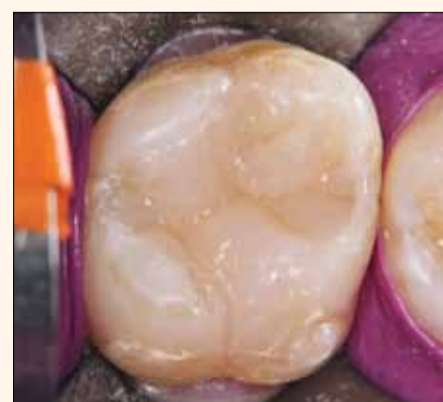
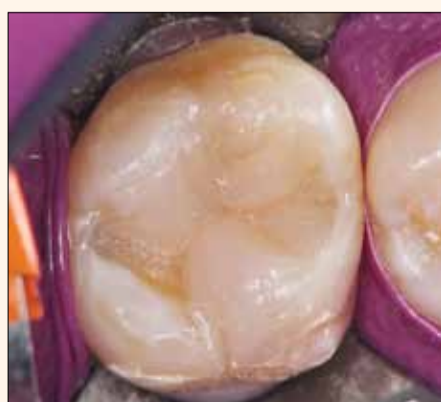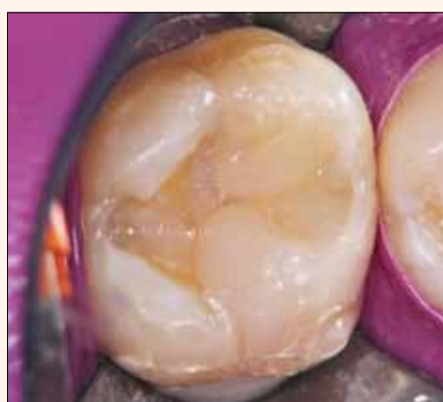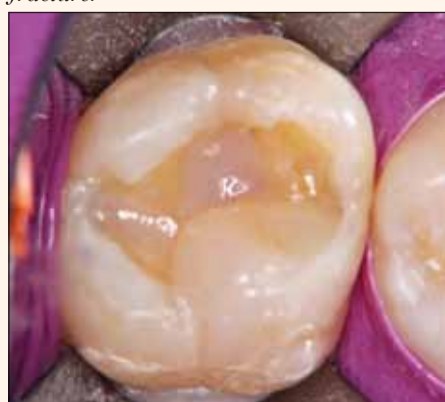Fig. 5. Prior to the application of the adhesive, the cavity is etched with phosphoric acid.



Figs 6 to 9. The anatomical features of the cusps are successively rebuilt until an ideal occlusal anatomy is achieved.



&lt; Page 8

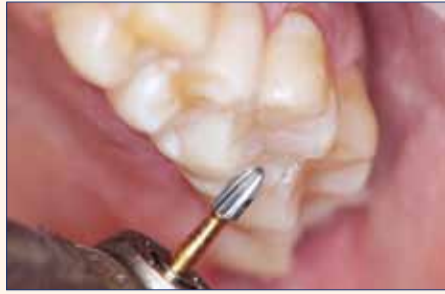

Fig. 10. Carbide burs are recommended for the removal of marginal overhangs.

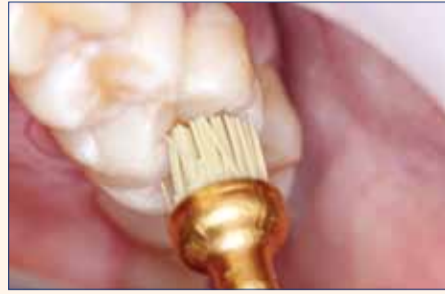
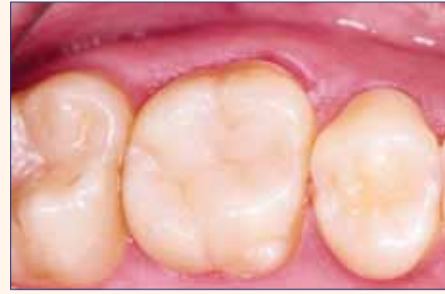
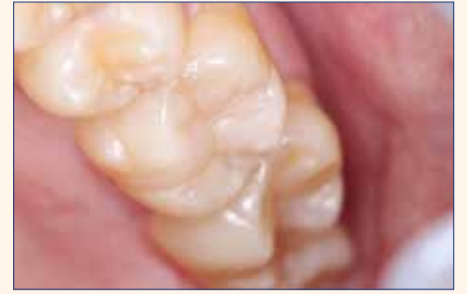Fig. 11. Final polishing is performed with Astrobrush.



Figs 12 and 13. The result is an esthetic posterior restoration without postoperative sensitivity.



achieved by means of the photoinitiator Ivocerin® for example, which is employed by Ivoclar Vivadent. Good mechanical properties such as high flexural strength and wear resistance are also important in order to make a composite resin suitable for use in occlusion bearing areas [8].

Tetric® N-Ceram Bulk Fill from Ivoclar Vivadent combines all of these qualities. This light-curing posterior composite has been specifically developed for the bulk-filling technique.

Increments of up to 4 mm thickness can be cured in only 10 seconds at a light intensity of > 1,000mW/cm<sup>2</sup>.

Tetric N-Ceram Bulk Fill contains four different types of fillers: a barium aluminium silicate filler, ytterbium trifluoride and mixed oxide. Additionally, a prepolymer filler (a shrinkage stress reliever) has been incorporated which keeps polymerization shrinkage and shrinkage stress to a minimum (Figs 1 and 2). It acts like a spring, dampening the forces generated during polymerization. As a result, gap formation and marginal leakage are minimized, thereby helping to eliminate the risk of secondary caries and postoperative sensitivity.

The photoinitiator system in Tetric N-Ceram Bulk Fill includes conventional initiators as well as the polymerization booster Ivocerin. This polymerization

booster ensures a reliable depth of cure in the deeper portions of the cavity after a relatively short irradiation time. A special light sensitivity inhibitor has also been incorporated which makes the composite resin less sensitive to ambient light and thus gives the clinician more time to apply and contour the restoration. Another useful quality of this material is its good polishability, which supports the achievement of a glossy surface, excellent resistance to wear in the contact areas and a high flexural strength of 120 MPa. Moreover, Tetric N-Ceram Bulk Fill is highly radiopaque; therefore, the restorative result is easy to examine on dental radiographs.

#### A clinical case

The shade of the composite to be used should always be selected at the start of the appointment, i.e. before the rubber dam is placed. This prevents incorrect colour matching due to dehydration. After the carious tissue has been removed (Figs 3 and 4) and the adhesive has been applied (Fig. 5), the entire restorative procedure can be performed with Tetric N-Ceram Bulk Fill. As a consequence, a uniform restoration featuring homogeneous strength is achieved.

Because of the material's natural-looking translucency, the shade of the restored site will blend in with the remaining tooth structure. If stained substrate is visible within the cavity,

the clinician may opt to place a layer of Tetric® N-Flow Dentin first. This material has a higher opacity and is thus capable of masking the darker colour of the underlying dentin.

Although the incremental technique has been advocated for the reduction of shrinkage stress, the composite resin described above is an ideal option for the restoration of deeper cavities using the bulk-filling technique. The successive build-up technique makes it possible to ensure correct occlusal morphology through the incremental placement of composite. Thin-bladed placement instruments and special brushes are used to sculpt and contour the restored site.

The composite is applied in bulk increments to rebuild each anatomic entity of the affected area. Each cuspal portion is reconstructed with one increment of composite resin, imparting to each of the cusps its adequate anatomical form.

The size and location of the cavity determines the number of increments needed. Relatively small Class I cavities can be filled with a single bulk increment. Medium-sized and large cavities are restored with several increments. Each cusp is rebuilt with an increment of maximum 4 mm thickness.

Anatomical features of the occlusal surface should be taken

into consideration during the application of the composite resin to mimic the natural tooth structure. Insensitivity to light is a considerable advantage of Tetric N-Ceram Bulk Fill, as it ensures that sufficient time is available to shape and contour the restoration (Figs 6 to 9).

If the composite resin is carefully placed using suitable instruments, only little time is required for the contouring and finishing of the restoration. Hand instruments such as LM Arte-Eccessa (LM Dental) are recommended for the removal of composite excess. Marginal overhangs can be removed with carbide burs (Fig. 10). Composite finishers are then used to refine the anatomical features. Polishing can be accomplished with ease and in one step using Astrobrush® (Fig. 11). The result is an esthetic posterior restoration without postoperative sensitivity (Figs 12 and 13).

#### Conclusion

Direct composite resin restorations can be performed in a predictable and efficient way if an appropriate technique and advanced materials are used. As the understanding of the characteristics of new filling materials improves among clinicians, the quality of the direct restorations they fabricate will also increase. Tetric N-Ceram Bulk Fill with its many innovative features enables clinicians to restore posterior teeth in a much more

efficient way. Proper attention to technological advances in the field of restorative therapy allows esthetic treatment to be provided that will satisfy not only the patient but also the dentist performing the restorative procedure.

Full list of references is available from the publisher.<sup>DT</sup>

#### Contact Information



Prof. Dr Masashi Miyazaki  
Nihon University School of Dentistry  
Department of Operative Dentistry  
1-8-15, Kanda-Surugadai,  
Chiyoda-ku  
Tokyo 101-8510  
Japan  
miyazaki-m@dent.nihon-u.ac.jp

## CAD CAM Technology: a Review

Dr. Kassis Cynthia., DDS, MSc  
Dr. Khoury Pierre., DDS, DESS  
Dr. Tatiana Zogheib, DDS  
Dr. Hardan Louis., DDS CES  
PhD head of Esthetic and Restorative Dentistry department, USJ

Prof. Mehanna Carina., DDS  
CES PhD FICD Director of Esthetic and Restorative Dentistry Postgraduate Program USJ,  
President of the continuing Education committee, Lebanese Dental Association

CAD/CAM technology and materials are currently used in a number of clinical applications, including the fabrication of indirect restorations. CAD-CAM gives both the dentist and the laboratory an opportunity to automate fixed restoration fabrication. Both chairside and chairside – laboratory integrated procedures are available. The properties of these restorative materials and their indications and appropriate use must be understood in order to enable the

achievement of predictable and esthetic results for patients.

#### KEYWORDS:

CAD-CAM systems  
Intraoral scanner  
Digital impression

#### Introduction

In the past decade, the demand for all ceramic restorations has increased in both anterior and posterior teeth and the search for materials with improved properties has expanded.<sup>1</sup> The need for a uniform material quality, reduction in production cost, and standardization of manufacturing process has encouraged researchers to seek to automate the manual process via the use of CAD-CAM technology since 1980.<sup>2</sup>

Computer-aided design (CAD) and computer-aided manufacturing (CAM) technology systems use computers to collect information and design, and to manufacture a wide range of products.<sup>3</sup> The introduction of

the first digital intraoral scanner for restorative dentistry was in the 1980s by a Swiss dentist, Dr. Werner Mörmann, and an Italian electrical engineer, Marco Brandestini, that developed the concept for what was to be introduced in 1987 as CEREC® by Sirona Dental Systems LLC (Charlotte, NC), the first commercially CAD/CAM system for dental restorations.<sup>4,5</sup> Ever since research and development sectors at a lot of companies have improved the technologies and created in-office intraoral scanners.

All the existing intraoral scanners try to face with problems and disadvantages of traditional impression fabrication process and are driven by several non-contact optical technologies and principles.

The purpose of this present publication is to provide an extensive review on the CAD-CAM technology and to emphasise on the application of

this technology in restorative dentistry.

#### CAD-CAM techniques

The major goals of the impression – taking process in restorative dentistry are obtaining a copy of one or several prepared teeth, healthy adjacent and antagonist teeth, establishing a proper interocclusal relationship and then converting this information into accurate replicas of the dentition on which indirect restorations can be performed.<sup>6</sup>

Traditional restorative techniques for fixed restorations require the use of impression materials to record the contours and dimensions of the preparation. This is followed by the pouring of stone models and dies prior to laboratory fabrication of the definitive fixed restoration. Taking an accurate impression is one of the most difficult procedures in dentistry, requiring careful retraction or removal of soft tissue around

preparation margins, hemostasis, and selection of an appropriate impression material and tray for the technique used.

By using a CAD/CAM restorative technique, a number of steps can be simplified or eliminated.<sup>7</sup>

Digital systems now offer the opportunity to avoid traditional, analog impressions, including the usual impression materials, time, and handling limitations associated with them. Intraoral scanners have the potential to offer excellent accuracy with a more comfortable experience for the patient and more efficient workflow for the office. But care must be taken to ensure that the whole preparation is scanned, to avoid introducing errors.

Two techniques can be used for CAD/CAM restorations: The chairside technique or the integrated chairside-laboratory procedure.

&gt; Page 10