

# DENTAL TRIBUNE

The World's Dental Newspaper · Middle East & Africa Edition

PRINTED IN DUBAI

www.dental-tribune.com

JULY - AUGUST 2013 | NO. 4, VOL. 2

**EVENT**

2<sup>nd</sup> AP CAD/CAM & Digital Dentistry International Conference Singapore



**MEDIA CME**

Immediate Rehabilitations Of Atrophic Jaws Using Tilted Implants



**TEASER**

1 Complete Solution



**EVENT**

5<sup>th</sup> Dental-Facial Cosmetic International Conference



> Page 25

> Page 6-7

> Page 14-15

> Page 2

## CEREC Omnicam – Most Innovative Product In Dentistry



By Sirona

London, UK: The CEREC Omnicam was bestowed with the award for the most innovative product at the recent Clinical Innovations Conference which was held on 17-18th May 2013 in London, UK, presented by Mash Seriki, CEO of Healthcare Learning; Smile-on.

The Clinical Innovations Conference is now in its 10th year and in keeping with the ethos of the event the awards allow the profession to celebrate the latest innovative products in aesthetic and restorative dentistry. Healthcare Learning; Smile-on invited the dental industry to nominate their products to be judged by a panel of experts.

**CEREC Omnicam demonstrates Sirona's Power of Innovation**

CEREC Omnicam generates full colour scans of intraoral surfaces without the need for a powder coating. Operating the camera is simple and

intuitive. The imaging functionality and camera dimensions have been ergonomically designed. The smooth operation of CEREC Omnicam is no more complicated than taking a video. Three features of the CEREC Omnicam stand out in particular: it supports video streaming; it digitizes the structures of the jaw in their natural colour; and it does not require a powder coating of the tooth surfaces.

**CEREC improves efficiency and patient experience**

CEREC is a great practice builder. With a busy lifestyle patients are impressed by the single appointment required for the fabrication of a permanent crown or bridge; the life-like appearance of their new restoration is fantastic with an incredible fit. There is no need to place temporary restorations in the majority of CEREC cases, allowing the restoration to be created and fitted in one appointment. CEREC has significantly improved the quality of treatment for patients, as well as enhancing the efficiency of the dental practice. [DT](#)

08-09 NOVEMBER 2013  
JUMEIRAH BEACH HOTEL  
DUBAI UAE

**5<sup>TH</sup> DENTAL - FACIAL COSMETIC INTERNATIONAL CONFERENCE**

Joint Meeting with  
AMERICAN ACADEMY OF IMPLANT DENTISTRY  
2<sup>nd</sup> Global Conference

### SCIENTIFIC PROGRAM



Dr. Andreas Kurbad, Germany

Lecture: Smile Design as a key factor in the Aesthetic treatment planning  
Lecture: Ceramic in Harmony with Nature - Ultraconservative Restoration of Enamel



Prof. Dr. Claus-Peter Ernst, Germany

Lecture: Tooth colored indirect restorations: Material selection, operative procedures, luting concepts  
Lecture: Directly placed anterior restorations today: Simplified concepts as the key to success



Dr. James Russell, UK

Lecture: Progressive Smile Design: Truly Minimally Invasive Cosmetic Dentistry For Every Dentist



Dr. Nick Katsikeris, Canada

Lecture: Possible Postulates of Peri-implantitis Complications



Dr. Shankar Iyer, USA

Lecture: Controversies explored in Implant Dentistry



Dr. Samar Mashabi  
KSA



Dr. Natalie Wong  
Canada



Dr. George E. Anastassov  
USA

Lecture: Aesthetic Considerations in Orthognathic and Dental Implant Surgery



Dr. Gary S. Wadhwa  
USA

Better Facial Esthetics & Reconstructive Implant Dentistry & Practice Management



Dr. Luca Cordaro  
Italy

Lecture: Alveolar Augmentation in the Aesthetic Zone



Dr. André P. Saadoun  
France

Lecture: Esthetic Soft Tissue Management around implants

WWW.CAPPMEA.COM/AESTHETIC2013

#### HANDS-ON COURSES

**AESTHETIC REHABILITATION:** Dr. Andreas Kurbad, Germany  
Est. CME 8 Hours November 7, 2013 9.00am-6.00pm, JBH

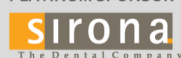**INDIRECT VENEERS:** Dr. Munir Silwadi, UAE  
Est. CME 8 Hours November 7 2013 9.00am-6.00pm  
3M Innovative Center, DIC

**THE NEW CONCEPT OF ALIGNMENT, BLEACHING AND BONDING(ABB)**  
(Inman Aligner Accreditation Course): Dr. James Russel, UK  
Est. CME 8 Hours November 10, 2013 9.00am-6.00pm, JBH

**SOFT TISSUE MANAGEMENT:** Dr. Andre Saadoun  
Est. CME 8 Hours November 10, 2013 9.00am-6.00pm, JBH

**HARD TISSUE MANAGEMENT:** Dr. Stuart Orton-Jones, UK  
Est. CME 8 Hours November 10, 2013 9.00am-6.00pm, JBH

PLATINUM SPONSOR



SILVER SPONSOR



GOLD SPONSORS



OFFICIAL SPONSORS



OTHER INDUSTRY PLAYERS



**ADA C-ERP** Continuing Education Recognition Program

Centre for Advanced Professional Practices (CAPP) is an ADA CERP Recognized Provider. ADA CERP is a service of the American Dental Association to assist dental professionals in identifying quality providers of continuing dental education. ADA CERP does not approve or endorse individual courses or instructors, nor does it imply acceptance of credit hours by boards of dentistry.

CAPP designates this activity for 15 continuing education credits.



# 5<sup>th</sup> Dental Facial Cosmetic International Conference

## Joint Event With

### American Academy Of Implant Dentistry, 2<sup>nd</sup> Global Conference

#### 08-09 November 2013, Jumeirah Beach Hotel, Dubai, UAE

**D**ear Colleagues of the Dental Team,  
It is my honor and pleasure to welcome you all to our 5th Dental - Facial Cosmetic International Conference! Our specialized conferences are evolving into landmarks in the field of Continuous Dental Education. We offer a unique blend of Science, Clinical Knowledge, and Cutting Edge Technology in the field of Dentistry and beyond. All of us, organizers, speakers, and sponsors spare no time or effort to bring forward the most up to date developments in various fields of Dentistry.

Our sponsors will show you the latest trends and developments from the leading dental manufacturers in the industry during a relaxed and cozy atmosphere at the amazing Jumeirah Beach Hotel in Dubai. Make sure to share your professional experience with Sirona, Ivoclar Vivadent, 3M ESPE, GSK, OralB, VITA, Carestream Dental, Philips Sonicare, Invisalign. Providing your feedback is the most important aspect in the developing of the products for the needs of the clinicians.

Dr. Adreas Kurbadform Germany, your favorite speaker will be with you presenting "Smile Design" and "Ceramic in Harmony in Nature". Prof. Dr. Claus-Peter Ernst, Germany will provide two lectures in Conservative Dentistry. His lectures will bring you to the new concepts of material selection, operative procedures and luting concept in the treatment of tooth colored indirect restorations. Simplified concept of direct place-

ment of anterior restorations will show you the key of success.

Dr James Russell, UK has been awarded the highly prestigious British Academy of Cosmetic Dentistry (BACD) Accreditation in recognition of excellence in cosmetic dentistry, the youngest dentist to achieve this. He is here for the first time with the "Progressive Smile Design: Truly Minimally Invasive Cosmetic Dentistry For Every Dentist". Simple treatments are sweeping aside the traditional approach to "Smile Makeovers" and are redirecting the evolution of cosmetic dentistry. These new protocols are allowing any dentist in any practice to offer this kind of treatment. Do not miss the opportunities to put something new in you aesthetic treatment after attending this lecture.

#### Joint Event

This 5th edition of our DFCIC features a special joint meeting with the American Academy of Implant Dentistry and their 2nd Global Conference. Comprehensive list of experienced, AAID credentialed Dental Professionals will show their practical skills for practicing Implant Dentistry. During this session, the AAID will share with us their vast knowledge and experience as well as the latest in the field of Aesthetic and Implant Dentistry. The team: Prof. George Anastassov USA, Dr. Gary Wadhwa, USA; Dr. André Saadoun, France; Dr. Luca Cordaro, Italy; Dr. Natalie Wong, Canada; Dr. Nick Katsikeris, Canada and Dr. Shankar Iyer USA.

#### Hands-On Courses

Five hands on courses will run as

pre- and post- -at the days of the conference.

Andreas Kurbad, Germany „Esthetic Rehabilitation Minimum Invasive All-Ceramic Restorations for Better Aesthetic Results Full day lecture and Hands-on course“; Dr. Munir Silwadi -Indirect Veneers; Dr James Russell, UK „The new concept of ABB Alignment, Bleaching and Bonding (the Inman Aligner accreditation course); Dr. Stuart Orton Jones; Mr. Metin facilitator - Hard Tissue Grafting; Dr. Andre Saadoun USA/ Dr. AmitVora (Periodontist, USA) facilitator - Soft Tissue Grafting. Make sure you take your place in time as the seats are limited.

I am sure that this conference will be of the greatest help to develop our knowledge and sharpen our skills in pursuing the goal that we all share, to provide our patients with the best possible solutions for their Aesthetic needs.

See you all in the dynamic city of Dubai and the amazing atmosphere of Jumeirah Beach Hotel!

**Dr. Munir Silwadi**  
Chairman and Scientific Program Adviser

**Dr. Ninette Bandy**  
Chairman and Scientific Program Adviser AAID

**Dr. Dobrina Mollova**  
Head of Organizing Committee, CAPP

#### Contact details

events@cappmea.com [DT](#)



#### International Imprint

##### Licensing by Dental Tribune International Group

**Editor** Daniel Zimmermann  
newsroom@dental-tribune.com  
+49 341 48 474 107

**Clinical Editor** Magda Wojtkiewicz

**Online Editors** Yvonne Bachmann  
Claudia Duschek

**Copy Editors** Sabrina Raaff  
Hans Motschmann

**Publisher/President/CEO** Torsten Oemus

**Director of Finance & Controlling** Dan Wunderlich

**Business Development Manager** Claudia Salwiczek

**Media Sales Managers** Matthias Diessner (*Key Accounts*)  
Melissa Brown (*International*)  
Peter Witteczek (*Asia Pacific*)  
Maria Kaiser (*USA*)  
Weridiana Mageswki (*Latin America*)  
Hélène Carpentier (*Europe*)

**Marketing & Sales Services** Esther Wodarski

**Accounting** Karen Hamatschek

**Executive Producer** Gernot Meyer

##### Dental Tribune International

Holbeinstr. 29, 04229 Leipzig, Germany  
Tel: +49 341 4 84 74 302 |  
Fax: +49 341 4 84 74 173  
www.dental-tribune.com  
info@dental-tribune.com

##### Regional Offices

###### Asia Pacific

Dental Tribune Asia Pacific Limited  
Room A, 20/F, Harvard Commercial Building,  
105-111 Thomson Road, Wanchai, Hong Kong  
Tel: +852 3113 6177 | Fax: +852 3113 6199

###### The Americas

Tribune America, LLC  
116 West 23rd Street, Ste. 500, New York,  
N.Y. 10011, USA  
Tel: +1 212 244 7181 | Fax: +1 212 224 7185

##### Dental Tribune Middle East & Africa

###### Edition Editorial Board

**Dr. Aisha Sultan Alsuwaidi**, *President Emirates Dental Society, UAE*

**Dr. Nabeel Humood Alsabeeha**, *Consultant Prosthodontist, Ministry of Health, UAE*

**Dr. Dobrina Mollova**, *MDS, UAE*

**Dr. Munir Silwadi**, *BDS, MRCDSO, DUSS, FADI, FICD, UAE*

**Dr. Khaled Abouseada**, *BDS, MS, orthod. cert.*

*Consultant Orthodontist, KSA*

**Dr. Rabih Abi Nader**, *B.D.S, D.E.S, D.E.S.S, Oral Surgeon and Implantologist, UAE*

**Rodny Abdallah**, *Dental Technician, CDT, Lebanon*

**Director of mCME** Dr. Dobrina Mollova  
info@cappmea.com  
+971 50 42 43072

**Business Development Manager** Tzvetan Deyanov  
deyanov@dental-tribune.com  
+971 55 11 28 581

## Shakira Becomes Ambassador Or Tooth-Whitening Products

By Dental Tribune International

**C**INCINNATI, USA: Procter & Gamble, international manufacturer of personal and health care products, has announced that it has entered into a partnership with Columbian singer-songwriter and dancer Shakira. Yesterday, the musician was named new global spokesperson for the company's Oral B and Crest 3D White collection.

As the global brand ambassador, Sha-

kira, who is also a member of President Obama's Advisory Commission on Educational Excellence for Hispanics, will help launch the latest additions to the collection, appearing in the brands' print and television advertising as well as public relations efforts.

The campaign will kick off worldwide in the fall of 2013.

Stephen Squire, global marketing director at P&G, said that the company was excited to have Shakira represent its brand. "As an award-winning art-

ist and beauty icon, she embodies the true spirit of the multidimensional woman, and always does it all with a brilliant smile on her face," he said.

In addition, Shakira announced that the partnership will include support of children in Colombia through her Barefoot Foundation, which currently provides education and food to over 6,000 impoverished children in Colombia and is expanding its work to other countries, including newly launched projects in Haiti and South Africa.

The partnership is Crest 3D White's first celebrity global partnership. [DT](#)



Shakira on Hollywood Boulevard, where she was honored with the 2,454th star on the Hollywood Walk of Fame in Nov. 2011. (Photo: Featureflash/Shutterstock)

# Modern life can be



## challenging

Modern, healthy lifestyles and dietary habits often mean an increase in the consumption of acid-rich foods and drinks. However, experts believe that as few as 4 acidic challenges a day can put patients at risk of Acid Wear.<sup>1-3</sup> In addition to giving behavioural advice (e.g. diet and brushing), your patients may also benefit from a daily toothpaste that can protect enamel from these multiple acid challenges.

Pronamel is proven to rehardens acid-softened enamel and provide ongoing protection from the effects of Acid Wear.<sup>4-6</sup>



Daily protection from the effects of Acid Wear



# CPD Dubai Runs First Event



By **Dental Tribune Middle East**

**D**ubai, UAE: 10th May 2013 saw 'CPD Dubai', a new CPD/CME provider in the region, hold their first event at The Address Hotel, Dubai Marina. The event catered for the whole dental team (dentists, hygienists and dental nurses) and covered the management of medical emergencies in dental practice.

Managing Director, Nicolas Bell commented, "We felt it was important that our first event here should be a topic that all dental practice staff could attend. When researching the market, the feedback we heard from dental professionals at all levels is that although there are a number of 'conference' and 'showcase' type events run in Dubai there is a lack of full-day, high-quality training events that focus on topics relevant to general dental practice. This is what CPD Dubai aims to provide and we are building up a strong network of speakers to enable us to put together high quality events, predominately using specialist trainers based in the UK to deliver here in Dubai."

With the introduction of a mandatory minimum CPD/CME points in Dubai and other Emirates for all dental practice staff as part of annual licence renewal, there is a greater demand for quality training provision. Dentists who are licenced through Dubai

(DHA) or Abu Dhabi (HAAD) for example, are now respectively required to complete a minimum of 30 or 50 accredited hours per year in order to have their licences renewed. Hygienists and nurses are also required to fulfil a set number of hours, and many health authorities are taking a firmer stance and auditing compliance.

On the introduction of accredited continuing professional development hours, Dr Raj Majithia, Postgraduate Dental Tutor from London, who was delivering the training, said, "I think this is a great move from the health authorities here. It has been the case in the UK and many other countries that dental professionals need to provide evidence of on-going learning in order to maintain their registration. This can only help to improve the quality of patient care and help dental professionals stay on top of latest developments. Nicolas Bell and the advisory board of CPD Dubai are to be congratulated on their forward thinking initiative which will promote team-working and enhance patient care."

Claire Wilson, a dental hygienist at Virginia Dental Clinic in Dubai attending the training, said, "The speaker was fantastic, very informative. The venue was brilliant too. I couldn't fault the day. I'm really enthusiastic about taking what I've learnt back to my colleagues in my practice and I'm hoping to come on more courses."

Hannah Keannie, a dentist at the Dubai London Clinic said, "I really enjoyed the event. Dr Raj was an excellent speaker, who made sure everyone felt involved and delivered very engaging training. The programme was perfect for me as it counts towards both my accredited CPD hours for my DHA licence and helps me fulfil one of the 'core topics' required by the General Dental Council in the UK so I can maintain my licence at home too."

Nicolas Bell, of CPD Dubai, agreed, "It's not just UK licensed dentists based in the UAE though. Because of the attractiveness of Dubai as a desti-



nation and an increase in the amount of quality training being provided, we are starting to receive more enquiries from dentists in the UK who are happy to visit Dubai and attend course which will count towards their verifiable hours in the UK."

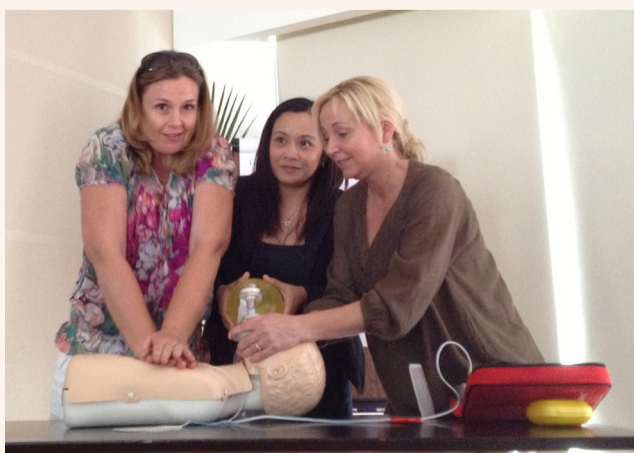When asked about what CPD Dubai planned for the future, he went on to say, "We have a number of lecture days running after the summer and further events, currently in the development stage, are scheduled for the end of this year and early 2014. We have an excellent speaker flying

in from the UK in October to run a couple of training events. Dr Johal is a leading authority in sleep-related breathing disorders and lectures throughout the UK and abroad. This is a really interesting topic for dentists to get involved with and it can be both professionally and financially rewarding. There is growing public awareness of sleep-related breathing disorders and the treatments available to combat them. Provision of mandibular advancement splints, constructed by a dentist, can offer an effective solution to conditions such as simple snoring right through to

obstructive sleep apnoea. The one-day training programme will give dentists a comprehensive understanding of the topic and will enable them to comprehensively assess patients and to treat suitable candidates safely." DT




### Contact Information

Information on CPD Dubai, licence renewal requirements and upcoming courses can be found at: [www.cpd-dubai.com](http://www.cpd-dubai.com)




UNDER THE HIGH PATRONAGE OF HIS EXCELLENCY  
THE PRESIDENT OF THE REPUBLIC OF LEBANON  
**GENERAL MICHEL SLEIMAN**

**Beirut International Dental Meeting 2013**

*Sharing Solutions*



L D A  
15  
CREDIT POINTS

المؤتمر الثاني والاربعون لاتحاد أطباء الاسنان العرب  
مؤتمر بيروت الدولي الثالث والعشرون لطب الاسنان

42<sup>ND</sup> CONFERENCE OF THE ARAB DENTAL FEDERATION  
23<sup>RD</sup> BEIRUT INTERNATIONAL DENTAL MEETING

Lebanese University RAFIC HARIRI Campus, Hadath  
September 25-28, 2013

BIDM 2013



# EUROPEAN UNIVERSITY COLLEGE

(formerly NICOLAS & ASP UNIVERSITY COLLEGE)

## FIRST INTERNATIONAL POSTGRADUATE DENTAL INSTITUTION IN THE REGION

### MASTER DEGREE IN ORTHODONTICS

In cooperation with  
**Malmö University**  
in Sweden

Leads to Royal College  
Membership (MOrth)

Accredited by:  
MOHESR-UAE

### MASTER DEGREE IN PEDIATRIC DENTISTRY

GA & OR Facilities &  
Special Needs Care

Leads to Royal College  
Membership (MPaed)

Accredited by:  
MOHESR-UAE

### MASTER DEGREE IN ENDODONTICS

Operating Microscope  
Facilities, Computerized  
Radiography

Leads to Royal College  
Membership (MEndo)

Accredited by:  
MOHESR-UAE

### DIPLOMA IN ADVANCED EDUCATION IN GENERAL DENTISTRY

Operating Microscope  
Facilities, Computerized  
Radiography

Accredited by:  
MOHESR-UAE

### HIGH DIPLOMA IN ORAL IMPLANTOLOGY

Comprehensive Clinical  
Training on Surgical &  
Implant Restoration

CBCT Diagnosis and  
Treatment Planning

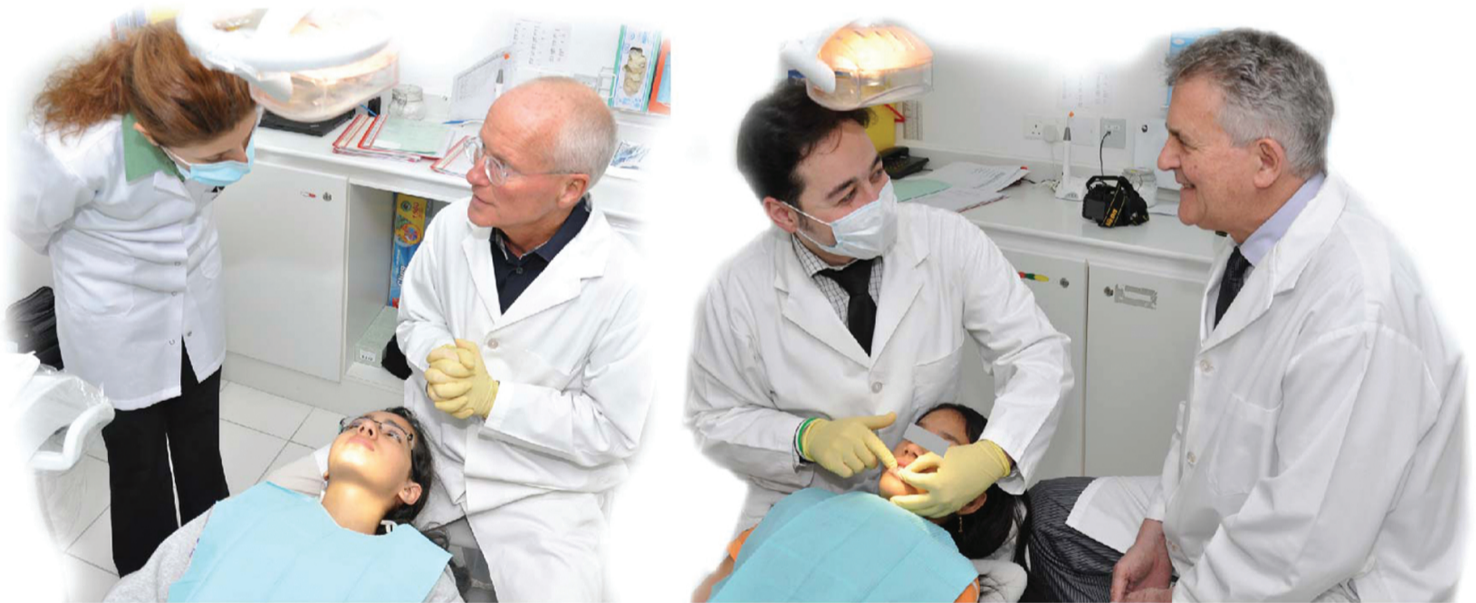Accredited by:  
MOHESR-UAE

**APPLY NOW**

MASTER DEGREE IN  
RESTORATIVE and  
PROSTHODONTICS

ASSOCIATE DEGREE IN  
DENTAL ASSISTING

- Accredited by The Ministry of Higher Education & Scientific Research (UAE)
- In Cooperation with Swedish Universities
- Accredited by the International Association of Universities (UNESCO)
- Teaching Faculty from reputed American & European Universities
- All programs include strong theoretical & clinical training
- Global pool of international students from Asia, Europe & the Middle East



CURRICULUM RECOGNIZED BY ROYAL COLLEGE OF EDINBURGH  
EUC ORTHODONTIC GRADUATES EXEMPTED FROM THE WRITTEN EXAMINATION

**ADMISSIONS FOR 2014 IS CURRENTLY OPEN**



+97143624787

[www.euc.ac.ae](http://www.euc.ac.ae)

[info@dubaipostgraduate.com](mailto:info@dubaipostgraduate.com)





# Immediate Rehabilitations Of Atrophic Jaws Using Tilted Implants

*mCME articles in Dental Tribune have been approved by HAAD as having educational content for CME credit hours. This article has been approved for 2 CME credit hours.*

**ADA C.E.R.P.**® | Continuing Education Recognition Program

Centre for Advanced Professional Practices (CAPP) is an ADA CERP Recognized Provider. ADA CERP is a service of the American Dental Association to assist dental professionals in identifying quality providers of continuing dental education. ADA CERP does not approve or endorse individual courses or instructors, nor does it imply acceptance of credit hours by boards of dentistry.

*CAPP designates this activity for 2 continuing education credits.*

By Enrico Agliardi, Matteo Clericò, Matteo Consonni, Davide Romeo

Since many years, rehabilitation according to the Brånemark protocol (Toronto-Bridge) has represented the gold standard in case of full-arch fixed implant hybrid prostheses 1. This approach consists in four to six implants, axially placed in the pre-maxilla or in the interforaminal region of the mandible, supporting a fixed bridge with bilateral distal extensions (cantilevers) 2. Implant and prosthetic success rates were very high also in the long-term, exceeding 20 years of follow-up 3,4. The original protocol entailed a healing period of at least 3 months for the mandible and 6 months for the maxilla, necessary for the osseointegration of the implants before the prosthetic phases can start 1. Professor Brånemark, who stated the first protocol for implant dentistry 1, considered that period of time necessary for the integration of the implants. Today, this prerequisite is no longer fundamental for the final success of the rehabilitation and implants can be loaded immediately after their placement.

In fact, as testified by recent consensus reports and systematic reviews 5,6, full-arch rehabilitations and immediate function seems to be a predictable approach if precise guidelines during surgical and immediate prosthetic phase are followed. In all those papers, authors pointed out that the key factor for the immediate function seems to be a minimum implant primary stability of 30 Newton 7. This can be achieved by using specific implant morphologies and osteoconductive surface in combination with a proper preparation of the surgical site that can guarantee a press fit of the implant and a stable bone engagement 8. Therefore, a rigid splinting of implants with a fixed bridge is also important to provide a firm fixtures stabilisation under occlusal load 9.

## The use of tilted implants

The trend in modern implant dentistry is the reduction of number of fixtures supporting a full-arch fixed restoration as well as the time elapsing between surgical phase and prosthetic loading. The lowest number was proposed with the Brånemark Novum concept 10, in which three implants of 5-mm diameter were inserted in the interforaminal area with the help of a surgical guide and prefabricated components. This approach was not very versatile because of the prefabricated components and it was indicated only in patients with a specific mandibular morphology and occlusal relationship. Therefore, the loss of one fixture led to complete failure of the prosthetic structure in a high percentage of patients. These results led to the conclusion that at least four implants, properly distributed, are required to support a fixed prosthesis and ensure long-term success. Earlier studies on immediate loading rehabilitations have included a high number of dental implants 11, specifically when applied in the maxilla because of its poor bone density, but

recent reports have shown good outcomes with the use of only four or six implants.

In a recent technique called All-on-4™ (Nobel Biocare AB, Göteborg, Sweden) 12,13, Paulo Malo proposed the use of two anterior implants placed axially in region of lateral incisors and two posterior fixtures tilted between 30 to 45 degrees relative to the occlusal plane. A provisional screw-retained prosthesis with 10 teeth can be delivered after few hours from the surgery, while the final restoration will be made after 6 months. Medium-term results are very encouraging; Malo reported 98.5% implant survival rate for 867 mandibular dental implants followed up for 10 years 14, while Agliardi showed 98.36% in the maxilla and 99.73% in the mandible, respectively, up to 60 months of loading 15.

One of the innovative aspects of this technique is the inclination of the distal implant, which offers surgical and prosthetic advantages. By tilting the implants, it is possible to place longer fixtures and achieve higher levels of primary stability because of the greater implant surface in contact with the bone 16. Furthermore, the area of emergence of the inferior alveolar nerve and the anterior wall of the maxillary sinus are characterised by a good bone quality and this enables clinician to find a solid mechanical support. Therefore, when implants are tilted distally, the prosthetic cantilever is also reduced. Further prosthetic consequences from implant

inclination consist of an increased interimplant distance, the creation of a more regular prosthetic polygon and an increase in the anteroposterior (AP) spread 17 compared with the Toronto-Brånemark rehabilitation, especially in mandibles of a rectangular shape. With the reduction of the number of platforms, it is easier to achieve a passive prosthetic fit, both for the provisional and for the final rehabilitation. Patients can also maintain optimal levels of oral hygiene because of the fewer number of surfaces and the wider distance between implants.

Tests on models and by finite element analysis performed on single angulated implants showed that tilting implants may increase the stress to surrounding bone. Tilted fixtures may also be subjected to bending, possibly increasing the marginal bone stress. However, when the implant belongs to a multiple implant-supported prosthesis, the spread of the implants and the rigidity of the prosthetic structure should reduce the bending 18,19. Furthermore, no difference in the marginal bone loss between tilted and axially placed implants placed either jaw has been reported 20, suggesting that tilting of the implants causes no detrimental effect on the osseointegration process.

## Immediate full-arch fixed prostheses

Immediate loading procedures have gained high popularity among clinicians. The reduction of total time

of treatment and the possibility to deliver a functional implant bridge few hours after the surgery represent a notable advantages for patients. Therefore, partial edentulous patients with a failing residual dentition can avoid the psychological trauma and discomfort of a transitional removable prosthesis 21.

The rehabilitation of edentulous jaws is often complicated by a reduced bone quantity, especially in poster region, because of the pneumatization of maxillary sinus or for the superficialization of the inferior alveolar nerve. To face these limitations, clinicians have different therapeutic options, such as long distal cantilever 22, the use of short fixtures 23, sinus lift and bone augmentation 24 or implants placed in specific anatomical areas such as pterygoid region 25, the tuber 26 or the zygoma 27.

Any of these procedures requires surgical and prosthetic expertise and has its own advantages, limits, risks and complications, involving sometimes high biological and financial costs. In the last years, different clinical studies assessed tilted implants as a feasible treatment option, with encouraging results in the medium term and no difference in bone loss compared to axially placed fixtures.

## Case report

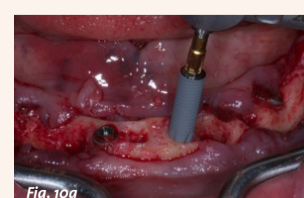
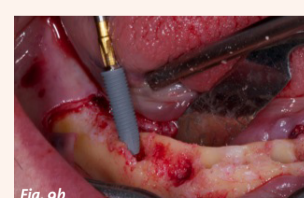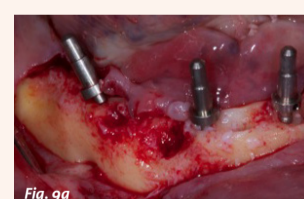
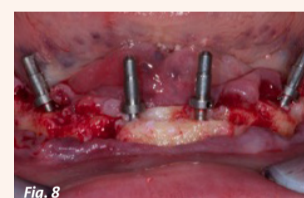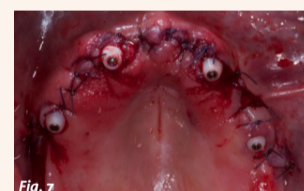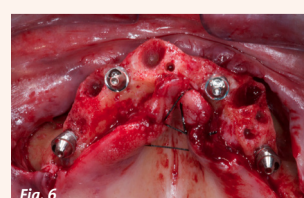
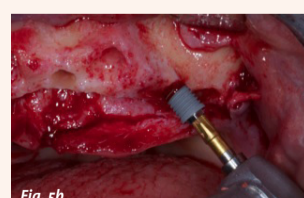
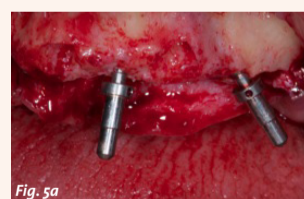
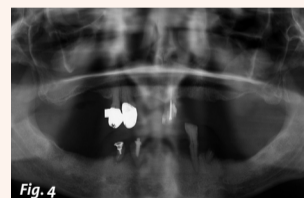
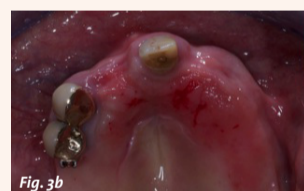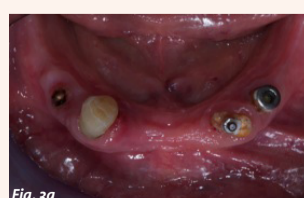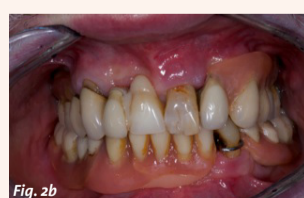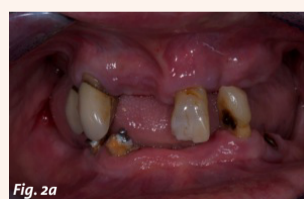A 62-years old male patient was referred to our office with a precise chief complain: fixing his failing dentition without going through multiple sur-

geries and in a relative short period of time (Fig. 1). His functional and esthetic demand was high, but he has financial limitations. He has removable partial prosthesis in both jaws, but now the mobility of the remaining teeth due to an advanced periodontal disease has compromise their stability in the mouth (Fig. 2-6). Therefore, he was not satisfied of his actual smile. After discussing possible treatment options, we decided to exclude extensive bone grafts (sinus lift with lateral approach) and to use the residual bone available, restoring both arches with a hybrid titanium prosthesis supported by two anterior axial and two posterior angled fixtures, according to the All-on-4™ concept. Final prosthesis will be realized with titanium CAD/CAM framework with nano-hybrid composite teeth (SR Phonares® II, Ivoclar Vivadent) and using the IvoBase® Injector.

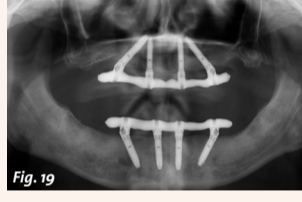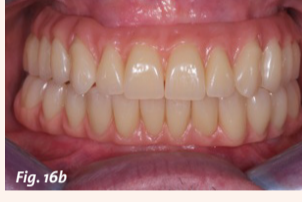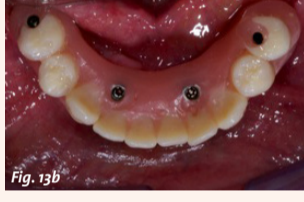
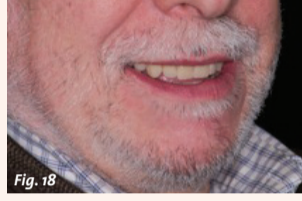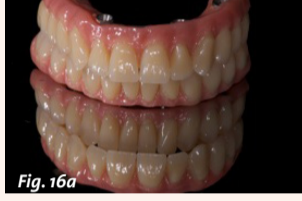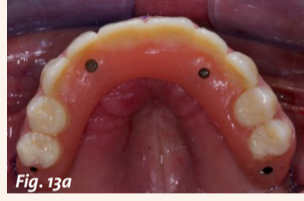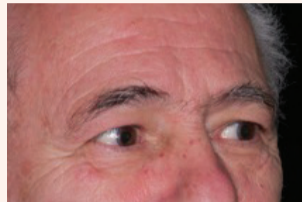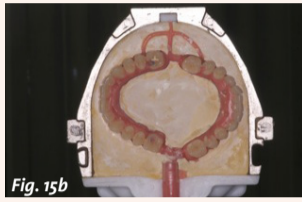
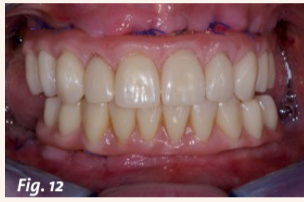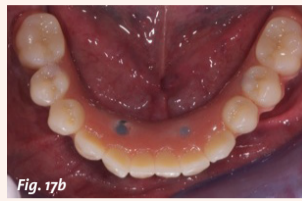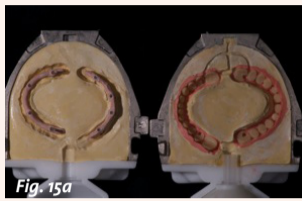
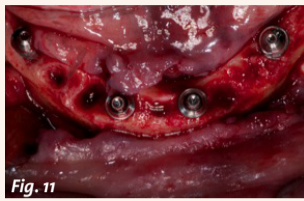
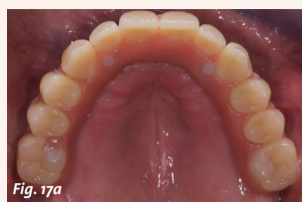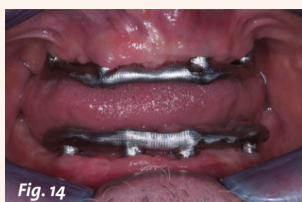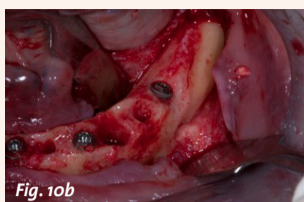
## Surgical and prosthetic phases

Implant surgery was done under intravenous sedation, starting with the upper jaw. After local anesthesia, compromised teeth were a-traumatically extracted and sockets were carefully debrided with sterile saline solution. Mid-crestal incision was done in keratinized gingiva starting from first molar region to contralateral side and a mucoperiosteal flap was elevated exposing the vestibular bony wall and the palatal mucosa. Bone crest regularization was done with bony forceps and rotary instruments whenever necessary. Distal implants were placed throughout the anterior sinus wall with an inclination of 40 degrees relative to the occlusal plane (Fig. 7,8), while two anterior fixtures were placed axially in positions of lateral incisors (Fig. 9). All implants have been inserted with a final torque of 50 Ncm. Angulated multi-unit abutments were connected to the tilted implants, while standard abutments were placed over anterior fixtures (Fig. 10). Sockets were filled with autogenous bone before closing the flap (Fig. 11). Same procedure was done for the mandible, with the placement of posterior tilted implants close to the mental nerve foramen and two anterior axial fixtures (Fig.12-17). A fundamental part of the procedure consists in detecting the mental foramen, isolating the emergence of the inferior alveolar nerve and evaluating the presence or not of the anterior loop with a periodontal probe. This structure represents the posterior anatomical limit for this type of rehabilitation.

Once the surgical phase was finished, polyether impressions and vertical dimension registration were taken. Three hours after, full acrylic provisional bridges with 10 teeth were delivered, keeping full contacts in maximum intercuspation from canine to canine and avoiding any lateral excursion (Fig. 18-20). After six months, final restorations with titanium CAD/CAM Procera® titanium frameworks (Nobel Biocare) were made and full occlusion with 12 teeth were given (Fig. 21-29).







**Legends**

Fig. 1 This 62-years old patient presented with a clear chief complain: "improve my smile with a fixed restoration"

Fig. 2a e 2b Intra-oral view showed few remaining teeth in the upper jaw and residual roots on the mandible. Partial removable prosthesis did not provided comfort during mastication and esthetic appearance anymore

Fig. 3a e 3b Occlusal view of both arches with an adequate amount of keratinized gingiva

Fig. 4 Panoramic x-ray evidenced bone loss in both arches due to chronic generalized periodontitis, with horizontal resorption and endo-perio lesions in the mandible. The extensive sinus pneumatization did not allow posterior implants placement without a preliminary sinus augmentation procedure.

Fig. 5a and 5b Note the inclination of posterior surgical site compared to the anterior one. Thanks to the inclination, the posterior implant can be placed following the anterior sinus wall, getting an high level of primary stability.

Fig. 6 Occlusal view showing implants distribution along the anterior maxilla. All implants have been placed with a 50 Newton torque. 30 degrees abutments are positioned in the posterior implants to correct their inclination, while 17 degrees abutments are screwed on the anterior fixtures for a favourable emergence of the prosthetic screw on the palatal side.

Fig. 7 Post-extraction gaps were filled with autogenous bone before flap closure. The flap is sutured in a way to create a minimum 2 mm collar of keratinized gingiva all around every abutment. This peri-implant seal will be very important for the long-term maintenance of the entire rehabilitation.

Fig. 8 Four verification pins evidenced the direction of surgical sites and the inclination of posterior osteotomies.

Fig. 9a and 9b After isolation of mental nerve and verification of a possible anterior loop, the preparation of the surgical site is conducted with a mesio-distal 30 degrees inclination, trying to engage the bone area anterior to the mental foramen without crea-

ting nerve injury. Implant is placed in an underprepared surgical site to increase primary stability.

Fig. 10a and 10b Anterior implants are axially inserted in position of lateral incisors.

Fig. 11 Occlusal view of mandibular implants with abutments.

Fig. 12 Provisional acrylic prosthesis containing ten teeth were delivered three hours after the surgery

Fig. 13a and 13b Full occlusal contacts are limited between canines with no lateral excursions

Fig. 14 Verification of passive fit of titanium CAD/CAM frameworks

Fig. 15a and 15b Final prosthesis will be realized with titanium CAD/CAM framework with nano-hybrid composite teeth and using the IvoBase \* Injector.

Fig. 16a and 16b Final bridges containing 12 teeth

Fig. 17a and 17b Occlusal view of final prosthesis with limited posterior cantilevers

Fig. 18 Lateral view of patient's smile with the final restorations

Fig. 19 Panoramic radiograph after one year of loading showing implants distribution and bone level maintenance.

**References**

1. Brånemark PI, Hansson BO, Adell R, Breine U, Lindstrom J, Hallen O, Ohman A. Osseointegrated implants in the treatment of the edentulous jaw. Experience from a 10-year period. *Scand J Plast Reconstr Surg Suppl.* 1977;16:1-132.
2. Branemark PI, Svensson B, van Steenberghe D. Ten-year survival rates of fixed prostheses on four or six implants ad modum Branemark in full edentulism. *Clin Oral Implants Res* 1995; 6: 227-231.
3. Adell R, Eriksson B, Lekholm U, Branemark PI, Jemt T. Long-term follow-up study of osseointegrated implants in the treatment of totally edentulous jaws. *Int J Oral Maxillofac Implants* 1990; 5: 347-359.
4. Ekelund JA, Lindquist LW, Carlsson GE, Jemt T. Implant treatment in the edentulous mandible: a prospective study on Branemark system implants over more than 20 years. *Int J Prosthodont* 2003; 16: 602-608.

5. Esposito M, Grusovin MG, Achille H, Coulthard P, Worthington HV. Interventions for replacing missing teeth: different times for loading dental implants. *Cochrane Database Syst Rev* 2009; CD003878.

Full list of references is available from the author. [DTI](#)

**Contact Information**


Dr. Enrico L. Agliardi obtained his Doctorate in Medicine from the University of Milano (Italy) and he specialized in Maxillofacial surgery and Orthodontics from the same university.



**Contact**  
e-mail: info@studioagliardi.it

**Contact Information**

Dr. Davide Romeo graduated in dentistry at the University of Milano, Italy. He received his PhD in new Techniques in Oral Prostheses and Rehabilitation from the same university and he attended the Full time Advanced Program in Periodontics at New York University.



**mCME SELF INSTRUCTION PROGRAM**

CAPP with Dental Tribune with its mCME- Self Instruction Program gives you the opportunity to have a quick and easy way to meet your continuing education needs. mCME offers you the flexibility to work at your own pace through the material from any location at any time. The content is international, drawn from the upper echelon of dental medicine, but also presents a regional outlook in terms of perspective and subject matter.

**Membership:**  
Take membership for one year by subscription for the newspaper: 600 AED  
Take article with one newspaper subscription: 100 AED per issue.

After the payment, you will receive your membership number and will be able to start the program.

- Completion of mCME**
- mCME participants are required to read a continuing medical education (CME) article in each issue.
  - Each article offers 2 CME Credit and followed by quiz questioner, which is available in <http://www.cappmea.com/mCME/questionnaires.html>.
  - Each quiz has to be return to [events@cappmea.com](mailto:events@cappmea.com) or fax to: +971436868883 in three months form the publication date
  - A minimum passing score of 80% must be achieved in order to claim credit
  - Not more then two answered questions can be submitted in the same time
  - Validity of the article – three months
  - Validity of the subscription – one year
  - Collection of Credit hours: you will receive the summary report with Certificate maximum one month after expire date of your membership. For single subscription Certificate and summery report will be send one month after the publication of the article.

The answers and critiques published herein have been checked carefully and represent authoritative opinions about the questions concerned.

Articles are available in [www.cappmea.com](http://www.cappmea.com) after the publication. For more information please contact [events@cappmea.com](mailto:events@cappmea.com) or +971 4 3616174

**FOR INTERACTION WITH THE WRITERS FIND THE CONTACT DETAIL AT THE END OF EACH ARTICLE.**

Explore new frontiers of learning



Admissions now open

Accreditation & Memberships

**DMD - Doctor of Dental Medicine**

Internationally recognized curriculum • Own teaching hospital • State of the Art Phantom head and Dental Simulation Laboratories • Summer Training Program • Clinical training at different sites across UAE. • A team of highly experienced and qualified faculty. • All programs approved and Accredited by Ministry of Higher Education and Scientific Research (MOHESR)

- GMU ALSO OFFERS**
- MBBS** - Bachelor of Medicine & Bachelor of Surgery
  - BPT** - Bachelor of Physical Therapy | **Pharm D** - Doctor of Pharmacy
  - MS CP** - Master of Science in Clinical Pathology
  - MTox** - Master in Toxicology | **MPH** - Master in Public Health
  - MS HRB** - Masters in Human Reproductive Biology
  - DipTox** - Post Graduate Diploma in Toxicology



P. O. Box: 4184, Ajman, United Arab Emirates, Tel: +971 6 7431333, Fax: +971 6 7431222  
E-mail: [admissions@gmu.ac.ae](mailto:admissions@gmu.ac.ae) Web: [www.gmu.ac.ae](http://www.gmu.ac.ae)

COLLEGE OF MEDICINE | COLLEGE OF ALLIED HEALTH SCIENCES  
COLLEGE OF PHARMACY | COLLEGE OF DENTISTRY | COLLEGE OF GRADUATE STUDIES  
CENTER FOR CONTINUING EDUCATION AND COMMUNITY OUTREACH





## Air Polishing

*mCME articles in Dental Tribune have been approved by HAAD as having educational content for CME credit hours. This article has been approved for 2 CME credit hours.*

By Salim Rayman, RDH, MPA, and Elvir Dincer, DDS

The concept of air polishing is based on a technology developed by Dr. Robert Black in 1945. Black invented a device called the Air Dent, which used compressed air, water and a highly abrasive powder to eliminate pain from cavity preparation, making anesthesia unnecessary.

While the Air Dent presented many problems, the technology represented the first step in air-polishing devices. Air polishing was first marketed in 1976, and from that time forward it became widely available. Air-powder polishing is accomplished by the propulsion of abrasive particles through a mixture of compressed air and water through a handpiece nozzle. The handpiece nozzle through which the slurry is propelled is activated with a foot control. The air pressure produced, measured in pounds per square inch (psi), depends on the type of air-powder polisher being used.

Air-powder polishers are manufactured as separate handpiece units that attach directly to the air/water connector on the dental unit as a separate device or in combination with an ultrasonic scaler.

### Indications for use

Coronal polishing is a cosmetic procedure designed to remove extrinsic stains from the enamel surfaces of the teeth. This can be accomplished by abrasion and erosion of the extrinsic stain. The most common technique for stain removal is rubber cup polishing. This technique uses an abrasive polishing agent and a slowly revolving polishing cup to abrade stain from the tooth surface. Air-powder polishing is accomplished by erosion of extrinsic stains by suspended abrasive particles within a moving fluid. Kinetic energy propels the air-powder polishing slurry particles against the tooth surface, thus removing stain (Figs. 1a, b).

The air-powder polisher is shown to be efficient, safe and effective in removing extrinsic stain and plaque biofilm from tooth surfaces. It is equally effective in decreasing root surface roughness after instrumentation. It is also reported to remove plaque biofilm and staining as effectively as a rubber cup and does so in less time.<sup>2</sup> Patients often exhibit extensive staining on root surfaces, specifically on areas of recession and at the cemento-enamel junction. Removing these stains with a curet has been shown to reduce root structure. However, when stain removal is for esthetic reasons, the air-powder polisher is preferable to the curet. The air-powder polisher removes less root structure than the curet in simulated three-month recalls for three years. The stain was also removed more than three times faster with the air-powder polisher.<sup>5</sup>

Using the air-powder polisher also creates less discomfort for patients who have dental hypersensitivity because the sodium bicarbonate particles embed in the dentinal tubules, lessening dentinal hypersensitivity discomfort almost immediately. In vitro, research has shown that there is little or no disruption of enamel, cementum and dentin surfaces with air-powder polishing.

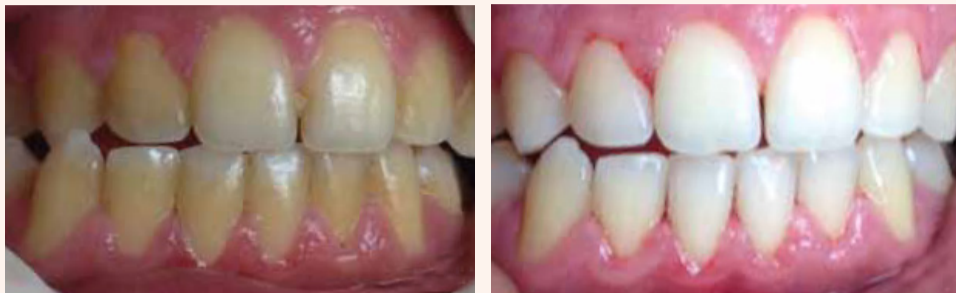

Fig. 1a,b Removal of extrinsic stains. (Photo/Provided by Yosi Behroozan, DDS, DENTSPLY Professional)



Fig. 2 Jet Fresh prophyl powder. (Photos/Provided DENTSPLY Professional unless otherwise noted)

Other research has shown that air-powder polishing can render cementum surfaces more uniformly smooth, compared with traditional polishing or the use of curets.<sup>5</sup>

The air-powder polisher can remove subgingival bacteria through the Venturi effect. This occurs when the air/water/powder spray is directed at a 90-degree angle to the interproximal spaces so that a vacuum is created that extracts tissue fluids, including subgingival bacteria from the subgingival space. The air-powder polisher has been used for debridement of Class V abraded areas before placement of glass ionomer cements.

When compared with cleaning the area with a rubber-cup polisher, the air-powder polished tooth had less microleakage around the enamel-cement interface. Similar results were noted when using the air-powder polisher before sealant application. It was reported to be superior to rubber-cup polishing in preparing enamel for etching and sealants. Deeper resin penetration into enamel and increased sealant bond strength was also reported in comparison with traditional polishing with pumice and water. In addition, clinicians prefer using the air-powder polisher on orthodontic patients, and research has shown that it does not affect the bracket adhesive system.

### Types of powder

The most common type of abrasive particle used with the air-powder polisher is sodium bicarbonate, which is treated to be free-flowing with calcium phosphate and silica. Sodium



Fig. 3 Fill the powder chamber with an abrasive recommended by the manufacturer.

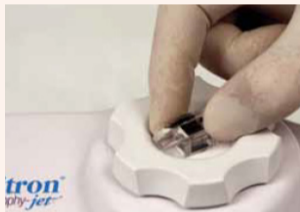

Fig. 4 Powder control knob.

bicarbonate is a food grade material, and each particle is approximately 74 mcm in size. The Mohs' scale hardness number for sodium bicarbonate is 2.5. In comparison, Pumice has a Mohs' hardness number of 6.

Sodium bicarbonate is safe for use on enamel, amalgam, gold, porcelain, implants (titanium) and orthodontic materials. However, its use should be avoided on all types of composites, glass ionomers and luting agents (cements).<sup>13</sup> When used on implants, air polishing with sodium bicarbonate, should not be directed subgingivally, thus it is the method of choice for decontamination of implants.

A sodium-free powder for air-powder polishing is available (Fig. 2) (Jet Fresh from DENTSPLY Professional, York, Pa.). Developed for patients who are sodium intolerant, this powder is made of aluminum trihydroxide, which has a Mohs' hardness number of 2.5 to 3.5 and a particle range in mesh size from 80 mcm to 325 mcm.

Aluminum trihydroxide powder is safe for enamel; however, it is too abrasive for use on other tooth structures, and its use should be avoided on all dental materials. While using aluminum trihydroxide does not cause surface disruption to porcelain, its use can remove the luting agent, causing a compromise in the margin integrity that can quickly lead to decay.<sup>4</sup>

### Patient assessment

Because of the various indications and contraindications associated with use of the air-powder polisher, patient assessment and treatment planning are critical prior to use. The patient assessment process should include a thorough health history evaluation to identify and possibly rule out patients who have hypertension and/or are on a physician-directed, sodium-restricted diet. However, the amount

of sodium bicarbonate ingested during air polishing is not sufficient to cause alkalosis or an increase in blood pressure or sodium levels in the blood.

Other patients who are contraindicated include those who have end-stage renal disease, are immunocompromised, have a communicable infection or have Addison's or Cushing's disease. In addition, patients with respiratory problems, such as chronic obstructive pulmonary disease or any condition that interferes with breathing or swallowing, should be treated with an alternative approach. Such patients could be compromised by the aerosols created by airpowder polishing, and they are also vulnerable to the development of pneumonia.<sup>4</sup>

Contraindications for using the air-powder polisher also include patients taking potassium, anti-diuretics or steroid therapy — all of which can disrupt the acid/base balance. Contraindications for use of the air-powder polisher also extend to the hard and soft tissues; therefore, the dental history assessment is paramount. Hard tissue that presents with any composite resins, sealants or glass ionomers should be avoided because of susceptibility of those materials to surface roughness or pitting.

Porcelain margins and margins of all restorations can be altered by extensive exposure of the airpowder polisher, and this can lead to loss of marginal integrity, surface roughness, staining and pitting.<sup>1</sup> Exposed cementum or dentin, because they are not as mineralized as enamel, are more susceptible to abrasion. In addition, patients who present with active periodontal conditions with soft and spongy tissue are contraindicated because the air-powder polisher can cause air embolism or small blood clots. Lastly, pediatric patients with deciduous teeth or newly erupted permanent teeth are contraindicated.

### Patient preparation

It is with utmost importance that before using the air-powder polisher, clinicians must prepare themselves and their patients. Patient preparation would include a thorough explanation of the procedure, review of medical history and taking of blood pressure. The clinician should place a disposable or plastic drape over the patient's clothing, provide the patient with safety glasses and confirm removal of contact lenses. The clinician should make sure the patient is in a more upright position. A non-petroleum lubricant should be applied to the patient's lips to protect them from the abrasive spray, which can dry the lips.

Research has confirmed that when the clinician performs air-powder polishing, aerosols of microorganisms can contaminate surfaces several

feet from the operative site. Instructing the patient to use an antimicrobial preprocedural rinse, such as 0.12 percent chlorhexidine, can reduce risk of bacterial contamination from these aerosols.

### Air-powder polishing unit and operator preparation

The clinician should be properly protected when performing air-powder polishing. Standard precautions include wearing fluid-resistant protective apparel, using a face shield or protective safety glasses with side shield and wearing gloves and a well-fitting mask with high filtration capabilities. In addition, because of the risk of contamination from the aerosols, the use of a high-speed evacuation system is recommended. Clinicians should always follow the manufacturer's user directions that are specific to the air-polishing unit being used.

Unit preparation includes obtaining all necessary equipment, such as the air-powder polishing unit and abrasive powder, according to patient selection.

The unit and handpiece nozzle is prepared according to manufacturer's directions, and the powder compartment is filled with the appropriate abrasive recommended for the machine being used (Fig. 3). The unit should be turned on for at least 15 seconds to eliminate residual powder or moisture in the lines. Also, water lines need to be flushed before use, according to the recommendations of the Centers for Disease Control and Prevention. When the unit's hamber is being filled with abrasive powder, the unit must be turned off. It needs to be filled with powder to the top of the center tube. The clinician can place a finger over the tube in the middle of the chamber to prevent powder from blocking the air line. Next, the clinician needs to use the control on top of the powder chamber cap to adjust the powder flow according to the patient's needs. For treating patients with heavy stains, it is recommended that the control knob should be turned to "H" for heavy powder flow, which is approximately the 12 o'clock position. For patients with light staining, the control knob will be set to "L" for reduced powder flow, which is approximately the 6 o'clock position (Fig. 4).

An aerosol-reduction device that connects to the saliva-ejector or high-speed-evacuation system used with the air-polisher handpiece has been shown to be effective in controlling and reducing airpowder aerosols, thus decreasing the potential for disease transmission. The aerosol-reduction device reduces or eliminates the visible aerosols normally produced during air-powder polishing. Additionally, the aerosol-reduction device (Fig. 5) eliminates the need for exact angulations with cup/nozzle, use of gauze, hand cupping and patient positioning.

Another advantage to the aerosol-reduction device is that it minimizes the possibility of tooth abrasion because the cup is placed on the tooth — as in traditional polishing techniques. When using the aerosol-reduction device, the clinician must follow the manufacturer's instructions for assembling and disassembling. The aerosol-reduction device contains two

ADA C.E.R.P.® | Continuing Education Recognition Program

Centre for Advanced Professional Practices (CAPP) is an ADA CERP Recognized Provider. ADA CERP is a service of the American Dental Association to assist dental professionals in identifying quality providers of continuing dental education. ADA CERP does not approve or endorse individual courses or instructors, nor does it imply acceptance of credit hours by boards of dentistry.

CAPP designates this activity for 2 continuing education credits.





Fig. 5 Aerosol-reduction device. (Photo/Provided by DENTSPLY/ Raintree Essix)

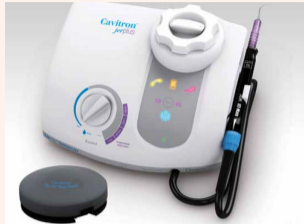

Fig. 6 DENTSPLY Cavitron Jet Plus with Tap-On technology.



Fig. 7 Setting options for Propphy Mode Auto Cycles: Manual, Short, Medium and Long.

parts, a disposable cup that attaches to the air-powder polisher nozzle and a clear tube extension that is attached to the saliva ejector or high volume evacuator (HVE).

*‘The patient assessment process should include a thorough health history evaluation to identify and possibly rule out patients who have hypertension and/or are on a physician-directed, sodium-restricted diet.’*

**Clinical technique**

There is a universal air-powder polishing technique that can be used with all types of systems, however manufacturers may have different instructions for use of their equipment.<sup>4</sup> The recommended technique prevents undue aerosols from deflecting back to the clinician or being directed into the patient soft tissues. The use of high-speed evacuation or the aerosol-reduction device is the most efficient way to control the aerosol spray. While positioning of the patient and operator are basically unchanged, direct vision and access become elementally important when the polisher is active.<sup>20</sup>

Positioning the patient slightly upright at 45 degrees with the patient’s head toward the operator to access areas — and reclining to treat maxillary lingual surfaces — provides a better field of vision and increase patient comfort. Placing moistened 2-by-2-inch gauze square over the tongue or on patient’s lip near the work area will help reduce burning and stinging experienced by some patients. The rheostat has two compressions levels: Full compression releases the aerosol powder-abrasive from the tip, and halfway compression produces a stream of water for rinsing and cleaning. Before the polisher is activated in the patient’s mouth, it is recommended that the clinician check the amount of water and powder coming from the unit, test the sensitivity of the alternating cycles and confirm the powder-to-water ratio.<sup>20</sup>

The clinician should establish and maintain a systemic pattern when using the air-powder polisher. The nozzle tip should maintain an appropriate distance from the tooth surface (approximately 3 to 4 mm). Holding the nozzle farther away from the tooth surface is not recommended because that reduces the abrasive action and increases aerosol production. Cupping the lip with the index finger and thumb to pool water in vestibule minimizes aerosol and eases evacuation. The nozzle tip also should be angled diagonally so that the spray is directed toward the middle third of the tooth.

The clinician should use a constant circular motion, sweeping or paint-brush motion from interproximal to interproximal. In addition, a systemic approach of polishing one or two teeth at a time will ensure that all tooth surfaces are adequately

polished. And alternate cycles of full-compression powder-spray and half-compression rinse every two or three teeth will increase efficiency and patient comfort.<sup>20</sup> The clinician must polish each tooth approximately one to two seconds; and to avoid loss of tooth structure, not subject any tooth to more than 10 seconds of air-polish slurry. Root surfaces should be exposed to slurry for even less time or entirely avoided because they abrade more rapidly than enamel.

The DENTSPLY Cavitron Jet Plus™ has Tap-On™ technology (Fig. 6) that automatically cycles between rinse and polish, thus eliminating the need for the clinician to pump the pedal. Tapping the foot pedal once activates the Tap-On automatic air polishing/rinse cycle, which lasts for approximately one minute. Tapping the pedal a second time disables the automatic air polishing/rinse cycle.

The autocycles work in short, medium or long settings (Fig. 7) within timed cycles of one minute. Each cycle begins with a two- to three-second stream of water. The “short” autocycle is 0.75 seconds of airpowder polishing followed by a 1.25-second rinse; the “medium” autocycle is two seconds of air-powder polishing followed by a one-second rinse; and the “long” autocycle is three seconds of air-powder polishing followed by a two-second rinse. The “manual” cycle setting enables the clinician to use the Tap On foot technology control to alternate manually between air-powder polishing and rinse.

When air-polishing the anterior teeth, the tip should be directed at a 60-degree angle to the tooth; for posterior teeth the angle should be 80 degrees; and for occlusal surfaces, a 90-degree angle is recommended. Using the aerosol-reduction device, the clinician will apply the disposable cup (attached to the nozzle) to the middle third of the tooth with light pressure to flare the cup. The clinician will then pivot the nozzle inside the cup to adapt to all areas of the tooth surface and polish for two seconds of spray for each segment of tooth.

**Completion of air-polishing procedure**

At completion of the air-polishing procedure, the clinician should rinse the teeth thoroughly, floss all interproximal surfaces and inspect the teeth for any remaining stain. Thorough rinsing is essential after air-powder polishing because of the basic nature of the sodium bicarbonate.<sup>20</sup>

If stain is still present, reinstrumentation and/or use of the air-powder polisher may be indicated. Any debris should be wiped off the patient’s face with a moist towel. And a re-application of lip balm should be offered. The aerosol-reduction device should

be disposed of and the nozzle should be cleaned with a wirecleaning tool to prevent clogging. Nozzle tips must be autoclaved after each use, and the entire unit should be disinfected with an EPA-approved disinfectant. Using a disposable barrier will help minimize disinfecting time.

At the end of the workday, the unit should be turned off, powder removed from chamber and unused powder discarded to prevent clogging of lines. Also, keep the powder chamber and air lines free of moisture, which can cause the system to fail.<sup>22</sup> The clinician then needs to remove any residual powder from the chamber with a HVE and activate the unit for approximately 15 seconds to clear any powder remaining in the chamber.

**Conclusion**

Therapeutic polishing is the removal of toxins from the unexposed root surfaces, which results in a decrease in disease parameters. Polishing root surfaces is possible with both the rubber-cup or airpowder polisher; however, the rationale for selecting the air-powder polisher is for its effectiveness and efficacy.<sup>20</sup>

The clinician should follow the precautions and considerations presented when polishing for therapeutic benefits with the air-powder polisher. The clinician should be aware to direct the air-powder spray against the tooth surface, not the exposed soft tissues. Most importantly the clinician must consider all options — esthetic, therapeutic and patient goals — when designing a treatment plan

that meets the individual patient’s specific needs.

References are available from the author. DT

Contact Information	Contact Information
<p>Salim Rayman, RDH, MPA, is an associate professor in the dental hygiene program at Eugenio Maria de Hostos Community College of the City University of New York. He can be contacted by email at <a href="mailto:srayman@hostos.cuny.edu">srayman@hostos.cuny.edu</a>.</p> 	<p>Elvir Dincer, DDS, is an associate professor in the dental hygiene program Eugenio Maria de Hostos Community College of the City University of New York. He can be contacted by email at <a href="mailto:edincer@hostos.cuny.edu">edincer@hostos.cuny.edu</a>.</p> 

**mCME SELF INSTRUCTION PROGRAM**

CAPP with Dental Tribune with its mCME- Self Instruction Program gives you the opportunity to have a quick and easy way to meet your continuing education needs. mCME offers you the flexibility to work at your own pace through the material from any location at any time. The content is international, drawn from the upper echelon of dental medicine, but also presents a regional outlook in terms of perspective and subject matter.

**Membership:**  
 Take membership for one year by subscription for the newspaper: 600 AED  
 Take article with one newspaper subscription: 100 AED per issue.

After the payment, you will receive your membership number and will be able to start the program.

**Completion of mCME**

- mCME participants are required to read a continuing medical education (CME) article in each issue.
- Each article offers 2 CME Credit and followed by quiz questioner, which is available in <http://www.cappmea.com/mCME/questionnaires.html>.
- Each quiz has to be return to [events@cappmea.com](mailto:events@cappmea.com) or fax to: +971436868883 in three months form the publication date
- A minimum passing score of 80% must be achieved in order to claim credit
- Not more then two answered questions can be submitted in the same time
- Validity of the article – three months
- Validity of the subscription – one year
- Collection of Credit hours: you will receive the summary report with Certificate maximum one month after expire date of your membership. For single subscription Certificate and summary report will be send one month after the publication of the article.

The answers and critiques published herein have been checked carefully and represent authoritative opinions about the questions concerned.

Articles are available in [www.cappmea.com](http://www.cappmea.com) after the publication. For more information please contact [events@cappmea.com](mailto:events@cappmea.com) or +971 4 3616174

**FOR INTERACTION WITH THE WRITERS FIND THE CONTACT DETAIL AT THE END OF EACH ARTICLE.**

**DID YOU KNOW**

Almost 1 in 5 people find stained teeth a turn off<sup>1</sup>. Beverly Hills Formula toothpaste removes over 91% of stains<sup>2</sup> to give you whiter teeth in 1 minute



[info@beverlyhillsformula.com](mailto:info@beverlyhillsformula.com)
[@BHF\\_Whitening](https://twitter.com/BHF_Whitening)
[Beverly Hills Formula](https://www.facebook.com/BeverlyHillsFormula)
[+353 1842 6611](tel:+35318426611)

**www.beverlyhillsformula.com**

Beverly Hills Formula toothpastes rank no.1 for stain removal when compared with other leading brands of whitening toothpastes and toothpolishes. (Stain Removal Data 2012) See the full range and results at [www.beverlyhillsformula.com](http://www.beverlyhillsformula.com)

Source: British Dental Health Foundation, January 2012. <sup>2</sup>Source: Stain Removal Data 2012. Applies to Beverly Hills Formula Natural Whitening Expert toothpaste only