

laser

international magazine of laser dentistry

2²⁰¹²



| **research**

The antibacterial effects of lasers in endodontics

| **overview**

Laser treatment of dentine hypersensitivity

| **case report**

A novel technique of Er:YAG laser-enhanced early implant stability



The Dual Wavelength *waterlase**iPlus™

Advancing Laser Technology to Its Ultimate

INTUITIVE & INTELLIGENT GRAPHICAL USER INTERFACE

For example, performing a Class I Cavity Prep with the iPlus™ is as easy as 1,2,3...

- Step 1** Select "Restorative" from the first screen
 - Step 2** Choose "Class I" from the next screen that appears automatically
 - Step 3** Specify any other concerns such as patient sensitivity or bond strength
- That's it! Step on the foot pedal, and start working.*


iLASE™ 940nm DIODE LASER DOCKING STATION

- + Adds dual wavelength versatility and convenience
- + First totally wireless dental laser
- + 5 Watts peak power with ComfortPulse™
- + Battery operated with finger switch activation
- + Exclusive bendable tips in many diameters & lengths



BREAKS THE SPEED BARRIER

- + RR™ powered laser delivers 100 pulses/sec. for superior soft-tissue cutting
- + Patented laser technology delivers 10 watts of power
- + Enables multi-quadrant same-day procedures



ENABLES BIOLOGICALLY FRIENDLY DENTISTRY

- + No micro-fractures or thermal damage
- + More precise, minimally invasive

PROVIDES GREAT RETURN ON INVESTMENT

- + Increases treatment acceptance of day-to-day restorative cases
- + Attracts new patients
- + Increases productivity and enables new procedures



©2012

Laser (in)dispensable in dentistry?



Dr Georg Bach

Have you been following the coverage of dental congresses in the past few weeks? If so, you might have felt just the same positive sensation as I have when I came across the fact that scientific contributions on laser applications in implantology have gained a high rank in the past congress season. By the way, the same holds true for scientific texts on implantology in dental specialist publications.

The growing impact of laser applications on both congresses and scientific literature does indeed pose a snapshot of the current status of laser in dental therapies and might even express a recent trend. This trend, in my view, bears various notable facets:

Many of the numerous implantological congresses and symposia intersecting with laser dentistry have included reports on the application of monochromatic light into their programs. Moreover, whole sessions are dedicated to laser in both implantological and periodontal congresses and symposia. On such occasions, the high value of atraumatic laser incisions with significantly reduced hemorrhage is highlighted, along with the lack of alternatives to laser surface decontamination in the treatment of periimplantitis.

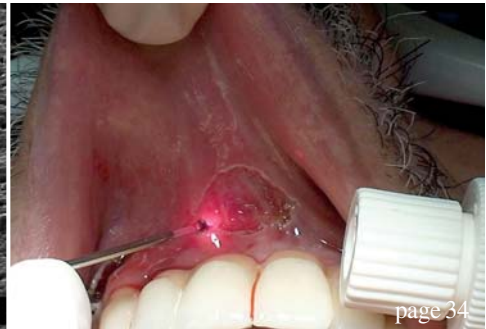
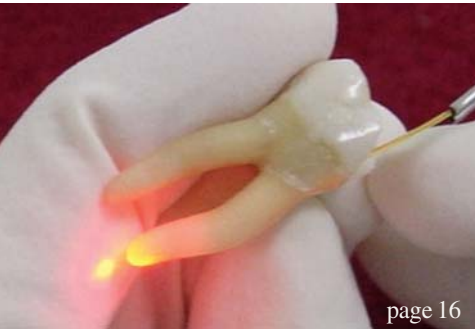
The antibacterial effects of lasers in endodontics and the advantages of laser therapy of oral haemangiomas contribute to the wide range of applications of laser in dentistry.

As you can see, we are provided with a sufficient (and evidence-based) number of opportunities to pursue our passion for monochromatic light in dental therapy. It follows that our résumé be "No (more) dentistry without laser"!

With best regards,



Dr Georg Bach



| editorial

- 03 **Laser (in)dispensable in dentistry?**
| Dr Georg Bach

| research

- 06 **Laser in oral surgery** and medicine—Part II
| Antonio Batista-Cruzado *et al.*
- 12 **Evaluation of combined Nd:YAG laser treatment of moderate periodontitis**
| Dr Anna-Maria Yiannikou-Loucaidou
- 16 **The antibacterial effects of lasers** in endodontics
| Dr Selma Cristina Cury Camargo

| overview

- 24 **Laser treatment of dentine hypersensitivity**
| Dr Ute Botzenhart *et al.*

| case report

- 28 **A novel technique of Er:YAG laser-enhanced early implant stability**
| Dr Kenneth Luk *et al.*
- 32 **Laser therapy of oral haemangiomas**
| Friedrich Müller *et al.*

| industry report

- 34 **Lasers in oral Implantology**
| Dr Ilay Maden *et al.*

| education

- 40 **“Laser Supported Dentistry”** in Turkey
| Prof Dr Aslihan Usumez *et al.*
- 42 **Innovation and information at IDS 2013**
| VDDI

| meetings


- 43 **International events 2012**
- 44 **DGL annual conference** in Leipzig, Germany
| Jürgen Isbaner
- 46 **“Scientifically, laser has now reached its highest standard”**
| Dajana Mischke

| news

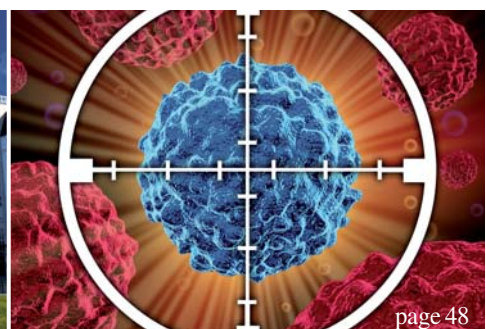
- 38 **Manufacturer News**
- 48 **News**

| about the publisher

- 50 | imprint



Cover image courtesy of Biolase Technology Inc., www.biolase.com.
Original Background: ©Excellent backgrounds
Artwork by Sarah Fuhrmann, OEMUS MEDIA AG.



FASCINATION OF LASER DENTISTRY

FOR EXPERTS AND BEGINNERS

SEPTEMBER 7-8, 2012
LEIPZIG
HOTEL THE WESTIN
LEIPZIG, GERMANY

16
JAHRESTAGUNG DER DGL e.V.
START UP 2012

LASER
START UP

7. UND 8. SEPTEMBER
HOTEL THE WESTIN LEIPZIG

FASCINATION OF
LASER DENTISTRY

21. JAHRESTAGUNG DER DGL e.V.

LASER START UP 2012



- 7./8. September 2012
- Hotel THE WESTIN LEIPZIG

HAUPTSPONSOR
BIOLASE

oemus

ORGANIZATION/ REGISTRATION

Deutsche Gesellschaft für Laserzahnheilkunde e.V.
(German Society for Laserdentistry)

Klinik für Zahnerhaltung, Parodontologie und Präventive
Zahnheilkunde Universitätsklinikum der RWTH Aachen,
Pauwelsstraße 30, 52074 Aachen, Germany

Fon: +49 241 8088-164

Fax: +49 241 803388-164

sekretariat@dgl-online.de

www.dgl-online.de

OEMUS MEDIA AG

Holbeinstraße 29

04229 Leipzig, Germany

Fon: +49 341 48474-308

Fax: +49 341 48474-390

event@oemus-media.de

www.oemus.com

www.dgl-jahrestagung.de

www.startup-laser.de

MAIN SPONSOR

BIOLASE

FURTHER INFORMATION

oemus

PLEASE FAX THIS FORM

+49 341 48474-390

Further information about:

LASER START UP 2012

21st ANNUAL CONGRESS OF THE DGL e.V.

September 7-8, 2012, Leipzig, Germany

NAME/E-MAIL

OFFICE STAMP

laser 2/12

Laser in oral surgery and medicine—Part II

Authors Antonio Batista-Cruzado, Daniel Torres-Lagares, Blanca Moreno-Manteca, Gerd Volland, Patricia Bargiela-Perez, Martin Jorgén & Jose-Luis Gutierrez-Perez, Spain

The laser has been used in the field of oral surgery for a wide range of indications. In this article, we focus on its surgical uses. The success of the surgical treatment of lesions in the oral cavity depends greatly on knowledge of the aetiology and histology of the lesion. There are pathologies that can be treated with laser, such as cancer sores and hyperkeratosis. Others, like candidiasis, cannot be treated with laser. Furthermore, laser has quickly become a predictable and favourable treatment modality for leukoplakia, haemangioma and epulis.

In the last issue of laser, the authors gave an overview on in vitro studies and in vivo animal studies in this field. They continued by giving examples of in vivo studies on humans on the subjects of wound and bone healing supported by laser treatment. Finally, the authors analysed soft-tissue surgery and examples of cancer treatment via CO₂ laser and photodynamic therapy under the headline of "clinical studies". They continue this chapter in the present issue of laser by discussing, among others, leukoplakia treatment, benign diseases and frenectomy. In the conclusion, they sum up the positive effects of laser on oral surgery.

Leukoplakia treatment

Leukoplakia is a premalignant lesion associated with excessive consumption of alcohol and tobacco.

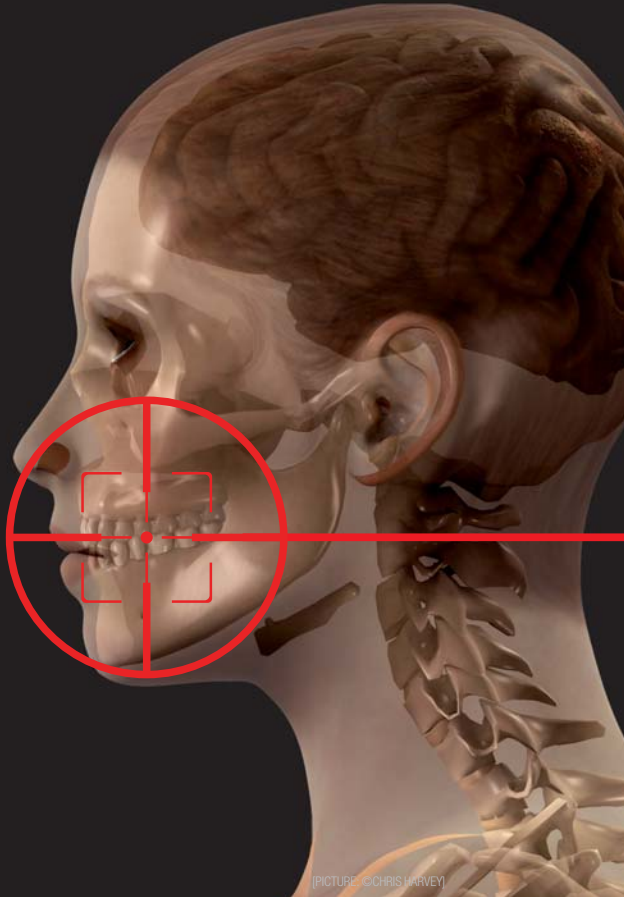
Although there is no specific treatment to prevent its recurrence, abandoning these habits can decrease the probability of recurrence, as well as the transformation into malignant tumours.

Vivek et al.²⁴ treated 28 patients with histologically diagnosed leukoplakia in order to study efficacy, safety and acceptability of lasers, particularly the Nd:YAG laser. After laser treatment, post-operative complications associated with ablation were assessed. They recorded only mild to moderate pain, with slight swelling up to 72 hours post-treatment. A follow-up study was initiated three years later. Approximately 92 per cent of the patients were found to have been cured. Therefore, the authors regarded Nd:YAG laser as an effective tool for the treatment of this pathology.

There are also studies that recommend CO₂ laser for the excision of leukoplakia. For example, Reddi and Shafer²⁵ found the CO₂ laser to be of great success in the excision of leukoplakia in their study. They also applied laser to the treatment of erythroplasia and lichen planus.

Treatment of lichen planus

Owing to its inflammatory effects, lichen planus can be painful both in atrophic and erosive forms.



Benign diseases

In this section, pathological entities treated with laser in recent years are discussed. Attention is paid to the technique applied, as well as frequency and impact of the laser used for the respective oral surgery.

Owing to the high frequency of pyogenic granuloma in the oral cavity, especially during pregnancy, Jafarzadeh et al.²⁸ reviewed this disease and considered treatments and new approaches. Possible treatment options are, among others, resection by means of a scalpel, cryotherapy, the use of corticosteroids, or the use of an Nd:YAG or CO₂ laser. The authors state that laser treatment can help control bleeding, does not result in adverse effects and is therefore consid-

ered a successful treatment method with high acceptance by patients.

Actinic cheilitis is another medical condition that can be treated with laser, since results show a high clinical resolution and low recurrence. Its successful treatment is based on the removal of epithelium while avoiding the resulting scarred tissue. De Godoy Peres et al.²⁹ compared two protocols of low morbidity clinico-histologically in which CO₂ laser was used with different parameters. A biopsy was done before and after laser treatment. In both groups, a significant reduction in epithelial dysplasia was achieved. Therefore, the authors recommend the use of lasers in cases of mild to moderate dysplasia.

Adipose tissue tumours are found frequently in the maxillo-facial region, for example on the lips and buccal mucosa. Although these tumours have traditionally been treated with a scalpel, laser can be a valid alternative. Suture is not necessary, and there is only minimal tissue scarring. Capodiferro et al.³⁰ is an insightful study on this topic.

Hyperkeratosis

Abnormal thickening of the stratum corneum caused by an increase of keratin is known as hyperkeratosis. The biological behaviour of this lesion is related to different histopathological changes. Various therapies, such as the use of scalpel, electrocautery, cryotherapy, PDT and topical medications have been proposed for its removal. Owing to advances in the use of laser in the oral environment, laser therapy appears a promising method for treating hyperkeratosis.

Santos et al.³¹ sought to verify the advantages of CO₂ lasers (10,600 nm) and removed lesions by focusing the beam of light around each lesion. The removed tissue was then sent for histopathological ex-

The traditional treatment, therefore, makes use of topical corticosteroids.

Cafaro et al.²⁶ conducted a prospective cohort study of 13 patients with lichen planus in order to investigate the effectiveness of LLLT. Patients were given biostimulation by diode laser (904 nm, pulsed mode). In general, a decrease in the size of the lesions and pain, and overall stable results were observed. The authors therefore recommend LLLT as a possible treatment for patients with lichen planus, but recommend that future studies be done with a larger group of patients in order to corroborate their results.

Aphthous stomatitis

LLLT has also been used in the treatment of recurrent aphthous stomatitis. The study by De Souza et al.²⁷ employed LLLT not as an inhibitor of the process, but for its modulating and healing effect on tissues. The authors assessed the effect of LLLT on aphthous stomatitis in 20 patients divided into two groups. Group I was treated with topical corticoids (triamcinolone acetonide) and group II was treated via diode laser (670 nm, 50 mW). Patients reported a decrease in pain already directly after laser treatment. Four days post-treatment, the lesion had receded completely in group I, compared with complete recession seven days post-treatment in group II.

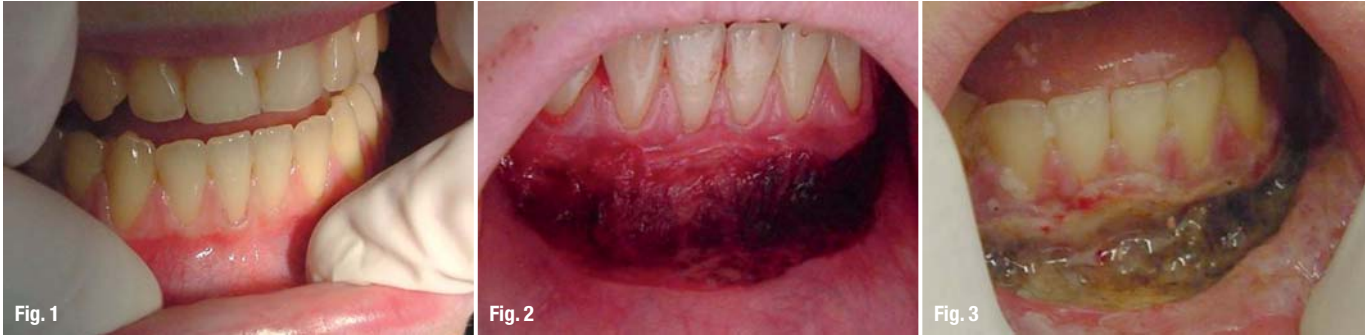

Fig. 1 Long-term case of vestibuloplasty. Situation on 15th of June, 2003: no gingiva attached at the lower jaw front.

Fig. 2 Long-term case of vestibuloplasty. ER:YAG treatment (1,000 μ s, 15 Hz, 400 mJ, no water, no air). Very low bleeding, periosteum not damaged. Gain of 10 mm.

Fig. 3 Long-term case of vestibuloplasty. Removal of peripac periodontal dressing, three days after the surgery.

amination. An improvement in haemostasis was achieved by defocusing the laser beam. The authors assert that this technique is easily applied and without post-operative complications.

Treatment of vascular lesions

Large vascular lesions in the orofacial region are often very difficult to remove. Therefore, the use of laser has been suggested as an effective way to remove major vascular lesions through photocoagulation. Angiero et al.³² investigated the effectiveness of photocoagulation and treated 136 patients with a diode laser. More than 98 % of these cases displayed complete remission. The study therefore demonstrated that diode laser treatment can prevent recurrence and complication, while the healing time is shortened.

Ostectomy

Stübinger et al.³³⁻³⁶ closely studied the use of Er:YAG laser on bone tissue and its biological effects. Applications range from different kinds of ostectomy, taking grafts from a tubercle and the chin, as well as tooth extraction. Among the benefits of Er:YAG laser treatment are high accuracy without wasting bone, along with a low risk of traumatising soft tissue or tissue charring, or of any complications in the healing of wounds. In order to achieve the best results, Stübinger et al.³³⁻³⁶ advocate the use of planning software. The amount of time needed for the surgery and the lack of depth control are among the disadvantages of the Er:YAG laser.

Third molar

Post-operative pain and oedema are common after the surgical removal of the lower third molar. Traditionally, non-steroidal anti-inflammatory drugs and steroids have been used to treat these symptoms. LLLT has only recently been considered as a possible analgesic agent to control post-operative pain, lock-jaw or inflammation. Markovic and Todorovic³⁷ compared the analgesic effects of two anaesthetics, the use of LLLT and the administration of diclofenac in their study. Compared with the control group, who only received regular post-operative recommendations, participants treated with

laser showed significantly reduced post-operative pain.

One year later, Markovic and Todorovic³⁸ studied the effectiveness of dexamethasone and the use of LLLT in reducing post-operative swelling. The study was conducted in 30 patients divided into four groups. Group I was irradiated immediately after the surgery. In addition to laser, an intramuscular injection of 4 mg dexamethasone was administered to group II in the internal pterygoid muscle. Group III was given 4 mg of systemic dexamethasone (intramuscular injection in the deltoid region) in addition to LLLT, which was followed by 4 mg dexamethasone intra-orally six hours after surgery. Group IV was the control group and received only the usual post-operative recommendations. Group II showed the lowest incidence of oedema. The authors concluded that LLLT can be recommended for the reduction of inflammation, an effect that can be increased by topical corticoids.

Amarillas-Escobar et al.³⁹ conducted a similar study on the extraction of wisdom teeth. Their study employed 15 patients who were treated with a diode laser (810 nm, 100 mW) intra-orally and extra-orally, and a control group of 15 patients who were not irradiated. The experimental group showed no statistically significant differences compared with the control group, although a reduction in post-operative pain, swelling and lock-jaw was detected.

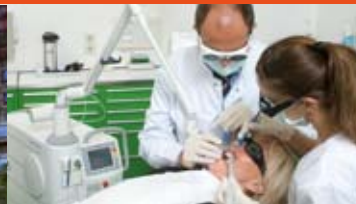Frenectomy

The term "frenectomy" refers to the complete removal of the frenulum from either the lip or the tongue. This can be done by either conventional surgery using a scalpel or laser. Recently, possible post-operative discomfort for the patient has been widely discussed.

Haytac and Ozcelik⁴⁰ randomly selected 40 patients for their study who had originally been intended to undergo another form of treatment. Each patient was asked to rate functional complications and pain according to a scale from one to seven. All of the patients perceived laser application positively

**Lay the Foundations to your
successful Future now!**

The next Master programme starts on **24 September 2012** in Aachen



Master of Science (M.Sc.) in Lasers in Dentistry

Become a part of the International Dentists' Elite!

- The first accredited M.Sc. programme in dentistry in Germany
- Career-accompanying postgraduate programme of two years at the University of Excellence RWTH Aachen
- Combination of lectures, skill training sessions, live ops, tutorials, and practical workshops
- Internationally accepted and accredited by the German Government, the European Union, the Washington Accord and the Bologna Process
- Science-based and practice-orientated on highest national and international level



Aachen Dental Laser Center

More information:

AALZ GmbH · Pauwelsstrasse 17 · 52074 Aachen · Germany
Tel. +49 - 2 41 - 47 57 13 10 · Fax +49 - 2 41 - 47 57 13 29
www.aalz.de · info@aalz.de

**RWTHAACHEN
UNIVERSITY**