

DENTAL TRIBUNE

The World's Dental Newspaper • Middle East & Africa Edition

PRINTED IN DUBAI

www.dental-tribune.com

Jan–Feb 2013 | No. 1, Vol. 2

DENTAL ACADEMIA TRIBUNE

'We will be offering specialty dental training programs in all the recognized dental specialties'

> page 24



DENTAL ORTHO TRIBUNE

Non-extraction treatment of adult skeletal Class III malocclusion


> page 13



MEDIA CME

Same-day inlay/onlays strive to save the tooth

> page 6



DENTAL IMPLANT TRIBUNE

DTMEA introduces 'Implant Tribune' section

> page 17



The concept is unique, it is the first and we believe there will be a good demand for it



By Dental Tribune Middle East & Africa

Dubai, UAE: We interviewed Dr. Costa Nicolopoulos at the amazing booth of Southern Implants at the 4th Dental Facial Cosmetic International Conference at the Jumeirah Beach Hotel. Dr. Costa, you had a very good lecture today; could you comment on your experience in general and here at the conference?

Thank you very much for having me here. I'm an oral and maxillofacial surgeon qualified in South Africa in 1990, and I have been practicing in Greece for the last 15 years. Recently we have relocated to Dubai and we are very proud to have opened, last week, the very first 'SameDay Dental Implant Clinic' in Dubai where patients can

walk in, have an extraction, have an implant placed at the same time and have a tooth placed all in the same day: that's why it's called 'SameDay Dental Implants' (www.samedayme.com). And this type of treatment where a patient can have one or all of his teeth extracted, replaced with implants and have the teeth placed—fixed, screwed teeth—is only possible by using Southern Implants, which are unique in the sense that they offer angled implants, called Co-Axis implants which are placed in the available bone so we do not have to do painful bone grafts. Instead we use wide implants called the 'MAX Implant' which means that you can take out a molar tooth (a back tooth) and replace it at the same time, it's the first FDA approved wide diameter immediate molar replacement implant. And what I showed at the lecture 2 hours ago was how we can achieve this same day concept by avoiding bone grafts, placing implants and teeth the same day and getting excellent results by using these Southern Implants.

Speaking to the delegates earlier it was indeed an impressive lecture with positive feedback. Have you familiarized yourself

>> See FILLING, page 17



Dr. Aisha Sultan Alsuwaidi, the first female dentist in United Arab Emirates

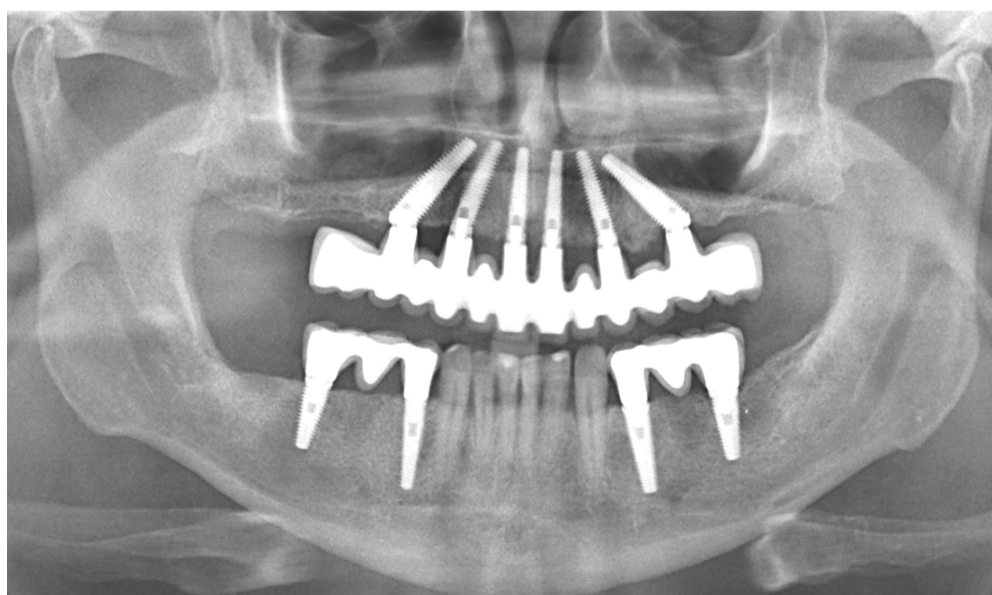
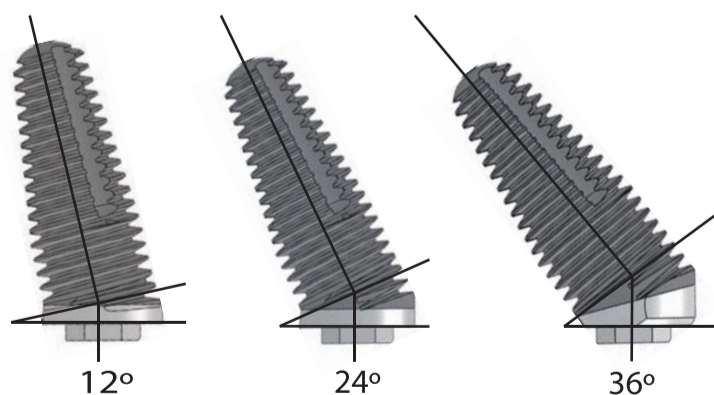
By Dental Tribune Middle East & Africa

Dubai, UAE: Dr. Aisha Sultan Alsuwaidi, Director of Dental Services in the Ministry of Health of Dubai and Northern Emirates, Chairwoman of the Dental Society of Emirates Medical Association, and Vice-President of the Asia-Pacific Dental Federation Middle East Region. Dr. Aisha is a remarkable key figure in the Dentistry Scene in the Middle East as she was the first female dentist in the United Arab Emirates,

serves as a role model for many young dentists and enjoys great admiration and respect throughout the region.

Dr. Aisha, it is a great pleasure to interview you here at the remarkable new offices of the Emirates Medical Association (EMA) in Dubai, UAE. Please share with us a little bit about your extraordinary life as dentist, role model and a mother of five. Welcome. My name is Dr. Aisha Sultan Alsuwaidi, currently working as the acting

>> See FILLING, page 1



AVOIDING SINUS BONE GRAFTS WITH Co-AXIS SOUTHERN IMPLANTS

DUBAI HEALTHCARE CITY Building 26, office 410, Dubai U.A.E.

T: +971.4431.2077, +971.50.8570347

info@southernimplants.net

www.southernimplants.com



Words from Dental Tribune Middle East & Africa



By T. Deyanov
Business Development Manager

Happy New Year from Dental Tribune Middle East & Africa! A new year, a new beginning! Undoubtedly, 2013 will be a big year for the dental industry with the biggest International Conference & Exhibition taking place at IDS Cologne, 12-16 March in Germany. The world's largest trade fair for the dental sector will welcome its 35th dental show with around 118,000 visitors who

will gather information on new products and innovations from 1,954 exhibitors from 58 countries according to its own figures. Dental Tribune International welcomes all colleagues and partners to visit us at the DTI booth at IDS and learn the latest news in dentistry through our trade publishers around the world covering more than 90 countries.

The Middle East dental market is continuing to develop rapidly. In the region this year we have key events such as the 24th Saudi Dental Society meeting in Riyadh in January, AEEDC in February, Seventh Annual Congress of Iranian General Dental Association in February, 8th CAD/CAM & Digital Dentistry International Conference in Dubai in May, LUSD 13th International Convention in Beirut, Lebanon in May, 5th

Dental Facial Cosmetic International Conference in Dubai in November and the 2nd Global Conference of AAID in December, also in Dubai. All mentioned are remarkable events in the Middle East and important for the dental society in the region.

The high increase in new courses, conferences and exhibitions taking place in the region is a proven reflection. New Dental Schools, Universities and Colleges continue to open their doors for the knowledge hungry students seeking a specialty in dentistry. DTMEA will be covering all major events in the region and will be interviewing various important figures in the field of dentistry to share their insight.

The DTMEA January-February edition proudly introduces two new items through

the Ortho & Implant Tribune. The Ortho Tribune, spearheaded by the passionate Dr. Khaled Abouseada, will bring forward breathtaking cases on the latest developments in Orthodontics in the region. The Implant Tribune will feature top professional Implantologists who are eager to share their experience and knowledge with our dear dental readers. Rest assured we have more eye-catching new features planned in the remaining editions of 2013.

DTMEA promises to continue bringing the latest news in dentistry forward to the entire Middle East through unique and innovative methods. We wish you pleasant and productive reading.

DTMEA. **DTI**

<< FILLING, page 1



Dr. Aisha Sultan Alsuwaidi

Director of Dental services in the Ministry of Health, Chairwomen of the Dental Society of Emirates Medical Association. Last year I was also elected as the Vice-President for the Middle East Region of the Asia-Pacific Dental Federation ahead of the APDC event which will be held on 17-19, June 2014 in Dubai. As a dentist, it all started when I left the UAE to complete my study in Cairo University, Egypt followed by Cardiff University, where I completed my specialty as a Periodontist. Soon after I returned to the UAE and began working in Al Baraha Hospital as Head of the Dental Department. Alongside my administration work, I practiced my specialty as a Periodontist and was soon elected to be the Chairwoman of the Dental Society – Emirates Medical Association. Two years ago I was appointed as Head of the Dental Services in the Ministry of Health, UAE. On a personal basis however, I am a mother of five children, two of whom are still studying in high school and three others have already completed their education: One being a businessman, the other a physician and the last, a lawyer.

How important is it to you, the choice of working for the government? Working for your country?

I love my country, I love Dubai, this is my home and I want to give back something to the people. When I was a young student, I knew exactly what I desired to be, I put in my mind that I was going to be a dentist. From that time I planned and worked hard to develop within this medical field. Proudly, as everyone knows, I became the first female dentist in the UAE which brings a lot

of responsibilities. I have marked out many goals which must be achieved in our country and which I hope to implement here. I have worked very hard in the government and as a volunteer in order to promote this field of dentistry to be recognized as an equal amongst other medical fields.

Compared when you first started out, how has dentistry developed through the years in UAE and the region?

It is a huge development, not just in terms of healthcare. No one could imagine this country would become the cultural and economic hub that it now is with the development not only being in healthcare, but in all aspects of life such as business, education and economy. Since the Union, 41 years ago, one can see a very significant movement forward in the development of the dental scene, particularly so during the last 10 years.

What are the driving factors behind this huge development over the last 10 years?

This generation is well educated and very well-travelled, whereas in my generation hardly anyone could go to university far abroad. Some who had this unique opportunity to study abroad, it was merely restricted to the neighboring countries. With the development of new dental schools, conferences, courses and continual medical education, it is a pleasure to see the new generation being able to receive high quality education without having to leave the borders of the United Arab Emirates. Through the vast improvement of the internet, communication channels, media and advertising, dentists have a wider availability of content to study from and can

stay up to date with the latest research & development as well as international cases written by famous clinicians.

Do you personally attend conferences, courses and workshops? Are there any particular ones in the region or other GCC countries that you often visit?

Most countries within the GCC have their own Dental Association and this is already in addition to any dental society that their governments might have. Each holds their own set of courses, workshops and conferences. There are many events to choose from but yearly we attend at least three or four just in the GCC in addition to any international events. I must say, it is extremely important to attend these conferences as the dental industry is updating products at least every 6 months using new materials and methods which we should know about.

As dentistry develops we notice more and more the involvement of Digital Dentistry, what are your thoughts on this new phenomenon?

It is very interesting. Dentists, as well as any medical professional should always be up-to-date in their work. As technology is significantly updating and is becoming a common facet in our lives, it becomes even more imperative and almost mandatory that we are aware of what is going on in the market. I believe that everyone should adapt to changes in their industry, technologically or otherwise.

How important is the dental media, especially in the region?

It is very important. Until recently there was no publication from United Arab Emirates let alone Dubai to cover the latest news in dentistry. We are very happy with the activities of Dental Tribune Middle East and the working ways of the team. The region is very hungry for knowledge and the importance of reaching out to the dentists, the technicians and all dental stakeholders is huge, especially during the times when there are no events and courses to keep updated during the year. For many years it was very difficult to follow and we were in need of a constant medium for the region. We are happy to welcome a local website, newspaper and online e-newsletters to update us on the latest news from the region. Previously, we had to look for the news, however now the news comes directly to us with the excellent services provided by the Dental Tribune Middle East & Africa e-newsletter.

Dr. Aisha, truly an honor to interview you here today. Is there anything else you

would like to share with the readers?

Dear readers, I would like to invite all dental professionals to attend the Asia-Pacific Dental Federation Conference in Dubai on 17-19th June which will continue to be one of the most significant and biggest International Events in dentistry. Since FDI Dubai years ago, APDC 2014 will be the most important dental event happening in the Middle East. **DTI**

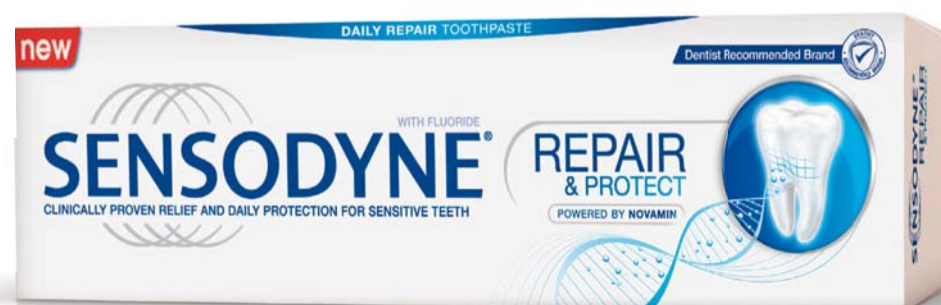International Imprint

Licensing by Dental Tribune International	
Publisher	Torsten Oemus
Group Editor	Daniel Zimmermann newsroom@dental-tribune.com +49 341 48 474 107
Clinical Editor	Magda Wojtkiewicz
Online Editor	Yvonne Bachmann
Editorial Assistance	Claudia Duschek
Copy Editors	Sabrina Raaff Hans Motschmann
Publisher/President/CEO	Torsten Oemus
Director of Finance & Controlling	Dan Wunderlich
Media Sales Managers	Matthias Diessner Peter Witteczek Maria Kaiser Melissa Brown Vera Baptist
Marketing & Sales Services	Esther Wodarski
License Inquiries	Jörg Warschat
Accounting	Karen Hamatschek
Business Development Manager	Bernhard Moldenhauer
Executive Producer	Gernot Meyer
International Editorial Board	
Dr Nasser Barghi, USA – Ceramics	
Dr Karl Behr, Germany – Endodontics	
Dr George Freedman, Canada – Aesthetics	
Dr Howard Glazer, USA – Cariology	
Prof Dr I. Krejci, Switzerland – Conservative Dentistry	
Dr Edward Lynch, Ireland – Restorative	
Dr Ziv Mazor, Israel – Implantology	
Prof Dr Georg Meyer, Germany – Restorative	
Prof Dr Rudolph Slavicek, Austria – Function	
Dr Marius Steigmann, Germany – Implantology	
© 2013, Dental Tribune International GmbH. All rights reserved.	
Dental Tribune makes every effort to report clinical information and manufacturer's product news accurately, but cannot assume responsibility for the validity of product claims, or for typographical errors. The publishers also do not assume responsibility for product names or claims, or statements made by advertisers. Opinions expressed by authors are their own and may not reflect those of Dental Tribune International.	
Dental Tribune International	
Holbeinstr. 29, 04229 Leipzig, Germany	
Tel.: +49 341 4 84 74 302 Fax: +49 341 4 84 74 173	
www.dental-tribune.com info@dental-tribune.com	
Dental Tribune Middle East & Africa Edition	
Editorial Board	
Dr. Aisha Sultan Alsuwaidi, President Emirates Dental Society, UAE	
Dr. Nabeel Humood Alsabeeha, Consultant Prosthodontist, Ministry of Health, UAE	
Dr. Dobrina Mollova, MDS, UAE	
Dr. Munir Silwadi, BDS, MRCDSo, DUSS, FADI, FICD, UAE	
Dr. Khaled Abouseada, BDS, MS, orthod. cert. Consultant Orthodontist, KSA	
Dr. Rabih Abi Nader, B.D.S, D.E.S, D.E.S.S, Oral Surgeon and Implantologist, UAE	
Rodny Abdallah, Dental Technician, CDT, Lebanon	
Director of mCME	Dr. Dobrina Mollova info@cappmea.com, +971 50 42 43072
Business Development Manager	Tzvetan Deyanov deyanov@dental-tribune.com +971 55 11 28 581
Designer	Antoaneta Voleva design@dental-tribune.net

Sensodyne Repair & Protect

Presenting a new layer of protection

Sensodyne Repair & Protect harnesses advanced NovaMin® technology to help build a robust hydroxyapatite-like layer over exposed dentine and within dentine tubules.¹⁻⁵ With Sensodyne Repair & Protect, you can do more than treat the pain of dentine hypersensitivity – you can repair and protect your patients' exposed dentine.



Think beyond pain relief and recommend
Sensodyne Repair & Protect



References: 1. Burwell A *et al.* J Clin Dent 2010; 21(Spec Iss): 66-71. 2. LaTorre G, Greenspan DC. J Clin Dent 2010; 21(3): 72-76. 3. West NX *et al.* J Clin Dent 2011; 22(Spec Iss): 82-89. 4. Earl J *et al.* J Clin Dent 2011; 22(Spec Iss): 62-67. 5. Efflandt SE *et al.* J Mater Sci Mater Med 2002; 26(6): 557-565. Prepared December 2011, Z-11-516.

OH/CA/01/13/001

French Dental and Aesthetic Center relocates within UAE

by Dental Tribune Middle East & Africa

Abu Dhabi, UAE: Dental Tribune Middle East was present at the opening of the French Dental and Aesthetic Center in Abu Dhabi on 12 December 2013. The French Dental and Aesthetic Center has been in Abu Dhabi for 7 years and has recently relocated to a new renovated villa where the center is divided into two groups: Dentistry and Dermatology/Aesthetics.

Dr. Tabarani introduces: 'At the moment we have four dentists soon to be five. We have Dr. Musa Jaffal (Manager and Specialist Orthodontist – TMJ Disorder), Dr. Mustafa Saad (Specialist Periodontist – Implantologist), Dr. Belal Mohsen (Dentist-Aesthetic Dentistry) and myself, Dr. Carine Tabarani (Specialist Oral Surgery). Momentarily we are awaiting a specialist in laser and aesthetics coming from Saudi Arabia to complete our team.

The team works together with the philo-



Opening of the new location in Abu Dhabi on 12 December 2012

phy to place a good treatment plan, follow the guidelines for every kind of treatment and choose professional dentists to paint the path forward. The clinic provides all types of dental treatment for rich and for the poor; although certain complicated

treatments may become a little bit expensive, the main goal of the center is to enhance the quality. To ensure this top quality, the staff attends workshops, seminars, conferences and exhibitions regularly both national and international. Having just at-

tended the 4th Dental Facial Cosmetic International Conference at the Jumeirah Beach Hotel in Dubai, UAE, and the ITI Conference in Abu Dhabi, UAE, the dentists at the clinic are fresh and up-to-date on the latest developments in dentistry. Some of the dentists are even national and international speakers who have numerous publications in several high-end international dental journals. The dental technicians and assistants also follow specialized trainings in the dental field to improve their professional development creating the ultimate dental team.

Speaking on the equipment available at the Dental Center, Dr. Moustafa Saad explains: 'In fact all the systems we choose are well known with a high level of scientific evidence for all our specialties. All are well documented and approved in many European countries as well as ADA.'

The French Dental & Aesthetic Center is now open and welcomes all to its new villa in Abu Dhabi, UAE. **DT**

Pierre Fauchard Academy Middle East

By Dr Dominique Caron

As you all know, PFA: (Pierre Fauchard Academy) Named in memory of Pierre FAUCHARD, a French dentist of the 18th Century called "father of modern dentistry", is the worldwide Academy of Dental Surgery.

The purpose is to bring the profession to the highest level and support health authorities to improve public dental health.

PFA is a non-profit association.

PFA is not in competition with all the dental associations and societies already existing, it just helps.

Fellowship is by invitation only.

Fellows are ethical and outstanding dentists ready to take the time to be helpful for the profession and for public health.

In the mind of the vision we have to set



Middle East as a rising area strongly linked to the leading elements all over the world

we are more than happy to tell you that Dr. Dobrina MOLLOVA, most well-known founder and President of CAPPMEA, is already one of our first new fellows.

The first Middle East PFA meeting for 2013 will be held during the next AEEDC.

7th of FEBRUARY 2013

12H00 to 14H00 in NOVOTEL BLUE BAR.

FREE ENTRANCE FOR PRACTITIONERS AND STUDENTS

12H00 NEWS OF PFA

12H30 Lecture on a new Topic: M.I.H. by Dr. Agnes ROZE

MIH: Molar Incisor Hypomineralisation

Characteristics, Management and Dilemma Molar Incisor Hypomineralisation (MIH)

is defined as a hypomineralisation of systemic origin of one to four permanent first molars frequently associated with affected incisors. MIH molars are fragile and caries can develop very easily in those molars. Early diagnosis is essential since rapid breakdown of tooth structure may occur, giving rise to acute symptoms and complicated treatment. The purpose of this conference is to review MIH and illustrate its clinical management in young children.

13H00 DISCUSSION

13H30 LATEST NEWS ON SLEEP APNEA **DT**

Contact Information

Dr. Dominique Caron
Dental Surgeon
Medical Director
dcaron@versaillesdentalclinic.com

Meet us at
Booth V-015
Hall 10.2



12.-16.3.2013

PROMEDICA
Highest quality made in Germany

- high quality glass ionomer cements
- first class composites
- innovative compomers
- modern bonding systems
- materials for long-term prophylaxis
- temporary solutions
- bleaching products ...

All our products convince by

- excellent physical properties
- perfect aesthetical results

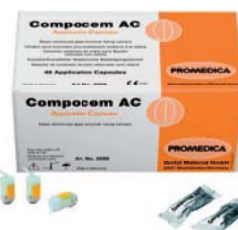
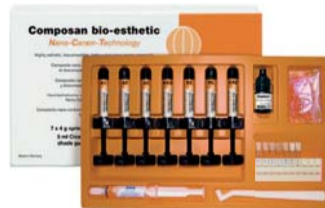
Temporary crown & bridge material

- less than 5 min. processing time
- strong functional load
- perfect long-term aesthetics
- excellent biocompatibility

Light-curing nano-ceram composite

- highly esthetic and biocompatible
- universal for all cavity classes
- comfortable handling, easy modellation
- also available as flowable version



Resin-reinforced glass ionomer luting cement

- strong adhesion
- very low film thickness
- especially suited for zirconia-based pieces

PROMEDICA Dental Material GmbH

phone: +49 43 21/5 41 73 · fax +49 43 21/5 19 08 · Internet: www.promedica.de · eMail: info@promedica.de

PROMEDICA

EUROPEAN UNIVERSITY COLLEGE

(formerly NICOLAS & ASP UNIVERSITY COLLEGE)

First International Postgraduate Dental Institution In The Region

MASTER DEGREE IN ORTHODONTICS

In Cooperation
with Malmo Univer-
sity - Sweden

Thesis Required

MASTER DEGREE IN PEDIATRIC DENTISTRY

GA & OR Facilities,
& Special Needs
Care

Thesis Required

MASTER DEGREE IN ENDODONTICS

Operating Microscope
Facilities, Computer-
ized Radiography

Thesis Required

DIPLOMA IN AD- VANCED EDUCA- TION IN GENERAL DENTISTRY

Clinical, Theoretical &
Evidence - Based

Operating Microscope
Facilities, Computer-
ized Radiography

HIGH DIPLOMA IN ORAL IMPLANTOLOGY

Comprehensive Clini-
cal Training on Surgi-
cal & Implant Restora-
tion

CBCT Diagnosis and
Treatment Planning

COMING SOON

✦ **MASTER DEGREE IN RESTORATIVE & PROSTHODONTICS**

✦ **ASSOCIATE DEGREE IN DENTAL ASSISTING**

- Accredited by The Ministry of Higher Education & Scientific Research (UAE)
- In Cooperation with Swedish Universities
- Accredited by the International Association of Universities (UNESCO)

- Teaching Faculty from reputed American & European Universities
- All programs include strong theoretical & clinical training
- Global pool of international students from Asia, Europe & the Middle East

Membership Preparatory Course

Royal College of Surgeons in Edinburgh

2nd MOrth preparatory course starts on March 1, 2013

International speakers

One to one guidance on case selection, preparation and write ups

Comprehensive topic review

Tips and tricks

Mock examination

CME Points to be Rewarded: DHA - HAAD - SCFHS

Visit us at AEEDC 2013, Stand No. 18

Curriculum approved by Royal College of Edinburgh

EUC Orthodontic graduates exempted from the written examination

Admissions for 2013 is currently open



+97143624787 • info@dubaipostgraduate.com • www.euc.ac.ae



Same-day inlay/onlays strive to save the tooth

mCME articles in Dental Tribune have been approved by HAAD as having educational content for CME credit hours. This article has been approved for 2 CME credit hours.

ADA CERP® | Continuing Education Recognition Program

Centre for Advanced Professional Practices (CAPP) is an ADA CERP Recognized Provider. ADA CERP is a service of the American Dental Association to assist dental professionals in identifying quality providers of continuing dental education. ADA CERP does not approve or endorse individuals courses or instructors, nor does it imply acceptance of credit hours by boards of dentistry.

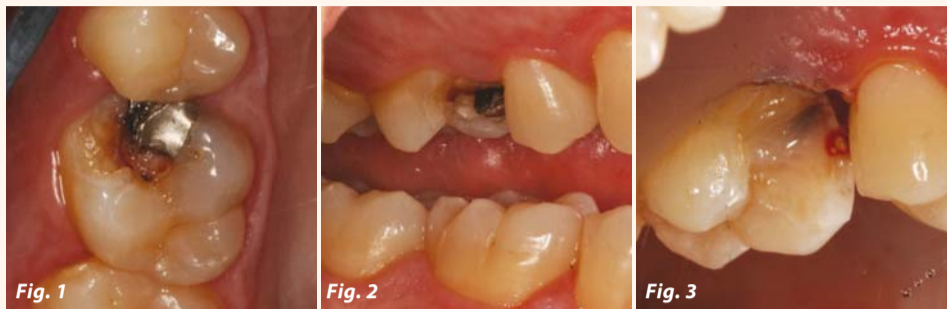

Fig. 1 #3 pre-op, palatal view. (Photos/Provided by Dr. Lorin Berland and Dr. Sarah Kong). **Fig. 2** #3 pre-op, buccal view. **Fig. 3** Decay removed and lining placed.

Authors **Lorin Berland, DDS, FAACD, and Sarah Kong, DDS**

The name of the game in dentistry today is to save the tooth for use in the future. In this age of adhesive dentistry, respecting and preserving the remaining healthy tooth structure as well as improving esthetics have become components of value as well. With today's advanced technology and materials, longevity is mainly a matter of diagnosis, correct treatment planning and proper execution of technique.

The problem with replacing old amalgams with tooth-colored composites is that they are difficult, inconsistent and unpredictable. Yet, the warranty on these 30-, 40- and 50-year-old silver fillings is running out. We have to remember that amalgam technology is more than 150 years old. At that time, people lost their teeth a lot earlier and died a lot earlier, too.

Now, however, we have a population that is over 50 years old and growing – and they want to keep their teeth feeling good and looking good. Patients are now living longer and they want and expect to keep their teeth for a lifetime.

Adhesive dentistry offers a more conservative restorative approach to conventional dentistry. Why take away healthy tooth structure when there's a viable alternative? Why not attempt to save the good and just replace the bad? Direct composites and laboratory composite resin systems are valuable and worthwhile options to preserve tooth structure and long-term dental health. After all, preserving a patient's natural tooth, whenever possible, is always in his or her best interest.

It has been our experience that providing multiple, large interproximal posterior composites directly can be difficult to achieve on a consistent basis in the oral environment, especially when replacing amalgams. Why? Because they take a lot of chair time. Amalgams require bulk. That's why we were taught the block type preparation to provide the necessary bulk for strength.

Furthermore, because amalgams do not bond, we were taught to create undercuts and "extension for prevention." As mercury contracts

and expands with cold and hot temperature changes over time, cracks form in the glass-like nature of teeth.

Most of the time, these large preps are difficult to restore with direct composite. There are isolation and contamination issues, and it is difficult to replicate nature in the mouth in a timely, cost-effective and predictable manner for every case, every time. In addition, curing in layers makes for a long appointment and increases the possibility of contamination. It is uncomfortable for patients to keep their mouths open for the prolonged amount of time necessary.

Often, large direct posterior composite resins yield unsatisfactory results in terms of esthetics, and especially long-term function, due to curing and contamination issues.

However, when we do same day inlay/onlays out of the mouth and in the laboratory, we find that multiple posterior restorations are easier, stronger and more anatomically correct. Because they are processed at the same time, they can be even more time efficient than using a CAD/CAM system and reduce tooth movement during the transitional phase that can result in altered contact or occlusion.

Not having to deal with provisional restorations absolutely eliminates those untimely emergencies when temporaries break or come off. Those costly, non-productive, uncomfortable and unhappy second appointments can also be avoided, saving everyone time and money. In addition, without concerns about retention of temporaries, preparation can be even more conservative.

Case No. 1

In this case, the patient came to our office on an emergency basis with a broken tooth on the upper right molar. It was no surprise that the tooth had a previously placed MO amalgam with recurrent decay that caused the mesio-buccal cusp to fracture off completely (Figs. 1, 2). Often, teeth that have had old amalgam fillings tend to break due to cracks caused by the expansion and contraction of the metal alloy in the tooth's glasslike substance.

In addition, caries detectors were non-existent when the bulk of amalgam restorations

were placed so many teeth have recurrent decay under the old amalgam fillings.

After thorough clinical and radiographic examinations were performed, it was determined with the patient's input that a same-day onlay would be the most prudent option for this tooth. This way, he would be receiving the maximum amount of care in the least amount of time.

The procedure

After placing topical anesthetic, articaine HCl 4 percent with 1:1,00,000 epinephrine was administered to achieve profound anesthesia. Next, a nitrous oxide nasal mask was placed to decrease the patient's exposure to mercury aerosol while the amalgam was being removed. In this case, because the patient opted not to use nitrous oxide, pure oxygen was administered through the nasal mask.

We continued by isolating tooth #3 with a rubber dam. This step was essential to reduce the amount of amalgam ingested by the patient. It also offers isolation, higher visibility and better dentistry for our patients. If doing quadrant dentistry, I like to use the split-dam technique, which stretches to include several adjacent teeth in a quadrant. A FenderWedge (Directa) was then placed to separate and protect the adjacent tooth during prep, air abrasion, etching, bonding and refining while continuing to wedge the teeth for a tighter interproximal contact in the final restoration.

To facilitate removal of the remaining amalgam restoration, an hourglass-shaped diamond bur was used as diamonds are less likely to produce the fracture and craze lines associated with carbide burs. High-speed evacuation was used throughout the procedure to help decrease possible inhalation and ingestion during amalgam removal.

Caries detector was painted onto the prepared surface, and it was noted that cracks associated with the long-time expansion and contraction of the mercury-filled amalgam restoration had contributed to the apparent interproximal decay. Once the decay was carefully and completely excavated using a small, round diamond bur and a spoon excavator, the tooth was insulated in a few important steps (Fig. 3).

First, disinfectant was placed on the prepared dentinal surface (Hemaseal & Cide, Advantage Dental Products) and air-thinned. Then, two coats of self-etching bonding agent (Opti-Bond All-In-One Unidose, Kerr Dental) were placed to provide reduced postoperative sensitivity and high dentin bond strength.

After air thinning and light curing, a flowable composite (Premise Flowable, Kerr Dental) in the lightest shade was added to the internal walls and floor to create an even floor and to fill in undercuts that were originally

prepared for amalgam retention. A flat-end cylinder, fine-grit, short shank diamond was used to refine the tooth preparation after insulation was completed (Fig. 4).

Next, two Identic hydrocolloid alginate impressions (Dux Dental) were taken fast and accurately. They take only 90 seconds to set with our chosen materials, so they are ideal for same-day inlay/onlays. Before expressing the hydrocolloid material into the prepped tooth, we squirted a little surfactant (PrepWet Plus, Dux Dental) onto the tooth to wet the prep while my assistant mixed the alginate.

Meanwhile, a second assistant was loading a syringe with warm Identic Syringable Hydrocolloid Cartiloids (Dux Dental) to hand to me. The "plug" was initially squirted away from the prep and then into the prep itself so as not to interfere with a "clean" impression. Once the tray had been loaded with the alginate (Identic, Dux Dental), the first assistant handed it to me. The tray was inserted with gentle pressure and held steady for 90 seconds. Another impression was taken using the same aforementioned steps.

The patient then had about an hour break while the inlay was being made and was able to make the most efficient use of his time by having his teeth cleaned with the hygienist during this break in treatment. This not only made the time seem to go by faster for the patient, but it also eliminated "dead time" in our schedule.

The patient made the most of his time in the chair, fixing his broken tooth and getting his teeth cleaned. This type of combination treatment lends itself to a more productive day when scheduled this way, and patients really appreciate it.

Lab work

Meanwhile, back in the lab, the impressions were first disinfected and then poured with MACH-SLO (Parkell) and based with bite registration material on a C-Bite articulator (C-Bite, Dental Products) (Fig. 5). An electric waxing unit was used to block out any undercuts on the die (Ultra Waxer, Kerr Lab).

The onlay was incrementally built in composite layers with a D2 primary dentin base shade (Premise Indirect Primary Dentin, Kerr Dental) followed by an A2 facial dentin shade (Premise Indirect Facial Dentin, Kerr Dental) and a neutral incisal shade (Premise Indirect Incisal, Kerr Dental).

Once the onlay was cured with light, heat and pressure in the BelleGlass curing unit (Kerr Dental) for 10 minutes, it was fitted, adjusted and polished on the silicone models (Figs. 6, 7) with various burs and polishing wheels. All margins, contacts and contours were easily and accurately verified outside the mouth, saving valuable chair time and clinical frustration.

Seating the onlay

When seating the onlay, a medium size Isolite (Isolite Systems) was applied for easy isolation, suction, bite rest and illumination during the cementation of the onlay. No further anesthesia needed to be administered as the tooth had been lined with flowable composite during the prep stage. Patients really appreciate this – especially because they are almost back to "normal" by the time they leave.

The onlay was then tried in to verify proper contacts, contours, margins and esthetics. Before cementation, Expasyl (Kerr Dental) was

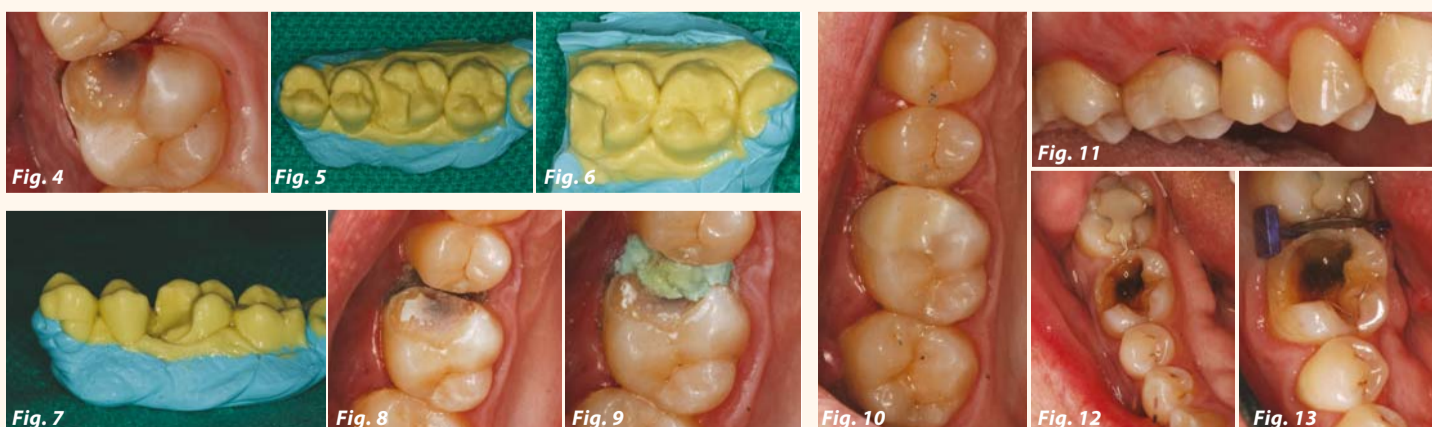


Fig. 4 Prepped tooth, palatal view. **Fig. 5** Silicone model. **Fig. 6** Sectioned model. **Fig. 7** Silicone model, buccal view. **Fig. 8** Tooth ready to bond. **Fig. 9** Expasyl placed interproximally prior to seat. **Fig. 10** Onlay seated, palatal view. **Fig. 11** Onlay seated, buccal view. **Fig. 12** #30 pre-op. **Fig. 13** FenderWedge in place.

gently packed into the sulcus (Fig. 8). The aluminum chloride dried the tissue, reducing the risk of sulcal seepage and contamination. The FenderWedges were then inserted beneath the interproximal floor to slightly separate and isolate the adjacent teeth and to help facilitate seating the onlay.

After rinsing the Expasyl (Kerr Dental) thoroughly, the enamel and composite core were gently micro-etched with aluminum oxide (EtchMaster, Groman Dental) to increase retention and remove any debris. Then the enamel and composite core were etched for 15–30 seconds. A single component, fifth-generation adhesive (OptiBond Solo Plus Unidose, Kerr Dental) was applied in two coats and air-thinned until there was no more movement. The enamel should be glossy (Fig. 9). Flowable composite (Premise Flowable, Kerr Dental) was dispensed into the prepped tooth and then the inlay was inserted into the tooth.

The FenderWedges were removed and the onlay was further seated using the Titanium-coated #21 Acorn with gentle pressure. Complete seating was facilitated using the contra-angle packer/condenser while an explorer was helpful in removing excess flowable before curing. When dealing with onlays involving interproximal surfaces, it is a good idea to floss after seating the onlay and before curing. The restoration was cured from all angles, starting at the interproximal gingival floors where leakage is most likely to occur.

Occlusal flash and excess flowable composite were then “buffed” with a short flame carbide while the interproximal margins were adjusted with bullet or needle carbides. Sometimes a Bard Parker #12 scalpel and Qwik Strip (Axis) are used to allow for easier removal of interproximal cement.

Once the proper occlusion was established, a diamond-impregnated point and/or cup was used to polish the restoration. Polishing was further enhanced through the addition of polishing paste.

In just one appointment, an esthetic and conservative interproximal onlay replacing a mesiobuccal cusp was prepped, placed and polished (Figs. 10, 11).

Case No. 2

This patient also came in with a dental emergency. The filling had fallen out of his broken, lower right molar the day before he was going overseas for three weeks on business. He wanted a “quick and permanent solution” (Fig. 12).

First the tooth was anesthetized. Next, a FenderWedge was used to isolate the involved tooth, protect the adjacent interproximal surface and pre-wedge the teeth for optimal contacts (Fig. 13). The Isolite was placed to obtain a dry and illuminated field. We used caries detector to ensure complete decay removal (Fig. 14). The tooth was then microetched, etched and desensitized with HemaSeal and Cide (Advantage Dental Products). Two layers of self-etching bonding agent (OptiBond All-In-One Unidose, Kerr Dental) were applied to provide reduced postoperative sensitivity and high dentin bond strength. This was then air-thinned and light-cured.

Flowable composite (Premise Flowable, Kerr Dental) was added to the internal walls and floor, creating an even floor and filling in undercuts that were originally prepared for caries removal and amalgam retention (Fig. 15). After the tooth was insulated, the prep was refined with a flat-end cylinder, fine-grit, short shank diamond.

Two Identic hydrocolloid impressions (Dux Dental) were then taken as before. These impressions were handed to the assistant to be poured in the lab (Fig. 16). During the time between the onlay prep and seat, a small filling was done on another tooth to make the most of this appointment time slot while the onlay was being fabricated in the lab.

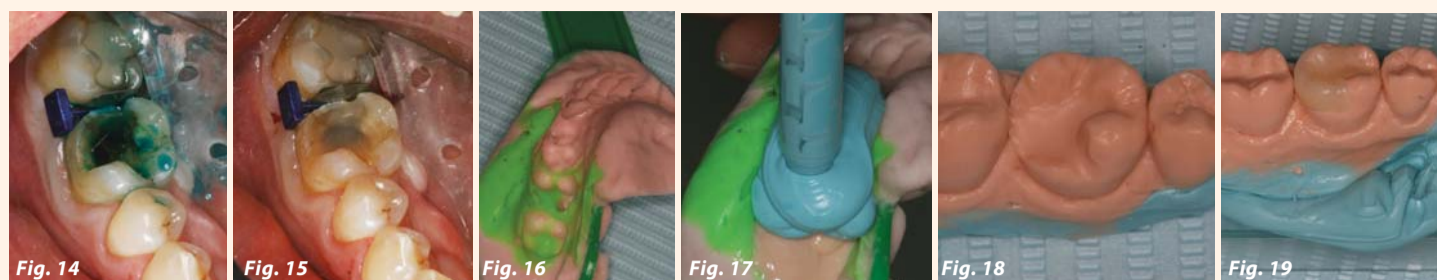


Fig. 14 Caries detector. Fig. 15 Prep with liner. Fig. 16 Identic Hydrocolloid impression. Fig. 17 Basing the poured impression. Fig. 18 Silicone model. Fig. 19 Model with undercuts waxed.

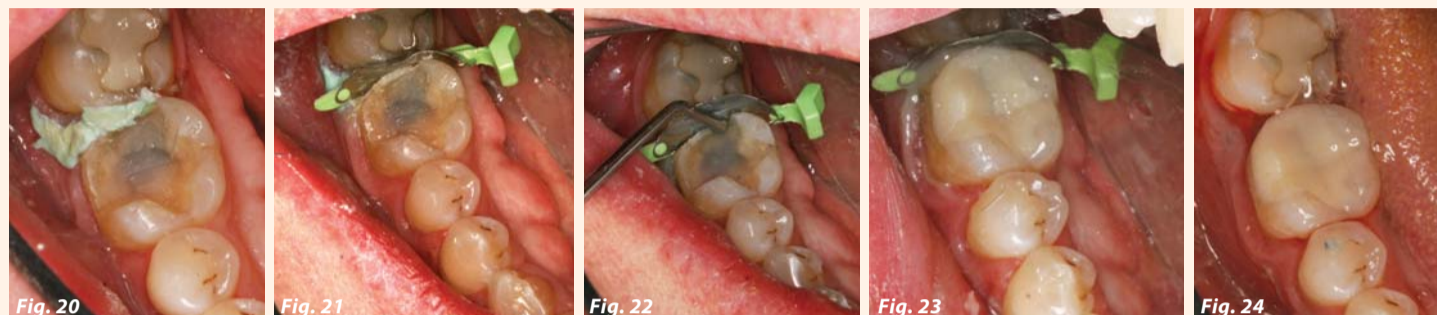


Fig. 20 Expasyl prior to seat. Fig. 21 Expasyl and FenderMate prior to seating. Fig. 22 Adapting FenderMate. Fig. 23 Seating onlay. Fig. 24 Final onlay.

Lab work

As described in Case No. 1, the assistant immediately poured the impressions in the lab with MACH-SLO (Parkell) after disinfecting them and basing them with a rigid, fast-setting bite registration material such as Blu-Mousse (Parkell) (Fig. 17). Within two minutes, we had a working silicone model on which to build the onlay (Fig. 18). The undercuts were then blocked out with an electric waxer (Ultra Water, Kerr Lab), paying special attention to avoid the margins (Fig. 19).

Starting with the Premise Indirect (Kerr Dental) dentinal shades (A2 primary dentin and A1 facial dentin) and ending with incisal shades (Neutral incisal), the onlay was incrementally fabricated in layers using various composite instruments. The onlay was then placed in the BelleGlass curing oven for heat, pressure and light curing.

In approximately 10 minutes, the onlay was ready to be finished with multiple finishing burs (Fig. 20) on the silicone models. The onlay was polished for a high shine and then checked on the model to verify accurate interproximal contacts and margins (Fig. 21).

Seating the onlay

When seating the onlay, the Isolite was reapplied for isolation, ease of placement and the patient's comfort during the cementation stage. Before cementation, Expasyl (Kerr Dental) was gently packed into the sulcus, creating a dry space between the tooth and tissue without any risk of rupturing the epithelial attachment (Fig. 22). The aluminum chloride in the Expasyl dried the tissue, reducing the risk of sulcal seepage and contamination.

The FenderMate was then inserted beneath the interproximal floor to slightly separate and isolate the adjacent teeth and to help facilitate seating the onlay (Fig. 23). The Expasyl (Kerr Dental) was rinsed off thoroughly and the FenderMate was adapted to the adjacent interproximal surface with a condenser (Fig. 24).

Once all of this was properly placed, the enamel and composite core were first micro-etched to remove any debris and increase mechanical retention of the surface of the composite flowable liner. Then the surface was further prepared for bonding with 37 percent phosphoric acid for 15–20 seconds.

A single-component, fifth-generation adhesive (OptiBond Solo Plus Unidose, Kerr Dental) was applied in two coats and air-thinned until there was no more movement. No curing was done at this time. Flowable composite (Premise Flowable, Kerr Dental) in the lightest shade was then dispensed into the prepped tooth before inserting the onlay into the tooth.

Before curing, the FenderMate was removed

and the onlay was further seated using a condenser with gentle pressure. Complete seating was facilitated using the contra-angle packer/condenser. An explorer was helpful in removing excess flowable before curing. Floss was applied between the involved interproximal surfaces before curing and left in place to remove excess interproximal cement and facilitate the cement removal step after curing.

The restoration was cured from all angles, starting at the interproximal gingival floors where leakage is most likely to occur. Occlusal flash and excess flowable composite was “buffed” with a short flame carbide while the interproximal margins were adjusted with bullet or needle carbides. A Bard Parker #12 scalpel and Qwik Strip (Axis) were used to remove interproximal cement and then the remaining floss was used to floss out any remaining cement and to ensure proper at-home flossing.

Once the ideal occlusion was established, diamond-impregnated points and/or cups were used to polish the restoration, starting with the coarsest grit first and finishing with the finest grit for a smooth finish while a PDQ composite polishing brush (Axis Dental) with composite polishing paste (Enamelize, Cosmedent) made for a final high shine.

Conclusion

There are certainly clear advantages for both the patient and the dentist when doing indirect composite resin restorations. These restorations have helped us save patients' teeth, time and money. Over the last 20 years, we have tweaked, updated and modified these restorations in terms of techniques, materials and equipment. These restorations not only save time and conserve healthy tooth structure, they are a valuable service to provide to our patients; and they appreciate it.

Direct composites are an essential part of our armamentarium. Nevertheless, indirect composite restorations have many advantages, especially when dealing with multiple restorations involving adjacent interproximal surfaces. There is simply no comparison between the strength of these materials made outside of the mouth with those cured in the mouth.

Moreover, it is much easier to build, control, polish and finish the occlusal, interproximal and facial/lingual morphology in the laboratory. Patients appreciate the numerous benefits of both direct and indirect composites, and they especially appreciate not having to be in cumbersome temporaries or having an inconvenient second appointment.

Perhaps the greatest advantage for the patient is being able to conserve the maximum amount of healthy structure while saving time and money — all at the same time. “The trend in dentistry today is clearly toward more esthetic and less invasive. Indirect resin and ceramic inlays and on-

lays are not only compatible with this trend, but fulfill very nicely the restorative void between fillings and crowns,” said Ronald D. Jackson, DDS, FAGD, FAACD (Cosmetic Tribune, Vol. 1, Nov. 4, Dec. 2008).

Regarding durability, esthetic inlays and onlays are not new anymore. They have a record of accomplishment, and it is good. Wherever you practice, and however you practice, these restorations are durable, esthetic, economical and very much appreciated! ^{DT}

Contact Information

Dr. Lorin Berland, a fellow of the AACD, pioneered the dental spa concept in his multi-clinician practice in the Dallas Arts District. His unique approach to dentistry has been featured on television (“20/20”) and in national publications and major dental journals, including Time magazine. In 2008, he was honored by the AACD for his contributions to the art and science of cosmetic dentistry. For more information on The Lorin Library Smile Style Guide, www.denturewearers.com and the Biomimetic Same Day Inlay/Onlay 8 AGD Credits CD-ROM, call (214) 999-0110 or visit www.berlanddentalarts.com.



Dr. Sarah Kong graduated from Baylor College of Dentistry where she has served on the faculty in the department of restorative dentistry. She was voted a Texas Super Dentist and Texas Best General Dentist for general dentistry by her peers. Kong is part of a unique multispecialty private practice group in Dallas, www.berlanddentalarts.com, where she focuses on preventive, cosmetic, restorative and pediatric care as well as oral appliance therapy for TMJ, snoring and sleep apnea. Kong is an active member in numerous professional organizations, such as the American Academy of Cosmetic Dentistry, American Dental Association, Academy of General Dentistry, Texas Dental Association and Dallas County Dental Society, where she has served on the membership committee and the peer-review board.



MEDIA CME Self-Instruction Program

How to earn CME Credits? Contact CAPP: events@cappmea.com; +971 43616174

Interview: 'It is not a matter of choice, it is a matter of what we offer'



by Dental Tribune Middle East & Africa

DUBAI, UAE: Sirona is the world's largest manufacturer of dental technology and amongst innovation leaders in dentistry. Preferred partner for many dental practices, clinics, dental laboratories and authorized distributors worldwide. The company develops, manufactures and markets a complete line of dental products. Dental Tribune Middle East & Africa interviewed Dr. Amro Adel, Sales Manager for the GCC Markets to find out more on Sirona in The Middle East. Dental Tribune Middle East & Africa: Sirona has over 10,000 dental clients in the entire GCC region, this means big support, big responsibilities, big planning. What are the plans for 2013?

Dr. Amro Adel: Well there's always a plan for the GCC. We always have many services we provide to the dentists. We cherish the support of our customers and we always try to give them the best service possible. Nowadays we are very keen to give them the updated equipment and units from the market, to give them technical support directly from Sirona along with our dealers, and this is something no other company in the Middle East actually do for their customers. With the support Sirona provides to our customers nowadays, we can rank

"The coming year, 2013, is a key year in the industry"

ourselves amongst the first companies in the entire Middle East with such services.

What is the feedback you receive from your clients?

Feedback is always welcome. Mostly we receive positive feedback and sometimes negative, but supportive, feedback which is a good thing. Negative feedback and competition are always welcome to have, without this we cannot improve. I believe all feedback we receive, negative, positive, thankful or harsh replies, will always keep us on the right track and lets us know what to do next.

Indeed the feedback will lead to improvements, new developments and innovations. What about the coming year, 2013, what are you planning for your clients?

The coming year, 2013, is a key year in the industry with major event such as IDS Cologne, CAD/CAM & Digital Dentistry Dubai and AEEDC Dubai. You know that we are already very present in the Middle East, we have the AEEDC in February followed by IDS in Cologne in March and CAD/CAM Digital Dentistry in Dubai again in May. During this period we are coming out with a huge variety in different, new products along the lines of what we are representing in the market (from imaging, CAD/CAM, instruments and dental units) and I hope that all dentist will have a chance to visit us at these conferences to

your opinion, why do you think so many dentists chose Sirona in comparison with the rest of the industry? Why does Sirona stand out so much?

Well it's not a matter of choice, it's a matter of what we offer: A fully dedicated team that supports the market unlike any other company in the whole Middle East region and this team actually is consisting out of many dentists as well as technical managers who are basically engineers. The team has only one focus which is "what we say is what we do", we promise you something and we always deliver and at the end of the day Sirona wants to reach each and every dental clinic and inform them about what the new products are. To my opinion, our crew gained the trust of all these dentists, by working in the market now and that is



Overlook of the state of the art Sirona office showroom in UAE

explore what new things Sirona is bringing to the market.

Any hints on what we can expect?

What I can hint about is that we are changing lots of products. First of all I cannot give you any information about the new ones, but I can give you information about the updates that we have on existing units and the first being the camera which we introduced onto our CAD/CAM system, which is the Omnicam. This is the dream of what dentists were looking for before, the powder free camera, the anatomical exact-like filming of the mouth. Like a camera it's very easy to use, it's something that everybody will be looking forward to have: a small size camera that can reach even more the non accessible areas to take pictures. So I think this is something very unique and all of our customers are welcome to see it very soon, because we get the new products very fast, we will show it at the 4th DFCIC in the coming week in November in the Jumeirah Beach Hotel so I think this will also be a good chance for the dentists to have a look.

Dr. Amro, you have vast experience in the Middle East and GCC region, according to

what they are really looking for, focusing on their needs. We are not looking only for sales, we offer support on the scientific base and this is also something different that we deliver to the market. In addition, we also have lots of subsidiaries worldwide which dentists like. You look at the market in UAE and the market in Qatar, you will not only find local dentists but lots of international dentists move from all over the world to come to the region to work. So as long as we have our subsidiaries serving dentists outside the middle east or even better, we give them another impression that we are also doing better than the competition proving that Sirona from one region to the other are doing their best to support their customers. So we are gaining the trust of our customers bit by bit, and to my opinion this is what Sirona is looking for momentarily, to prove that we are the best, prove that Sirona has the real name 'Sirona The Dental Company' and at end of the day; unique products, dedicated people, and here we go.

In addition to the Dentists, Sirona also target the Dental Technician, an important part of the dental team. Could you empha-

size on the services and trainings you provide them?

In the region here we have lots of professional dental technicians and the sector for dental technicians is actually a section that we are really focusing on at the moment, there is a full support from our CAD/CAM division to support our product, which is the inLab CAD/CAM system, now considered to be one of the pioneering products in the market proving really good in lots of countries such as Kuwait, UAE and in Egypt, a long way through The Middle East. We have an excellent feedback about our products so far and what I can say is that we started to ranked very good in the market in the lab site, and the idea behind this, why we reached this point at the moment is because we are really focused. The dental technicians really need more support and they really need the companies to focus more on their needs. It is not just playing around with a computer saying I can design CAD & CAM, but it's also the support that you get from the principle company, the support that you get out of them in the way that I can reach my goals, I can deliver: when I ask my customer to pay for something he pays because he knows exactly what is quality. So I believe that the dental technicians will be playing an important role in our future, and the CAD/CAM system we're delivering at the moment will be exactly like the clinical side more and more improved based on the feedback. We will be backing up the dental technicians for sure.

To summarize, Sirona not only offers the full total package with your solutions but also offers the full aftersales service which is even more important to dentists, dental technicians and dental clinics nowadays?

We always have and will always do our best to do so.

Dr. Amro, is there anything else you would like to share with us?

Thank you very much, we are always looking forward to such kind of meetings, such kind of interviews where we can display a wide screening of what exactly the principles of the company are and what we are doing here in the region. We achieve our goals, we do our jobs and at the end of the day it's a win-win situation.

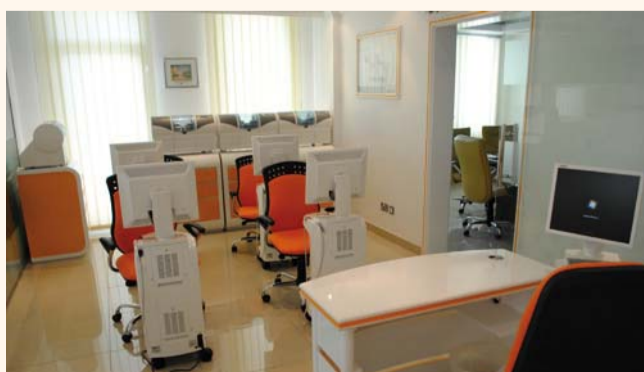Thank you Dr. Amro Adel, we wish you all the best in the very important coming year for Sirona and yourself. DT

Contact Information

Dr Amro Adel
Sales Manager GCC
Sirona Dental Systems GmbH
amro.adel@sirona.com



Technical Training facility



CAD/CAM Training Facility



Continuous Education Programmes: Part of Sirona Training Facilities. Dr. Amro Adel and Mr. Sebastian Schäfer

Sirona appoints new CEO

By Dental Tribune International

BENSHEIM, Germany/NEW YORK, USA: Sirona, global provider of dental products, has appointed a new CEO. As from 20 February 2013, Jeffrey T. Slovin will succeed Jost Fischer, who has held the position for 11 years. Fifty-eight-year-old Fischer will be retiring, giving up his position as both CEO and chairman of the board.

Sirona also announced that Dr Thomas Jetter, a current member of Sirona's board of directors, will assume the role of non-executive chairman of the board upon Fischer's retirement. Effective immediately, as part of the succession plan, Rainer Berthan has been promoted to executive vice-president responsible for the company's business segments.

"Jeffrey Slovin is the ideal candidate to succeed me as Sirona's CEO," Fischer commented. "He has the necessary experience and stellar reputation within the dental community to take Sirona into the future. Before joining Sirona in 2006, Jeff was CEO of publicly traded Schick Technologies, Inc. where he built a reputation as an innovator and operator, and delivered significant shareholder value. Since joining Sirona, he has consistently demonstrated excellent judgement and played a major role in

improving our operations, targeting our research and development efforts and leading growth initiatives."

Fischer continued: "This appointment is part of a leadership succession process that was methodically developed over the past several years in preparation for this very day. Jeff has the full support of myself and the board. During my 11 years as CEO of Sirona, we have built Sirona from a primarily German company to a truly global leader in dental technology. Sirona is well positioned for the future, with a powerful sales and service infrastructure, a strong management team, and an outstanding product portfolio. I am excited to watch as Jeff takes Sirona to new heights."

"Thomas Jetter was the private equity partner responsible for the investment in Sirona after its spin-off from Siemens, from 1997 to 2004. His relationship with the other board members, his global experience and long history with Sirona should make the transition seamless," Fischer added.

Slovin, 48, has served as Sirona's president since September 2010 and prior to that as executive vice-president and chief operating officer of its US operations. Before that, Slovin was CEO of Schick Technologies, a leading dental technology company that was acquired by Sirona in 2006. Slovin is currently a member of the Board of Fellows



Jeffrey T. Slovin will be the new CEO of Sirona. (Photo courtesy of Sirona)



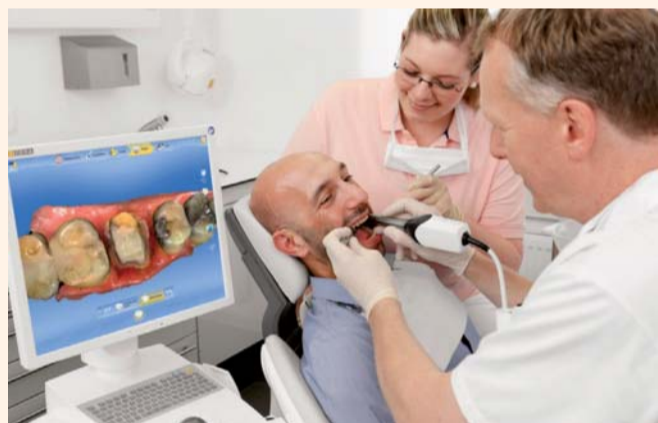Jost Fischer has served as Chief Executive Officer of Sirona since April 2002 and has served as Chairman of the Board of Directors since June 2006

of the Harvard School of Dental Medicine, and a member of the Young Presidents' Organization. He holds an MBA from Harvard Business School.

Jetter, 55, has served as a director since April 2010 and is currently a member of the Nominating and Corporate Governance Committee of Sirona's board of directors. From April 1995 to March 2008, Jetter was a partner at Permira, where he initiated and managed investments in a variety of medical technology, industrial, and chemical companies and helped expand the firm's global reach to include areas such as the US, Brazil and China. Prior to that, Jetter gained extensive experience at McKinsey in Germany and Brazil. He holds a PhD

degree in Economics and Banking, and an MBA from Saarland University in Saarbrücken, Germany.

Berthan, 48, joined the company as a vice-president in September 2012. Prior to joining Sirona, Berthan served at Demag Cranes, a publicly listed company, as executive vice-president. From 2004 to 2008, Berthan was President of Weidmuller in China, a leading German company in the industrial automation business. Prior to these roles, he held various senior management positions at leading companies. Berthan holds a Master's degree in Economics from the Munich University of Applied Sciences, Germany. **DT**



Making the dream better...

Since 1980; when Pr. W. Mörmann (University of Zurich) and M. Brandestini invented the first chairside CAD/CAM unit (CEREC) and come out with the prototype then the CEREC 1 in 1985 the dream just continued getting better.

From the questions:

Can we make a Chair-side CAD/CAM restoration? How durable will it be? How aesthetic can it be? Is it economically feasible? Are dentists ready for this technology?

... Came other questions later on as the Dental World accepted this technology with opened arms.

All through the 80's, 90's and the beginning of the 21st Century, researchers continued their hard work and attempts to improve, coupled with the advancing Software and Hardware Technology, as well as the remarkable improvements in the Science of Materials whether Dental Ceramics or Resin Cements.

So what exactly was done to make the dream better?

Intra-oral Scanners got more and more precise, accurate and easy to use

Softwares became much more sophisticated yet more user friendly than ever.

Milling accuracy reached a remarkable level.

With these 3 factors in mind (and years of research work showing an extraordinary success rate), we can now take multiple intra-oral scans of the prepared teeth, opposing dentition and even the bite registration to form a True-colour 3D virtual model, without the use of a reflecting medium (Spraying powder or painting liquids). Use these models to design every little detail of our restorations (whether inlays, onlays, Veneers, Crowns, Bridges, attachments, bars, abutments or whether importing these images to 3D Cone beam C.T. for Implant planning), and then mill our restorations (in-house Surgical guides) with great ease; making our patients visits easier and less time consuming while the Dentists enjoy an impression-free, bite registration-free and Temporaries-free work flow.

This is CEREC AC OmniCam, the latest generation of Chair-side CAD/CAM systems from Sirona. **DT**

Dr. AbdelAziz Yehia
Sirona Middle East -
Business Development Manager CAD/CAM

Sirona moves headquarters in Austria



Jost Fischer (right) and staff celebrating the opening on Monday. (DTI/Photo courtesy of Sirona Dental Systems/Austria)

By Dental Tribune International

WALS-SIEZENHEIM, Austria: Dental technology manufacturer Sirona Dental Systems opened its new headquarters in Wals-Siezenheim near Salzburg in Austria this week. The new facility, which also boasts a nearby street bearing the company's name, will offer expanded capacity for 120 employees working in administration, financing, human resources, marketing and sales.

Much of the company's production will still be based in Benzheim in Germany, where the company originated as a subsidiary of industry giant Siemens over 50 years ago. CEO Jost Fischer said that the opening of a new, larger headquarters was necessary to keep pace with the growth of the company. "We have invested over US\$250 million in the last six years to keep ahead of the mar-

ket and to offer customers the most innovative products," he commented.

Sirona moved from Germany to Austria in 2007 and has since quadrupled its staff, according to Fischer. Worldwide, the company now employs 3,000 people in 29 subsidiaries and achieves global revenues of over €700 million annually.

Sirona has operated as an independent entity in the market for over 15 years. Since 2004 and 2006, US-based Schick Technologies and the Danish specialist in dental hygiene products Nitram Dental have also belonged to the Sirona Group. In addition to its dental CAD/CAM system CEREC, it has established itself as a leading developer of high-tech dental equipment, including instruments, as well as a number of imaging and digital treatment solutions. Recently, the company unveiled a new intra-oral camera during its 27-and-a-half-year anniversary celebration in Las Vegas, among other new products. **DT**