

DENTAL TRIBUNE

—The World's Dental Newspaper · Middle East & Africa Edition—

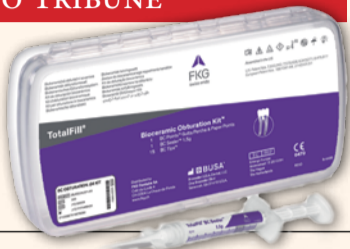Printed in Dubai

www.dental-tribune.me

January-February 2016 | No. 1, Vol. 6

ENDO TRIBUNE

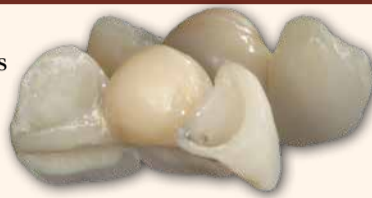Non-surgical repair of a cervical resorptive defect utilizing...



>Insertion

LAB TRIBUNE

Together towards pink-white esthetics



>Insertion

HYGIENE TRIBUNE

Classic versus modern: Comparison of new method of professional...



>Insertion

Oral-B paves the way forward with 'Up-To-Date' scientific exchange seminars

By Dental Tribune MEA/CAPPmea

The Oral-B brand is a global leader in the brushing market. Part of Procter & Gamble Company since 2005, Oral-B brand includes manual and power toothbrushes for children and adults, oral irrigators, oral care centers and interdental products such as dental floss.

Since joining as the Professional & Academic Relations Manager at Oral-B, Dr. Ashhad Kazi and the AP team have played a significant role in the develop-

ment of Dental Education in the Middle East and Africa region over the past 5 years.

In 2014, the Oral-B team successfully launched the very first scientific exchange seminars for dentists, hygienists and dental therapists at several different locations within the GCC. The proven concept which has been running in Europe for several years has now become a pivotal backbone of the Oral-B philosophy within the MEA region. Dr. Kazi commented "We over exceeded our plans and expectations for the region in 2015. Over



EPDC Meeting 2015 – Supported by Oral-B

the last two years we have strived to deliver top notch education whilst improving overall health conditions in the region through our new initiative. With science and groundbreaking technol-

ogy, the Oral-B innovations of stabilized stannous fluoride (in the Oral-B

> Page 49

Successful Ormco 2nd MENA Symposium in Dubai

By Dental Tribune MEA/CAPPmea

DUBAI, UAE: On 4 and 5 December 2015, American orthodontic, Ormco, held its 2nd MENA Symposium in Dubai Jumeirah Emir-

ates Towers. 500 international delegates attended the various presentations of the international speakers. The presentations were mainly focused on Damon System and its umbrella products usage. Ormco has offered a variety of topics af-

ter which the delegates could pursue the excellence of orthodontics by attending the event.

The first day has started with Dr. Stuart Frost from the US lecture with the title "It is all about the finish. Becoming a Damon Master finisher!" During which he has discussed the importance of facial based treatment planning for more beautiful faces and smiles with excellent finishes. The lecture was followed by Dr. Hans Seeholzer from Germany who spoke mainly about marketing in orthodontics with the lecture titled "Tips and tricks to be a successful and modern orthodontist today" and

> Page 2



From the left, Tarek Haneya, Xavier Cherbavaz, Steffen Saupe, Dr. Jeff Kozlowski, Ahmed Dahbi, Dr. Naser Al Hamlan



Dr. Hans Seeholzer, Germany

CAREERS

Career Opportunities
Job openings
Dental Categories

www.dental-tribune.com/careers

EVENTS	1, 2, 46-49
INDUSTRY	6-7
MEDIA mCME	8-12
ORAL HEALTH	12-15
AESTHETICS	16-21
PAEDIATRIC TRIBUNE	22-23
IMPLANT TRIBUNE	24-30
CAD/CAM	32-36
ORTHO TRIBUNE	38-40
GENERAL DENTISTRY	42-43
PRACTICE MNG	44



Dr. Zakaira Bentahar, Morocco



Dr. Andrey Tikhonov, Russia



Ormco team during the 2nd MENA Symposium



Delegates during the 2nd MENA Symposium



Ormco booth during the 2nd MENA Symposium



Delegates during the 2nd MENA Symposium

the day was finished by Dr. Zakaria Bentahar who answered the question “How to improve efficiency with passive self-ligating brackets?” In the end of the day, after the full day of lectures the delegates were invited to attend the cocktail reception that was held in Jumeirah Emirates Towers.

Dr. Andrey Tikhonov from Russia has opened the second day program of the 2nd MENA Symposium with his lecture

“Damon System Truths versus Myths” during which he said that “Orthodontics is about changing people destiny, so it is not only about straightening teeth.” The lecture of Dr. Tikhonov was followed by Dr. Philippe Van Steenberghe on elastics and how important they are under the title “Early elastics a new world to explore”. The day was finished with two lectures of Dr. Jeff Kozlowski’s Digital Orthodontics showing how to use

Insignia and how passive self-ligation can help enhance the efficiency and effectiveness of treatment for your practice and patient.

During the two day symposium the speakers elaborated mainly on the benefits of Damon System usage in their practices. Additionally, during the breaks in between the lectures, the participants could see an interactive display of the Damon System and also

displayed Damon System umbrella products displayed in Ormco booth.

Moreover, the new addition to the 2 day agenda were hands-on courses on brackets positioning. The two hands-on courses were given by Dr. Stuart Frost and Dr. Dimitris Mavreas. During the courses the guests could practice on the Ormco typodonts and discover further the Damon System. [DT](#)

Orthodontics goes Digital with CEREC from Sirona

By Dr. AbdelAziz Yehia, UAE

It finally happened... Since I.D.S. 2015, when Sirona unveiled the CEREC Ortho Software, a Software uniquely designed to send accurate 3D full arch scans to World-Class providers like, and in cooperation with Invisalign, 5M Incognito, Dolphin Software, and

others... as well as the possibility to connecting to a Sirona laboratory, and the Dental Market has been waiting the release of this Software; with the Gulf (specifically United Arab Emirates) being no exception.

Now (since December, 2015) Dr. Amro Adel, General Man-

“On the 11th of December, the first CEREC Ortho training took place in the Raffles Hotel”

> Page 38



Sirona users enjoying the simplicity of the CEREC Omnicam.



The special course attracted 11 participants representing 4 Dental Centers in Dubai – U.A.E., and 1 Dental Center in Doha – Qatar.



Sirona Dental System L.L.C (Dubai – U.A.E.) has officially announced the launch of the CEREC Ortho Software that can be supplied in combinations. First CEREC Ortho Training on 11th of December 2015.

DENTAL TRIBUNE

The World's Dental Newspaper - Middle East & Africa Edition

GROUP EDITOR
Daniel Zimmermann
newsroom@dental-tribune.com
Tel.: +49 541 48 474 107

CLINICAL EDITOR
Magda Wojtkiewicz

ONLINE EDITOR
SOCIAL MEDIA MANAGER
Claudia Duschek

EDITORIAL ASSISTANTS
Anne Faulmann
Kristin Hübner

COPY EDITORS
Sabrina Raaff
Hans Motschmann

PUBLISHER/PRESIDENT/CEO
Torsten Oemus

CHIEF FINANCIAL OFFICER
Dan Wunderlich

CHIEF TECHNOLOGY OFFICER
Serban Veres

BUSINESS DEVELOPMENT MANAGER
Claudia Salwiczek

JUNIOR MANAGER BUSINESS DEVELOPMENT
Sarah Schubert

PROJECT MANAGER ONLINE
Tom Carvalho

EDUCATION MANAGER
Christiane Ferret

EVENT MANAGER
Lars Hoffmann

MARKETING & SALES SERVICES
Nicole Andra

EVENT SERVICES
Esther Wodarski

ACCOUNTING SERVICES
Karen Hamatschek
Anja Maywald
Manuela Hunger

MEDIA SALES MANAGERS
Matthias Diessner (Key Accounts)
Melissa Brown (International)
Antje Kahnt (International)
Peter Witteczek (Asia Pacific)
Weridiana Mageswki (Latin America)
Maria Kaiser (USA)
Hélène Carpentier (Europe)
Barbora Solarova (Easten Europe)

EXECUTIVE PRODUCER
Gernot Meyer

ADVERTISING DISPOSITION
Marius Mezger

DENTAL TRIBUNE INTERNATIONAL
Holbeinstr. 29, 04229 Leipzig, Germany
Tel.: +49 541 48 474 502
Fax: +49 541 48 474 173
www.dental-tribune.com
info@dental-tribune.com

DENTAL TRIBUNE ASIA PACIFIC LTD.
Room A, 20/F
Harvard Commercial Building
105-111 Thomson Road, Wanchai, HK
Tel.: +852 3113 6177
Fax: +852 3113 6199

THE AMERICA, LLC
116 West 25rd Street, Ste. 500, New York
N.Y. 10011, USA
Tel.: +1 212 244 7181
Fax: +1 212 244 7185

DENTAL TRIBUNE MEA EDITION EDITORIAL BOARD
Dr. Aisha Sultan Alsuwaidi, UAE
Dr. Ninette Banday, UAE
Dr. Nabeel Humood Alsabeeha, UAE
Dr. Mohammad Al-Obaida, KSA
Dr. Meshari F. Alotaibi, KSA
Dr. Jasim M. Al-Saedi, Oman
Dr. Mohammed Sultan Al-Darwish
Prof. Khaled Balto, KSA
Dr. Dobrina Mollova, UAE
Dr. Munir Silwadi, UAE
Dr. Khaled Abouseada, KSA
Dr. Rabih Abi Nader, UAE
Dr. George Sanoop, UAE
Dr. Olivier Carcuac, UAE
Aiham Farrah, CDT, UAE
Retty M. Matthew, UAE

PARTNERS
Emirates Dental Society
Saudi Dental Society
Lebanese Dental Association
Qatar Dental Society
Oman Dental Society

DIRECTOR OF mCME
Dr. Dobrina Mollova
mollova@dental-tribune.me
Tel.: +971 50 42 45072

DIRECTOR
Tzvetan Deyanov
deyanov@dental-tribune.me
Tel.: +971 55 11 28 581

DESIGNER
Kinga Romik
k.romik@dental-tribune.me

SMALL CHANGE. BIG DIFFERENCE.

The new imaging plate scanner XIOS Scan completes the intraoral family from Sirona. Whether you're taking the first steps into the digital world or establishing or updating a fully digital practice, XIOS Scan and XIOS XG Sensors offer perfectly synchronized solutions for every-workflow. **Enjoy every day. With Sirona.**



THE NEW
IMAGING PLATE
SCANNER:
XIOS Scan

SIRONA.COM

The Dental Company

sirona.

3M Oral Care at Saudi Dental Society

By 3M

On 5-7 January 2016 3M Oral Care Saudi Arabia took part in the 16th King Saud University International Dental Conference and the 27th Saudi Dental Society Conference held at the Riyadh International Convention and Exhibition Center. Newest Oral Care products and solutions were presented and the exhibition booth which was equipped with designated areas for customer hospitality, product demonstrations and hands-on workshops.

Wide range of dental and orthodontic products used and recognized by thousands of oral care professionals worldwide was presented at the booth. Doctors demonstrated keen interest in new 3M products and solutions such as Filtek™ Bulk Fill Posterior Restorative,

Ketac™ Universal Glass Ionomer Restorative, 3M™ True Definition Scanner as well as Clarity™ Advanced Ceramic brackets and APC™ Flash-Free orthodontic systems.

Traditionally core dental products such as Single Bond Universal Adhesive, Filtek™ Z350 XT Universal Restorative, RelyX™ cements range, Penta™ impression materials for Pentamix™ mixing units, temporization products including Protemp™ 4, Stainless Steel Crowns, Pedo Strip Crowns as well as orthodontic products including Victory Series™ Bracket System, TADS and Incognito™ Appliance System were also displayed at the booth.

A special area equipped with products and all necessary tools for hands-on workshops was allocated at the booth. The workshops were run by

3M Scientific Affairs & Education Team specialists Dr. Haitham Yousef and Dr. Mustafa El Sammak. The 3-day workshop schedule included sessions on such actual topics as new trends in posterior restorations, precise conventional and digital impressions with innovative 3M™ True Definition Intra Oral Scanner. In the breaks between the workshops doctors could relax with the cup of fresh Arabic coffee and dates in the hospitality lounge with comfortable sofas.

“3M has been working hand in hand with the Dental Industry in the Kingdom of Saudi Arabia for over a decade. We strongly believe in transfer of knowledge and enhancing the level of patient care through a variety of hands-on workshops, lectures and seminars. We believe that once the dentist is convinced on the efficacy and



3M booth at Saudi Dental Society Int'l Conference 2016



efficiency of our products he will become a lifelong user. 3M tries to cater to the needs of all segments of the industry, be it Government, Private clinics or Universities. To further increase our relevance to the local requirements, 3M has recently started work on the set up of the first manufacturing facility in the Middle East & Africa region. The groundbreaking ceremony was held in December 2015 at the site in Dammam. This step will bring us even more close to the

customers as we will be able to customize our products and solutions for the local needs.” – commented Michal Mirowski, General Manager, Health Care Business Group, Saudi Arabia. ^{DM}

Contact Information

For more information please contact 3M at www.3MGulf.com/espe

Large diastema closure with Filtek™ Z350XT Universal Restorative

By 3M

Female patient, 26 years old. Main complaint about the spacing between her teeth with complete rejection of orthodontic treatment and laminate veneers. Direct restoration was made using Filtek™ Z350XT Universal composite (Enamel and Dentine), Single Bond Universal adhesive, Sof-Lex™ finishing and polishing discs and interproximal finishing strips. ^{DM}

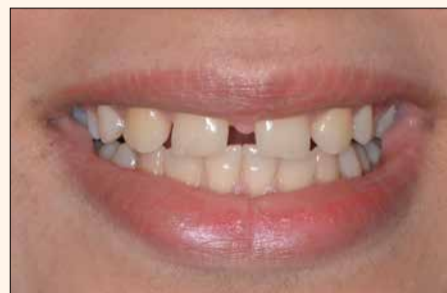

Fig. 1: Pre-operative view

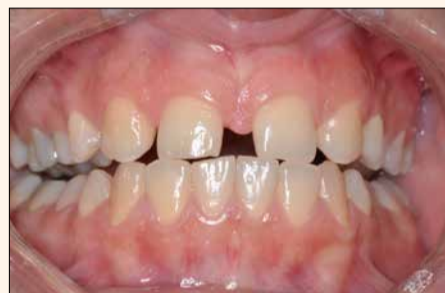

Fig. 2: Pre-operative view with retracted lips

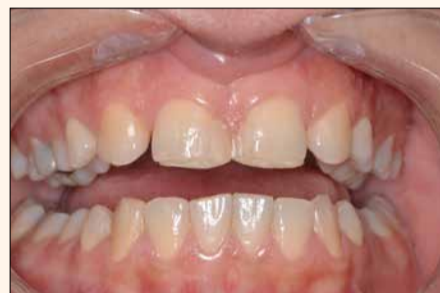

Fig. 3: Composite mock-up for the two centrals

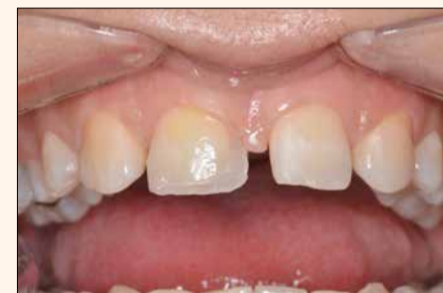

Fig. 4: Palatal matrix of Filtek™ Z350XT Universal Composite (Enamel A2) for upper right central

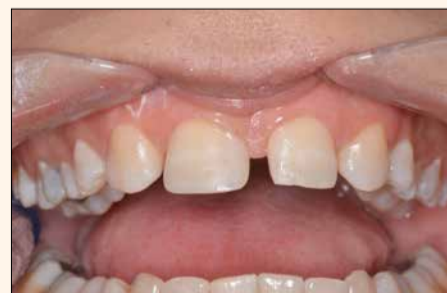

Fig. 5: Finished composite for upper right central using Enamel A2 and Dentine A2

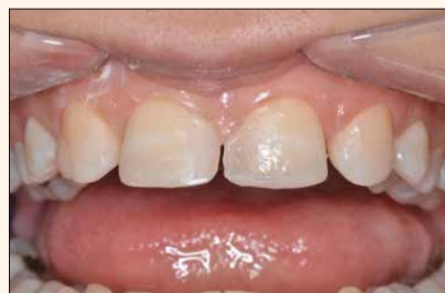

Fig. 6: Palatal Matrix of Filtek™ Z350XT Universal Composite (Enamel A2) for upper left central

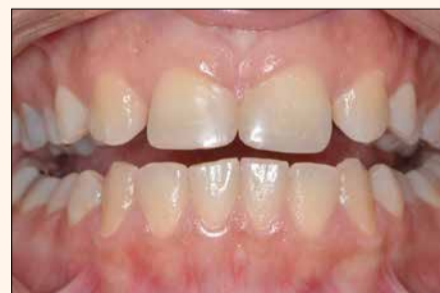

Fig. 7: Finished composite for upper right central using Enamel A2, Dentine A2

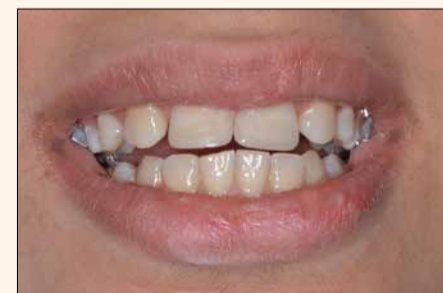

Fig. 8: Post-operative view for upper right and left centrals

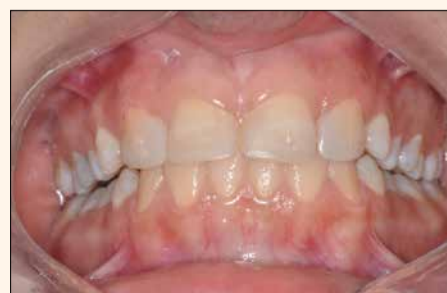

Fig. 9: Reshaping of upper right and left laterals using Enamel A2 and Dentine A2

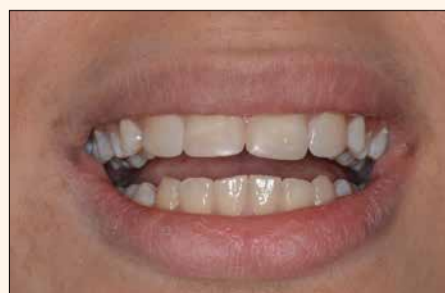

Fig. 10: Post-operative view of the case

About the Author



Dr. Mohamed Fouad Haridy
Associate Professor of Restorative Dentistry, Cairo University.

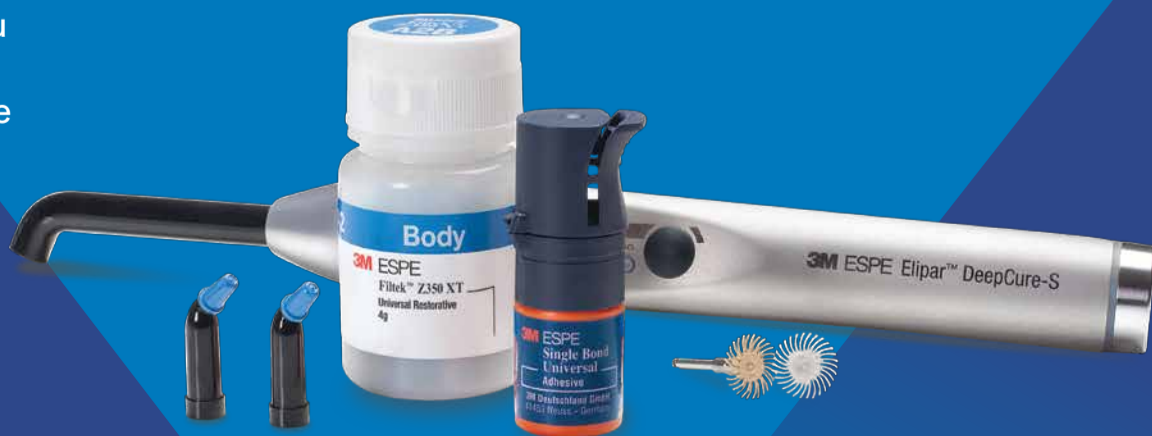Head of Restorative Department of British University in Egypt (BUE)

Let's make happiness a clinical outcome

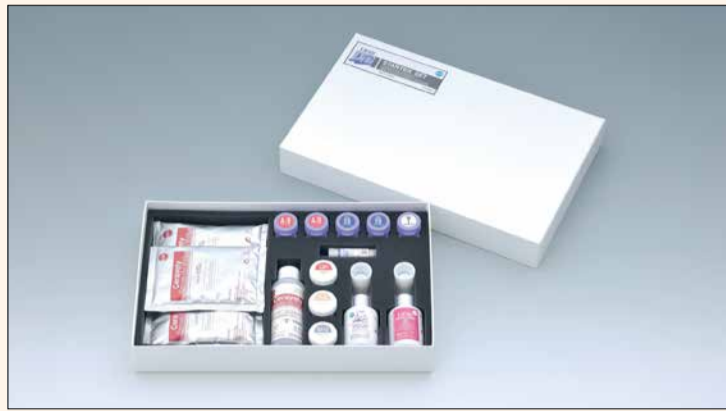Postoperative sensitivity. All dentists worry about it. No patient wants it. With Single Bond Universal Adhesive, you can virtually eliminate it whether you prefer a total-etch, self-etch or selective-etch technique. And for strength and esthetics anywhere in the mouth, use Filtek™ Z350 XT Universal Restorative. Then complete the restoration with Sof-Lex™ Spiral Finishing and Polishing Wheels, which adapt to all tooth surfaces.

It's one simple system that's as versatile as it is effective. At 3M, we simplify outcomes. Especially happiness. For you and your patients.

www.3MGulf.com/espe



Vintage LD... The Better Lithium Disilicate



Vintage LD

By SHOFU

Vintage LD is an innovative lithium disilicate system from Shofu that offers you greater flexibility, more treatment options and aes-

thetic versatility for a variety of all-ceramic anterior and posterior restorations. A combination of three perfectly compatible components comprising of high strength Lithium Disilicate glass ceramic ingots in varying

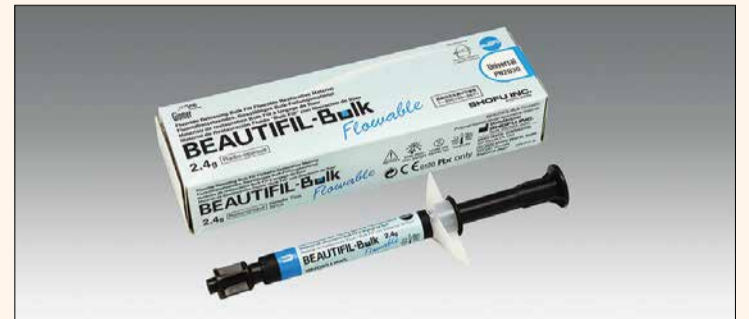levels of translucency, a naturally shaded, opalescent silicate based veneering porcelain and a comprehensive range of low fusing fluorescent stains offers the choice of pressing, staining and highly aesthetic cut back or full build-up layering techniques.

Designed to fulfill the demanding aesthetic requisites of discerning dental professionals, Vintage LD exhibits outstanding shade stability even with multiple firings with virtually non-existent reaction layer for a faster, simpler and error-free fabrication cycle.

Available in sets or as refills to meet the individual needs of your lab. [DT](#)

Beautiful Bulk

A Smart approach to smarter dentistry



Bulkfill flow



Bulkfill

By SHOFU

Reduce chair time and your inventory too... with Beautiful BULK, the new generation bulk fill resin restorative developed for easier, faster and predictable posterior restoration. Formulated in 2 discrete viscosities to fulfill individual preferences, Beautiful BULK Flow, a flowable variant is ideal for dentin replacement and a sculptable Beautiful BULK restorative to restore to full contour. Excellent chameleon effect is achieved with just two shades (Restorative Universal and A shade) of Beautiful BULK restorative that blends in imperceptibly with surrounding tooth structure.

Developed with S-PRG filler technology, Beautiful BULK Giomer resins come with additional anti-plaque benefits and sustained fluoride release and recharge to protect against recurrent caries. Exceptionally high filler load with unique filler resin structure maximizes light penetration for optimum cure (Up to 4 mm) while lowering polymerization shrinkage stress. [DT](#)

bicon
DENTAL IMPLANTS

Since 1985 » Simple. Predictable. Profitable.

SHORTEX
IMPLANTS

31 YEARS OF CLINICAL USE SINCE 1985

6.0 x 5.7 mm, 5.0 x 6.0 mm, 5.0 x 6.0 mm, 5.0 x 5.0 mm, 5.0 x 6.0 mm, 6.0 x 5.0 mm, 6.0 x 5.7 mm, 8 Years

TRINIA

14 Years 6.0 x 5.7 mm, 4.5 x 6.0 mm, 7 Years, 5.0 x 5.0 mm, 6.0 x 5.7 mm, 6.0 x 5.7 mm

Blood Vessel within Haversian System

Register now for our free IMPLANTOLOGY COURSES!



Bicon Europe Ltd. ■ Office 204, Swiss Tower ■ Jumeirah Lake Towers, Dubai, UAE ■ P.O.Box: 634313 ■ phone: +971 4 4410793 fax: +971 4 4470799 ■ e-mail: emirates@bicon.com ■ mobile: +971 558087259 ■ www.bicon.com

Contact Information

SHOFU DENTAL ASIA-PACIFIC PTE. LTD.
10 Science Park Road
#05-12 The Alpha
Science Park II
Singapore 117684
Tel: 65 6377 2722
Fax: 65 6377 1121
Website: www.shofu.com.sg

Splyce ID: Designing Bespoke Modern Wonder Clinics Part III (The Color White)



“Choosing the right white in itself is a job. There are unbelievable choices of white available to pick from...”

By Nijas Salim, UAE

There's a lot of white at play in clinics. But it seems like we still can't have enough. So what is with the color white I want to know?

That previous line almost plays out in my head like lyrics to a song. But that's what I am asking Ranjit Prasad, the Principal Architect of Splyce. We know the obvious, white is the embodiment of cleanliness, of health and hygiene, the spick-and-span-germ-free hue, the sign that there is nothing sinister, however small in size, lurking, an RGB version of what you see is what you really get.

White has always been symbolic of purity and of freshness but Ranjit will tell you that despite white being a de facto color of use in the healthcare industry, white makes a massive design statement and its use has desired effects. White has the ability to expand the sense of space, and alter the experience of shapes. Though easy on the eye, it still needs utmost care, and this care is transformed into the assimilation of attributes of luxury. White is also quite relaxing and nourishing.

“Choosing the right white in itself is a job. There are unbelievable choices of white available to pick from. We once sourced the same paint used on the body of luxury cars for a wall to convey uber luxury.

White really brings out the accents

and suddenly accents get an elevated status. The warmth of wood or gold trimmings, they all finally get maximum exposure. White also brings artificial light sources into play, and the impact of the color of the light gets magnified. White helps natural light seeping in to get a magnificent glow. So much more can be done with finishes when coupled with white. I also like how white accentuates minute details and curves, thus allowing the care, thought, and stand out details of our design to be really seen and experienced.”

And suddenly I remember the importance of the color white, the understated king, the one that all colors unite to become. I remember that Krzysztof Kieslowski film, the one that imitates life, the one that is filled with humor, is called, White.

Splyce Interior Designs is a boutique agency driven to meet satisfactions of a clientele that know the value of good design and has incorporated that into their own philosophy. Splyce believes its raison d'être is creating stunning designs that exceeds client expectations.

Contact Information

Nijas Salim, UAE
E: nijas@backerandbacker.com

BRILLIANT EverGlow™

UNIVERSAL SUBMICRON HYBRID COMPOSITE

- Outstanding polishability and gloss retention
- Brilliant single-shade restorations
- Ideal handling through a smooth consistency
- Good wettability on the tooth surface

The glow of the art

<https://everglow.coltene.com>

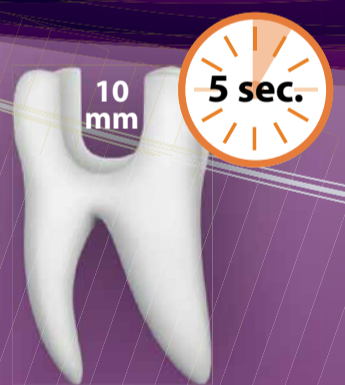

Fill-Up!

DUAL CURING BULK COMPOSITE

In a single step to give a perfect result

- Optimal depth polymerisation with minimal shrinkage due to dual curing system restoration.
- Guaranteed single-layer technique - even in very deep cavities of 10 mm
- Optimised sealing of margins - reduced post-operative sensitivity
- Universal shade in a convenient Automix syringe for efficient placement



YOUR CONTACT

Dietmar Goldmann
Sales Manager Middle East and Africa
dietmar.goldmann@coltene.com
www.coltene.com

COLTENE

Predictable Endo 102: Why warm and soft is so good

System 'S' for injectable or carrier-based GP



mCME articles in Dental Tribune have been approved by:
HAAD as having educational content for 2 CME Credit Hours
DHA awarded this program for 2 CPD Credit Points

ADA CERP® | Continuing Education Recognition Program

Centre for Advanced Professional Practices (CAPPP) is an ADA CERP Recognized Provider. ADA CERP is a service of the American Dental Association to assist dental professionals in identifying quality providers of continuing dental education. ADA CERP does not approve or endorse individual courses or instructors, nor does it imply acceptance of credit hours by boards of dentistry.

CAPPmea designates this activity for 2 continuing education credits.

By John J. Stropko, DDS

The author has been in private practice and a continuing student for the past 50 years. The first half was spent practicing restorative dentistry, and the second half in a specialty practice limited to endodontics. On the road to predictability, it became apparent there was a definite relationship present between root canal treatment, periodontal status, prosthetics and/or subsequent restorative procedures. Each operator has to decide what steps for a more predictable outcome they are willing to trust another to do. This article is an attempt to share some "secrets of success" and perhaps serve as a checklist for a system that works in the attempt to achieve predictability of endodontic treatments. During the earlier years of the past century, several techniques were devised for the obturation of the canal system after removal of the diseased pulp, or necrotic tissue. Some of the most popular were silver points, lateral condensation of gutta-percha (GP), Sargenti paste and chloropercha. Currently there are seven techniques that utilize gutta-percha as the obturation material of choice:

- 1) Single cone
- 2) Lateral condensation
- 3) Chloropercha technique
- 4) Vertical compaction of warm GP (Schilder, continuous wave, System "B," McSpadden, System "A")
- 5) Carrier-based (Thermafil)
- 6) Injection of thermo-plasticized GP (often referred to as "squinting" using a Calamus or Obtura unit)
- 7) Mechanically assisted compaction (Pac Mac).

In 1967, Dr. Herb Schilder, often referred to as "the father of modern endodontics," introduced the concept of filling the root canals in three dimensions.¹ The Schilder Technique involved a new and different approach for obturation of the canal system and resulted in much controversy.

Evidently, the controversy did create interest from some doctors, because in the mid 1970s new ideas and techniques evolved that became most of what are the currently accepted concepts of modern endodontic principles and techniques. Today, the numerous clinical reports, published research and the rapid advancements in technology have significantly changed the operator's obturation preferences. Ease of communication, along with modern marketing, has become a very important determinant when

making a choice of techniques. More recent studies have discounted some previous obturation materials that were popular, but some form of GP still remains the most acceptable and widely used. The purpose of this article is to share a simple, six-step protocol (System "S") in a straightforward manner, to achieve predictability of endodontic treatment for the benefit of the patient.

There are six important components to the System "S" protocol: 1) Proper shaping with patency 2) Adequate cleaning, disinfection and drying 3) Delivery of pre-warmed GP to apex (Calamus/Obtura) 4) Coronal seal for the rest of the system 5) Respect for the endo-pros relationship 6) Use of the surgical operating microscope (SOM) for the entire endodontic treatment

The author believes that as long as the gutta-percha is introduced to the apical third of the canal system, pre-warmed and pre-softened, the deformation and adaptation to the canal walls is more predictable, resulting in a better seal that is significantly less "sealer-dependent." It has been shown that the pre-warmed techniques (Obtura and Thermafil) produce a better seal than lateral condensation.²

Due to the lack of deformity inherent at room temperature, the techniques utilizing non-softened GP are more "sealer-dependent." The two most popular thermoplastic obturation techniques are the "carrier-based" (e.g., Thermafil) and "direct injection" (e.g., Calamus/Obtura). The pros and cons of each will be discussed, but regardless of the technique used, the "shape" of the prepared canal system is of utmost importance and must be discussed.

Access and shaping the canal system

In the early '70s, Schilder clearly stated the requirements for the proper shape using GP to achieve three-dimensional obturation of the canal system:

- 1) The root canal preparation should develop a continuously tapering cone shape.
- 2) It should have decreasing cross-sectional diameters at every point apically and increasing at each point as the access cavity is approached.
- 3) It should have multiple planes, which introduces the concept of "flow."
- 4) The foramen should not be transported.
- 5) The apical opening should be




Fig. 1. Typical rotaries, one of several popular brands. (Photos/ Provided by John J. Stropko, DDS, unless otherwise noted)




Fig. 2. NaOCl irrigating syringes can be warmed in a beaker on a coffee warmer. Note the anesthetic syringes on a heating pad in the background.

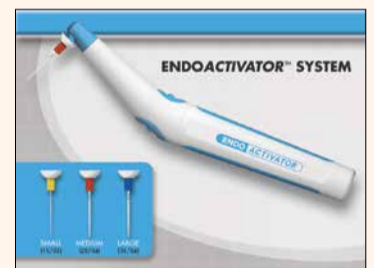

Fig. 3. The Endo Activator is used for the "tsunami effect" for cleaning canals.

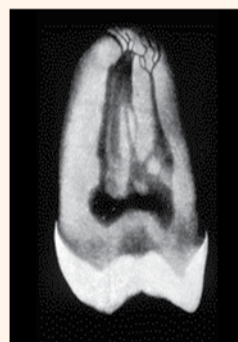

Fig. 4a. The canal system can be very complicated.

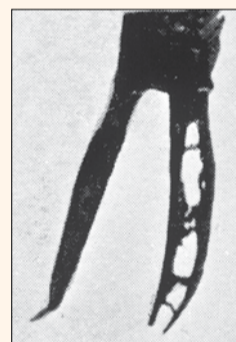

Fig. 4b. The Walter Hess studies with vulcanite clearly demonstrated the complexity of canal systems.

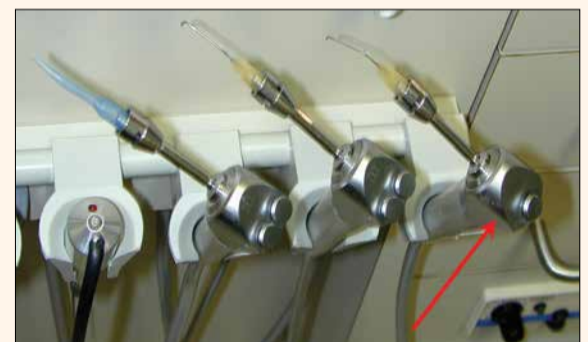

Fig. 5. Set of three Stropko Irrigators with various 27-gauge tips bent for use. Arrow points to the dedicated "air-only," single-button DCI syringe.

kept as small as practical in all cases.

There were several other requirements more clinically definitive. Following are a few of them: After placement of the rubber dam, an appropriate access is made. Unless the access is large enough for adequate vision, appropriate instrumentation may be compromised and canals missed. A perfect example is a maxillary first molar; if the access is made as though there was an MB2, it is amazing how many times an MB2 is found. A general rule of thumb is, if you access for it, you are more likely to find it. A proper access will also facilitate the creation of the continuously tapering shape of the canal, necessary for the warm GP technique.

Occasionally after caries or old restorations are removed, a "pre-endodontic" restoration may be required to control and maintain a sterile environment until the endodontic treatment is complete. This can usually be accomplished using a bonded composite technique.

Shaping should be confined to the anatomy of canal system, following the natural curvatures. Instrumentation beyond the apex is unnecessary and may needlessly enlarge and deform the apical foramen.⁵ Using the Schilder protocol to achieve the desired shape of the canal system was a time-consuming process. It involved the tedious use of pre-curved files and reamers to follow the anatomical curvatures of the canal.

Other requirements that caused some controversy then (and still does), besides the size of the access opening, was the need to keep the apical foramen as small as possible, and to maintain patency throughout the entire process. The majority of more recently published research and clinical studies have confirmed the rationale for an appropriate access and correct shaping.

In the early 1990s, technology brought about the introduction of rotary instruments, relieving the operator of considerable time spent creating an acceptable shape. The ProFile rotary bur (Tulsa Dental) with 0.04 and 0.06 taper, was introduced to the profession. Creating the shape necessary for the successful use of the warm obturation techniques was made easier and faster.

By the beginning of this century, numerous designs gradually evolved utilizing varying tapers, active or passive cutting blades, etc. (Fig. 1). At first, the biggest problem with the rotary files was breakage during use. But modern nickel titanium (NiTi) metallurgy technology has developed more, and more dependable, rotary files. As a result, today the separation of a rotary instrument during use is of virtually little or no concern. It has also been shown that proper shape permits more thorough irrigation and the removal of significantly more debris from the prepared canal system.

Disinfecting irrigation should

be used between each instrument during the entire shaping process and patency continually maintained with a #10 file. Note: The quantity of irritants used is not as important as the frequency of use. The irrigation protocol, instruments, fluids, etc., are in constant evolution and becoming more effective. However, a clean and sterile environment of the canal system prior to obturation is still the objective.

Irrigation for cleaning the canal system

After shaping is completed, final cleaning can be effectively accomplished by the alternative use of:

- 1) Warm 3- to 6-percent NaOCl
- 2) 17 percent aqueous EDTA for approximately 30 seconds (smear layer removal)
- 3) Warm 3- to 6-percent NaOCl (further disinfect and stop action of the EDTA).

The NaOCl can be effectively warmed by placing the irrigating syringes in a beaker of water set on a small coffee warmer (Fig. 2). The canal(s) are completely flooded with the desired solution; an Endo Activator (Dentsply) is appropriately used for the "tsunami effect," then re-irrigated with the same solution for flushing of debris (Fig. 5). The NaOCl is then effectively removed with a capillary tip (Ultradent) attached to a high-speed evacuator. Other

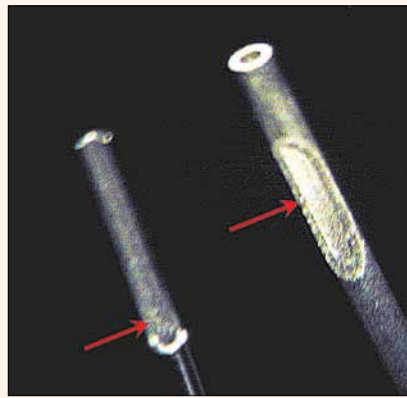


Fig. 6. When drying canals with air, needles must be notched or sidevented (arrows).



Fig. 7. The Chapman-Huffman in-line air regulator and 0-15 psi gauge works well.

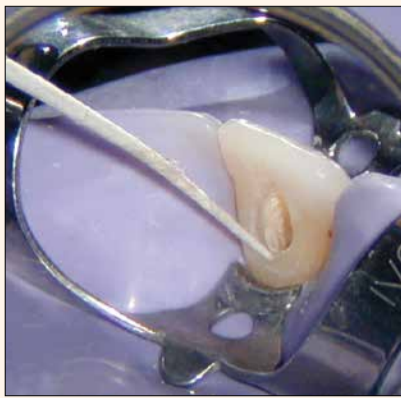

Fig. 8. Fresh absorbent points are used to remove excess sealer until 'blotchy'.



Fig. 9. Only a very thin layer of sealer needs to coat the walls for lubrication. (Photo/Courtesy of Bob Sharp, Sacramento, Calif.)

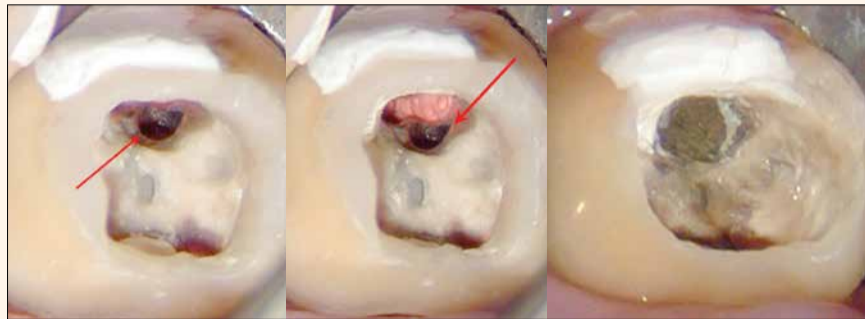


Fig. 10a. A furcal perforation in the distal root of a mandibular first molar.
Fig. 10b. Canal filled just apical to furcal perforation.
Fig. 10c. MTA placed to repair the perforation.

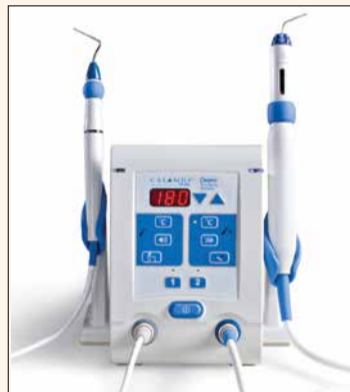

Fig. 11a. The Calamus Dual unit with a thermal handpiece. (Photo/Courtesy of Dentsply Tulsa Dental Specialties).

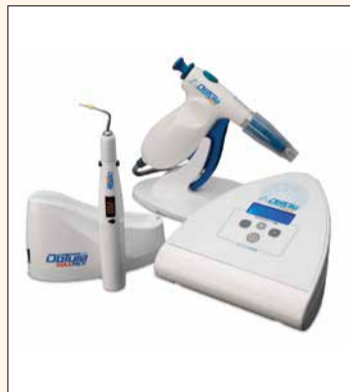

Fig. 11b. An Obtura III Max Pack Dual also has the thermal handpiece.

solutions (hydrogen peroxide, chlorhexidine, 17 percent aqueous EDTA, MTAD, etc.) can also be used alternately, depending on operator preference. Close observation with an SOM will clearly indicate complete cleaning of the canal system when no debris is flushed out during the irrigation process. During the evacuation with the capillary tip, it becomes apparent if there is a joining of the canal systems within the root. For example, if using the SOM as the MB1 canal is being evacuated and it is noted that fluid is simultaneously being drawn from the MB2 canal, there is a good indication that the system

is complicated and does join at some point (Figs. 4a,b). There are occasions, especially in lower molars, where the mesial root canal system unexpectedly joins with the distal root canal system.

On occasion, the maxillary canal system will have the DB or MB canal system connected to the palatal system. These "surprises" are important to be aware of, before obturation of the canal system, especially when using either carriers or injectable GP.

Drying canals with F•I•R•E

The canal(s) are Flooded with 95 percent ethanol (Everclear, available at local liquor store), agitation of the fluids are Initiated with an activator for the tsunami effect, then Re-irrigated with the 95 percent ethanol, and then Evacuated with the capillary tip. The canal(s) are then best dried by using a Stropko Irrigator on a dedicated, air-only syringe (DCI), but if a three-way syringe is used, be sure to ex-

press all water from the line first (Fig. 5). Next, with a 27- or 30-gauge notched or sidevented needle (Monoject), fitted to the tip of the Stropko Irrigator and bent as necessary, to easily dry the canal system (Fig. 6). Important note: It is essential to regulate the air pressure to the air syringe at 1 to 5 psi and use a side-vented or notched needle, to prevent any possibility of inadvertently forcing air through the apical foramen. This is easily achieved with an in-line regulator, the Chapman-Huffman Regulator & Gauge, Part #17-050-00 (Fig. 7).

As dentists, we are accustomed to a "blast" of air while using the usual air/water syringe tip and high air pressure to the A/W syringes. With a properly regulated Stropko Irrigator fitted with an appropriate small gauge needle, only a "kiss" of air is necessary to create the flow necessary for thorough air drying of the canal. On occasion, one has to direct the air to a sensitive area on himself or herself to be sure the air is even flowing. Just watching the evaporation that occurs within the canal, while using the SOM, is enough to convince any operator that there is indeed a flow of air.

There is enough physiologic back pressure of the apical environment (1.5 mm Hg) to prevent movement of the air past the terminus in the correctly shaped canal. In almost 20 years, with many different doctors using the Stropko Irrigator to "air dry" canals, the author has only heard of one unfavorable incident. In that one case, the doctor did not use a side-vented needle and did not regulate the air pressure to the air syringe. To repeat, when the Stropko Irrigator is used with the properly regulated air pressure (1 to 5 psi) and the appropriate 27- to 30-gauge, side-vented/notched needle is used, there is no fear of forcing air into apical tissues.

Sealer application

To the SOM user, the ineffectiveness of drying the canal with a paper point is soon realized. It is also easy to observe how differently the Kerr Pulp Canal Sealer EWT (SybronEndo) acts when the canal is in fact dry, not just blotted. After blotting with a paper point, the sealer tends to act like a drop of oil when placed on the canal wall. But when the surface is dried, using alcohol and air as described above, the sealer readily spreads onto the canal wall, much like a coat of paint. The complete dryness of the canal to the desired working length

is checked with a clean absorbent point that fits to length. This also gives the operator an excellent chance to recheck the working length and dryness of the canal. Any sealer (Kerr EWT, Roth, AH Plus, etc.) can be used as long as the heat of the warm GP does not cause a "flash set." The end 5 mm of a sterile paper point is coated with the sealer of choice and placed into the canal to the working length.

The author uses Kerr Pulp Canal Sealer EWT, mixed per usual directions, but a little "on the thin side." Using short, rapid apical-coronal movements, the walls of the canal are completely coated with sealer. The use of the SOM is a great aid for observing when the coating of the canal wall by the sealer is complete. Then, a sterile absorbent point is used, in the same manner, to remove any excess sealer that may remain.

Depending on the amount of sealer placed at the beginning, more than one absorbent point may be necessary to get the "blotchy appearance" on the final point (Fig. 8). Only a thin coat of sealer is necessary for lubrication, so very little remains on the walls of the canal (Fig. 9). One of the most common mistakes, made at first, is using too much sealer. When this happens, the excess sealer will be extruded back into the chamber, or apically when the warm GP is placed. In some cases, the GP may be prevented from completing the desired "flow" apically. Typically, only one or two points are normally needed once the operator achieves proficiency at applying the correct amount of sealer to begin with. Thermoplastic GP techniques are not sealer-dependent and depend more on the sealer as a lubricant and facilitate the flow of the thermoplastic GP.

Important consideration between using injection or carrier-based obturation. Essentially, there is one very significant difference between the two techniques. The injection technique fills the canal system from the apical to the coronal, whereas the carrier-based techniques fill from coronal to the apical. This is important to take into account, especially in cases in which the operator does not want to fill the canal to the orifice or needs to control the "depth" of the fill. A good example would be in the case of treatment of a perforation repair. Using injection, the "fill" can be accomplished rather easily, and both the sealer and GP can be confined apical to the perforation. MTA can then

be added to the repair in a very controlled manner (Figs. 10a-c). When a post space is required, the GP can be injected to any level in the canal, but it is better to obturate the entire canal first, so unknown anatomy more coronally in the canal won't be missed.

Injection of thermo-plasticized GP with a Calamus or Obtura

After using the Obtura for more than a decade for thermo-plasticized GP obturation, the author switched to the Calamus when it was introduced many years ago. After thousands of canals were obturated using both of them, several advantages were noted when comparing the two units (Table 1).

Both units are available as a single unit, or a dual unit combined with a thermal handpiece for convenience (Figs. 11a,b). The consistent flow of the Calamus unit does make the learning curve quicker and easier to master than the Obtura, because the relatively large muscle action of squeezing the trigger could vary from patient to patient, or day to day. The much smaller muscle action of using a finger to press the collar of the Calamus is significantly less, and the resulting flow of the GP can be pre-set for consistency.

The size of the needle used in the Calamus or Obtura (20 vs. 25 gauge) is generally a matter of preference and can also depend on what the canal wants. It does not make any difference, in the scheme of things, how far apically into the canal the needle is placed, as long as it is non-binding.⁴

For example, a straighter and larger canal will take a larger needle. On some occasions, the 20-gauge needle will not be far enough apical to the orifice of the canal before binding. If the canal preparation is narrower, this is an indication to use the smaller, 25-gauge needle. As long as it is not binding and the canal has the correct shape, the GP will flow to the apex. Note: If the canal is parallel in shape, the canal then becomes an extension of the needle and apical control is severely handicapped. Shape is of the utmost importance, especially in these techniques.

The settings on the Calamus are checked to assure the desired set temperature has been achieved (the author uses 160 C), and the flow rate is set correctly (the author prefers 100 percent). When the unit reaches the set temperature, it will stop blinking. Note: As a safety feature, until the unit has achieved the pre-set parameters, the motorized plunger will not initiate and GP is not ejected. When all is ready, the collar is pressed until the initial GP is extruded and then the collar is released. The slight amount of GP at the tip is removed.

The needle is then placed into the canal apically, just short of binding, and the collar is pressed to reactivate the flow of GP. It is good practice to barely move the tip, in a very slight apical-coronal direction as the GP is flowing. The moment there is a sensa-

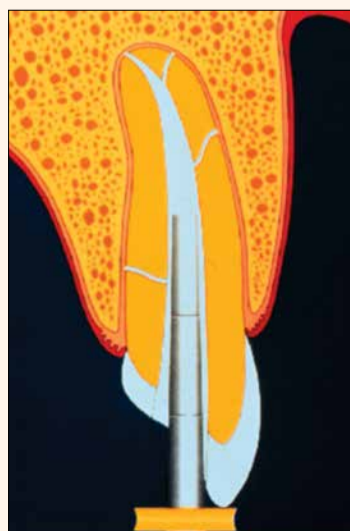


Fig. 12. The plugger is pre-fit, short of binding, to avoid unnecessary contact with the canal walls during deep compaction of the softened GP. (Image/Courtesy of Arnaldo Castellucci, Florence, Italy).

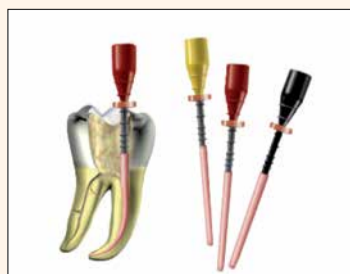


Fig. 13. The GuttaCore carriers are just one of many popular products for carrier-based GP. (Photo/Courtesy of Dentsply Tulsa Dental Specialties).