

DENTAL TRIBUNE

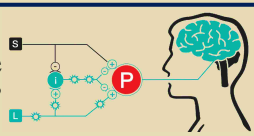
The World's Dental Newspaper • Pakistan Edition

PUBLISHED IN PAKISTAN

www.dental-tribune.com.pk

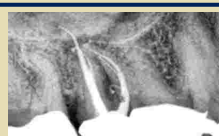
JULY, 2014 - No. 04 Vol.1

Stop hurting your patients! Deliver the "WOW experience" and watch your practice grow



► Page 2

Diagnosis 2014: The things you need to know for successful endodontic treatment



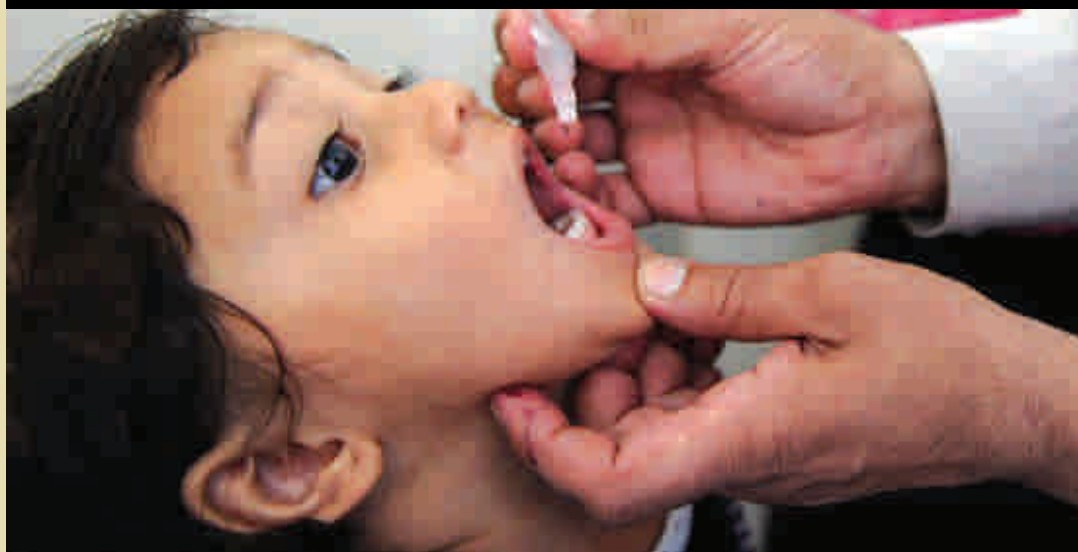► Page 4

Expert symposium on implantology encourages patient centric treatment approach



► Page 8

IDP camps provide unique Polio vaccination opportunity



DT Pakistan Report

The presence of thousands of children from North Waziristan in Pakistan's camps for internally displaced persons (IDPs) offers an unexpected opportunity for anti-polio teams to vaccinate those who could not previously be accessed. Experts say that this is an excellent opportunity and must not be missed. Areas of

N.Waziristan were previously thought inaccessible because of the prevalent law and order situations. Hundreds of Thousands of children were not vaccinated because militants in the affected areas had opposed the vaccination campaigns. This is thought to have contributed to the various polio

Continued from page 11

FDA changes recommendations on lidocaine for teething pain

DT Pakistan Report

Washington: The Food and Drug Administration (FDA) announced that a box warning on prescription products containing viscous lidocaine solution is now required that states that such products should not be used to treat teething pain in children. In response, a U.S. trade association has voiced concerns that such suggestions create confusion among consumers and health care providers. It has urged the FDA to clarify its announcement.

A box warning on a drug label is the FDA's strongest warning. In the current case, the agency required a new box warning for oral viscous lidocaine 2 percent solution because it is not approved to treat teething pain and could cause serious harm in infants. In its safety announcement issued on June 26, the FDA called upon health care professionals not to prescribe or recommend this product for teething pain.

In addition, the agency instructed parents and caregivers to use a chilled teething ring or to rub the child's gums with a finger to relieve the symptoms. The FDA further emphasized that topical pain relievers rubbed on the gums are not necessary. When

Continued from page 11



The President of India to inaugurate FDI 2014

DT Pakistan Report

New Delhi: The upcoming Annual World Dental Congress (AWDC) of the FDI World Dental Federation in New Delhi will see a visit by the highest political figure in India. President Pranab Mukherjee will inaugurate the opening ceremony on Thursday, 11 September, the FDI confirmed last week.

Mukherjee recently accepted an invitation from the Indian Dental Association in Mumbai to join the international event, which is being organised in partnership

including in the Ministry of Finance, which he headed before being elected president. The 78-year-old member of the ruling United Progressive Alliance has also periodically held seats in India's upper and lower houses for over 50 years. He has served as head of state since mid-2012, when he was elected in a landslide win against leftist rival candidate Purno Agitok Sangma.

Mukherjee is the 13th holder of the office of president, which was established after India gained independence from Great Britain in 1947.

with the Geneva-based dental federation. The 102nd edition will be held at the India Expo Centre in Greater Noida in Uttar Pradesh from 11 to 14 September. According to the FDI, it has received significant interest, with more than 10,000 registrations in early July.

The son of a freedom fighter, Mukherjee has held a number of high political positions in his country,

Amalgam recycling starts in Brazil

DT Pakistan Report

Brazil: Together with the Universidade Federal Fluminense, one of the largest universities in Brazil, Dental Recycling International (DRI), a dental waste management company, has initiated a pilot project that aims to promote environmentally friendly disposal of dental amalgam in Brazil.

DRI announced that it will be installing amalgam separators at the university's Faculty of Dentistry and providing a number of chairside amalgam recycling kits.

Continued from page 11

Stop hurting your patients! Deliver the “WOW experience” and watch your practice grow

By Dr. Steven G. Goldberg, USA

Every dentist is looking to grow his or her practice, and we are all looking to bring in as many new patients as we can. Numerous excellent articles have been written by many highly successful clinicians and marketing gurus on a myriad of ways to grow your practice.

According to Dr. Joe Blaes, editor of Dental Economics, speaking of the DentalVibe Injection Comfort System in his column “Pearls for your practice” (January 2011), “The best WOW experience that we can give in dental practices is to not hurt our patients.

You will get more referrals from patients if you have a pain-free practice than any other marketing tool you can use. [...] DentalVibe’s synchronized percussive vibration provides an ideal way to administer anesthetic injections, anywhere in the mouth, without discomfort. DentalVibe is cordless, portable, and easily affordable for every office.”

The fact is that as dentists we are so focused on our technical skills while we are performing our craft that we lose sight of one of the most important issues on the business side of dentistry: the patients’ perspective. They are desperately afraid that we are going to hurt them. Many people are so afraid of pain that they avoid going to the dentist altogether. According to worlddental.org, studies by the Dental Fears Research Clinic in Seattle, Washington, report that upwards of 40 million Americans avoid going to the dentist because of this fear. This is quite alarming when you consider the negative health effects directly related to poor oral health.

Consider the following scenario. You spend half an hour with a new patient, treating tooth 14 with an MOD composite bonded filling. You carefully excavate the decay, skilfully prepare the tooth with perfect cavosurface margins, etch, prime, place adhesive and composite, and cure for the appropriate period. You spend a great deal of time creating a beautifully artistic representation of occlusal anatomy, and even place secondary grooves in the marginal ridges. Then you polish like you have never polished before. You are proud of the artistic piece that you have created and you have provided a tremendous service to your patient.

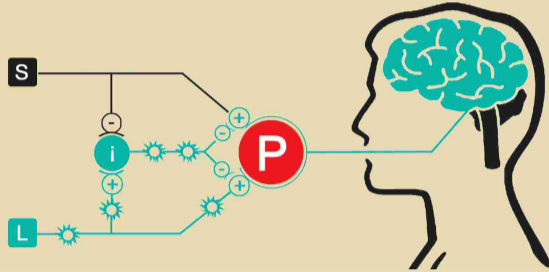
However, when your patient goes home and reports back to his or her family and friends about his or her dental experience, is the patient going to tell them how wonderful your secondary grooves are? More likely, what the patient will say is whether you hurt him or her.

What patients remember is the very beginning of the appointment, the dreaded dental injection. If you anesthetise your patients painlessly, you will be considered a painless dentist. After all, dentistry does not hurt. A filling does not hurt, an extraction does not hurt, and even a root canal does not hurt, because once your patient is anesthetised,

you are practising painless dentistry. But if you hurt your patients during the injection process, you are no longer considered a painless dentist.

With the use of the DentalVibe Injection Comfort System now in its second generation, as an adjunct to the injection process, you no longer have to hurt your patients to help them. This patented, award-winning device utilises revolutionary VibraPulse technology to send soothing, pulsed, percussive vibrations deep

into the oral mucosa during the delivery of an injection. This stimulation is perceived by the submucosal sensory receptors, sending a message to the brain,



effectively closing the neural pain “gate”, allowing for the comfortable administration of intra-oral injections. Adults and children have reported painless injections and dentists report less stress during the injection process. The device is cordless, portable, non-threatening, easily affordable, has been receiving rave reviews all around the world from key opinion leaders in dentistry, and has been featured on all of the TV news networks.

DentalVibe is based on the Gate Control Theory of Pain, proposed by Drs Ronald Melzack and Patrick Wall of McGill University, and published in the Science journal in 1965. According to this theory, there is a gating mechanism located in the dorsal horn of the spinal cord. This gating mechanism either permits or prevents the sensation of pain from travelling up the spinothalamic tract to the brain. When the DentalVibe is used simultaneously during the administration of an injection, the pulsed vibratory impulses generated by the device travel along thick myelinated A beta nerve fibres 37.5 times faster to the brain than the sensation of pain from the injection, which travels along thin unmyelinated C nerve fibres. As the vibration sensation reaches the brain first, a signal is sent to a synapse in the spinal cord, activating inhibitory interneurons that prevent the action of projection neurons, thereby shutting a gate, blocking the pain from the injection.

This is one dental product that holds universal appeal to consumers. Nobody wants to feel pain and these days patients are no longer willing to accept it, as they may have in years gone by. Therefore, Bing Innovations, the developer of DentalVibe, has launched a multimillion-dollar patient-awareness campaign, including TV commercials, print advertisements, cinema advertising, Internet banner advertisements and a web-based dentist locator. This tremendous effort is effectively educating tens of millions of consumers on the wonderful benefits of DentalVibe for virtually painless injections and driving patients to those dentists who use it.

Give your patients the “WOW experience” with DentalVibe, so that both you and your patient’s can enjoy our wonderful profession a little bit more.

DENTAL TRIBUNE

The World's Dental Newspaper • Pakistan Edition

Publisher/CEO

Syed Hashim A. Hasan
hashim.hasan@dental-tribune.com.pk

Editor Clinical Research:

Dr. Inayatullah Padhiar

Editors Research & Public Health

Prof. Dr. Ayyaz Ali Khan

Editorial Assistance

Dr. Ahmed Ali

Editor - Online

Haseeb Uddin

Graphics Designer

Sh. M. Sadiq Ali

Dental Tribune Pakistan

3rd floor, Mahmood Centre, BC-11, Block-9
Clifton, Karachi, Pakistan.

Tel.: +92 21 35378440-2 | Fax: +92 21 35836940

www.dental-tribune.com.pk info@dental-tribune.com.pk

Dental Tribune Pakistan cannot assume responsibility for the validity of product claims or for typographical errors. The publisher also does not assume responsibility for product names or statements made by advertisers. Opinions expressed by authors are their own and may not reflect of Dental Tribune Pakistan.

International Imprint

Group Editor

Daniel Zimmermann

newsroom@dental-tribune.com

Tel.: +49 341 48 474 107

Clinical Editor

Magda Wojtkiewicz

Online Editors

Yvonne Bachmann

Claudia Duschek

Sabrina Raaff

Hans Motschmann

Copy Editors

Publisher/President/CEO

Torsten Oemus

Chief Financial Officer

Dan Wunderlich

Business Development Manager

Claudia Salwiczek

Events Manager

Lars Hoffmann

Media Sales Managers

Matthias Diessner

(Key Accounts)

Melissa Brown

(International)

Peter Witteczek

(Asia Pacific)

Maria Kaiser

(North America)

Weridiana Mageswki

(Latin America)

Hélène Carpentier

(Europe)

Marketing & Sales Services

Nadine Dehmel

Nicole Andrä

Accounting

Karen Hamatschek

Anja Maywald

Manuela Hunger

Executive Producer

Gernot Meyer

Dental Tribune International

Holbeinstr. 29, 04229 Leipzig, Germany

Tel.: +49 341 48 474 302 | Fax: +49 341 48 474 173

info@dental-tribune.com | www.dental-tribune.com

Regional Offices

Asia Pacific

Dental Tribune Asia Pacific Limited

Room A, 20/F, Harvard Commercial Building,

105-111 Thomson Road, Wanchai, Hong Kong

Tel.: +852 3113 6177 | Fax: +8523113 6199

The Americas

Tribune America, LLC

116 West 23rd Street, Ste. 500, New York, N.Y. 10011, USA

Tel.: +1 212 244 7181 | Fax: +1 212 244 7185

INTRODUCING



**DIGITAL
DENTISTRY
SHOW**

AT
INTERNATIONAL EXPODENTAL MILAN

16 | 17 | 18 OCTOBER 2014

EXHIBITION

LIVE PRODUCT PRESENTATIONS

HANDS-ON WORKSHOPS

PRINTED REFERENCE GUIDE

COFFEE WITH THE EXPERTS

www.DigitalDentistryShow.com

Organized by Dental Tribune International in cooperation with Promunidi.
Dental Tribune International | Holbeinstraße 29 | 04229 Leipzig | Germany
T +49 341 48474 134 | F +49 341 48474 173
E info@digitaldentistryshow.com | W www.DigitalDentistryShow.com

dti Dental
Tribune
International

PROMUNIDI

Diagnosis 2014: The things you need to know for successful endodontic treatment

By Dr. Thomas Jovicich

ce credit

roots



This article qualifies for CE credit. To take the CE quiz, log on to www.dtstudyclub.com. Click on 'CE articles' and search for this edition of the magazine. If you are not registered with the site, you will be asked to do so before taking the quiz. You may also access the quiz by using the QR code below.

The goal of endodontic treatment is for the clinician to achieve an effective cleaning and debridement of the root canal system, including the smear layer and all of its mechanical and bacterial byproducts. Traditionally this is accomplished via mechanical instrumentation in conjunction with chemical irrigants together and actively engaged to completely debride and sterilize the root canal system.

The root canal system is a vast and complex three-dimensional structure comprising deltas and lateral canals, along with multiple branches off of the main root canal system (Figs. 1, 2, 9).

Before the clinician can begin to treat a patient in need of endodontic treatment, he or she first must come up with the proper diagnosis. Once the diagnosis has been made, it then must be integrated with the treatment plan. Taking that treatment plan and presenting it to the patient creates the next challenge: creating value for the patient. One of my most difficult challenges as a working endodontist is creating value for the patient in my chair who has no pain and is here because his or her dentist "saw something" on the radiograph. Pain is the greatest patient motivator we have in dentistry today.

The focus of this article is on diagnosis, and it is my goal to provide the reader with a good grasp of diagnosis as it relates to endodontic treatment.

Endodontics is all about vision. You have it. I have it. The dentist down the street has it. Doing root canals today is all about having the confidence to make the proper diagnosis. This is achieved through repetition. The more you do it, the easier it becomes. In addition, you need consistency that is achieved through positive reinforcement. Once you believe you can do it and the results support that, you then develop competence. This allows you to retain the skills you have worked hard to hone. The most important trait to utilize in clinical practice today is common sense. This is what separates the true artisans from tooth mechanics. The key component to endodontic treatment is diagnosis. It is based upon using a multifocal approach that

involves:

- patient report,
- medical and dental history,
- clinical signs and symptoms,
- diagnostic testing,
- radiographic findings,
- restorability.

Taking and collating all of this information will allow the clinician to arrive at a proper and thorough diagnosis. Let's break these down and delve into what needs to be done.

Patient report

This is the first opportunity to create a road map to a diagnosis. The goal is to ascertain the nature of the problem. Step one: Ask the patient where the pain is located. Once you've localized the area, it's imperative to ask a few more questions. The next question should involve determining pulpal vitality through the use of an ice pencil. Other times the patient will volunteer this information with a statement like: "The minute I put anything cold on this tooth, the pain is present and quite intense." This information suggests that the pain may be pulpal in origin. Because the trigeminal nerve is involved in endodontics, it is important to determine any type of radiating pain. It is not uncommon for maxillary pain to radiate from the mandibular area and vice versa. A final area of feedback I want from patients relates to biting and chewing. The patient's report is the foundation upon which we begin the diagnostic procedure. Asking probing and leading questions in "plain English" will allow the patient to give you critical diagnostic information.

Medical and dental history

Once you have the patient's report, probing his or her medical and dental history gives clarity to the background. What are the patient's medical allergies? What recent dental treatment has the patient had? Was there any mention of restorations placed that were near or at the pulp? Many times a patient will mention having heard the dentist tell his assistant that they were close to the pulp during the excavation of decay. Asking detailed questions enables you to enrich the diagnostic canvas as to why the patient is sitting in your chair.

Clinical signs and symptoms

By this point, you have listened to the patient's chief complaint and you have taken radiographs or digital

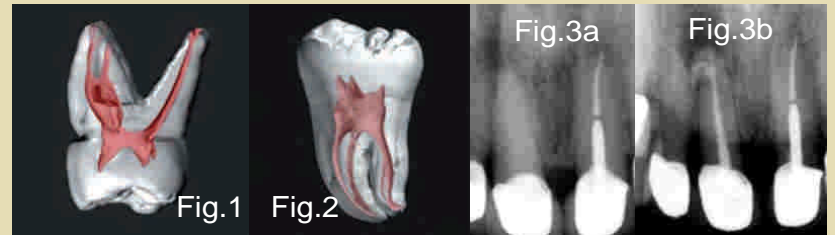


Fig.1 Maxillary molar. Note the complex anatomy and multiple portals of exit. (Photos/Provided by Thomas Jovicich, MS, DMD)

Fig.2 Mandibular molar. Note the curvature along with the multiple portals of exit.

Fig.3a Maxillary central incisor with a periapical lesion. This is a markedly calcified canal.

Fig.3b Maxillary central incisor with completed root canal using Sybron TFA rotary nickel titanium instruments, Sealapex sealer. Note the multiple portals of exit in the apical region.

images. It's time to "test" the patient. The "bite test" involves having the patient attempt to reproduce the pain through biting on an orangewood stick or a cotton swab or a wet cotton roll. If there is pain to bite, you are dealing with some degree of pulpal inflammation with secondary involvement of the periodontal ligament. Once you have this information, the next step is to look at your digital imaging and analyze the relationship of the periodontal ligament (pdl) to the root. Is there a thickening? Is there a widening?

If the patient reports pain to bite upon release, this infers that there may be some structural root damage (Figs. 5a & b). At that point it is essential to look at the occlusal surface of the tooth, account for the type and age of any restoration and inquire if any recent dentistry has been done. In addition, it is imperative to probe the suspected tooth.

Probing from buccal to lingual with at least four measurements per side is the best barometer to assess periodontal health. If you find an isolated defect in any single probing, you are most likely dealing with a fracture of the root. Endodontic treatment to confirm or rule out a fracture is indicated in these clinical situations.

Diagnostic testing

The percussion test involves using the blunt end of a mouth mirror or periodontal probe to assess for periodontal inflammation. It is imperative that the clinician gets a frame of reference. This is accomplished by testing the same tooth on the opposite side of the arch. In addition, it is prudent to test the suspected tooth as well as the teeth on either side. Testing should involve both the occlusal and facial surfaces.

Thermal tests utilizing hot or cold are the definitive modality to assess pulpal vitality. There are a myriad of ways to test with cold, including CO₂ systems, refrigerant sprays and ice

cubes (pellets). I believe ice pellets are the best way to test for cold symptoms. In our practice, we use anesthetic carpules that are filled up with water and frozen.

This method is cheap, efficient and plentiful. The goal is to reproduce the patient's symptoms. Many patients who report pulpal hyperemia have managed this symptom by utilizing the opposite side of their mouth. Temperature symptoms are a major motivator for patients to seek dental care.

Testing with ice involves establishing a baseline to cold. Typically, I chose to test the same tooth on the opposite side or the maxillary central incisor. I ask patients to tell me when they feel an "electrical shock or jolt" to the tooth. As soon as they do that, I remove the ice from the tooth. This is easily accomplished on the buccal surface of the tooth at the margin of the gingiva. When porcelain restorations are present, I strive to put the ice right at the margin on or above any metal margins.

Sometimes it is necessary to apply the ice on the lingual aspect of the tooth. As unresponsive as porcelain restorations can be, the clinician needs to be aware that pulp testing gold restorations can have the opposite effect. This is because of the metallurgical properties of gold. It is an amazing conductor of temperature. Always forewarn the patient when testing gold-restored teeth.

Ask the patient if the cold on the tooth reproduced his or her pain. Also, ask if the pain lingered after you removed the ice from the test site. If the pain it is lingering, it is a sign of irreversible pulpitis.

In some cases the pain can and does radiate along the pathway of the trigeminal nerve. Sometimes, especially in the maxilla, referred pain can be related to sinus issues, such as sinusitis, allergic rhinitis and rhinovirus.

If the patient does not respond to

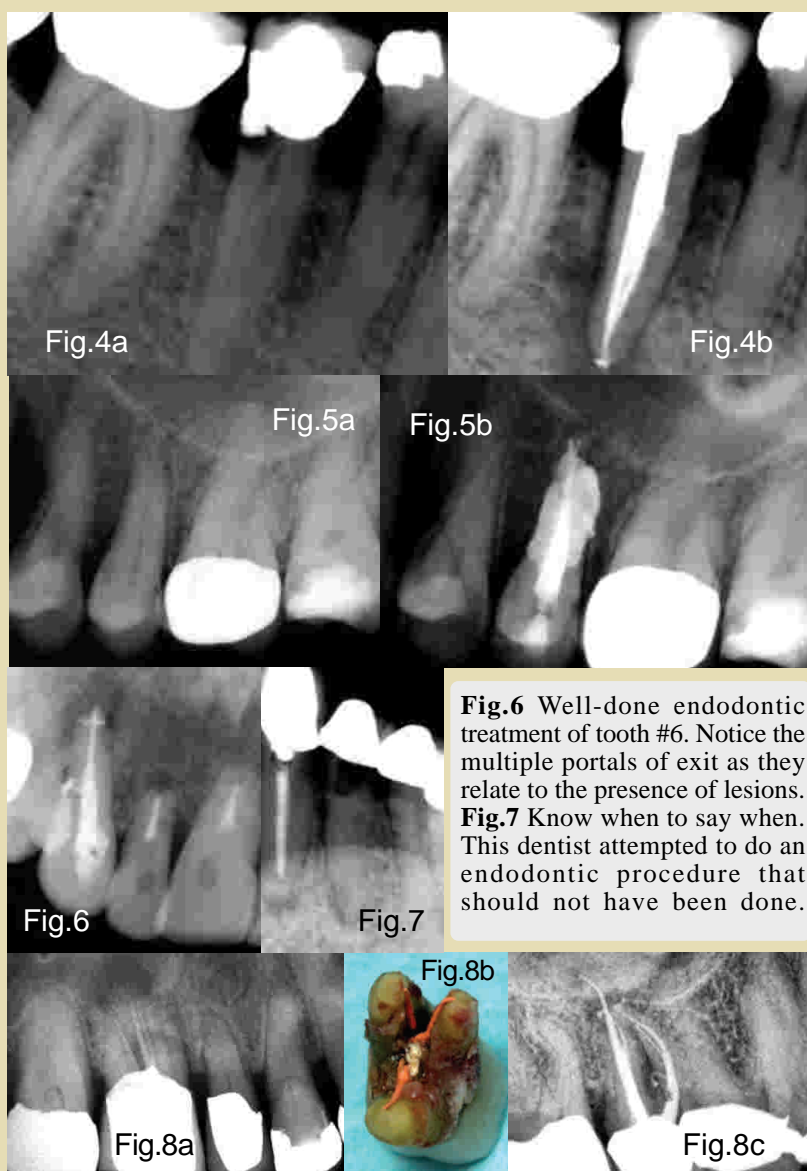


Fig.4a The presence of caries under the margin of a restoration. The caries extend to the pulp and will need endodontic treatment. **Fig.4b** The endodontic treatment is completed. In this case, the patient was lost to the practice for three years and came back when his face was swollen because of incomplete treatment.

Fig.5a Cracked tooth syndrome. Pre-treatment radiograph. **Fig.5b** What can happen in a cracked tooth when you obturate with warm, vertical condensation of gutta-percha.

Fig.6 Well-done endodontic treatment of tooth #6. Notice the multiple portals of exit as they relate to the presence of lesions. **Fig.7** Know when to say when. This dentist attempted to do an endodontic procedure that should not have been done.

Its meaning has evolved as technology has become the backbone of modern dentistry. Prior to the incorporation of implant dentistry, restorability had a very different meaning. Dentists were much more motivated to save teeth. Options and creativity were necessary for clinical success, both in endodontics as well as in restorative dentistry.

Technology has taken away one form of resourcefulness and replaced it with the promise of a panacea. It has become far too easy for general dentists to recommend removal of a tooth to a patient with the promise that an implant will save the day.

‘In modern endodontics, as technology advances and we bring on file systems that shape more efficiently and safely—and we develop a greater understanding of the role of irrigation in endodontics—we can offer higher success rates than at any time in history.’

Historically speaking, the diagnosis of a tooth being non-restorable came after a myriad of attempts to save the tooth. Every aspect of dentistry came into play. Periodontists did osseous surgery and root amputations. Endodontists performed conventional endodontics and, if necessary, surgical intervention to do everything possible to save the tooth. Decisions involving the long-term prognosis of the tooth were relevant. Decisions about the type of restoration were discussed. Decisions about the osseous health of the roots and surrounding bone structures were relevant.

The goal of every specialist is to be an extension of the general dentist’s practice. To that end, deciding whether a tooth was restorable or not was, at a minimum, a conversation to be had between the specialist and the general dentist.

Leap forward to the new millennium, and dentists no longer fight to save teeth. Dentists realize the financial windfall that implants offer their practices. Dentists can attend a myriad of continuing education courses over a weekend and on Monday become nascent

implantologists. This fact makes diagnosis and saving a tooth the most important facet of restorative dentistry moving forward.

Treatment planning and restorability are integral to success both for the patient and the dentist. A patient in pain presents a unique opportunity for the dentist. Many questions need to be asked and answered. Among them: What can the dentist do to manage the pain? What is the cause of the pain? How long has the patient been in pain? Once the initial triage phase is complete, other factors must be addressed. These include: Is the tooth restorable? If endodontic treatment is indicated, what further treatment will be needed? Is there a need for periodontal intervention? If so, what type of treatment is it? Osseous surgery? Does the tooth need crownlengthening surgery? How will these procedures affect the adjacent teeth?

The above paragraph speaks volumes as to the complexities of treatment planning in dentistry today. Every day in offices around the world, a patient visits his or her dentist in pain. How the dentist responds to this will go a long way in determining the patient’s dental well-being. A well rounded practice with high moral fiber will enable the dentist and patient to work synergistically to develop a realistic treatment plan.

The last essential ingredient to success is that the dentist knows “when to say when” (Fig. 7). As a specialist and lecturer, I believe that if a general dentist does roughly 80 per cent of the endodontic cases that walk in the door of his practice and refers out the remaining 20 per cent, he or she will have a very busy endodontic practice. In the past five years, especially since the decline in the economy and busyness of practices, more than 50 per cent of my practice consists of retreatment. The general dentist should have never attempted more than half of those cases. I can only speculate how much more there would be if dentists didn’t have implants to fall back upon.

Implants vs. endodontic treatment

The next aspect of the diagnostic conundrum is the increasing role implants play in treatment planning. When I first began practicing endodontics in 1988, implants were in their nascent stages. If a patient had a root canal and continued to experience pain or discomfort, both the dentist and the endodontist had a myriad of choices, from retreatment to surgical correction. In 2013, the knee-jerk reaction to placing implants has never been greater. More and more general dentists go to weekend “seminars/courses,” and on Monday morning they are placing implants. Much of this is based on the financially lucrative aspect of

Continued from page 11

Fig.8a Initial digital image with a patient whose chief complaint was mild pain to bite and chew.

Fig.8b Digital photo of the tooth after I extracted it, showing a gross negligence. The tooth was perforated through the furcation, and gutta-percha was placed in what the dentist thought was the root canal system.

Fig.9 The complexities of maxillary molar endodontics and multiple portals of exit. Of note, I was never able to shape the MB2 canal.

any thermal tests, both hot and cold, it is a sign that the pulp is necrotic, dying or infected. In this instance, studying the digital imaging may aid the diagnosis. One caveat: It is possible to have a necrotic pulp without being able to quantify it via digital images. In many incipient pathology issues, it takes approximately 90 to 120 days for breakdown to manifest itself on imaging. Today’s cone-beam imaging technology can shorten that process to 30 days. It is not uncommon to have a patient in the chair with symptoms that you cannot quantify radiographically.

Radiographic findings

Radiographic findings (Figs. 8a & b) are the road map for endodontics. Thorough study and evaluation of imaging allows the clinician to determine a multitude of facts about the tooth in question. What does the image reveal? Can you see if there is a widening of the pdl? If there is a widening of the pdl, it is essential to have the patient bite down on a bite stick.

Once he or she does that, you must ask if the pain, if present, is worse upon bite or upon release of bite. The latter is highly correlated with root

fracture. Once that is confirmed, the next step is to prepare the patient for a root canal. The dentist must convincingly explain the procedure’s value as well as caution the patient about the possibility of losing the tooth due to the fracture extending apical from the cemento-enamel junction (CEJ). Is there a lesion (Figs. 3a & b) present? This information allows me to frame my diagnostic questions to the patient. These include: Is the tooth sensitive to cold? I know from the lesion that the answer to that should be no. If, however, the answer is yes, it automatically triggers my mind to look for another tooth.

Generally, speaking teeth with lesions of endodontic origin (LEOs) test non-vital to thermal or electric pulp testing. In sequencing, I first ask for the patient’s report, followed by radiographic findings, which I then augment with clinical testing to tie it all together and arrive at a diagnosis. Lastly, are caries present? The location of caries is a determining factor as to whether a root canal is needed (Figs. 4a & b).

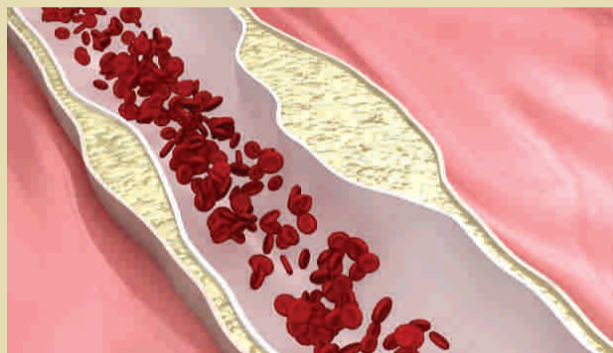
Restorability

Restorability is an issue that has been a hot topic in dentistry for years.

Periodontal therapy may improve heart health in high-risk populations

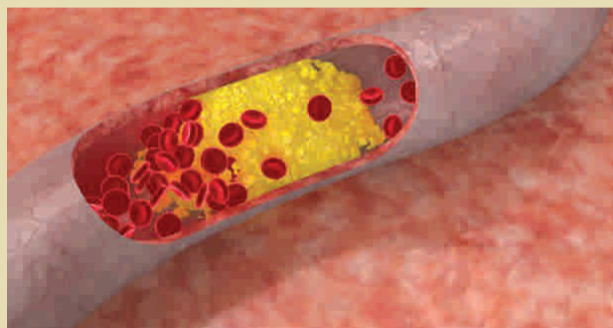
Sydney, Australia: The findings of a new study indicate that, in addition to treating periodontal disease, periodontal therapy could have a considerable systemic impact. Researchers have found that a single session of non-surgical treatment for periodontal disease significantly reduced the thickness of artery walls, a risk factor for heart disease, in patients.

The study was conducted at various research institutions throughout Australia and focused on Aboriginal Australians, a high-risk group for both periodontal disease and



cardiovascular disease. In order to assess the effect of periodontal treatment on cardiovascular health, 273 Aboriginal Australians aged 18 and over with periodontitis were recruited. Half of the participants received full-mouth periodontal scaling during a single visit while the controls received no treatment.

After a period of 12 months, the researchers measured changes in carotid intima-media thickness and observed a significant decline in thickening of artery walls in the treatment group but not in the control group. "The effect is comparable to a 30 per cent fall in low-density lipoprotein cholesterol,



commonly referred to as bad cholesterol, which is associated with a decreased risk of heart disease," said study co-author Dr Michael Skilton from the University of Sydney. "It is also equivalent to the effects of reversing four years of aging, 8 kg/m² lower body mass index, or 25 mm Hg lower systolic blood pressure."

However, the researchers found no effect of periodontal therapy on arterial stiffness, another indicator of atherosclerotic vascular disease. There were no significant differences between the groups in pulse wave velocity at three months or 12 months, according to the study.

The findings may have important implications for the treatment of high-risk populations, such as Indigenous Australians. According to the researchers, periodontal disease is twice as common in Aboriginal Australians as in the rest of the population. An estimated 90 per cent of Aboriginal adults suffer from periodontal disease.

The study, titled "Effect of periodontal therapy on arterial structure and function among Aboriginal Australians", was published online on 23 June in the Hypertension journal ahead of print.

Henry Schein acquires Sirona Dental's French distribution business



Melville, N.Y., USA: Henry Schein has acquired Sirona Direct, the French dental distribution business of Sirona Dental Systems. In addition to its acquisition of Sirona Direct, Henry Schein has entered into an exclusive distribution agreement with Sirona Dental Systems for the promotion and distribution of Sirona's full line of dental equipment, including the CEREC CAD/CAM system, to practitioners in most of France, including the Paris region.

With sales of approximately \$14 million, Sirona Direct is the exclusive distributor of dental equipment for Sirona Dental Systems in Paris and Normandy.

Over the past several years, Henry Schein has acquired other businesses in France with exclusive regional distribution agreements for products manufactured by Sirona Dental Systems. These acquisitions, coupled with the acquisition and distribution agreements announced now, establish Henry Schein as Sirona Dental Systems' exclusive distributor to practitioners across most of France.


"We are pleased to exclusively represent Sirona's high-quality, innovative products across the vast majority of France," said Vincent Junod, vice president of Henry Schein European Dental Group, western region, and managing director of Henry Schein France. "France is an important and growing dental market, and Henry Schein is committed to providing the French dental community with a comprehensive offering to meet all of its practice needs. Sirona's innovative products are an important part of our ConnectDental platform, which is designed to bring the latest digital dental solutions to the practitioners we serve in this rapidly changing dental marketplace."

Continued from page 11

Dental Tribune Pakistan hosts iftar dinner

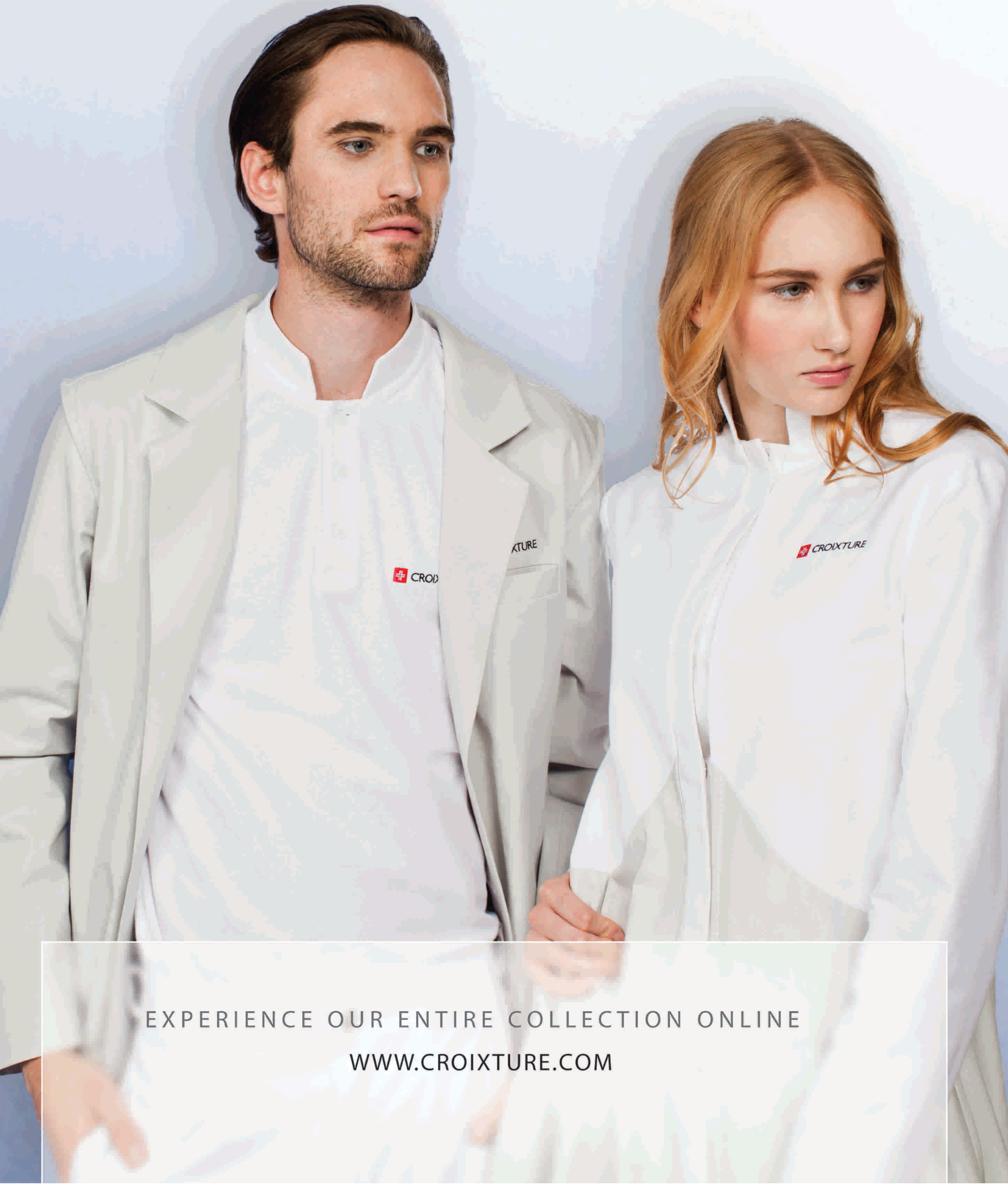Karachi: Dental Tribune recently hosted an Iftar dinner for the dental and allied profession at the Pearl Continental Hotel Karachi. The dinner was attended by Pakistan Dental Association President, office bearers of the association, senior dental surgeons and members of the Dental Trade and Manufacturers Association.





CROIXTURE

PROFESSIONAL MEDICAL COUTURE



EXPERIENCE OUR ENTIRE COLLECTION ONLINE

WWW.CROIXTURE.COM

Expert symposium on implantology encourages patient centric treatment approach

DT Pakistan Report

Karachi-Expert Symposium on Implantology was organized and conducted at Royal Rodale Club, Karachi, which attracted participation from all leading colleges. The Key Clinical Speakers for the event were Prof. Dr. Navid Rashid, Dr. Yawar Abidi, Dr. Sameer Quraeshi and Dr. Irfan Qureshi. The Gold Sponsors of the event were Henry Schein and Chughtai Dental

that implants involves 4 eyes and 4 hands, which means having a very good assistant is mandatory. Angulations is important for the success of implants and patients history is a must as the dentist must know if the patient is suffering from any disease like diabetes, osteoporosis or some other illness which may affect the bone absorption.

Dr. Syed Yawar Ali Abidi; a Fellow

Prosthetics actually determines the success of a clinical implant. He said that most clinicians err in the prosthetic element, and it is because of this that implant failures are seen.

Dr. Irfan Qureshi, MSc in Prosthodontics from King's College; Diplomat of the RCS and ICOI, currently the Head, Department of Prosthetics at SSDC, well-known both nationally and internationally for

NASDAQ 100® Index, Henry Schein employs nearly 17,000 Team Schein Members and serves more than 800,000 customers.

The Company has entered Pakistan Market and taken it by storm with the introduction of products and solutions. The Company offers a comprehensive selection of products and services, including value-added solutions for operating efficient practices and



Supply.

The Guests of Honours for the event were Dr. Asif Niaz Arain, Dr. Anwar Saeed and Dr. Mahmood Shah for their extraordinary performance at the APDF elections.

The proceedings started with the recitation from the holy Quran followed by Prof. Dr. Navid Rashid a well-known Oral Surgeon, President PDA Karachi Chapter and Principal of Liaquat College of Medicine and Dentistry was the first speaker of the evening. Dr. Navid highlighted the importance of anticipation as this helps minimal complications since one has planned the case well before the treatment is done. He said that there have been various advancements in the field of Clinical Implantology, and now with the availability of Bones and Membranes - the chances of failure have reduced considerably.

Addressing a full house, Dr. Navid Rashid, stressed the need of getting patient's consent about the procedure in writing so as to avoid legal issues later. Prof. Navid's presentation on complications in Implantology was an eye opener for the audience focusing issues which are seldom talked about.

Sharing his experiences he said that with the advent of 3D technology, dentists stand to gain a lot more which will eventually benefit the patients. He said that ideal safety margin of 2mm is a must and always remember

and an Associate Professor and Head, Department of Operative Dentistry DIKIOHS - DOW University, director for MDS and Supervisor of the FCPS programme. Dr. Yawar during the course of his presentation explained how it is important to treat each patient with an assigned treatment protocol. He gave a comprehensive clinical presentation comparing and differentiating implants and endodontics. Dr. Yawar Abidi in his presentation stressed the need of mentorship and said that the focus of our treatment should be patient centered and self-centered. Citing his experience he said that he has seen complications in 34% of the patients after 5 years, so implant complications are not rare and 95% implants are just serving for 5 years. Based on his experiences he feels that Endo should be the treatment of choice and implants should be the last option. Dr. Yawar also pointed towards the high incidence of peri-implantitis. He said that this is a problem of growing concern, and proper implant placement protocols must be followed to ensure that such problems don't occur.

Dr. Sameer Quraeshi, Masters in Clinical Science from the University of Manchester and an Asst. Professor Department of Prosthetics at FJDC, is a renowned prosthodontist and consultant implantologist. Dr. Sameer laid special emphasis on how Implant

his sound understanding of the subject. Dr. Irfan gave a comprehensive presentation on case selection, insertion protocols and implant prosthetics. He said that Success or failure of implants depends on the health of the person receiving it, drugs which impact the chances of osseointegration and the health of the tissues in the mouth. The amount of stress that will be put on the implant and fixture during normal function is also evaluated. Planning the position and number of implants is key to the long-term health of the prosthetic since biomechanical forces created during chewing can be significant. The position of implants is determined by the position and angle of adjacent teeth, lab simulations or by using computed tomography with CAD/CAM simulations and surgical guides called stents. The prerequisites to long-term success of osseointegrated dental implants are healthy bone and gingiva.

The programme's gold sponsor was Henry Schein represented in Pakistan by Chughtai Dental Supplies. Henry Schein, Inc. is the world's largest provider of health care products and services to office-based dental, animal health and medical practitioners. The Company also serves dental laboratories, government and institutional health care clinics, and other alternate care sites. A Fortune 500® Company and a member of the

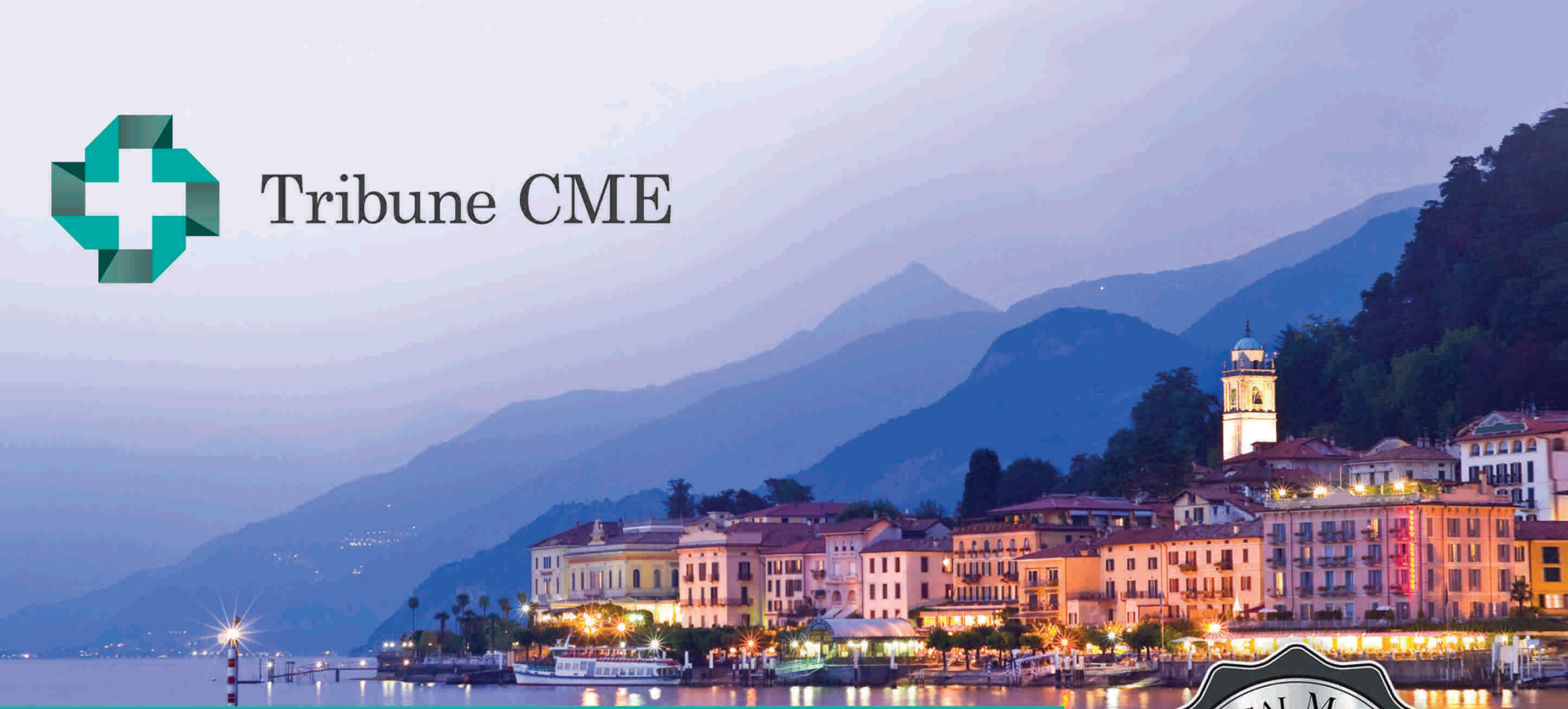delivering high-quality care. Henry Schein operates through a centralized and automated distribution network, with a selection of more than 96,000 branded products and Henry Schein private-brand products in stock, as well as more than 110,000 additional products available as special-order items. The Company also offers its customers exclusive, innovative technology solutions, including practice management software and e-commerce solutions, as well as a broad range of financial services.

The programme offered 2 credit hours to all the registered participants courtesy ICOI and the symposium ensured that the audience take back latest advancements in clinical Implantology. Speaking to Dental News, Dr. Fahmed Patel one of the leading Practitioners of Pakistan said, 'I would like to congratulate the entire team of Dental News for such a well-organized event. I have never seen a program so well coordinated and planned.'

The program saw virality on the social media, both Facebook and Twitter. Participants were encouraged to engage using #DNES14. Dental News has received numerous emails to conduct more programs focusing on other specialties; 'I want Dental News to conduct programs on all specialties especially endodontics', said Dr. Muhammad Ali who is an MCPS Trainee at FJDC.



Tribune CME



6 Months Clinical Masters Program in **Advanced Implant Aesthetics**

17 July 2014 to 22 November 2014, a total of 12 days of intensive live training
with the Masters in **Como (IT), Barcelona (ES), Munich (DE)**



Live surgery and **hands-on** with the masters in their own institutes plus online mentoring and on-demand learning at your own pace and location.

Learn from the Masters of Advanced Implant Aesthetics:



Dr. Tiziano Testori



Dr. Fabio Scutellà



Dr. Matteo Invernizzi



Dr. Xavier Vela



Dr. Xavier Rodríguez



Dr. Víctor Méndez



Mr. Javier Pérez



Dr. Markus Hürzeler

Registration information:

17 July 2014 to 22 November 2014

a total of 12 days in **Como (IT), Barcelona (ES), Munich (DE)**

Details on www.TribuneCME.com/618

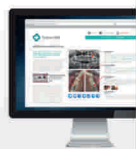Curriculum fee: € 11,900

contact us at tel.: +92 302 820 8566

email: medical@super.net.pk

Collaborate
on your cases

and access hours of
premium video training
and live webinars



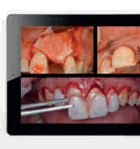University
of the Pacific

you will receive a
certificate from the
University of the Pacific



Latest iPad
with courses

all registrants receive
an iPad preloaded with
premium dental courses



100 ADA CERP
C.E. CREDITS

ADA C.E.R.P.® | Continuing Educator
Recognition Program

Tribune America LLC is the ADA CERP provider. ADA CERP is a service of the American Dental Association to assist dental professionals in identifying quality providers of continuing dental education. ADA CERP does not approve or endorse individual courses or instructors, nor does it imply acceptance of credit hours by boards of dentistry.