

DENTAL TRIBUNE

— The World's Dental Newspaper · Middle East & Africa Edition —

*Middle East & Africa
License Owned By:*

CAPP



PRINT
DIGITAL
EDUCATION
EVENTS

ESSENTIAL DENTAL MEDIA

www.dental-tribune.com



The DTI publishing group is composed of the world's leading dental trade publishers that reach more than 650,000 dentists in more than 90 countries.

dti Dental
Tribune
International



DENTAL TRIBUNE

The World's Dental Newspaper · Middle East & Africa Edition

Printed in Dubai

www.dental-tribune.me

March-April 2015 | No. 2, Vol. 4

HYGIENE TRIBUNE

Stannous Fluoride Dentifrice with Sodium Hexametaphosphate...

>Page 1B

>Insertion

LAB TRIBUNE

Firsthand experience with Polychromatic LS2 ingot... IPS e.max Multi... because it works

>Page 1C

>Insertion

INT'L DENTAL SHOW



Cologne, Germany
10-14 March 2015

>Insertion

DUBAI DENTAL MEETINGS

Dubai
Dental
Meetings

CAD/CAM
06-10 May 2015
7th DFCIC
11-15 November 2015

>Insertion

From IDS Cologne to DUBAI: High Tech...

...Innovations in Dentistry at 10th CAD/CAM & Digital Dentistry International Conference, Jumeirah Beach Hotel Dubai, 08-09 May 2015

By Centre For Advanced Professional Practices

COLOGNE, Germany / DUBAI, UAE: The 36th International Dental Show (10-14 March 2015) surpassed its predecessors with a record

number of dental companies exhibiting in 2015 and over 125,000 dental professionals expected to attend the world's largest dental showcase. Those who missed the opportunity to travel to Cologne, do not fear, the latest news and technological advances will be showcased in Dubai,



Jumeirah Beach Hotel Dubai, UAE

SOUTHERNIMPLANTS

MAX Implants

Co-Axis Implants

May Eliminate The Need For Grafting
Shortens Treatment Time

Appropriate Emergence

Stable Enough For Immediate Restoration

5 Different Connections



in May 2015. For the tenth consecutive time, organized by Centre For Advanced Professional Practices (CAPP) and Emirates Dental Society, 10th CAD/CAM & Digital Dentistry Int'l Conference (a part of Dubai Dental Meetings) will take place at the remarkable Jumeirah Beach Hotel between 06 - 10 May 2015.

"Do you provide CEREC restorations in your office? Does this office use Zirconia and eMax for crowns and veneers? Doctor, are you into CAD/CAM technology? These are quite common questions the patients usually ask nowadays. Questions which are very hard to answer unless dental professionals are really involved in this fast moving technology. This is precisely the importance of such conferences. Our societies are becoming more and more dependent on technology and what it can offer to make our lives easier and more enjoyable. Dentistry is no exception. Our patients are all the way different than they used to be a couple of decades ago. They have unrestricted easy access to knowledge through the web. They are becoming more and more demanding in terms of services that we provide as well as the technology we employ to do so. Our team of Organizers, Sponsors, as well as Speakers will continue the quest to keep all of you well ahead and updated in all fields of CAD/CAM and Digital Dentistry." - Dr. Munir Silwadi, Conference Chairman & Scientific Program Adviseor comments on the lead up of an anniversary year in Digital Dentistry for the Middle East dental professionals.

This year's CAD/CAM & Digital Dentistry Scientific Program is set to be arguably the most advanced of the series in its rich ten year history. Over 28 International Key Opinion Leaders are expected to walk and talk on the podium including Prof. Daniel Wismeijer (ACTA Amster-

dam - The Netherlands), Prof. Paul Tipton (UK), Prof. Richard Simonsen (USA), Dr. Andrea Gandolfi (Italy), Dr. Jan-Frederik Güth (Germany), Dr. Eduardo Mahn (Chile), Dr. Morten Worsoe, (Denmark), Dr. Harald Hüskens (German), MUDr. Petr Hajný, (Czech Republic) and lots more. Topics presented will vary from Ethics of Elective Dental Treatments,

> IDS Insertion Page 3

NEWS

King of Sweden ... 2

MEDIA CME

Immediate implantation... 6-7

AESTHETICS

The Importance of Cementation... 12-15

PAEDIATRIC TRIBUNE

Face asymmetries in children... 14

ORTHO TRIBUNE

Clear Fixed Appliances Chosen... 18

IMPLANT TRIBUNE

Drill through the tooth technique... 20-21

REFERRAL CLINIC

Troughing: Detection of three... 24-26

CAD/CAM

Carestream Dental CS Adapt... 35

PRACTICE MANAGEMENT

AAA - After Appointment Action 40

P.O. BOX 505190, DUBAI, U.A.E.

Tel: +971 (0)56 131 1574

Fax: +971 (0)4 427 5011

info@southernimplants.net | www.southernimplants.com

King of Sweden introduced to new standard of dental technology at Planmeca

By Dental Tribune International

HELSINKI, Finland: The Royal Technology Mission, with His Majesty King Carl XVI Gustaf of Sweden as its patron, visited Finnish health care technology manufacturer Planmeca in Helsinki on 27 November. His Majesty, along with 30 other top representatives of Sweden's government, private sector and academia, learnt about the company's growth story and innovations.

The Royal Technology Mission visited Finland to gain inspiration from the country's innovative companies, initiatives and growth strategies. At Planmeca, the mission was introduced to revolutionary 5x5D technology, patient-specific 5-D implants, and the dental unit-integrated intra-oral scanner Planmeca PlanScan. Planmeca is one of the



> Page 42

His Majesty King Carl XVI Gustaf of Sweden (left) shaking hands with Heikki Kyöstiä (right), President of Planmeca. His Majesty visited Finland for inspiration from innovative companies such as the dental market leader. (Photographs: Planmeca)

KaVo DIAGNOcam

Seeing is Believing.

KaVo DIAGNOcam
Images that change your world.

- Outstanding caries diagnosis
- Unsurpassed approximal caries identification
- Visual monitoring at its best



KaVo. Dental Excellence.

KaVo Dental GmbH · Dubai Healthcare City · Building 34, 3rd Floor · Phone: +971 4 550 8600 · Fax: +971 4 550 8781 · Email: info.mea@kavo.com · www.kavo.com/mea

DENTAL TRIBUNE

The World's Dental Newspaper - Middle East & Africa Edition

GROUP EDITOR

Daniel Zimmermann
newsroom@dental-tribune.com
Tel.: +49 541 48 474 107

CLINICAL EDITOR

Magda Wojtkiewicz

ONLINE EDITORS

Yvonne Bachmann
Claudia Duschek

COPY EDITORS

Sabrina Raaff
Hans Motschmann

PUBLISHER/PRESIDENT/CEO

Torsten Oemus

CHIEF FINANCIAL OFFICER

Dan Wunderlich

BUSINESS DEVELOPMENT MANAGER

Claudia Salwiczek

JUNIOR MANAGER BUSINESS DEVELOPMENT

Sarah Schubert

EVENT MANAGER

Lars Hoffmann

MARKETING SERVICES

Nadine Dehmel

SALES SERVICES

Nicole Andrä

EVENT SERVICES

Esther Wodarski

PROJECT MANAGER ONLINE

Martin Bauer

MEDIA SALES MANAGERS

Matthias Diessner (Key Accounts)
Melissa Brown (International)
Peter Witteczek (Asia Pacific)
Weridiana Mageswki (Latin America)
Maria Kaiser (USA)
Hélène Carpentier (Europe)
Barbora Solarova (Easten Europe)

ACCOUNTING

Karen Hamatschek
Anja Maywald
Manuela Hunger

ADVERTISING DISPOSITION

Marius Mezger

EXECUTIVE PRODUCER

Gernot Meyer

DENTAL TRIBUNE INTERNATIONAL

Holbeinstr. 29, 04229 Leipzig, Germany
Tel.: +49 541 48 474 502
Fax: +49 541 48 474 175
www.dental-tribune.com
info@dental-tribune.com

DENTAL TRIBUNE ASIA PACIFIC LTD.

Room A, 20/F, Harvard Commercial Building,
105-111 Thomson Road, Wanchai, HK
Tel.: +852 5115 6177
Fax: +852 5115 6199

THE AMERICA, LLC

116 West 23rd Street, Ste. 500, New York N.Y. 10011, USA
Tel.: +1 212 244 7181
Fax: +1 212 244 7185

DENTAL TRIBUNE MEA

EDITION EDITORIAL BOARD
Dr. Aisha Sultan Alsuwaidi, UAE
Dr. Ninette Banday, UAE
Dr. Nabeel Humood Alsaabeha, UAE
Dr. Mohammad Al-Obaida, KSA
Dr. Meshari F. Alotaibi, KSA
Dr. Jasim M. Al-Saeedi, Oman
Dr. Mohammed Sultan Al-Darwish
Prof. Khaled Balto, KSA
Dr. Dobrina Mollova, UAE
Dr. Munir Silwadi, UAE
Dr. Khaled Abouseada, KSA
Dr. Rabih Abi Nader, UAE
Dr. George Sanoop, UAE
Aiham Farrah, CDT, UAE
Retty M. Matthew, UAE

PARTNERS

Emirates Dental Society
Saudi Dental Society
Lebanese Dental Association
Qatar Dental Society
Oman Dental Society

DIRECTOR OF mCME

Dr. Dobrina Mollova
mollova@dental-tribune.me
Tel.: +971 50 42 43072

DIRECTOR

Tzvetan Deyanov
deyanov@dental-tribune.me
Tel.: +971 55 11 28 581

CEREC Omnicam

POWDER-FREE AND IN NATURAL COLOR.

Scanning with the new CEREC Omnicam combines powder-free ease of handling with natural color reproduction to provide an inspiring treatment experience for the patient. Discover the new simplicity of digital dentistry. **Enjoy every day. with Sirona.**



Mohamed Abdel Aziz
Sirona - Kuwait
Sirona Dental GmbH
office : +96522246063
mobile: +96567057908
email address : mohamed.abdelaziz@sirona.com

Sirona – The Dental Company shines in Dubai

By Sirona

DUBAI, UAE: Sirona Middle East was again at the center of attention at the 19th International Dental Conference & Arab Dental Exhibition in Dubai between 17-19th February 2015. The Dental Company exhibited with a specially designed booth conducting ongoing trainings and presentations given by Sirona staff, CEREC trainers and Key Opinion Leaders including the infamous Dr. Daniel Vasquez, USA. Dr. Vasquez also presented at last year's CEREC Desert Fest in Dubai.

Sirona will soon enter a new milestone in the Middle East region where a direct operation and dedicated dealership will work together on bringing an optimal support bringing the sales and services of The Dental Company to a higher level compared to the rest in the industry. We presented the model to our customers during the International Dental Conference & Arab Dental Exhibition in Dubai and we expect a market service boost in the years to come.

After the successful CEREC Desert Fest in September last year we brought back Dr. Daniel Vasquez (USA) who is an icon in presenting CEREC to new customers. With his unique appeal



Dr. Daniel Vasquez, USA – presented various lectures and hands-on presentations on stage



Sirona booth was at the center of attention during the trade show in Dubai

in detailing the product to audiences Dr. Daniel provided several hands-on presentations at the trade show in front of interested potential and existing customers. The presentations showed the ease of using CEREC and how it is the CAD/CAM application which should be used in dentistry for the present and future.

Recently Sirona launched yet again a new system, providing a freedom of choice with the MCX5. The new InLab system will have a big impact on the CAD/CAM lab business. The product was officially launched in the Middle East in February

and the feedback was above expectations. The smart compact designed five-axis milling and grinding unit is especially developed for the demands of the dental laboratories completing Sirona's inLab system. Dental Technicians will now benefit from the great flexibility for the entire production process of esthetically pleasing restorations and the largest selection of materials available on the market. IDS Cologne 2015 – the Mondial of the Dental Industry is set to begin on 10th March and Sirona will bring all the new products to the marketing boosting the industry with different product lines such as Imaging and CAD/

CAM systems, Treatment Centers and Instruments.

Sirona will continue to grow worldwide and in the Middle East region which will be shown through our core built on Education in our products which we produce for the dental industry. We are in a sector of our society that has built careers on knowledge and product understanding in order to deliver the best treatment to their patients. Sirona aims to always be in the background of our customers and supply them not only with the technology but the know-how behind the fast changing industry. This has been and will

continue to be achieved through well maintained high level continuing dental education programs ensuring the long term continuity of our customers' business. [DT](#)

Contact Information

Dr. Amro Adel
Area Manager GCC & Pakistan
Country Manager Saudi Arabia
Sirona Dental GmbH
Email: amro.adel@sirona.com
Web: www.Sirona.com

www.idem-singapore.com

THE BUSINESS OF DENTISTRY



INTERNATIONAL DENTAL EXHIBITION AND MEETING APRIL 8 - 10, 2016

Suntec Singapore Convention & Exhibition Centre

Now Open for Exhibition Applications,
Sponsorship Opportunities

Supporting Forums



Visit us at
V006,
Passage 10/11

IDS
2015

Endorsed By



Supported By



Held In



In Cooperation With



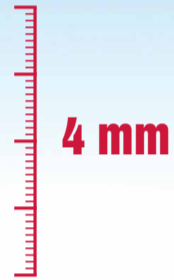
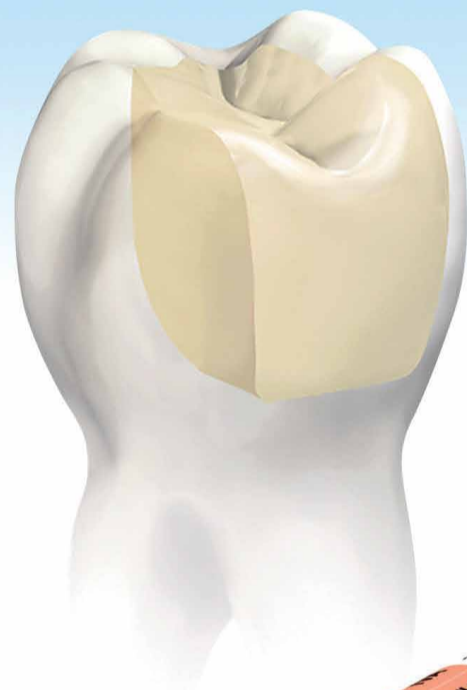Co-organizer



Tetric[®] N-Ceram Bulk Fill

The nano-optimized 4-mm composite

Discover the new
time-saving
composite



4 mm to success

- Bulk filling is possible due to Ivocerin[®], the patented light initiator
- Special filler technology ensures low shrinkage stress
- Esthetic results are achieved quickly and efficiently in the posterior region

www.ivoclarvivadent.com

Ivoclar Vivadent AG
Bendererstr. 2 | 9494 Schaan | Liechtenstein | Tel.: +423 235 35 35 | Fax: +423 235 33 60

ivoclar
vivadent[®]
passion vision innovation

Immediate implantation and provisionalization: Single-tooth restoration in the esthetic zone



mCME articles in Dental Tribune have been approved by:

HAAD as having educational content for 2 CME Credit Hours

DHA awarded this program for 2 CPD Credit Points

ADA CERP® | Continuing Education Recognition Program

Centre for Advanced Professional Practices (CAPP) is an ADA CERP Recognized Provider. ADA CERP is a service of the American Dental Association to assist dental professionals in identifying quality providers of continuing dental education. ADA CERP does not approve or endorse individual courses or instructors, nor does it imply acceptance of credit hours by boards of dentistry.

CAPP designates this activity for 2 CE credits.

By Susan McMahon, DMD and Karrah Petruska

Anterior tooth loss and restoration in the esthetic zone is a common challenge in dentistry today. The prominent visibility of the area can be especially distressing to the patient and requires a timely and esthetically pleasing solution.

Immediate single-tooth implantation followed by immediate provisionalization is becoming an increasingly desirable treatment that offers numerous benefits over conventional delayed loading.

In the past, the non-restorable tooth was extracted and possibly grafted for site preservation. A removable partial denture (or flipper) was fabricated and placed for use during healing. After an adequate healing period, an implant was placed and buried under the gingiva, and the patient continued to wear the flipper until the implant had osseointegrated and was ready to be uncovered and restored. The patient would therefore wear the removable partial denture for upwards of six to eight months.

This course of treatment often results in a less than desirable gingival architecture surrounding the final restoration. There are also clear indications that partial removable dentures are an important causative factor in the alveolar bone resorption process.¹ Today, immediate treatment offers a better solution. Immediate implantation and same-day provisional replacement of single anterior teeth minimizes treatment time and cost while enhancing esthetic quality.² In addition to alleviating patient trauma, this technique decreases resorption of hard and soft tissue and results in better function.² Overall, this leads to greater patient satisfaction.

In this process, the implant is placed and a provisional is quickly loaded. A nonfunctioning, also known as non-occluding, provisional is used in a protected occlusal scheme.

The placement of the non-occluding restoration must occur within 48 hours to be considered immediate loading.³ Both of the following cases received same day provisionalization.

The clinician faces several challenges when restoring teeth in the esthetic zone. Major cosmetic concerns in the fabrication of the

immediately placed provisional are the retention of the interdental papilla and prevention of alveolar bone collapse.⁴ Research has suggested that immediate provisionalization following implantation allows for greater clinical control over the regeneration of tissue surrounding the site of extraction.⁵

Unfavorable alterations to the alveolar bone structure must be avoided using ridge preservation techniques and precautions in terms of osseous exposure.⁵ Immediate placement of the implant into fresh extraction sockets prevents the post-extraction resorption that occurs commonly with alternate forms of treatment, preserving the integrity of the alveolar ridge.⁶

A compromised implantation site is also a concern when dealing with tooth loss. Bone resorption may leave insufficient bone for implantation. Furthermore, a deteriorated gingival architecture produces an inferior esthetic. Immediate implantation into the fresh extraction socket allows the clinician to maintain the gingival tissue and create a more esthetically pleasing restoration.²

Minimum criteria for implant placement have been established for successful immediate loading. Rough quantitative values for insertion torque and implant stability quotient (ISQ) as well as surgical assessment play a role. Values as low as 15N-cm for insertion torque and 50 ISQ both resulted in successful provisionalization. Additionally, the surgeon must assess where there is adequate bone support at the apex, at least 3 mm of circumferential bone, and primary stability of the implant. Research has shown that "early loading of dental implants does not appear to interfere with osseous modeling of a developing osseointegration as long as significant micromovement does not occur".⁷

In addition to providing both esthetic and functional benefits, immediate implantation and loading of a nonfunctioning provisional has also been found to result in comparable implant survival outcomes to more traditional techniques.

A recent study measuring clinical success, survival, and satisfaction found the technique to be "not less favorable than conventional loading."⁸ In consideration of this, current literature is now purporting immediate implantation and

non-occlusal loading to be the "treatment of choice" in cases of single anterior tooth restoration.⁸ The following are two case studies involving immediate provisionalization. In both cases, the maxillary right central incisors had sustained trauma, were endodontically treated and functioned for a number of years. Approximately 15-20 years later, the teeth in each case failed due to internal resorption. The failing teeth were extracted and implants were inserted immediately and restored the same day with a non-functional provisional.

Dental root resorption involves the loss of hard tissues that compose the teeth (dentin, cementum and enamel).⁹ In most cases, tooth resorption is the result of trauma or irritation to the periodontal ligament and/or tooth pulp.⁹ These conditions may occur as a result of injury, inflammation or chronic infection of the pulp, periodontal conditions, orthodontic tooth motility or tooth eruption.^{9,10} Internal resorption is generally asymptomatic and is discovered most frequently through radiographic examination.^{9,10}

If internal root resorption is left to progress untreated, it may result in extension to the periodontal ligament through a crown or root perforation.⁹

Case study 1: failing maxillary right central incisor

The patient is a 30-year-old healthy male who was examined in our office for a failing maxillary right central incisor. His history involves a soccer accident in 1995 that resulted in an elbow to the face with trauma to the right maxillary central incisor. Approximately one week subsequent to the accident, the patient's tooth was treated endodontically. It eventually became discolored and grew increasingly out of alignment (Fig.1). Radiographic examination revealed internal resorption.

Clinically, all other maxillary and mandibular teeth were in good condition. Periodontal examination revealed healthy gingival tissue. The patient was concerned that his anterior tooth would fracture unexpectedly and desired an immediate replacement.

Treatment options

Several treatment options were considered. The first was extraction of the maxillary right central incisor and fabrication and

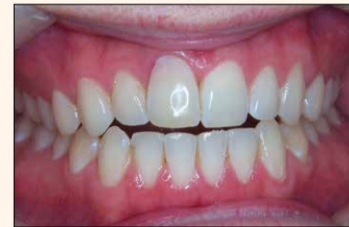

Fig. 1

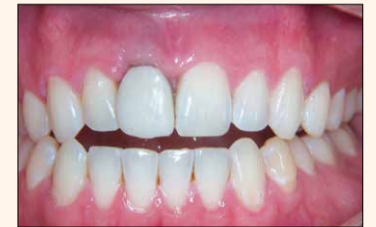

Fig. 2

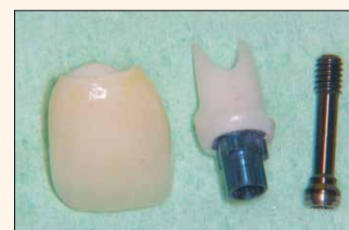

Fig. 3



Fig. 4

placement of a conventional fixed bridge of porcelain fused to metal or an all-ceramic system. The second option was extraction of the tooth followed by placement of a removable partial denture. The next option was extraction, provisionalization with a removable partial denture (flipper) followed by implant placement, healing while wearing the flipper and, finally, restoration of the implant. The best alternative was extraction and immediate replacement of the extracted tooth with an implant, followed by immediate loading with a nonfunctioning provisional. After adequate osseointegration, a final restoration would be fabricated. Advantages and disadvantages of all options were explained to the patient. He decided to continue treatment with an immediate implant restoration. The patient was then referred to a periodontist for further evaluation and implant consultation.

Implant evaluation

Implant examination revealed adequate bone height and width for implant placement immediately following extraction of the failing tooth. A surgical date was scheduled with the periodontist for extraction of the tooth and placement of the implant. An appointment was coordinated with our office for the patient directly following the surgical procedure for provisionalization of the implant.

Surgical protocol

The right central incisor was removed and a NobelReplace Tapered Groovy (internal connection) 5.0 mm x 15 mm implant was placed. An osseous graft of demineralized freeze-dried bone and a collagen membrane were utilized to augment the surgi-

cal site. The fixture received an emergence profile, healing abutment.

Provisionalization

The patient presented in our office after the implant placement with a healing abutment in place. The healing abutment was removed. A Nobel Biocare immediate temporary abutment was placed and a provisional was fabricated.

Care was taken to contour the emergence of the provisional as to best support the gingival architecture. The plastic coping for the immediate temporary abutment was roughened with a 56 carbide bur to enhance adherence of the integrity provisional material used.

The provisional was polished and placed on the immediate temporary abutment with a small amount of flowable composite to enhance retention. The provisional crown was fabricated to be completely out of occlusion and non-functional to ensure the implant adequate osseointegration time undisturbed by occlusal forces. The provisional restoration was observed periodically during the six-month healing process to monitor gingival adaptation (Fig. 2).

Final restoration

Six months post surgery, the patient was scheduled for placement of the final restoration. After removing the provisional crown and the immediate temporary abutment, an implant impression post was placed, radiographic verification was made to assure complete seating and a final impression was taken with a polyether system. Complex shade-mapping was carefully performed to match the existing contralateral natural



< Page 6

teeth. The provisional was then reinserted.

A Procera zirconia custom implant abutment was chosen. Zirconium implant abutments have not only been noted for their tooth-like color and esthetic appeal but also for tissue tolerability, high load strength and intrasulcular design enhancement.¹¹

The extraordinary load strength of the oxide ceramics is not compromised by high bending and tensile strength, and fracture and chemical resistance.¹¹

Zirconium abutments are mechanically equivalent to their metal counterparts but boast greater biological compatibility.¹¹ Results of a recent study provide evidence that the ceramic oxide abutments can be safely utilized in the incisor region of both the maxilla and mandible as determined by maximal bite forces in the esthetic zone.¹¹ Due to excellent restorative properties in terms of strength and color conformity, the zirconium implant-abutment is becoming increasingly favored by clinicians for esthetically pleasing anterior implant restorations.¹² A Procera zirconia crown was fabricated for this patient with Noritake CZR porcelain (Fig. 5).

At the time of insert, the provisional crown and immediate temporary abutment were removed. The Procera zirconia custom abutment was seated, the screw was hand tightened and the screw was torqued to 35 Ncm with the manual torque wrench. The access was filled with a small cotton pellet and topped with a thin layer of flowable composite.

The Procera zirconia crown

was then seated; margins, contacts and occlusion were confirmed; and the crown was cemented in place with 3M ESPE RelyX luting cement (Fig. 4).

Case study 2: fractured maxillary right central incisor

This patient, a healthy male in his late 50s, was examined in my office for a fractured maxillary right central incisor. The patient had Feldspathic porcelain restorations on his upper central and upper lateral incisors that were placed several years ago. He had a history of trauma to the anterior teeth from a sports injury and subsequent endodontic treatment. Recent periapical radiographs showed internal resorption in the upper incisors (Fig. 5). The patient sustained additional trauma to the maxillary right central incisor through a fall, which resulted in complete fracture of the crown (Fig. 6). The tooth was nonrestorable.

After reviewing the different treatment options, the patient decided on an immediate implant restoration. Although the maxillary left central incisor also exhibited signs of internal resorption, it was decided that treatment of that tooth would be performed at a later date. Consideration was given to the poor gingival architecture that results from placing adjacent implants in the esthetic zone.

He was then evaluated by the periodontist for the surgical placement of the immediate implant for the maxillary right central incisor. The patient's treatment was similar to that of the patient in the

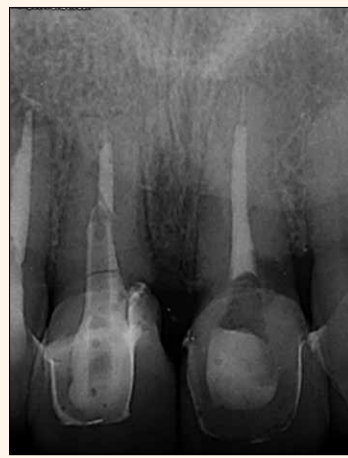

Fig. 5

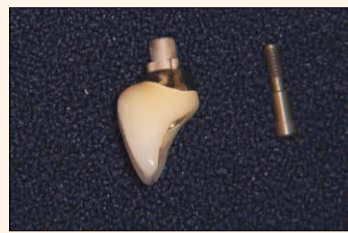

Fig. 7

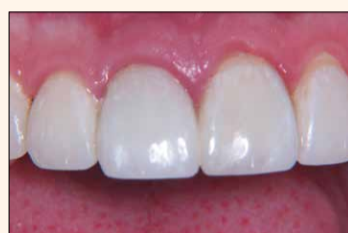

Fig. 9

first case study.

The right central incisor was removed and a NobelReplace Tapered Groovy (internal connection) 5.0 mm x 13 mm implant was placed. An osseous graft of demineralized freeze-dried bone was utilized to augment the surgical site. The fixture received an emergence profile, healing abutment. The patient then received an immediate non-functioning provisional.

Final restoration

After the six-month healing period the final restoration was fabricated. In this case, a one-piece screw-through abutment made from a Nobel Biocare GoldAdapt Engaging NobelReplace (Fig. 7) was fabricated in order to obtain a correct emergence profile of the restoration due to the slightly lingual placement of the implant (Fig. 8).

The restoration was seated, and the screw was hand tightened and then torqued to 35 Ncm with the manual torque wrench. The lingual screw access was filled with a cotton pellet and composite restoration (Fig. 9).

Conclusion

In the cases cited above, both patients had sustained injuries to their anterior teeth as young adults while engaging in sports. Each of the patients had been treated endodontically and experienced internal resorption of the traumatized teeth approximately 15 years later. Both of their careers and lifestyles demanded immediate replacements that were non-removable and esthetically pleasing.

The failing teeth were extracted and implants were inserted immediately and restored the same day with a non-functional loaded

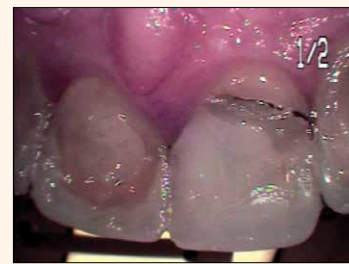

Fig. 6

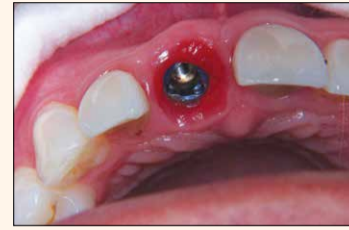

Fig. 8

provisional. Immediate placement and restoration of a single implant offers a highly esthetic and timely treatment option in the case of internal resorption and tooth failure in the maxillary central incisors.

Furthermore, this treatment eliminates the need for a removable partial denture while maintaining the gingival architecture and preventing alveolar bone loss in the extraction site.

As esthetic expectations of patients and the desire for a convenient and timely treatment continue to increase, instantaneous replacement of failing teeth is becoming more routine.¹³ Not only does placing the implant immediately following extraction maintain the alveolar architecture and retain the interdental papillas, placing the provisional immediately thereafter refines the level of treatment the clinician can offer the patient. Esthetic quality is enhanced without comprising long-term implant stability. Immediately placing and loading implants is both functionally and cosmetically beneficial.

References

- 1) Mijiritsky E. Implants in conjunction with removable partial dentures: a literature review. *Implant Dentistry* 2007; 16(2):146-154.
- 2) Singh A, Gupta A, Yadav A, Chaturvedi TP, Bhatnagar A, Singh BP. Immediate placement of implant in fresh extraction socket with early loading. *Contemporary Clinical Dentistry* 2012; 3(Suppl 2):S219-222.
- 3) den Hartog L, Raghoobar GM, Stellingsma K, Vissink A, Meijer HJ. Immediate non-occlusal loading of single implants in the esthetic zone: a randomized clinical trial. *Journal of Clinical Periodontology* 2011; 38(2):186-194.
- 4) Saghezchi K. Replacing a single anterior tooth immediately after extraction with a single implant to preserve interproximal papilla and alveolar bone. *The Journal of Cosmetic Dentistry* 2004; 19(4):70-76.
- 5) De Kok I, Chang S, Moriarty J, Cooper L. A retrospective analysis of peri-implant tissue responses at immediate load/provisionalized microthreaded implants. *International Journal of*

Oral and Maxillofacial Implants 2006; 21(5):405-412.

6) Ormianer Z, Schirotti G. Maxillary single-tooth replacement utilizing a novel ceramic restorative system: Results to 30 months. *Journal of Oral Implantology* 2006; 32(4):190-199.

7) Becker CM, Wilson TG Jr, Jensen OT. Minimum criteria for immediate provisionalization of single-tooth dental implants in extraction sites: a 1-year retrospective study of 100 consecutive cases. *Journal of Oral and Maxillofacial Surgery* 2011; 69(2):491-497.

8) Malchiodi L, Cucchi A, Ghensi P, Nocini PF. Evaluation of the esthetic results of 64 nonfunctional immediately loaded postextraction implants in the maxilla: correlation between interproximal alveolar crest and soft tissues at three years of follow-up. *Clinical Implant Dentistry and Related Research* 2011 Dec 16; Epub ahead of print.

9) Ne R, Witherspoon D, Gutmann J. Tooth Resorption. *Quintessence International Dental Digest* 1999; 30(1):9-25.

10) Gunraj MN. Dental root resorption. *Oral Surgery, Oral Medicine, Oral Pathology* 1999; 88(6):647-655.

11) Gehrke P, Dhong G, Brunner J, Ing D, Wolf D, Degidi M, Piattelli A. Zirconium implant abutments: Fracture strength and influence of cyclic loading on retaining-screw loosening. *Quintessence International* 2006; 37(1):19-26.

12) Biow Tan P, Dunne J. An esthetic comparison of a metal ceramic crown and cast metal abutment with an all-ceramic crown and zirconia abutment: a clinical report. *Journal of Prosthetic Dentistry* 2004; 91(5):215-218.

13) Barone A, Rispoli L, Voza I, Quaranta A, Lovani U. Immediate restoration of single implants placed immediately after tooth extraction. *Journal of Periodontology* 2006; 77(11):1914-1920. **DT**

mCME SELF INSTRUCTION PROGRAM

CAPP together with Dental Tribune provides the opportunity with its mCME- Self Instruction Program a quick and simple way to meet your continuing education needs. mCME offers you the flexibility to work at your own pace through the material from any location at any time. The content is international, drawn from the upper echelon of dental medicine, but also presents a regional outlook in terms of perspective and subject matter.

Membership:

Yearly membership subscription for mCME: 900 AED
One Time article newspaper subscription: 250 AED per issue.
After the payment, you will receive your membership number and allowing you to start the program.

Completion of mCME

- mCME participants are required to read the continuing medical education (CME) articles published in each issue.
- Each article offers 2 CME Credit and are followed by a quiz Questionnaire online, which is available on <http://www.cappmea.com/mCME/questionnaires.html>.
- Each quiz has to be returned to events@cappmea.com or faxed to: +97145686885 in three months from the publication date.
- A minimum passing score of 80% must be achieved in order to claim credit.
- No more than two answered questions can be submitted at the same time
- Validity of the article – 5 months
- Validity of the subscription – 1 year
- Collection of Credit hours: You will receive the summary report with Certificate, maximum one month after the expiry date of your membership. For single subscription certificates and summary reports will be sent one month after the publication of the article.

The answers and critiques published herein have been checked carefully and represent authoritative opinions about the questions concerned.

Articles are available on www.cappmea.com after the publication. For more information please contact events@cappmea.com or +971 4 5616174

FOR INTERACTION WITH THE AUTHORS FIND THE CONTACT DETAILS AT THE END OF EACH ARTICLE.

About the Authors

Susan McMahon, DMD, is in private practice in Pittsburgh. She is accredited by the American Academy of Cosmetic Dentistry and is a six-time award winner in the AACD Annual Smile Gallery. She has served as a clinical professor in prosthodontics and operative dentistry at the University of Pittsburgh, School of Dental Medicine. McMahon is a guest lecturer in cosmetic dentistry at West Virginia School of Dentistry and lectures to dentists in the United States and Europe. You may contact McMahon at www.wowinsmile.com.

Karrah Petruska is a graduate of the University of Wisconsin-Madison. She is in the dual master's program, post-baccalaureate pre-medical program and master's of health management systems at Duquesne University.