

Journal of

Oral Science Rehabilitation &

Journal for periodontology, implant dentistry,
dental prosthodontics and maxillofacial surgery

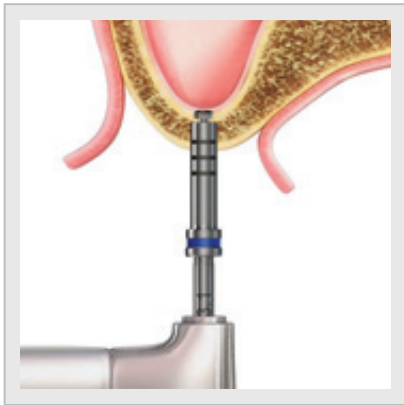
ISSN 2365-6891

Volume 2 — Issue 3/2016

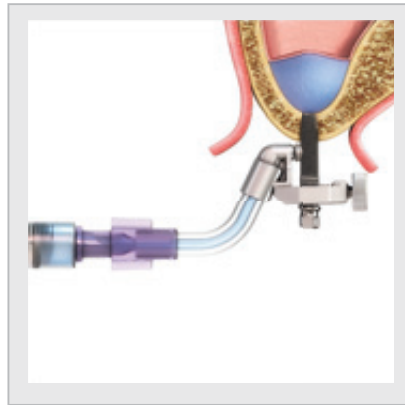
dti] Dental
Tribune
International

iRaiseTM SINUS LIFT SYSTEM

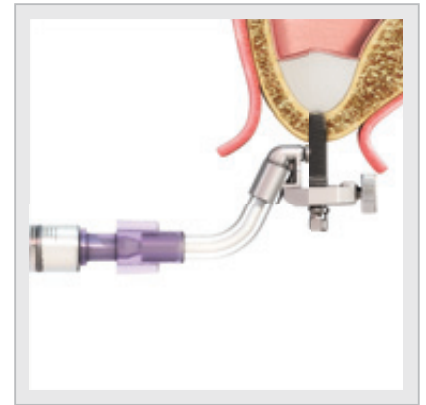
Perform sinus lifts in 25 minutes at your clinic



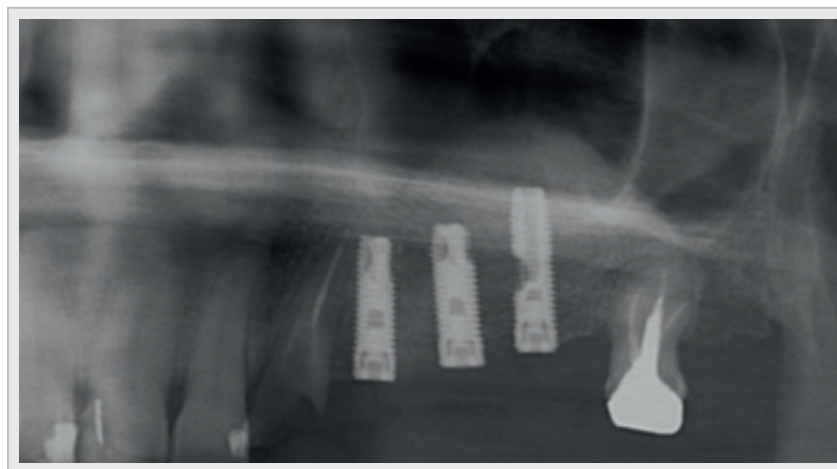
1 Reach sinus safely:
special cortex drill



2 Elevate membrane
with saline pressure



3 Inject
bone graft



Post-op panoramic X-ray

perform sinus lift procedures with **confidence** and **ease**
dramatically improve your patients' **experience** and **quality of life**

**Seeking exclusive distributors:
come and share the iRaise success**

www.maxillent.com

e-mail: info@maxillent.com

maXillent



Journal of

Oral Science & Rehabilitation

What is the most severe
early complication concerning dental implants?

The placement of dental implants, although not without early complications—which are usually self-limited—has become a scheduled, routine and standardized surgical procedure. However, it is important that education in oral implantology adequately cover the immediate bleeding complications, especially in the floor of the mouth, that may arise and that, although infrequent, may be severe, sometimes even life-threatening, and require hospitalization for emergency treatment.

The interforaminal area in the mandible is quite often considered as the easiest region in which to insert dental implants, such as placing two implants to support an overdenture. However, the most serious bleeding accidents occur in this region owing to injury of the terminal branches of the sublingual or submental arteries if the lingual cortical plate is perforated during drilling or implant placement. This vascular injury can trigger massive internal bleeding in the mouth floor, which expands, causing protrusion and displacement of the tongue and sometimes subsequent obstruction of the airways, which may necessitate an emergency tracheotomy or even be fatal. Thus, the clinician should not treat placement of anterior mandibular implants lightly in the belief that placement in this region is easy.

In order to minimize the possibility of perforating the lingual cortical plate, some authors recommend placing implants that are not very long (10–12 mm) in the anterior region of the mandible. Tilting implants in a buccolingual direction, tipping the implant apex toward the vestibule, is another option. Perhaps the most important factor concerning minimization of the risk of these complications is that the surgeon carrying out the implant therapy should have extensive anatomical knowledge of this area, including the important anatomical structures located in the sublingual space.

Dr. Miguel Peñarrocha Diago
Co-Editor

03

Editorial

Dr. Miguel Peñarrocha Diago

06

About the *Journal of Oral Science & Rehabilitation*

08

Marco Tallarico et al.

Minimally invasive hydraulic elevation of the Schneiderian membrane and insertion of bone graft material using a novel self-tapping implant system: Radiographic and prosthetic aspects

16

Marco Annunziata et al.

Impact of argon plasma treatment on microbiological surface receptivity of titanium implants: An *in vitro* study

20

Erta Xhanari and Milena Pisano

Comparison of hard- and soft-tissue changes using a superimposition technique: A prospective case series study

26

Rubén Agustín Panadero et al.

Influence of fatigue on resistance and deformation of implant abutments used for provisional prosthetic restoration

34

Gaia Pellegrini et al.

Human pulps capped with PDGF: A pilot study

42

Fabio Camacho Alonso et al.

Importance of the axial reference plane in computed tomography for dental implant surgery: A cadaveric study

50

Giovanni Polizzi et al.

Immediate loading of variable-thread expanding tapered-body implants placed into maxillary post-extraction or healed sites using a guided surgery approach: An up-to-5 year retrospective analysis

62

Atsuko Imai et al.

An *in vitro* study on viscosity using an electromagnetically spinning sphere viscometer

68

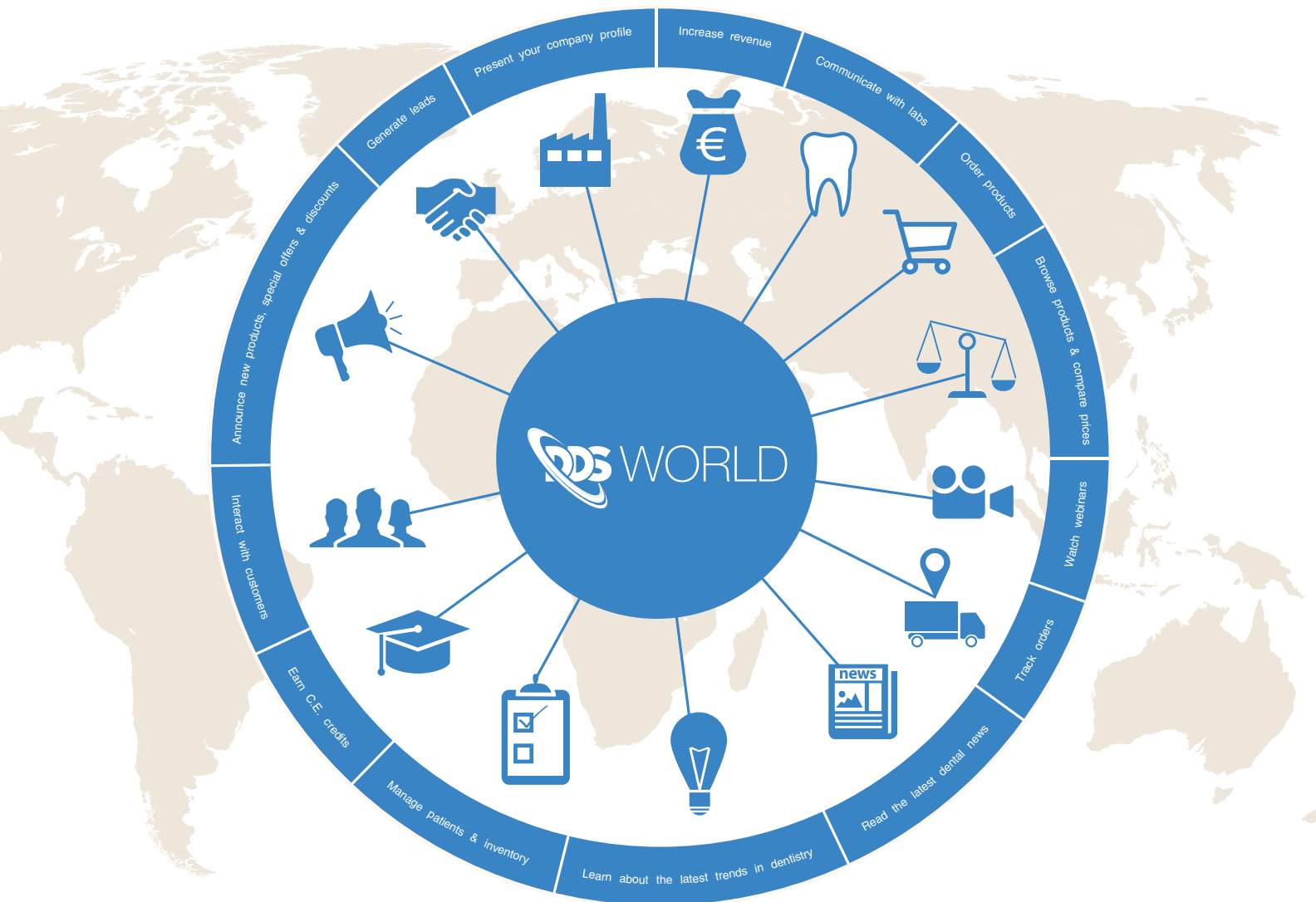Guidelines for authors

70

Imprint — about the publisher

The New Digital Marketplace

The most comprehensive resource in dentistry



FOR VENDORS

- ✓ List products & special offers
- ✓ Announce new products & discounts
- ✓ Generate leads & increase sales
- ✓ Release & distribute articles, videos & tutorials
- ✓ Present your company profile
- ✓ Interact with your clients

FOR DENTAL PROFESSIONALS

- ✓ Manage patients & inventory
- ✓ Browse products & compare prices
- ✓ Place orders & track delivery status
- ✓ Collaborate with labs & colleagues
- ✓ Read the latest international dental news & research
- ✓ Watch webinars & earn C.E. credits

About the *Journal of Oral Science & Rehabilitation*

The aim of the *Journal of Oral Science & Rehabilitation* is to promote rapid communication of scientific information between academia, industry and dental practitioners, thereby influencing the decision-making in clinical practice on an international level.

The *Journal of Oral Science & Rehabilitation* publishes original and high-quality research and clinical papers in the fields of periodontology, implant dentistry, prosthodontics and maxillofacial surgery. Priority is given to papers focusing on clinical techniques and with a direct impact on clinical decision-making and outcomes in the above-mentioned fields. Furthermore, book reviews, summaries and abstracts of scientific meetings are published in the journal.

Papers submitted to the *Journal of Oral Science & Rehabilitation* are subject to rigorous double-blind peer review. Papers are initially screened for relevance to the scope of the journal, as well as for scientific content and quality. Once accepted, the manuscript is sent to the relevant associate editors and reviewers of the journal for peer review. It is then returned to the author for revision and thereafter submitted for copy editing. The decision of the editor-in-chief is made after the review process and is considered final.

About Dental Tribune Science

Dental Tribune Science (DT Science) is an online open-access publishing platform (www.dtscience.com) on which the *Journal of Oral Science & Rehabilitation* is hosted and published.

DT Science is a project of the Dental Tribune International Publishing Group (DTI). DTI is composed of the leading dental trade publishers around the world. For more, visit

www.dental-tribune.com



Benefits of publishing in the journal for authors

There are numerous advantages of publishing in the *Journal of Oral Science & Rehabilitation*:

- Accepted papers are published in print and as e-papers on www.dtscience.com.
- Authors' work is granted exposure to a wide readership, ensuring increased impact of their research through open-access publishing on www.dtscience.com.
- Authors have the opportunity to present and promote their research by way of interviews and articles published on both www.dtscience.com and www.dental-tribune.com.
- Authors can also post videos relating to their research, present a webinar and blog on www.dtscience.com.

Subscription price

€50.00 per issue, including VAT and shipping costs.

Information for subscribers

The journal is published quarterly. Each issue is published as both a print version and an e-paper on www.dtscience.com.

Terms of delivery

The subscription price includes delivery of print journals to the recipient's address. The terms of delivery are delivered at place (DAP); the recipient is responsible for any import duty or taxes.

Copyright © 2016 Dental Tribune International GmbH. Published by Dental Tribune International GmbH. All rights reserved. No part of this publication may be reproduced, stored or transmitted in any form or by any means without prior permission in writing from the copyright holder.

Minimally invasive hydraulic elevation of the Schneiderian membrane and insertion of bone graft material using a novel self-tapping implant system: Radiographic and prosthetic aspects

Abstract

Objective

The objective of this article was to report the clinical and radiographic performance of a novel implant system that allows for hydraulic Schneiderian membrane elevation and simultaneous bone graft augmentation.

Case description

A 63-year-old female patient presenting with compromised fixed dental prostheses supported by failing teeth in her posterior maxilla underwent transcrestal sinus floor elevation using a novel implant system. Implant failure, any complications and bone gain measured using cone beam computed tomography (CBCT) were assessed.

Results

The residual alveolar ridge height was 3.2 mm. A 14.5 mm length implant was placed and followed for 20 months. Bone gain was 18.5 mm after a healing period of eight months. One year after implant loading, CBCT scans showed the stability of the grafted material.

Conclusion

Hydraulic elevation of the Schneiderian membrane using the iRaise sinus lift system (Maxillent, Herzliya, Israel) can be considered a valuable treatment option for the rehabilitation of atrophic edentulous posterior maxillae.

Keywords

Dental implant, sinus lift, Schneiderian membrane, atrophic maxilla, bone augmentation.

Marco Tallarico,^{a, b} Erta Khanari,^c Paolo Paglia^d & Silvio Mario Meloni^b

^a Private practice, Rome, Italy

^b Dentistry Unit, University Hospital of Sassari, Sassari, Italy

^c Private practice, Tirana, Albania

^d Private dental laboratory, Rome, Italy

Corresponding author:

Dr. Marco Tallarico

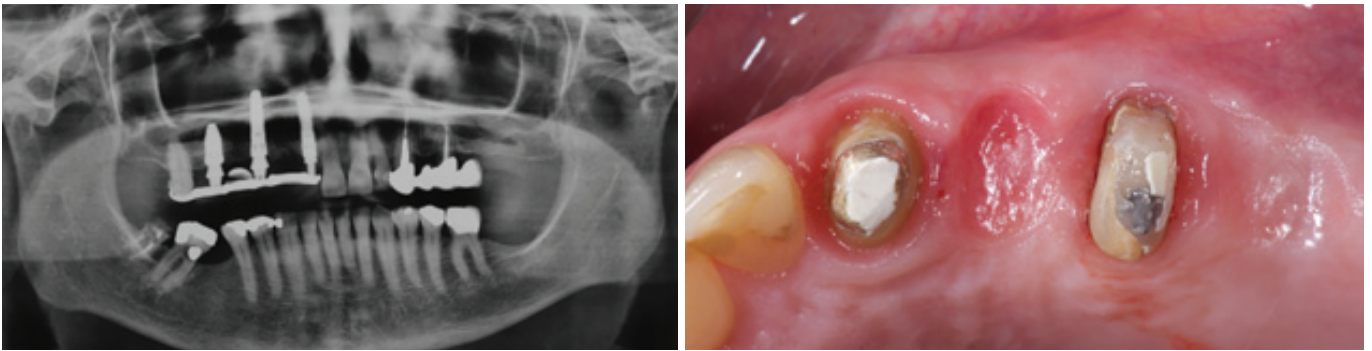
Via di Val Tellina 116
00151 Rome
Italy

T +39 328 075 8769
me@studiomarcotallarico.it

How to cite this article:

Tallarico M, Khanari E, Paglia P, Meloni SM. Minimally invasive hydraulic elevation of the Schneiderian membrane and insertion of bone graft material using a novel self-tapping implant system: radiographic and prosthetic aspects. J Oral Science Rehabilitation. 2016 Sep;2(3):8–14.

Figs. 1 & 2



Introduction

In the posterior sextants of the maxilla, tooth loss is generally associated with alveolar bone loss and sinus pneumatization.¹ In addition, poor bone quality may have a negative influence on the survival rate of implants.² There is no consensus on treatment for the atrophic posterior maxilla, with the dilemma of whether to place short implants^{3,4} or tilted implants^{5,6} or to augment the floor of the maxillary sinus.^{7,8} In a recent review of the literature, Pjetursson et al. reported that the placement of dental implants in combination with maxillary sinus floor elevation using a lateral approach is a predictable treatment option showing high medium-term implant survival rates and low incidences of complications.⁷ However, the lateral approach to the sinus entails elevation of a large mucoperiosteal flap that affects postoperative recovery of the patient and the additional expense of the augmentation procedure.⁹ Schneiderian membrane perforations, nose bleeding, postoperative pain and swelling could be considered major risks.¹⁰ The elevation of the maxillary sinus floor through the alveolar crest (transalveolar) was first described by Tatum¹¹ and modified by Summers.¹² Subsequently, various modifications to the original technique have been reported, in order to improve the predictability and safety, such as the use of atraumatic lifting drills,¹³ membrane elevation via inflation of a balloon catheter,¹⁴ and the use of hydraulic¹⁵ or negative pressure.¹⁶

The aim of this clinical report was to present a novel self-tapping endosseous implant system (iRaise, Maxillent, Herzliya, Israel) developed for sinus augmentation. The advantage of this system is the ability to perform major sinus lift augmentation via a minimally invasive transcrestal approach and to simultaneously place an implant, with minimal patient discomfort and shortened treatment time.

Case presentation

A 63-year-old female patient presented with compromised fixed dental prostheses supported by failing teeth in her posterior maxilla (**Figs. 1 & 2**). The patient reported esthetic concerns and impairment of her masticatory function; consequently, she desired replacement of the prostheses. A cone beam computed tomography (CBCT) scan was performed to evaluate the amount of residual bone. On the right side, conventional implant placement was planned. However, on the left side, the distance from the maxillary crest to the sinus floor was 3.2 mm, requiring a bone augmentation procedure. After detailed consultation, various treatment options were discussed with the patient. Closed major sinus floor augmentation with a transcrestal approach using the iRaise implant system was planned for the maxillary left first molar position to support a screw-retained fixed dental prosthesis. An adjunctive implant was planned for the maxillary left first premolar position.

The day before the implant placement, the patient underwent intranasal spray therapy (thiamphenicol glycinate acetylcysteinate, 810 mg/4 mL) b.i.d. One hour before surgery, a single dose of antibiotic (2 g of amoxicillin and clavulanic acid) was administered prophylactically. A 0.2% chlorhexidine mouthwash was administered for 1 min prior to the implantation procedure.

Local anesthesia was administered (articaine with 1:100,000 epinephrine) and a small full-thickness mucoperiosteal flap was elevated. A 2 mm diameter round bur was used to mark the implant site. The osteotomy was prepared with a 2 mm twist drill 1 mm below the sinus floor. A periapical radiograph with a depth guide was performed in order to verify the drilling angle and depth, as well as the distance to the sinus floor. The implant recipient site was wide-

Fig. 1

Preoperative panoramic radiograph.

Fig. 2

Alveolar ridge before implant placement (occlusal view).