

Journal of

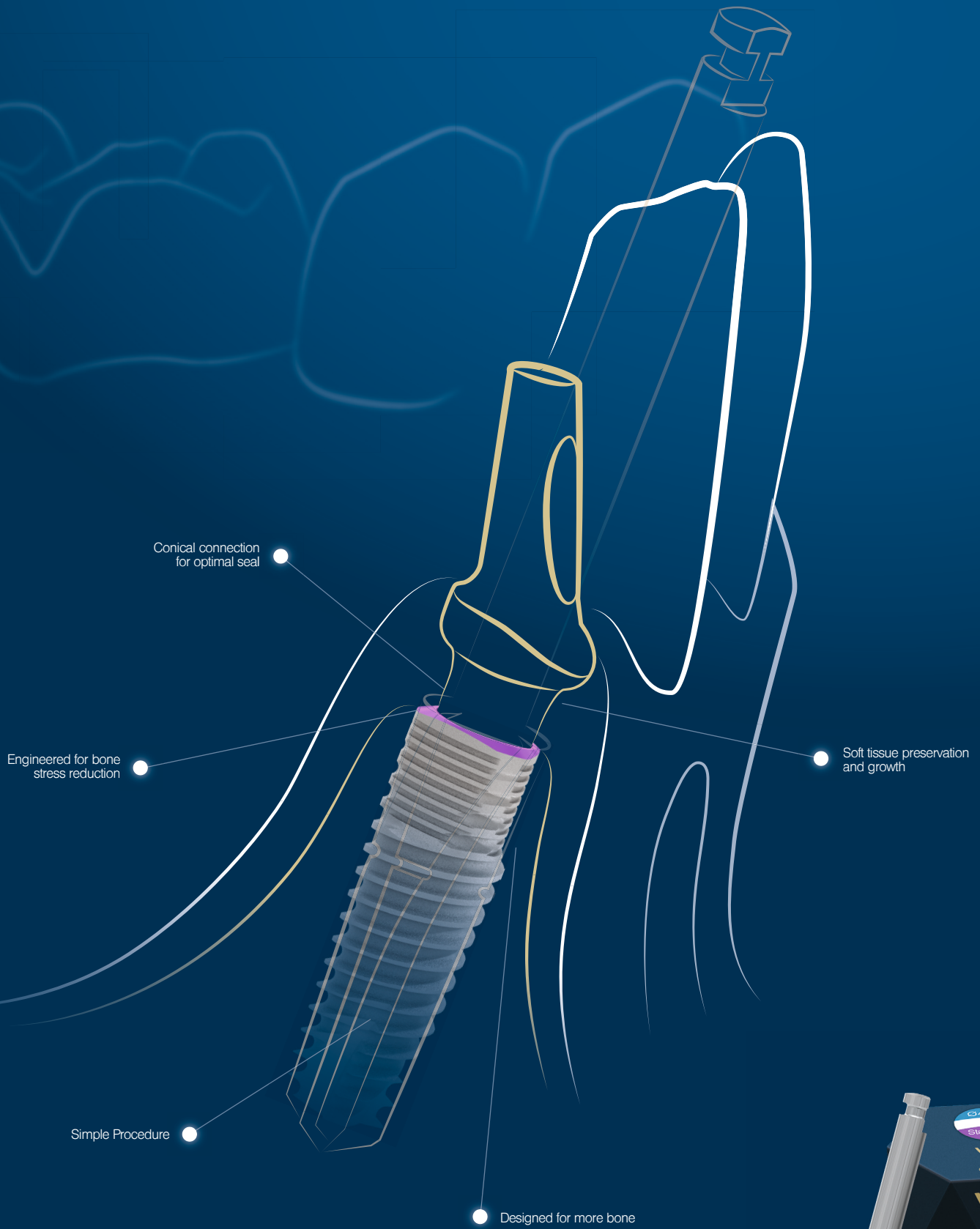
Oral Science & Rehabilitation

Journal for periodontology, implant dentistry,
dental prosthodontics and maxillofacial surgery

ISSN 2365-6123 (Print)
ISSN 2365-6891 (Online)

Volume 4 — Issue 1/2018

dti | Dental
Tribune
International



MAKE IT SIMPLE. WE KNOW HOW!

The MIS V3 Implant System was designed to offer immediate biological benefits and improved performance, while keeping surgical procedure simple. Learn more about the V3 implant and MIS at: www.mis-implants.com

mis® | V3

Journal of

Oral Science & Rehabilitation

Flap detachment and retraction in periapical surgery

In many cases, periapical surgery is required instead of tooth extraction and implant placement. In this regard, flap detachment and retraction, affording adequate access to the periapical lesion with good visualization of the surgical field, is crucial in order to ensure meticulous, rapid and correct periapical surgery and treatment success. This in turn avoids damage to the surrounding soft tissue and neurovascular elements, allowing adequate ostectomy, with the sutures resting on hard tissue.

The raising of the flap and traction must be carried out firmly but gently in order to minimize trauma. The sulcus technique, described in apicoectomy of the mandibular premolars, allows safe stabilization of the retractor supported on the bone without harming the surrounding tissue. Adequate soft-tissue management not only results in a better postoperative course, with less pain and inflammation, but also guarantees optimum wound healing. Furthermore, an adequate flap design will increase the efficiency of surgery, resulting in a shorter operating time.

Flap detachment and retraction is fundamental in periapical surgery, but in the past has not been well addressed from the teaching perspective in the books and articles published on this subject. It is important for dental surgeons to learn, use and trust these techniques in order to adequately decide when and when not to indicate dental implant placement.

Dr. Miguel Peñarrocha Diago
Editor-in-Chief

03

Editorial

Dr. Miguel Peñarrocha Diago

06

About the Journal of Oral Science & Rehabilitation

08

Luigi Canullo

Sinus lift surgery in severely resorbed maxillae: One-year follow-up

16

Alexandre Perez et al.

Immediate implants in the esthetic area: Our perspective and clinical guidelines

24

Juan Cervera Ballester et al.

New perspectives in periapical surgery: Flap detachment and retraction

32

Luca Sbricoli et al.

Influence of abutment material and detersion protocol on bacterial adhesion: An in vitro study

38

Marcus Seiler et al.

Individualized CAD/CAM produced titanium scaffolds for alveolar bone augmentation: A retrospective analysis of dehiscence events in relation to demographic and surgical parameters

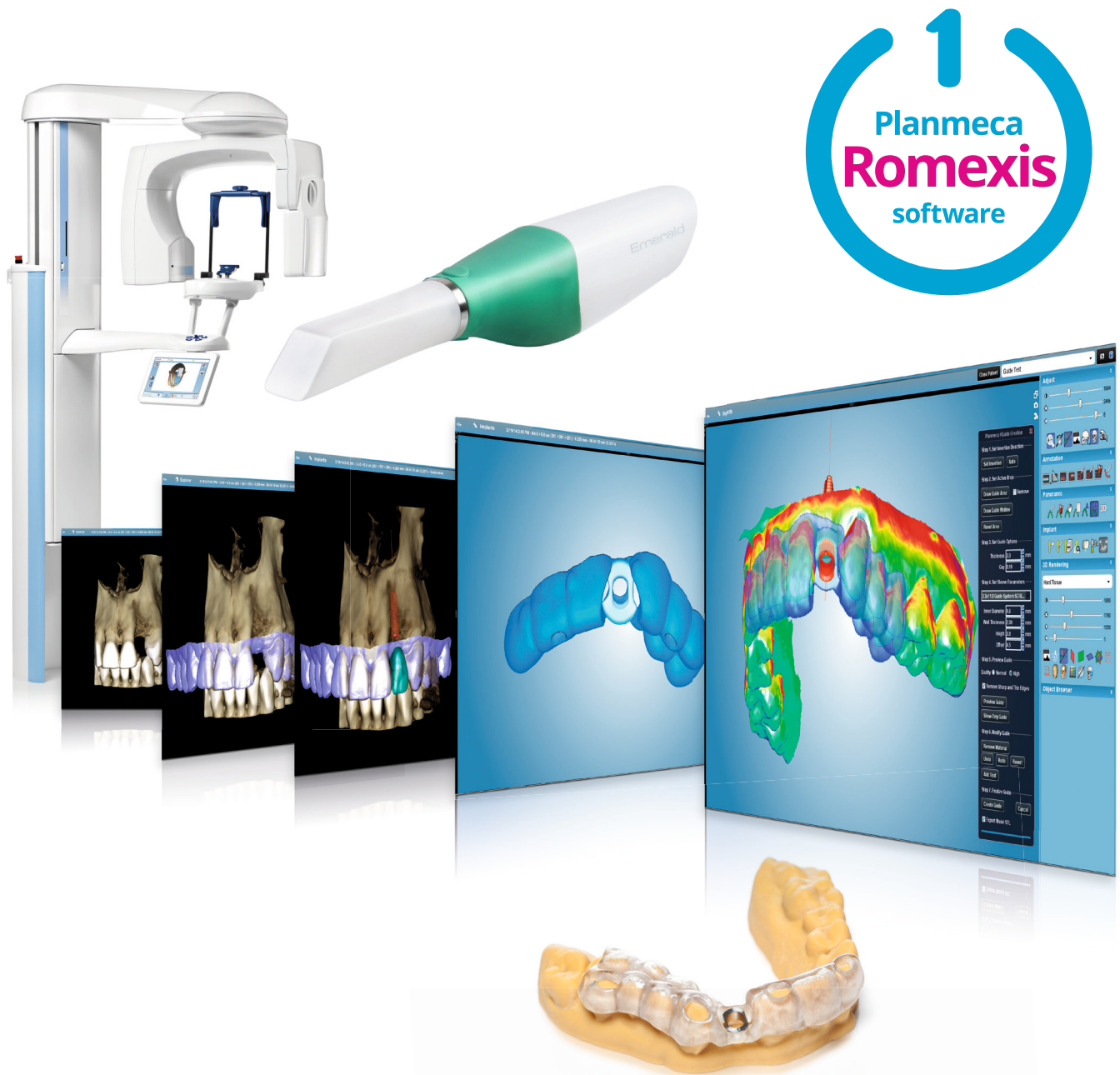48

Guidelines for authors

50

Imprint — about the publisher

The complete implant workflow – easiness with **one software**



Taking an implant plan to actual surgery is now easier than ever!
From imaging to implant planning and guide design, all workflow steps
can be controlled and completed in the **Planmeca Romexis®** software.

Find more info and your local dealer!

www.planmeca.com



PLANMECA

About the Journal of Oral Science & Rehabilitation

The aim of the *Journal of Oral Science & Rehabilitation* is to promote rapid communication of scientific information between academia, industry and dental practitioners, thereby influencing the decision-making in clinical practice on an international level.

The *Journal of Oral Science & Rehabilitation* publishes original and high-quality research and clinical papers in the fields of periodontology, implant dentistry, prosthodontics and maxillofacial surgery. Priority is given to papers focusing on clinical techniques and with a direct impact on clinical decision-making and outcomes in the above-mentioned fields. Furthermore, book reviews, summaries and abstracts of scientific meetings are published in the journal.

Papers submitted to the *Journal of Oral Science & Rehabilitation* are subject to rigorous double-blind peer review. Papers are initially screened for relevance to the scope of the journal, as well as for scientific content and quality. Once accepted, the manuscript is sent to the relevant associate editors and reviewers of the journal for peer review. It is then returned to the author for revision and thereafter submitted for copy editing. The decision of the editor-in-chief is made after the review process and is considered final.

About Dental Tribune Science

Dental Tribune Science (DT Science) is an online open-access publishing platform (www.dtscience.com) on which the *Journal of Oral Science & Rehabilitation* is hosted and published.

DT Science is a project of the Dental Tribune International Publishing Group (DTI). DTI is composed of the leading dental trade publishers around the world. For more, visit

www.dental-tribune.com



Benefits of publishing in the journal for authors

There are numerous advantages of publishing in the *Journal of Oral Science & Rehabilitation*:

- Accepted papers are published in print and as e-papers on www.dtscience.com.
- Authors' work is granted exposure to a wide readership, ensuring increased impact of their research through open-access publishing on www.dtscience.com.
- Authors have the opportunity to present and promote their research by way of interviews and articles published on both www.dtscience.com and www.dental-tribune.com.
- Authors can also post videos relating to their research, present a webinar and blog on www.dtscience.com.

Subscription price

€50.00 per issue, including VAT and shipping costs.

Information for subscribers

The journal is published quarterly. Each issue is published as both a print version and an e-paper on www.dtscience.com.

Terms of delivery

The subscription price includes delivery of print journals to the recipient's address. The terms of delivery are delivered at place (DAP); the recipient is responsible for any import duty or taxes.

Copyright © Dental Tribune International GmbH. Published by Dental Tribune International GmbH. All rights reserved. No part of this publication may be reproduced, stored or transmitted in any form or by any means without prior permission in writing from the copyright holder.

Sinus lift surgery in severely resorbed maxillae: One-year follow-up

Abstract

Objective

The aim of this prospective study was to clinically analyze the behavior of implants inserted into severely resorbed maxillae after sinus grafting.

Materials and methods

Twenty-six wide-diameter implants with a rough surface over their entire length were inserted during 13 consecutive sinus lifts. Radiographic analysis was preoperatively requested for each patient. After Schneiderian membrane elevation, a magnesium-enriched hydroxyapatite (Mg-e HA) and collagen-based scaffold with a porous 3-D structure was used to prevent perforation during implant placement. Sinus grafting was performed using a biomimetic Mg-e HA. No membrane was used to cover the buccal window. The preoperative residual bone height ranged between 1 and 4 mm (mean value: 2.5 mm; SD: 1.0 mm).

After 6 months of healing, uncovering was carried out and the definitive restoration was seated after 2 weeks. In order to monitor the stability changes, resonance frequency analysis was performed and ISQ (Implant Stability Quotient) values were collected at the first surgery (baseline, T_0), at the abutment connection (T_1) and at the 1-year follow-up (T_2).

In order to measure bone changes, the patients underwent panoramic radiographs after 2-year follow-up. Image analysis software calculated the grafted bone height changes at the level of the implant site, comparing preoperative and follow-up panoramic radiographs.

Results

No postoperative complications were observed. The mean ISQ value was 42.5 (SD: 2.7) at T_0 , 75.3 (SD: 8.2) at T_1 and 81.5 (SD: 2.6) at T_2 . Statistically significant differences ($P \leq 0.005$) regarding mean ISQ values were found between T_1 and T_0 , as well as between T_1 and T_2 . After 12 months of functional loading, only 1 implant was lost (cumulative survival rate: 96.15%). During the same observation period, the mean radiographic vertical height of the grafted sinus floor was 11.05 mm (SD: 2.10 mm), with a mean gain of 8.50 mm.

Conclusion

Within the limitations of this study, despite preoperative critical residual bone height, maxillary sinus lift restoration using a biomimetic Mg-e HA and an Mg-e HA/collagen-based scaffold with a porous 3-D structure seems to be a reliable procedure.

Keywords

Sinus lift, magnesium enriched hydroxyapatite, x-ray analysis, ISQ.

Luigi Canullo^a

^a Private practice, Rome, Italy

Corresponding author:

Dr. Luigi Canullo

Via Nizza 46
00198 Rome
Italy

T +39 06 8411980
luigicanullo@yahoo.com

How to cite this article:

Canullo L. Sinus lift surgery in severely resorbed maxillae: one-year follow-up. J Oral Science Rehabilitation. 2018 Mar;4(1):08–14.

Introduction

Sinus floor augmentation has recently become a widely accepted surgical procedure to improve the amount of bone volume before implant placement. Although the use of autogenous bone appears to be the gold standard,^{1,2} much attention has been paid to the use of bone substitutes. After the harvesting procedure, donor site morbidity has to be taken into consideration.³ Additional disadvantages for autografts are the limited availability and the tendency to resorb.⁴ In order to overcome these limitations, several biomaterials have been evaluated in experimental and clinical studies, such as demineralized freeze-dried bone allograft,⁵ bovine bone matrix,⁴ composite bone graft including platelet-rich plasma,⁶ resorbable and nonresorbable hydroxyapatite^{7,8} and beta-tricalcium phosphate.⁹ In particular, bioceramics based on calcium phosphate are widely used owing to their biocompatibility, absence of immunogenic factors and osteoconductivity; although, the high temperature during the sintering process could negatively influence osteoconductivity and resorption time.¹⁰ New hydroxyapatites enriched with magnesium (Mg-e HAs) have recently been introduced on the market. Mg-e HA has been demonstrated to allow complete healing of the tissue around a graft and undergoes almost complete resorption already after 1 year.¹¹ Despite its high predictability, the more recent literature has highlighted possible complications after this procedure.¹² The main complication is membrane perforation, mostly during implant insertion. Mg-e HA/collagen-based scaffolds have been successfully used for sinus augmentation procedures, demonstrating bone formation after 6 months already.¹³ Owing to its properties, this material might be suitable to protect the sinus membrane from eventual perforation during implant insertion.

The present preliminary prospective study was designed to evaluate clinically and radiologically implant restorations 12 months after prosthetic loading in severely resorbed maxillae requiring 1-stage sinus lift surgery. The graft used was an Mg-e HA and Mg-e HA/collagen-based scaffold with a porous 3-D structure and was used to prevent Schneiderian membrane perforation.

Materials and methods

Study design and patient selection

One dental center consecutively recruited 13 patients scheduled for implant-supported

restoration in the posterior maxilla with a sinus augmentation procedure. A total of 26 wide-diameter implants with a rough surface over their entire length were inserted in extremely resorbed posterior maxillae. The present study was performed following the principles outlined in the Declaration of Helsinki of 1975, as revised in 2013, on experimentation involving human subjects. All of the patients were in general good health. They were informed about the procedure and required to sign a consent form. They were followed for a period of 12 months after prosthetic rehabilitation. The principal inclusion criterion was a residual bone crest (distance between the sinus floor and bone crest) ranging between 1 and 3 mm in height and allowing wide-diameter implant insertion. Additional inclusion and exclusion criteria are summarized below:

Subject inclusion criteria:

- Need for fixed implant-supported prosthesis in the posterior maxilla.
- Aged > 18 years.
- No relevant medical conditions.
- Nonsmoker or smoked ≤ 10 cigarettes/day (pipe or cigar smokers were excluded).
- Full-mouth plaque score and full-mouth bleeding score of ≤ 25%.

Study site inclusion criteria:

- Native bone height of 1–3 mm in the sinus zone.

Subject and site exclusion criteria:

- Acute infection of the Schneiderian membrane or chronic sinusitis.
- Allergies involving the respiratory system.
- A history of bisphosphonate therapy.
- Uncontrolled diabetes (glycated hemoglobin A_{1c} > 6%, glycemic level > 110 mg/dL).

Preoperative and postoperative medication

The patients underwent a preoperative digital panoramic radiograph, subsequently used as baseline. A cone beam computed tomography scan was also required to investigate antral anatomy (**Fig. 1**). One week before the surgical procedure, full-mouth professional prophylaxis was performed. The patients were instructed to use 1 g of penicillin clavulanate 1 day prior to surgery and continue with 2 g per day for 6 days. Just before surgery, the patients underwent a 5-min mouth rinse with 0.2% chlorhexidine gluconate.