
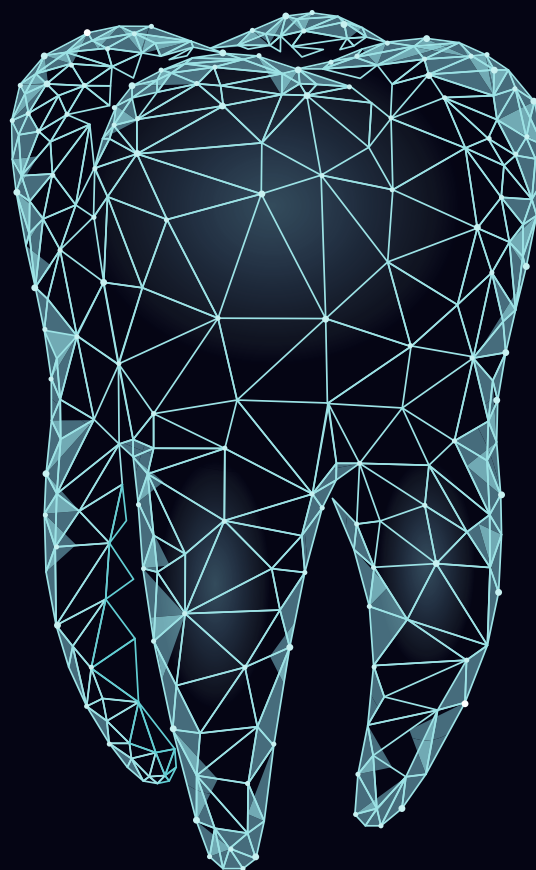


digital

international magazine of digital dentistry



trends & applications

Digital dentistry in daily practice

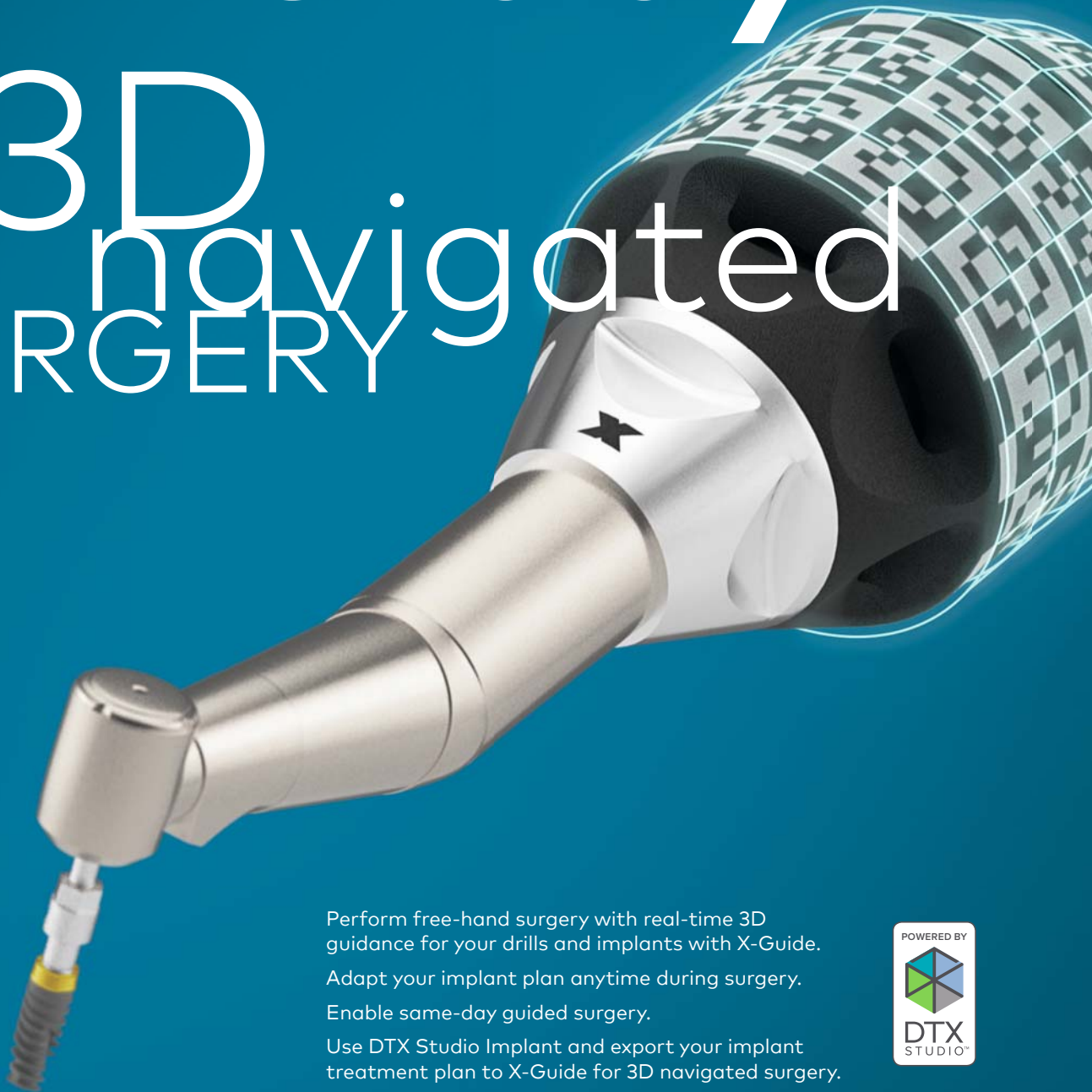
case report

Digital workflow versus conventional approach in aesthetic dentistry

feature

Dental startups are harnessing artificial intelligence

Same-day 3D navigated SURGERY



Perform free-hand surgery with real-time 3D guidance for your drills and implants with X-Guide.
Adapt your implant plan anytime during surgery.
Enable same-day guided surgery.
Use DTX Studio Implant and export your implant treatment plan to X-Guide for 3D navigated surgery.



nobelbiocare.com/x-guide

GMT 63673 GB 1907 © Nobel Biocare Services AG, 2019. All rights reserved. Distributed by: Nobel Biocare. X-Guide is either registered trademark or trademark of X-Nav Technologies, LLC in the United States and/or other countries. Nobel Biocare, the Nobel Biocare logotype and all other trademarks are, if nothing else is stated or is evident from the context in a certain case, trademarks of Nobel Biocare. Please refer to nobelbiocare.com/trademarks for more information. Product images are not necessarily to scale. All product images are for illustration purposes only and may not be an exact representation of the product. Disclaimer: Some products may not be regulatory cleared/released for sale in all markets. Please contact the local Nobel Biocare sales office for current product assortment and availability. For prescription use only. Caution: Federal (United States) law restricts this device to sale by or on the order of a licensed clinician, medical professional or physician. See Instructions For Use for full prescribing information, including indications, contraindications, warnings and precautions.

Dr Scott D. Ganz

Editor-in-Chief



digital is here!

What a great way to start off 2020! You might have noticed: our new name is **digital**! How great is that? It was a necessary change to encompass everything that we do today, to provide a platform for an exchange of ideas among the finest clinicians, researchers, educators, and much more, a platform that reflects the state-of-the-art in dentistry today. As I like to start many of my own presentations, there is a danger when we are bound by 2D concepts, when we truly live in a 3D world. Digital allows us all to communicate globally with a universal language that connects us all, the general practitioner, restorative dentist, surgical specialist, prosthodontist, paediatric dentist, orthodontist, oral and maxillofacial radiologist, dental laboratory technician, auxiliaries, and more.

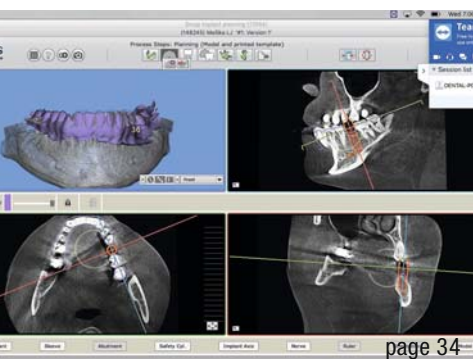
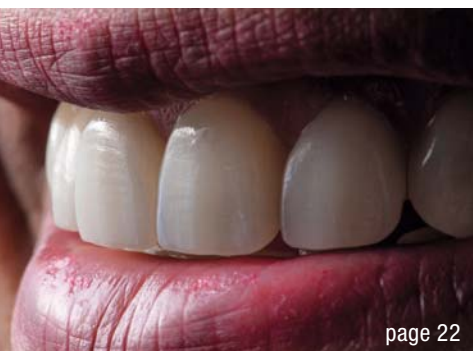Digital represents the evolution from the analogue modalities of Dr G.V. Black as incorporated in the curriculum of every dental school worldwide to perhaps unforeseen technological advances of today that have dramatically changed how we deliver care to our patients. Digital allows us to capture the intra-oral condition of a patient's occlusion without costly impression material, to visualise the result on a high-resolution LCD computer monitor and to utilise sophisticated software tools to diagnose, plan treatment and virtually simulate a smile design—to the amazement of our patients. Digital then allows us to virtually produce state-of-the-art CAD/CAM restorations with new and improved materials, a long way from the lost wax method of casting metal for metal-ceramic crown and bridgework. Digital allows a patient with malpositioned teeth to see a computer-driven simulation of how his or her teeth can be moved into the cor-

rect functional and aesthetic positions and then through rapid prototyping 3D printing modalities achieve these results with a series of wearable aligners.

Digital represents tremendous advances in the assessment of patients' individual and unique anatomy through cone beam computed tomography (CBCT) to diagnose potential pathology, to appreciate proximity of vital structures when planning for dental implants, to assess temporomandibular joint disorders, to plan for third molar extractions and bone grafting, and much more. The ability to then merge the data sets of a CBCT scan and an intra-oral scan enhances the clinician's diagnostic capability to fabricate static surgical guides, or as the foundation for dynamic navigation, greatly improving implant placement based upon a truly restoratively driven plan. Can we imagine placing implants without 3D imaging today? Digital finally allows for a seamless platform for the clinician to communicate and interact with the dental laboratory technician, who is crucial to changing the quality of life of our patients.

How can we be educated on our new universal language? Within the pages of this first issue of 2020, you will find articles by some of the best and brightest that illustrate these concepts, helping us to move from the constraints of two dimensions into the unlimited potential of the 3D world. Enjoy our first issue of **digital** in 2020!

Respectfully,
Dr Scott D. Ganz
Editor-in-Chief



Cover image:
LuckyStep | Shutterstock.com



editorial

digital is here!

Dr Scott D. Ganz

03

trends & applications

Digital dentistry in daily **practice**

Dr Edouard Lanoiselée

16

education

The integration of CAD/CAM into **dental school curricula**

Brendan Day

10

case report

Digital workflow versus conventional approach in **aesthetic dentistry**

Dr Florin Lăzărescu

14

A new smile in one **day**

Dr Gustavo Harfagar

22

The copyCAD

Dr Yassine Harichane

26

Immediate post-extraction implants in the anterior maxilla

Drs Gian Battista Greco & Danilo Alessio Di Stefano

30

Digital workflow with a metal-free surgical guide and **zirconia implant**

Dr Saurabh Gupta

34

Treatment of an **edentulous space** with a **digital workflow**

Prof. Heinz Kniha, Thomas Lassen & Dr Kristian Kniha

38

special report

Digitally fabricated bulb obturator using **virtual data** and 3D printing

Dr Tariq Saadi

42

manufacturer news

48

feature

Dental startups are harnessing **artificial intelligence**

Jeremy Booth

52

practice management

“As dental coaches, we are servants in a noble profession”

An interview with Kirk Behrendt

56

meetings

Nobel Biocare Global Symposium 2020 postponed to **early 2021**

58

about the publisher

submission guidelines

60

international imprint

62

[DIGITAL]

Virtuo Vivo™

Capture each note.



SCANNING IN
REAL COLOR.

SMALL
AND LIGHT
HANDPIECE.

REMOVABLE
AND AUTO-
CLAVABLE
SLEEVES.



Contact your local Straumann representative
now or visit www.straumann.com.

A0019/en/A/00™ 03/20

 **straumann**

Digital dentistry in daily practice

Dr Edouard Lanoiselée, France

How can a patient's treatment be optimised? How can both speed and efficiency be increased without sacrificing quality? These questions are constantly being asked in our practices. Our patients' demands are becoming increasingly advanced in terms of aesthetic and functional results, yet they have ever less time to dedicate to treatments. We now have a great deal of equipment at our disposal that enables this optimisation. Many of these tools are digital and as such allow us to digitise our patient files in order to transfer as much information as possible to the prosthetic laboratory. This information can thus be prioritised and streamlined to be processed in the laboratory by the appropriate people in the respective field (modelling, ceramic coating, etc.). In this effort to

centralise information, colour is a complex area that requires extensive resources in terms of information. It is usually assessed in the chair by means of comparison of the patient's teeth to one or more shade guides. This reading is influenced by many factors, and results can be significantly affected by surrounding interference (brightness of the room, bright colour of lipstick, etc.), making it particularly subjective.^{1, 2}

Dental photography is now considered an excellent way to convey colour information. It requires the prosthetist to use a shade guide as a reference to ensure that the information is as objective as possible. Working with dental photography, however, increases working time, as the prosthetist has to perform map-

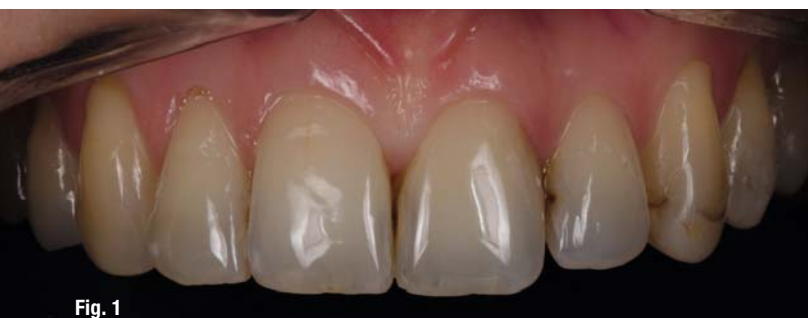

Fig. 1

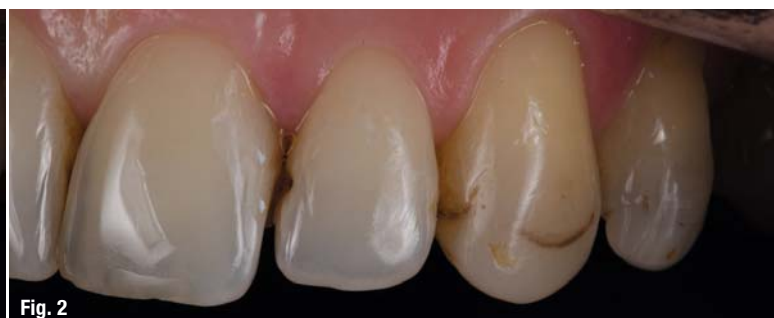

Fig. 2

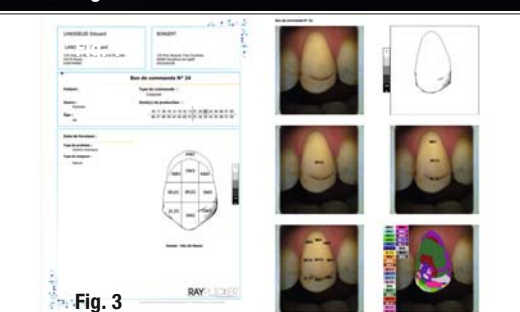


Fig. 3

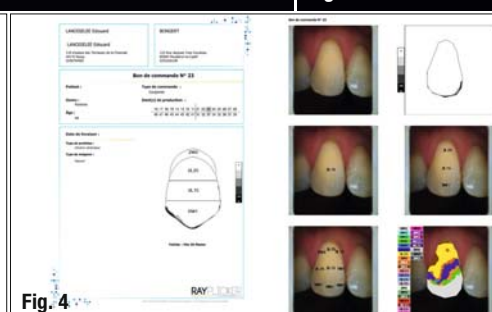


Fig. 4

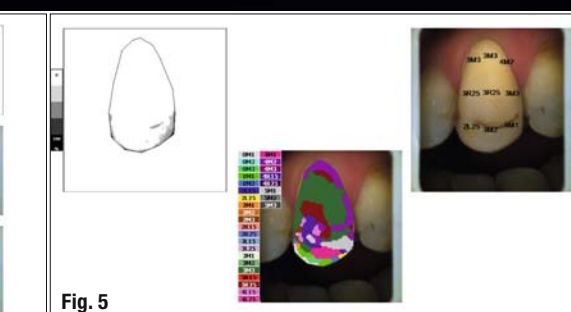


Fig. 5

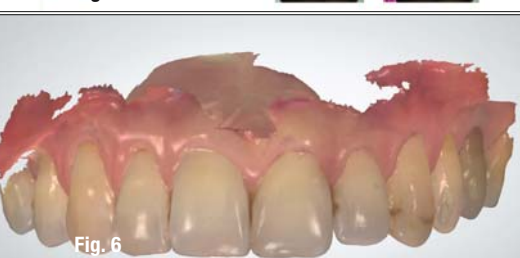

Fig. 6

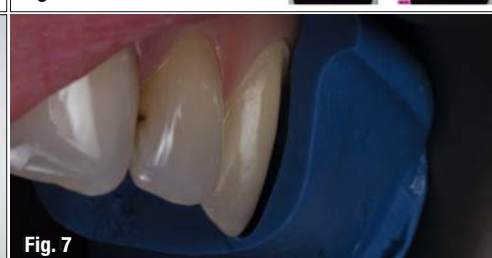

Fig. 7

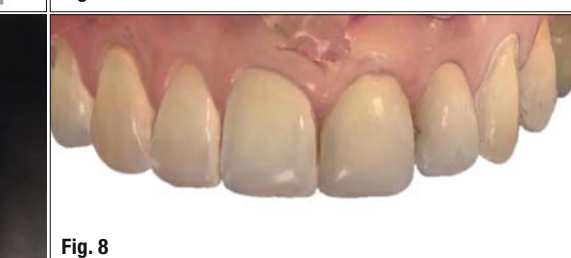

Fig. 8

Figs. 1 & 2: Initial situation: teeth #22 and #23 required restoration. **Fig. 3:** Colour reading sheet on the tooth to be treated. **Fig. 4:** Colour reading sheet on the contralateral tooth. **Fig. 5:** Translucency, detailed (pixel by pixel) and 9 parts shade mappings. **Fig. 6:** Optical impression. **Fig. 7:** Reduction control. **Fig. 8:** Optical impression of the preparation (with TRIOS 4, 3Shape).

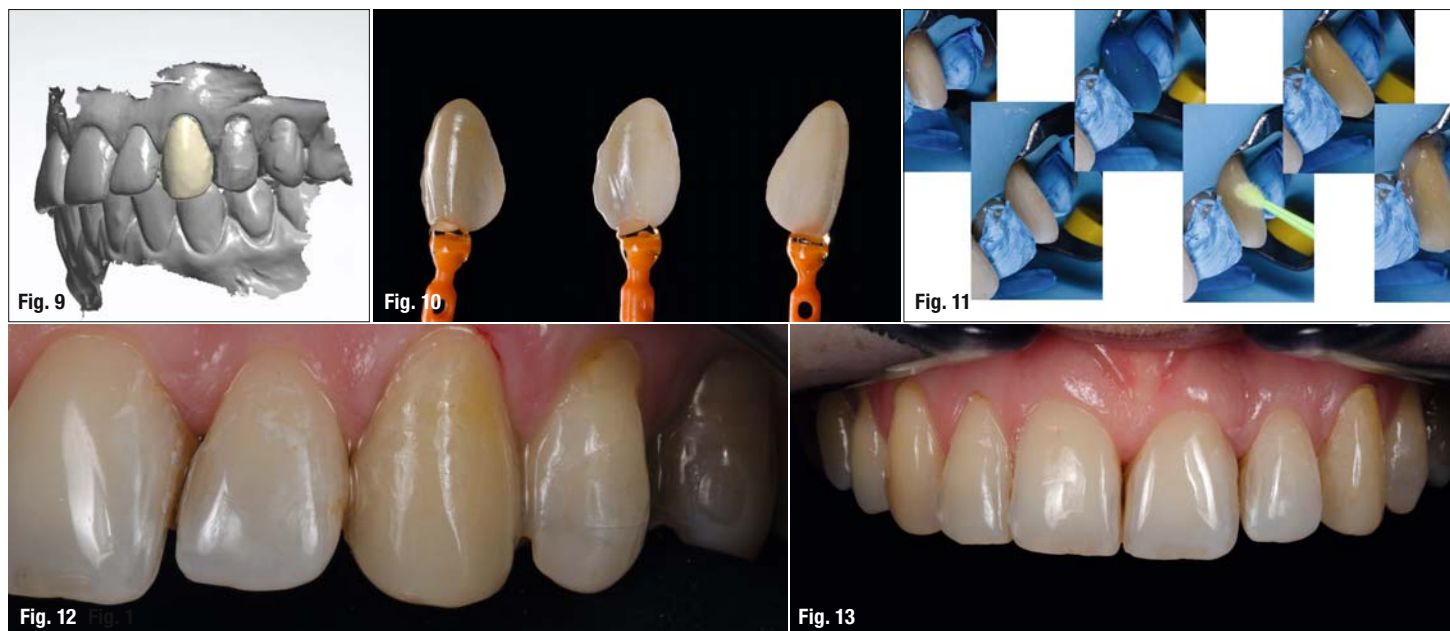


Fig. 9: Modelling of the restoration (with Dental System, 3Shape). **Fig. 10:** The veneer, ready to be seated in the patient's mouth. **Fig. 11:** Seating of the final restoration under dental dam isolation. **Fig. 12:** Final situation immediately after removal of the dental dam. **Fig. 13:** Check-up at four months.

ping based on the information obtained from the photographs. Moreover, cameras are sensitive to shade variations, depending on the colour temperatures predetermined by the camera, which can skew this reading.³ To counter this problem, spectrophotometers are currently the best tools we have to objectify a result. They work by emitting calibrated light which, depending on the reflection registered, enables a colour reading to be taken. This reading is unaffected by environmental factors that could potentially skew its results (lipstick, colourful clothing, unsuitable lights, etc.).^{4, 5}

Some models allow a photograph to be taken with mapping of the tooth, which enables the prosthetist to be guided more effectively in the process of creating the prosthesis. The sheet is then stored on the software and can be processed and archived in a patient file. The Raypickler (Borea) is a device that allows the practitioner to record all the information collected and communicate it to the prosthetic laboratory. The laboratory sheet can be sent via a secure portal and reprocessed by the prosthetic laboratory. This flow enables the form to be marked as reviewed by the laboratory, in order to monitor the progress of the treatment from the practice. Most shade guides on the market are referenced, making the work easier for the laboratory.

Clinical case

The patient attended the practice for replacement of the restoration on tooth #23, which she found un-

sightly. The clinical examination revealed the presence of a composite restoration on the vestibular surface of tooth #23 with a stained joint, as well as the presence of early carious lesions on the neighbouring teeth (Figs. 1 & 2). After discussing treatment options with the patient, it was decided on composite restorations for the carious lesion and a veneer for tooth #23. However, there was a constraint that made this case more difficult: the patient had to go abroad for three months and needed the work to be done within ten days of accepting the treatment.

The first step in the treatment was registering the colour, performed using the Raypickler. A reading was taken of the tooth to be restored and of the contralateral tooth (Figs. 3 & 4). This double reading would give the prosthetist information not only on the tooth to be restored but also on the overall integration of this tooth. The readings were sent to the laboratory via a secure server. The important information for creating the restoration is centralised on this sheet: translucency, detailed mass mapping and the shade guide values (Fig. 5).

As the treatment did not require any modification of shape, it was decided to use the initial situation as a reference for the laboratory, and an optical impression was taken, which would guide the laboratory in the design of the veneer (Fig. 6). A reduction guide was then made with silicone and the tooth was prepared (Fig. 7). The thickness would be checked at the end of preparation with this key, which enables the ceramic thickness, the homogeneity and the homothety of the preparation to be checked.

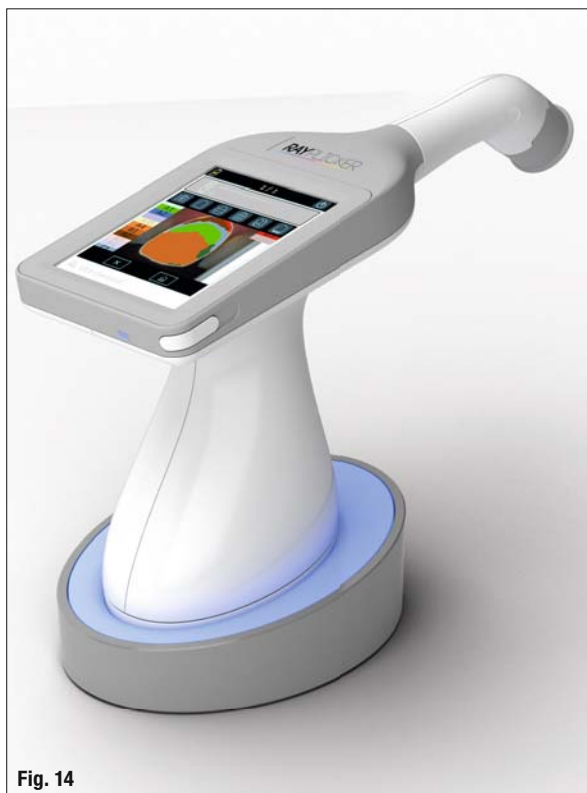

Fig. 14

Fig. 14: Spectrophotometer Raypicker developed by BOREA.

The optical impression of the preparation was then performed (Fig. 8). To do this, tooth #23 was erased on the initial impression and then the area was registered. This would enable the impressions to be merged easily in the laboratory to control the modelling process. All the information was then sent to the laboratory (shade sheet and optical impression). In both cases, the files were sent via a secure portal with the option of verifying receipt by the dental surgeon. The veneer was then modelled in the Dental System software (3Shape; Fig. 9) and then printed in burnout resin on a 3D printer. It was then processed conventionally using the pressed ceramic technique, as the fineness of the veneer is not easily compatible with a machining technique (Fig. 10).

After curettage and sealing of the lesion on tooth #22, the veneer was placed with a try-in paste (Fig. 11). The patient confirmed the result, and then the veneer was glued on to the tooth. Only light-polymerised glue (G-CEM veneer, GC) is used for this—the advantage of this type of glue is the longer working time and therefore the management of excess glue, which is easier to remove. After thorough polishing, the dental dam was removed and a final polish was performed (Fig. 12).

The patient was seen again at four months, when she returned from abroad for a check-up. The teeth were

rehydrated and the periodontal tissue that had been pushed in when the dam was put in place had resumed its original position (Fig. 13). It was evident that the restoration had integrated well.

The use of digital techniques means that it is now possible to create simple and reproducible protocols. If the practitioner or prosthetist encounters difficulties, these can be analysed and resolved quickly. While shape can now easily be checked by the practitioner, colour is one of the crucial points to master during procedures. Spectrophotometers such as the Raypicker now offer a simple, fast and effective solution. The secure platform facilitates interaction between the practice and the prosthetic laboratory, as well as confirms receipt of documents, centralises information and provides the option of enhancing the content with photographs clarifying the surface qualities and characterisations required for the integration of the prosthesis. All these elements combined deliver qualitative and rapid results in line with patients' expectations.

Editorial note: A list of references is available from the publisher.

about



Dr Edouard Lanoiselée graduated from the Faculty of Dentistry of the University of Nantes in France and later obtained a master's degree in medical sciences. He worked as a university hospital assistant at the teaching and research centre of the Nantes university hospital in the prosthetic department.

He is the coordinator of the aesthetic dental restoration university degree at the University of Nantes and a consultant to the implantology department of Nantes university hospital. Dr Lanoiselée is a CAD/CAM specialist and a partner at a general dental practice in Nozay in France.



Digital Implant Workflow

Streamlined collaboration for your treatment team

From data capturing, planning and guided surgery to the final restorative solutions, with the Digital Implant Workflow from Dentsply Sirona you have all the support you need to save time, deliver predictable results and provide your patients with the best possible care.

Follow Dentsply Sirona Implants



dentsplysirona.com/implants

