

FOR THE
DENTAL PROFESSIONALS

DENTAL TRIBUNE

—The World's Dental Newspaper · Middle East & Africa Edition—

PUBLISHED IN DUBAI

www.dental-tribune.me

September-October 2016 | No. 5, Vol. 6

HYGIENE TRIBUNE

To floss or to brush—that is the (interdental) question

Subgingival air polishing: A new method

►Insertion

ENDO TRIBUNE

Endo Meets 3D

“Find it, fix it, and leave it alone”

►Insertion

LAB TRIBUNE

Minimally invasive prosthetic treatment with various...

3Shape CAD/CAM in a major Dental Lab

►Insertion

IMPLANT TRIBUNE

Ten facts about dental implants

CBCT zones of the jaw

►Insertion

ORTHO TRIBUNE

Invisible braces market to grow rapidly over next five years

DT launches new international ortho magazine

►Insertion

The 1st Emirates Paediatric Dentistry Club Conference

By EPDC

DUBAI, UAE: The Emirate Paediatric Dentistry Club (EPDC) has the great honor of hosting the regional Congress of the International Association of Paediatric Dentistry (IAPD) March 1 - 3, 2017. We are committed to make this joint EPDC first dental conference and the prestigious IAPD conference in Dubai, United

Arab emirates a very successful and a memorable conference. This will be the first meet of IAPD in the middle-east region.

The theme of IAPD Dubai 2017 is Bright Smiles into the Future and this conference will present a very comprehensive scientific program highlighting the latest evidence-based research and clinical topics

in the field of paediatric dentistry. These up-to-date topics will be delivered by high profile and renowned international speakers including: Prof Tim Wright (USA), Dr Bill Waggoner (USA), Prof Jorge Luis Castillo (Peru), Prof Richard Wellbury (UK), Prof Zafer Cehreli (Turkey), Dr Aziza



►Page 2 Board Members of the Emirates Paediatric Dentistry Club and CAPP Team Members (the Organizer)

AMD LASERS®
EFFECTIVE. PRACTICAL. AFFORDABLE. WORLD CLASS LASERS.

PICASSO LITE+ (NEW!)

PICASSO+ (NEW!)

#1 Lasers in the World

GLOBE
step into the Future

TAMER
DROGUERIE

دبي للمعدات الطبية ذ.م.ك.
Dubai Medical Equipment L.L.C.

GLOBE
ADDRESS: 11, EL OBOUR BUILDINGS, OROUBA AV. HOLIOPOLIS, CAIRO, EGYPT
TELEFAX: +2024045621 - +2024010579
MOB: +2 01000 99 6265
WEBSITE: WWW.GLOBEEGYPT.NET
EMAIL: INFO@GLOBEEGYPT.NET

TAMER DROGUERIE
ADDRESS: BEIRUT-LEBANON
WEBSITE: WWW.TAMERHOLDING.COM
E-MAIL: DENTAL@TAMERHOLDING.COM
PHONE: 961.1.694 000
FAX: 961.1.694 777

DUBAI MEDICAL EQUIPMENT
UNITED ARAB EMIRATES
TEL. NO: +971 6 5308055
FAX NO: +971 6 5308077
MOB : +971 50 7370011
MOB : +971 55 4417490
DT_UAE@EMIRATES.NET.AE

866.999.2635 AMDLASERS.COM

◀Page 1



Dr. Sumaya Al Rubaei Board member of EPDC



Dr. Tarun Walia Board member of EPDC



Dr. Elias Berdouses and Dr. Manal Al Halabi Board members of EPDC

Aljohar (KSA) and will benefit paediatric dentists, dental students, general dental practitioners and other dental specialities. A pre-conference workshop on Primary Zirconia Crowns sponsored by NuSmile crowns and Pre-veneered Stainless Steel Crowns supported by 3M will also be held on 1st of March, 2017.

It gives us great pleasure to invite you all to the joint first EPDC and the



regional IAPD conference to be held in Dubai, the beautiful city in the United Arab Emirates. Please note that all registered participants will be entitled to free 2-year IAPD membership. Details of the congress can be found at www.epdc.ae.

The Centre for Advanced Professional Practices (CAPP) is the official event organizer. www.capp.ae

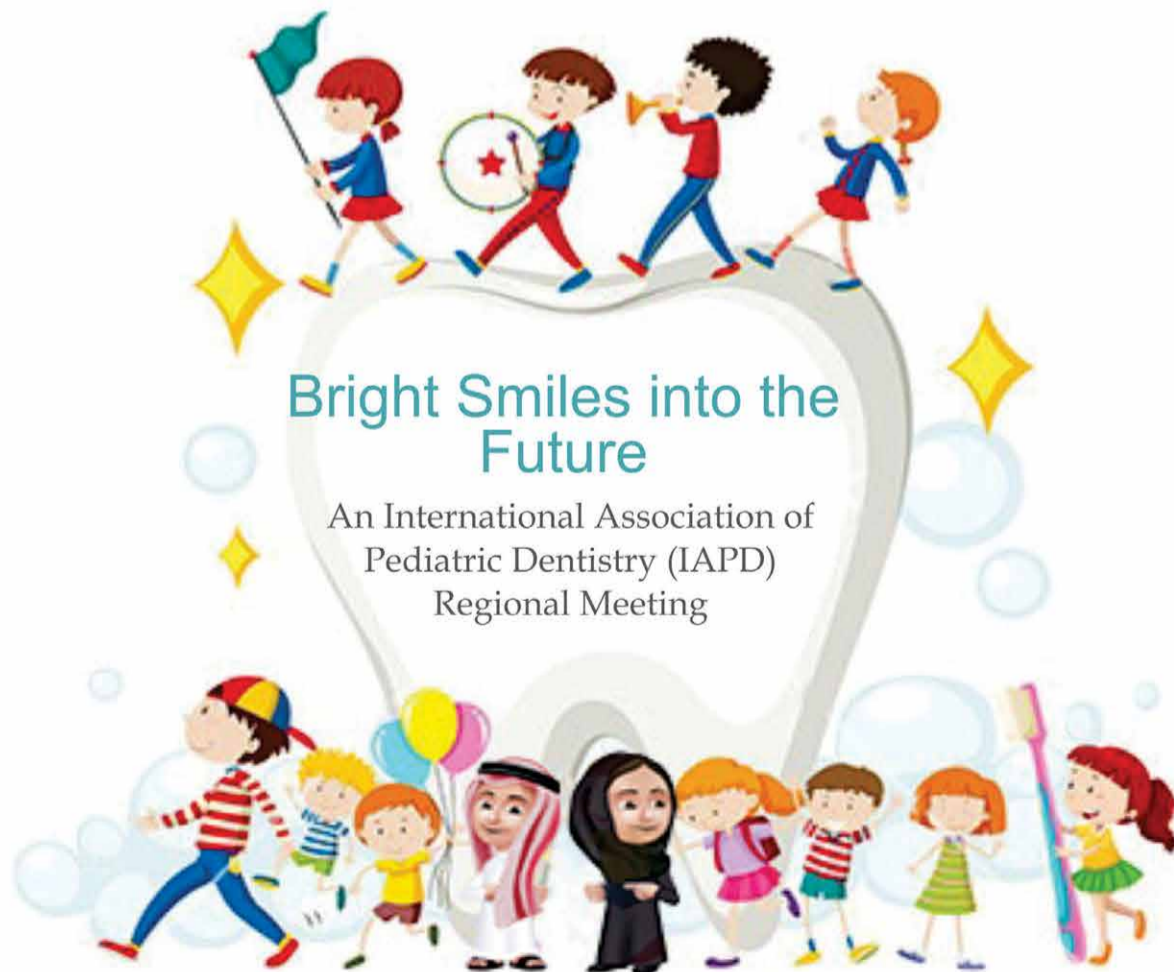

IAPD - Regional Meeting

&

The 1st Emirates Pediatric Dentistry Club Conference (EPDC)

March 1 - 3, 2017
Dubai, United Arab Emirates



Hands on workshops on 1st March, 2017
"Pediatric Zirconia Crowns and Primary Stainless Steel Crowns"

* SPEAKERS *

- * Prof. Tim Wright (USA) * Dr. Bill Waggoner (USA) * Prof. Jorge Luis Castillo (Peru)
- * Prof. Richard Welbury (UK) * Prof. Zafer Cehreli (Turkey) * Dr. Aziza Al Johar (Saudi Arabia)
- * Dr. Yousef Alawadhi (Kuwait) * Prof. Suhad Al Jundi (Jordan) * Dr. Catherine Hong (Singapore)
- * Dr. Ali Alehaideb (Saudi Arabia)

www.epdc.ae

IMPRINT

GROUP EDITOR
Daniel ZIMMERMANN
newsroom@dental-tribune.com
Tel.: +44 161 223 1830

CLINICAL EDITOR
Magda WOJTKIEWICZ

ONLINE EDITOR
SOCIAL MEDIA MANAGER
Claudia DUSCHEK

EDITORS
Anne FAULMANN
Kristin HÜBNER
Yvonne BACHMANN

COPY EDITORS
Sabrina RAAFF
Hans MOTSCHMANN

PUBLISHER/PRESIDENT/CEO
Torsten OEMUS

CHIEF FINANCIAL OFFICER
Dan WUNDERLICH

CHIEF TECHNOLOGY OFFICER
Serban VERES

BUSINESS DEVELOPMENT MANAGER
Claudia SALWICZEK-MAJONEK

EVENT SERVICES/PROJECT MANAGER
Sarah SCHUBERT

TRIBUNE CME & CROIXTURE
PROJECT MANAGER ONLINE
Tom CARVALHO

EVENT MANAGER
Lars HOFFMANN

EDUCATION MANAGER
Christiane FERRET

PR & COMMUNICATIONS MANAGER
Marc CHALUPSKY

MARKETING SERVICES
Nadine DEHMEL

SALES SERVICES
Nicole ANDRA

ACCOUNTING SERVICES
Karen HAMATSCHKE
Anja MAYWALD
Manuela HUNGER

MEDIA SALES MANAGERS
Matthias DIESSNER (Key Accounts)
Melissa BROWN (International)
Antje KAHNT (International)
Peter WITTECZEK (Asia Pacific)
Weridiana MAGESWKI (Latin America)
Maria KAISER (North America)
Hélène CARPENTIER (Europe)
Barbora SOLAROVA (Eastern Europe)

EXECUTIVE PRODUCER
Gernot MEYER

ADVERTISING DISPOSITION
Marius MEZGER

DENTAL TRIBUNE INTERNATIONAL
Holbeinstr. 29, 04229 Leipzig, Germany
Tel.: +49 341 48 474 302
Fax: +49 341 48 474 173
www.dental-tribune.com
info@dental-tribune.com

DENTAL TRIBUNE ASIA PACIFIC LTD.
Room A, 20/F
Harvard Commercial Building
105-111 Thomson Road, Wanchai, HK
Tel.: +852 3113 6177
Fax: +852 3113 6199

THE AMERICA, LLC
116 West 23rd Street, Ste. 500, New York
N.Y. 10011, USA
Tel.: +1 212 244 7181
Fax: +1 212 244 7185

DENTAL TRIBUNE MEA EDITION
EDITORIAL BOARD
Dr. Aisha SULTAN ALSUWAI, UAE
Dr. Ninette BANDAY, UAE
Dr. Nabeel HUMOOD ALSABEEHA, UAE
Dr. Mohammad AL-OBAIDA, KSA
Dr. Meshari F. ALOTAIBI, KSA
Dr. Jasim M. AL-SAEEDI, Oman
Dr. Mohammed AL-DARWISH, Qatar
Prof. Khaled BALTO, KSA
Prof. Paul TIPTON, UK
Dr. Dobrina MOLLOVA, UAE
Dr. Munir SILWADI, UAE
Dr. Khaled ABOUSEADA, KSA
Dr. Rabih ABI NADER, UAE
Dr. George SANOOP, UAE
Dr. Olivier CARCUAC, UAE
Dr. Ehab RASHED, UAE
Dr. Olivier CARCUAC, UAE
Dr. Ehab Heikal, Egypt
Aiham FARRAH, CDT, UAE
Retty M. MATTHEW, UAE

PARTNERS
Emirates Dental Society
Saudi Dental Society
Lebanese Dental Association
Qatar Dental Society
Oman Dental Society

DIRECTOR OF mCME
Dr. Dobrina Mollova
mollova@dental-tribune.me
Tel.: +971 50 42 43072

DIRECTOR
Tzvetan Deyanov
deyanov@dental-tribune.me
Tel.: +971 55 11 28 581

DESIGNER
Kinga Romik
k.romik@dental-tribune.me

PRINTING HOUSE & DISTRIBUTION
Al Nisr Printing
P. O. Box 6519, Dubai, UAE
800 4585/04-4067170

SMALL CHANGE. BIG DIFFERENCE.

The new imaging plate scanner XIOS Scan completes the intraoral family from Sirona. Whether you're taking the first steps into the digital world or establishing or updating a fully digital practice, XIOS Scan and XIOS XG Sensors offer perfectly synchronized solutions for every workflow. **Enjoy every day. With Sirona.**



THE NEW
IMAGING PLATE
SCANNER:
XIOS Scan

SIRONA.COM

The Dental Company

sirona.

Esthetic replacement of two restorations on mandibular second molar

By Dr. Giuseppe Chiodera, Italy

About the Case

Male patient, 28 years old. The patient came to the office for a routine check-up. The mandibular second molar showed two insufficient fillings (occlusal and buccal) with sec-

ondary caries, open margins and occlusal wear. Both restorations needed to be replaced. The patient opted for an esthetic, multi-layer composite restoration for a natural looking outcome.

Challenge

Poor accessibility and visibility of this restoration lead to a variety of clinical challenges such as composite placement and proper light curing. **DT**



Dr. Chiodera graduated from the University of Brescia with a degree in Dentistry. Winner of a scholarship of Kings College University of London in 2004. Dr. Chiodera is an author of articles in various national and international magazines. At the moment he is working in a private practice in Brescia and specialising primarily in conservative dentistry and endodontics.

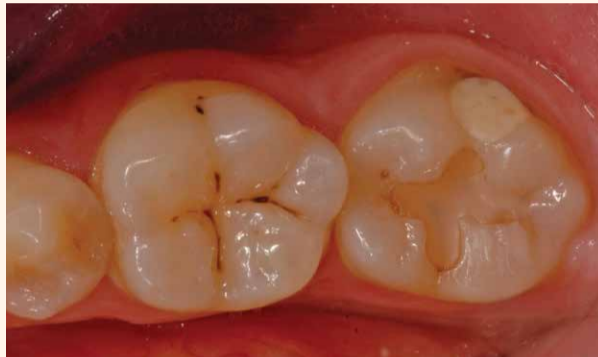

Fig. 1: Initial situation: mandibular second molar with restorations require replacement.

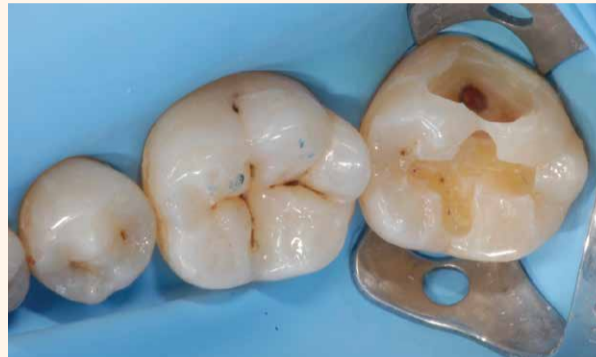

Fig. 2: After placement of rubber dam the insufficient fillings were completely removed.

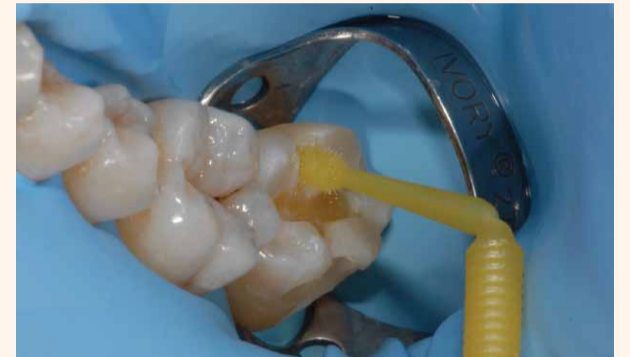

Fig. 3: After selective enamel etching, Single Bond Universal Adhesive was applied.

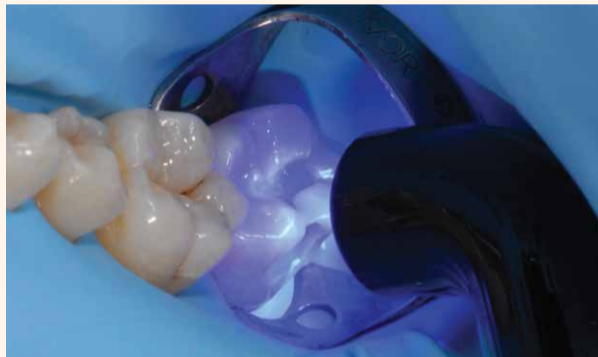

Fig. 4: Adhesive was cured for 10 seconds with Elipar™ DeepCure-S LED Curing Light after scrubbing and air drying steps were completed.

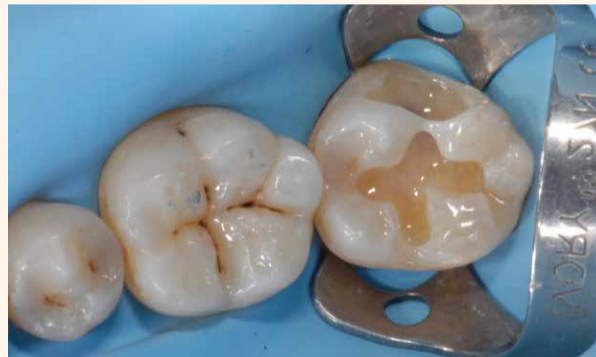

Fig. 5: Filtek™ Z350 XT Flowable Restorative, shade A3 was used as a liner for easy adaptation.

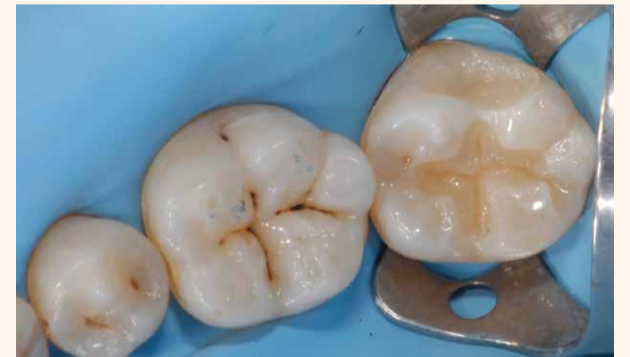

Fig. 6: Dentin was replaced with incremental placement and curing of Filtek™ Z350 XT Universal Restorative, shade A3B.

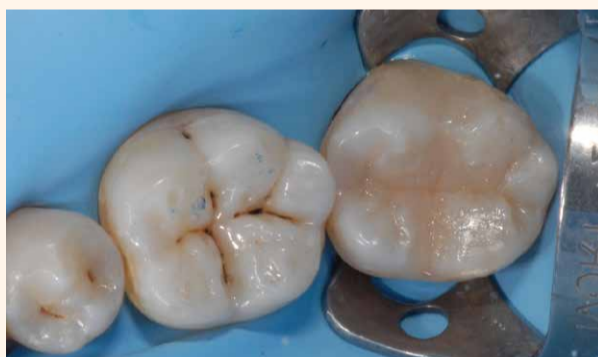

Fig. 7: Enamel was replaced with Filtek™ Z350 XT Universal Restorative, shade A3E and light cured. Stains were applied in the fissure.

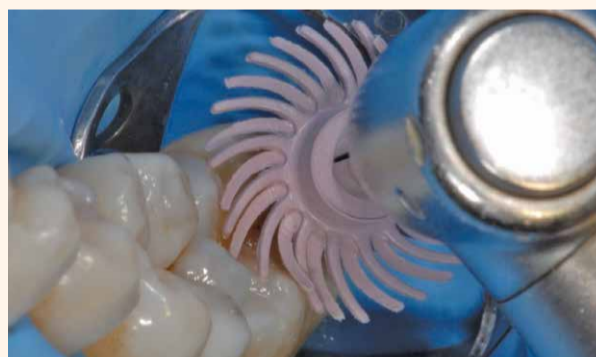

Fig. 8: The initial finishing was completed with Sof-Lex™ Discs, followed by pre-polishing with Sof-Lex™ Pre-Polishing Spiral and high gloss polish with Sof-Lex™ Diamond Polishing Spiral.

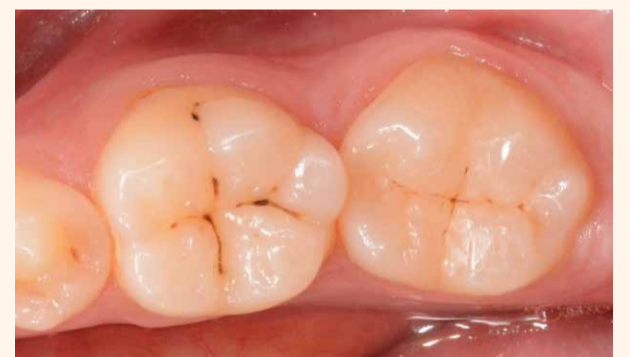

Fig. 9: Final restorations with an excellent esthetic appearance.

3M Science. Applied to Life.™

Practical dental solutions to apply in your clinic.

3M™ Health Care Academy

The lectures are now available online on www.dentistryinpractice.com

Practical dental solutions to apply in your clinic

By 3MSM Health Care Academy

3M is a global innovation company that never stops inventing. Over the years our innovations have improved daily life for hundreds of millions of people all over the world. Every day at 3M, one idea always leads to the next, igniting momentum to make progress possible around the world. You can now be a part of our world of science and learn how it is applied to life!

In May 2016 dental professionals and opinion leaders from Central and Eastern Europe and Middle East gathered in Warsaw for the "Dentistry in Practice International Meeting" provided by 3M. In 22 specialized lectures practical information, trends and solutions were shared. Solutions, based on modern science, which can be applied in any dental office, making patient care more effective, comfortable and safer. **DT**

Stay on top of your dental practice! Access the lectures online at www.dentistryinpractice.com

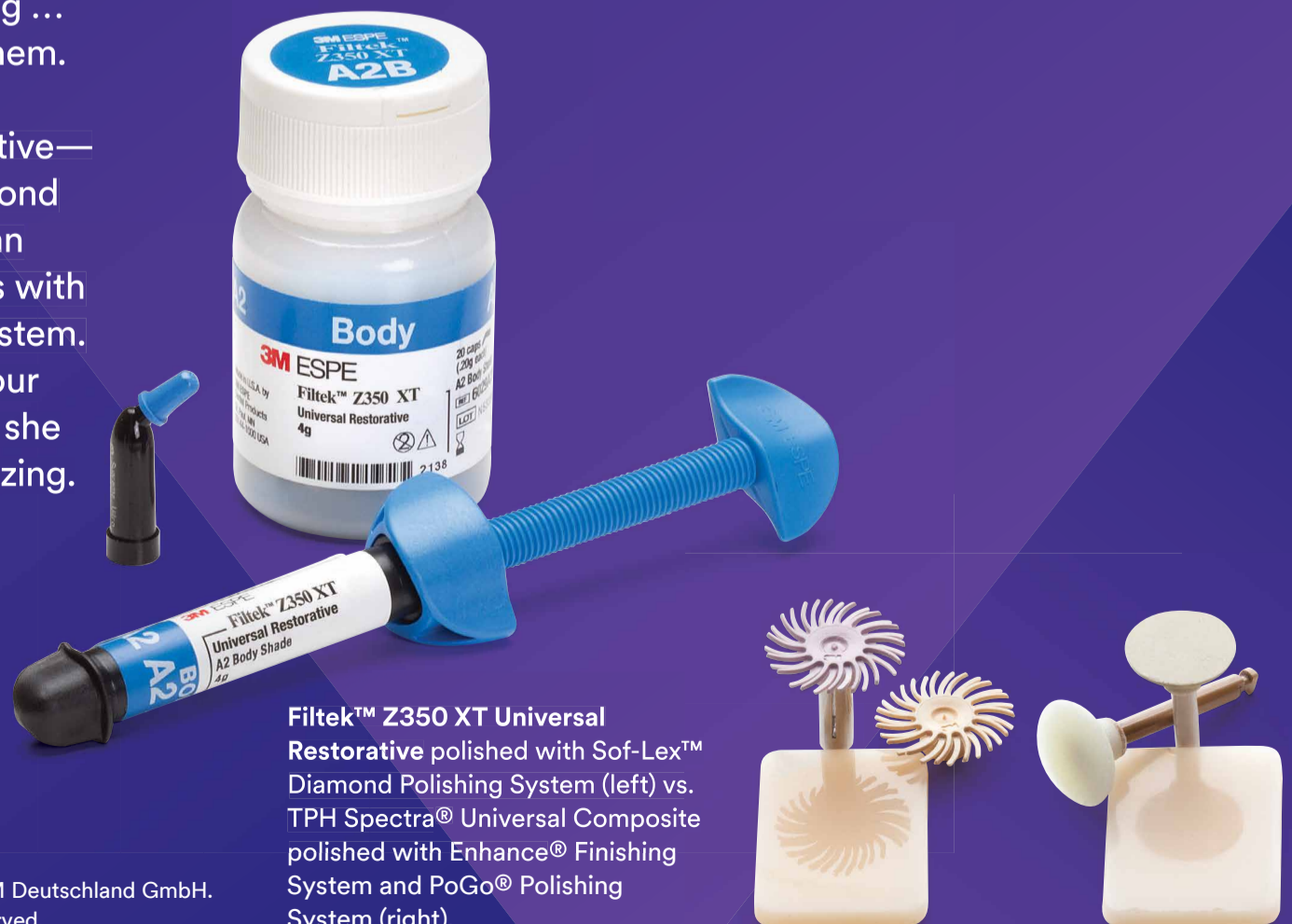Contact Information
Elena Golubeva
Marketing Manager CEEMEA
Oral Care Solutions Division
egolubeva@mmm.com

3M Science.
Applied to Life.™

A beautiful smile she can't wait to share.

There are things in life worth sharing ... and now, her smile can be one of them. Restore with beautifully strong Filtek™ Z350 XT Universal Restorative—and polish with the Sof-Lex™ Diamond Polishing System. Together, they can produce a diamond paste-like gloss with the convenience of a rubberized system. Oh, don't be surprised if word of your great work gets around ... because she shares everything she thinks is amazing.

www.3MGulf.com/espe



Filtek™ Z350 XT Universal Restorative polished with Sof-Lex™ Diamond Polishing System (left) vs. TPH Spectra® Universal Composite polished with Enhance® Finishing System and PoGo® Polishing System (right).

Certificate & Diploma in Restorative Aesthetic Dentistry

British Academy of Restorative Dentistry **DUBAI** دبي

2016

www.cappmea.com/capptipton



British Academy
of
Restorative Dentistry

CAPP / TIPTON
Dental Academy



"You learn fundamentals of dentistry that you will apply to diagnostic dentistry, understanding why your patients is having problems that they're having..."

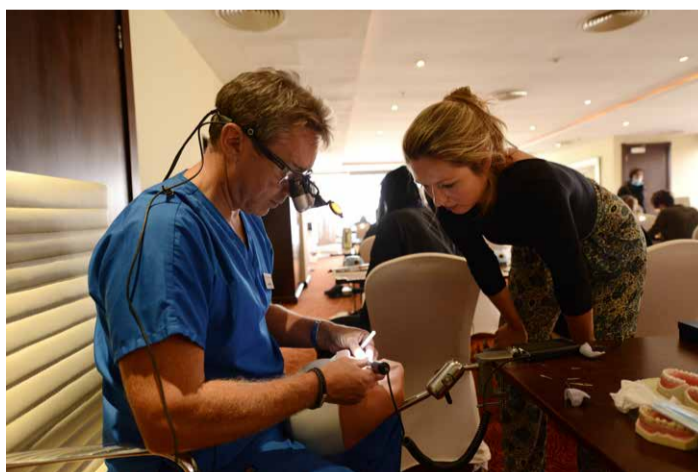Dr. Maxine Annette Sowden, Zambia



Prof. Paul Tipton

"The biggest thing that I have learnt from this course is occlusion and tips that I can introduce to my practice."

Dr. Stephen Denny, UK



"This is the first course in 20 years when I get so much of new information."

Dr. Khadishat Sadulaeva, Dubai



04-05 NOVEMBER 2016
JUMEIRAH BEACH HOTEL
DUBAI UAE

8TH DENTAL - FACIAL COSMETIC INTERNATIONAL CONFERENCE

Joint Meeting with

5TH AAID GLOBAL CONFERENCE
DENTAL HYGIENIST SEMINAR

HANDS-ON: 01-07 Nov 2016

CONFERENCE/EXHIBITION: 04-05 Nov 2016

ORGANIZED BY

CAPPevents
exhibitions & conferences

AAID
AMERICAN ACADEMY
OF IMPLANT DENTISTRY



SUPPORTED BY



ADA C.E.R.P.® Continuing Education
Recognition Program

Centre for Advanced Professional Practices (CAPP) is an ADA CERP Recognized Provider. ADA CERP is a service of the American Dental Association to assist dental professionals in identifying quality providers of continuing dental education. ADA CERP does not approve or endorse individual courses or instructors, nor does it imply acceptance of credit hours by boards of dentistry.

CAPP designates this activity for 49 CE Credits

dti Dental
Tribune
MEA

www.cappmea.com/aesthetic

www.facebook.com/cappmea

Aesthetic laser therapy correction of physiological gingival hyperpigmentation

ADA C.E.R.P.® | Continuing Education Recognition Program

Centre for Advanced Professional Practices (CAPP) is an ADA C.E.R.P. Recognized Provider. ADA C.E.R.P. is a service of the American Dental Association to assist dental professionals in identifying quality providers of continuing dental education. ADA C.E.R.P. does not approve or endorse individual courses or instructors, nor does it imply acceptance of credit hours by boards of dentistry.

CAPP designates this activity for 2 CE Credits



mCME articles in Dental Tribune have been approved by:
HAAD as having educational content for 2 CME Credit Hours
DHA awarded this program for 2 CPD Credit Points

By Howard Gluckman, Jonathan Du Toit, South Africa

A beautiful smile is dependent on many factors. One of those factors is the gingival scaffold. Symmetry, proportion, as well as colour and appearance of the gingiva are critical to an aesthetically pleasing smile. Physiological gingival hyperpigmentation does not present as clinical pathology requiring intervention, nonetheless it may be of aesthetic concern to the patient. Minimally invasive intervention by means of cryosurgery, electrosurgery, laser therapy or other may produce dramatic change in the appearance of the patient's smile with a sustainable, long-term aesthetic outcome.

Hereafter a case is presented demonstrating laser therapy removal of gingival hyperpigmentation with stable, pink gingival aesthetics at the 2-year follow-up.

Case report

A 34-year-old female patient of Indian descent presented by referral to a specialist in periodontics and oral medicine at her request for "pink gums". The patient was a non-smoker and the medical history was non-contributory. Examination of the face denoted multiple, poorly defined, hyperpigmented macules of the lips, mild in severity and greater in number on the lower lip. The patient's high smile line was noted with excessive gingival display, the entirety of which involved hyperpigmentation, blue-black/dark brown in colour (Fig. 1). Intraoral examination denoted a healthy, largely restorative-free dentition, with exemplary oral hygiene maintenance.

Hyperpigmentation was noted involving the attached gingiva of both the mandible and maxilla, with the latter greater in severity (Fig. 2). The patient scored 4 on the Dummet Oral Pigmentation Index in terms of pigmentation intensity (heavy clinical pigmentation), and scored 2 on the Takashi melanin pigmentation index in terms of its extension (formation of continuous ribbon extending from the neighbouring solitary units).⁴ In both the mandible and the maxilla the hyperpigmentation appeared mostly as singular, posteriorly extending macular lesions with well demarcated borders limited coronal to the mucogingival junctions. A diagnosis of physiological gingival hyperpigmentation was made and intervention for aesthetic correction was indicated (the patient initially sought treatment of the maxilla only). Digital smile design (DSD) and smile analysis of the patient indicated need for correction of the altered passive eruption. De-epithelialization of the affected areas as well as crown lengthening by laser gingivoplasty was opted for. The working field was retracted and isolated (OptraGate, Ivoclar Vivadent), and local anaesthesia achieved by slow infiltration of a 4% articaine with adrenaline (1:200,000) local anaesthetic solution (Ubistesin™ forte, 3M ESPE). The area, mucosa and teeth surfaces, were cleaned with sterile gauze soaked in chlorhexidine gluconate aqueous solution (never use an alcohol solution with medical lasers). An Er,Cr:YSSG laser (Waterlase iPlus 2.0, Biolase) was used for all the periodontal soft tissue surgeries. The crown lengthening by gingivectomy was first carried out as per the DSD guide, with a fine tip (MGG6),

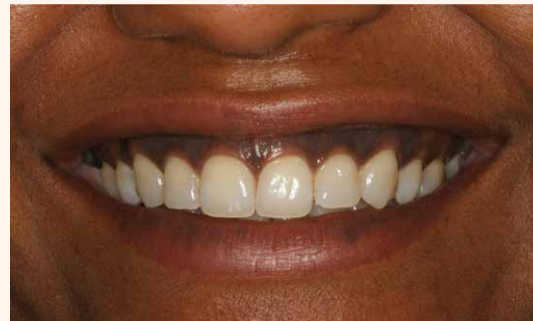

Figure 1: Preoperative view of the patient's smile

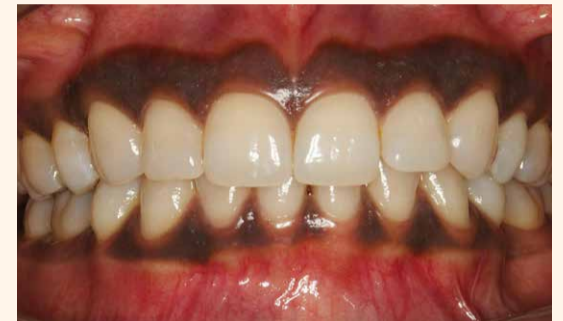

Figure 2: Retracted, preoperative, intraoral view demonstrating the degree of pigmentation and extension of the affected areas

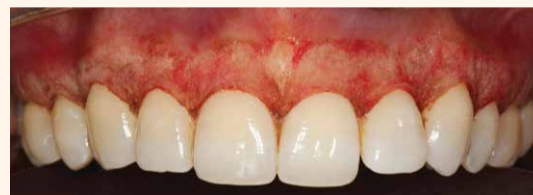

Figure 3: Immediately postoperative, crown lengthening and deepithelialization of pigmented tissue completed

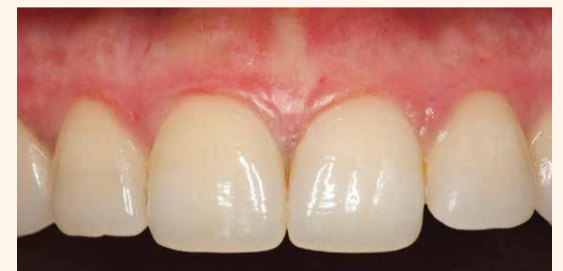

Figure 4: 10-days postoperative, rapid healing with dramatic results in gingival colour

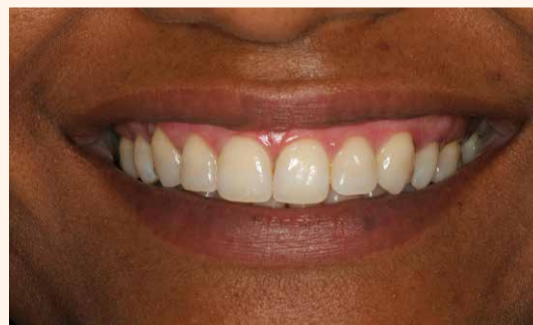

Figure 5: The patient's smile 10 days after the laser deepithelialization and crown lengthening

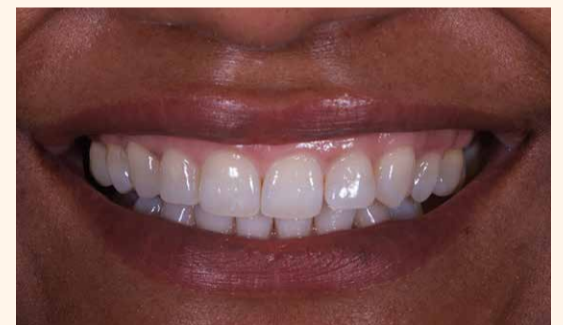

Figure 6: Patient's smile at the 2-year recall; dental bleaching, increased clinical crown size, coral-pink gingiva, all contribute to a healthy, aesthetic smile

applied more parallel to the tooth, with the unit's power settings at 3W 75Hz, with water and air settings 50

and 40 respectively. Thereafter, a broader, chisel tip (MC3) was interchanged for the depigmentation/gross de-epithelialization, with power settings increased to 5W 25Hz. The tip size and power allowed for faster removal of tissue with water and air settings on for cooling.

Broad, gradual strokes de-epithelialized the pigmented areas up to 1–2 mm beyond the lesions' borders. To conclude the procedure, the unit was set to "laser bandage" mode, with lowered power settings at 1–1.5W 75Hz, and water and air off for hemostasis, leaving a layer of coagulum that would aid with the tissue healing. After the entire affected area was de-epithelialized (Fig. 3) postoperative instructions were given (no tooth brushing near the treated area for 1 week, rinse with chlorhexidine mouthwash BID 1 minute (Andolex C, iNova Pharmaceuticals), soft diet avoiding spicy/irritating foods). The patient was recalled at 10 days, reporting having had no pain or discomfort, and demonstrating near complete healing of the entire treated area (Fig. 4). There were no areas of hyperpigmentation noted (Fig. 5). The patient was rescored as zero for both pigmentation indices. Following dental bleaching the patient presented at the 2-year recall with no notable signs of repigmentation. The patient remained a score

of zero on both indices. The gingival contour and colour remained stable with aesthetic results pleasing to the patient (Fig. 6).

Discussion

Pigmentation of the gingiva may pose an aesthetic concern to the patient seeking cosmetic correction thereof. Laser depigmentation is an evidence-supported, beneficial treatment modality.¹ "Laser" is an acronym for light amplification by stimulated emission of radiation.⁷ Possibly the first report of laser radiation on oral soft tissues was as early as 1965.⁸ The first commercial laser for use in dentistry, the dLase 300 Nd:YAG laser, was introduced in 1990.⁶ At present, a range of laser wavelengths are used in dentistry for a plethora of applications (Table 1). The fundamental mode of action of lasers is that waves consisting of photons (basic unit of radiant energy, light) travel at the speed of light and these waves can be defined by their wavelength and amplitude.¹¹ Amplitude is the vertical height of the wave, and in lasers this corresponds to "brightness", its potential energy to do work. Wavelength is the distance between two corresponding points on the wave – the unit typically in laser dentistry is

Laser type	Active medium	Wavelength (nm)	Treatments, applications
Excimer lasers	Argon fluoride (ArF)	488	Hard tissue ablation, phased out of dentistry. Medical use primarily
	Xenon-chloride (XeCl)	308	Dental caries and calculus detection
Gas lasers	Carbon dioxide (CO ₂)	9300; 10,600	Sulcular debridement, peri-implantitis, soft tissue surgery
	Argon (Ar)	488 - 514	Phased out of dentistry. Medical use primarily.
	Helium-neon (HeNe)	630	Pulp vitality testing, therapeutic photobiomodulation
Diode lasers	Indium-gallium-arsenide-phosphorus (InGaAsP)	800 – 1064	Dental caries and calculus detection
	Gallium-aluminum-arsenide (GaAlAs)		Intraoral general and implant soft tissue surgery, sulcular debridement (subgingival curettage in periodontitis and periimplantitis), analgesia, treatment of dentin hypersensitivity, pulpotomy, root canal disinfection, aphthous ulcers, gingival depigmentation
	Gallium-arsenide (GaAs)		
Solid-state lasers	Potassium titanyl phosphate (KTP)	532	Dental bleaching, medical applications
	Neodymium:yttrium-aluminum-garnet (Nd:YAG)	1064	Soft tissue surgery, sulcular debridement, analgesia, dentin hypersensitivity, pulpotomy, root canal disinfection, enamel caries removal, aphthous ulcers, gingival depigmentation
Erbium group:	Erbium-doped yttrium aluminum garnet (Er:YAG)	2940	Caries removal, cavity preparation, soft tissue surgery, sulcular debridement (teeth and implants), scaling root surfaces, osseous surgery,
	Erbium: yttrium-scandium-gallium garnet (Er:YSSG)	2790	dentin hypersensitivity, analgesia, pulpotomy, root canal treatment & disinfection, aphthous ulcers, gingival pigmentation
	Erbium, chromium: yttrium-scandium-gallium garnet (Er,Cr:YSSG)	2780	
Other	Low level lasers	600 – 635	Non-surgical, photobiomodulation, caries detection

Table 1: Lasers currently used in dentistry

nanometer (nm). Waves rise and fall around the zero axis many times a second, referred to as oscillations, and the number of oscillations per second is the frequency, measured in hertz (Hz). The laser utilized in the treatment of this case (Er,Cr:YSSG) functions at a wavelength 2780 nm, and at a frequency of 1 – 100 Hz. Hertz also states the number of laser pulses per second of emitted energy. To put these properties into perspective, light from a household bulb is white and diffuse, it is not focused. Laser light differs in that it is monochromatic (a beam of single colour), and that its waves are coherent. This means they are identical in size and shape. The amplitude as well as the frequency of all the waves of photons are identical. The production of focused electromagnetic (EM) energy is a direct result of this coherence. Whilst a 100Watt bulb may light a room, a 2Watt laser may perform a surgical excision, since all the photons in the laser light are focused and "work together".¹² A laser consists of three structural components, namely the active medium, the pumping mechanism, and the optical resonator (Figs. 7a, b). In-depth electromagnetism physics may not be essential knowledge for the clinician, but it may be helpful to know that lasers derive their product nomenclature from these components. The active medium may consist of a container of gas (CO₂ lasers), a solid crystal (Er,Cr:YSSG laser), a solid-state semiconductor (diode laser), or as a liquid. The active medium is surrounded by the pumping mechanism which is an excitation source (source of energy, electric coil, lamp strobe, etc). The excitation source will excite electrons, and as they return to their resting state they emit energy in the form of photons.

Completing the laser cavity are optical resonators (typically mirrors) that reflect waves back and forth, thereby collimating and amplifying the beam.¹² As with normal light, the clinician may note that laser light waves exist on the EM spectrum and can correlate the type of laser to its respective wavelength (Fig. 8). All

commercially available dental lasers emit light and wavelengths ranging 500 – 10,000 nm.¹³ As such, a dental laser may fall within the visible or invisible and nonionizing range of the EM spectrum. An erbium laser for example then may have an additional light source in the device for the clinician to visualize the application point.

Furthermore, the point of caution here is that all persons in the laser operating room are to wear laser protective eyewear.

When the laser is activated there may be four possible interactions between the laser light and the target area, depending on the tissues' optical properties, depending on the light's wavelength.¹⁰ Reflection will occur when the light is deflected off the surface, with no effect. This may be of consequence to neighbouring, absorbing tissues, and may cause injury to a nearby person's unprotected eyes. The laser light may also be transmitted, again with no effect on the target tissue, but possible unintended or detrimental effect to neighbouring tissue. Absorption may be the most desired effect. The amount of absorption further depends on the tissue's water content, and pigmentation. The fourth interaction is scattering, whereby the photons penetrating the tissue change directions and leads to absorption in a greater area. As laser energy is absorbed by the tissue the interaction is photothermal (laser energy transformed into thermal energy). The effects then are either incision/ excision, ablation/vaporization, or hemostatic/coagulation.¹⁴ When the beam's spot size (diameter) is small and focused, it is suited for an incision/excision procedure. A wider beam size will interact with the tissue more superficially producing surface ablation. And when the beam is out of focus or less focused coagulation can be performed. In the treatment of this gingival hyperpigmentation case, a larger beam diameter allowed for superficial tissue interaction but deep enough to target the basal and suprabasal epithelial layers rich in melanocytes.

The ablative action of the laser over a wider area allowed for removal of the superficial gingival layers rather than focused cutting. Oral mucosa is high in water content and the laser's effect primarily involves the thermal change in the tissue. When water temperature is raised to 100° C vaporization of the water within the mucosa occurs, called ablation. Incision and excision of oral soft tissues occurs at this temperature. Between 60° and 100° C proteins will denature without vaporization of underlying tissue, ideal for the removal of diseased degranulation tissue, for hemostasis and coagulation.¹⁵ Charring of the tissues will however occur at temperatures at around 200° C.¹⁶ When removing hyperpigmented tissues, lower temperatures are needed, and much less energy is needed since chromophores attract lasers. Conversely, higher energy would be needed to excise fibrotic tissue with less chromophores.¹⁷ Lasers used for the aesthetic correction of physiological hyperpigmentation have been extensively described in the literature, and suggested as superior to other treatments due to the fast healing, reduced pain and discomfort, clean and dry operating field, and stable results.^{19,20,21} The formation of protein coagulum on the laser treated wound surface reduces postoperative pain. Laser light may also "seal" free nerve endings.¹⁸ The patient treated in the case presented here required only 1 ampoule local anaesthetic infiltration per quadrant delivered segmentally across the working area.

The operating field was dry and void of any profuse bleeding. Nearly the entirety of the hyperpigmented lesions had the superficial layers of tissue layers removed. Healing was rapid with no report of pain, infection, nor discomfort.

At as early as 10 days postoperative the area was nearly entirely healed with radical results in tissue colour and contour. The literature reports the expected chronological and degrees of repigmentation following removal by various modes of treatment. Depigmentation by laser ranks low (1.16 %) in terms of percentage repigmentation (Table 2).

Conclusion

Er,Cr:YSSG laser therapy for de-epithelialization can successfully alter blue – black/dark brown gingiva to uniform pink colour with numerous benefits for both clinician and patient. The results can be dramatic for patients seeking this treatment, remaining stable over the long-term, contributing greatly to an aesthetically pleasing smile.

References

- Lin YH, Tu YK, Lu CT, Chung WC, Huang CF, Huang MS, et al. Systematic review of treatment modalities for gingival depigmentation: a random-effects poisson regression analysis. *J Esthet Restor Dent.* 2014;26(3):162-78.
- Fiorellini JP, Kim DM, Uzel NG. Anatomy of the periodontium. In: Newman MG, Takei HH, Klokkevold PR, Carranza FA, editors. *Carranza's Clinical Periodontology.* St. Louis: Elsevier; 2012. p. 12 – 27.
- Fiorellini JP, Kim DM, Uzel NG. Clinical features of gingivitis. In: Newman MG, Takei HH, Klokkevold PR, Carranza FA, editors. *Carranza's Clinical Periodontology.* St. Louis: Elsevier; 2012. p. 79 - 80.
- Bakhshi M, Rahmani S, Rahmani A. Lasers in esthetic treatment of gingival melanin hyperpigmentation: a review article. *Lasers Med Sci.* 2015;30(8):2195-203.
- Peeran SW, Ramalingam K, Peeran SA, Altaher OB, Alsaid FM, Mugarbi MH. Gingival pigmentation index proposal of a new index with a brief

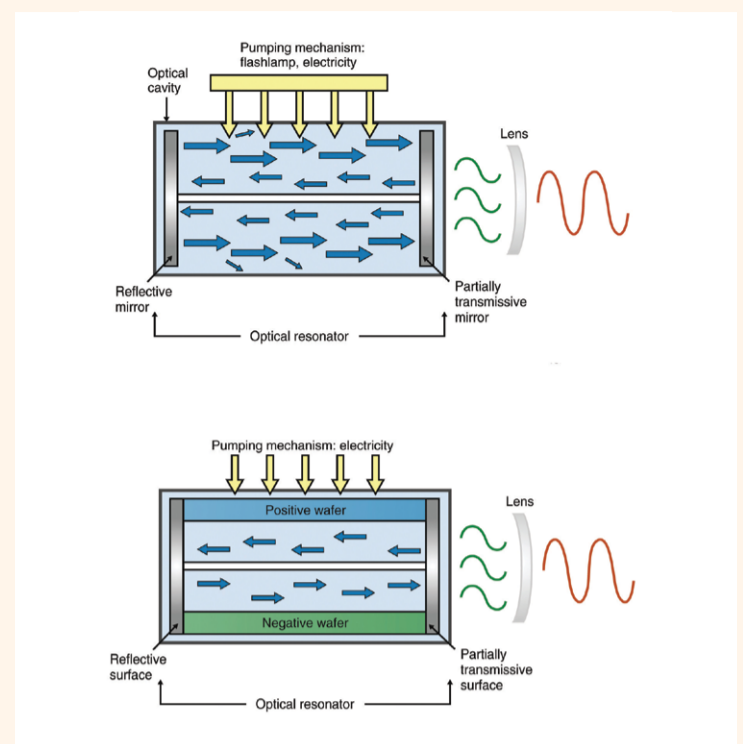


Figure 7: (a) Components of a gas or solid active-medium laser, eg. CO₂ or Nd:YAG laser, and (b) a diode laser. Adapted from *Principles and Practice of Laser Dentistry 2nd ed (p. 14), by Convisar RA, 2015, St. Louis: Mosby Elsevier*

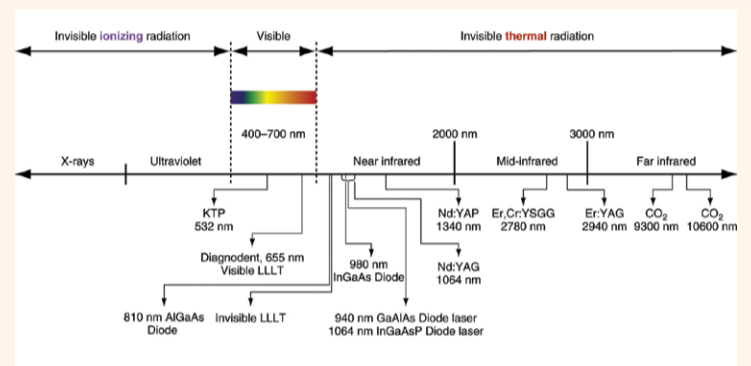


Figure 8: Wavelengths of the various laser lights and their position within the EM spectrum. Adapted from *Principles and Practice of Laser Dentistry 2nd ed (p. 14), by Convisar RA, 2015, St. Louis: Mosby Elsevier*

Treatment	No. of studies	Repigmentation rate (%)
Bur abrasion	16	8.99
Scalpel gingivoplasty	23	4.25
Gingival graft	3	1.96
Laser	27	1.16
Electrosurgery	9	0.74
Cryosurgery	12	0.32
Laser		
Nd:YAG	4	2.86
CO ₂	4	2.14
Er:YAG	8	1.41
Diode	12	0.19

Table 2: Literature review 1951 – 2013; pigmentation recurrence rates (%) by random-effects Poisson regression¹

review of current indices. *Eur J Dent* 2014;8:287-90.

- Sulewski JG. Einstein's "Splendid Light": Origins and Dental Applications. In: Convisar RA. *Principles and Practice of Laser Dentistry.* 2nd ed. St. Louis: Mosby Elsevier; 2015. p. 7.
- Coluzzi DJ, Convisar RA, Roshkind DM. *Laser Fundamentals.* In: Convisar RA. *Principles and Practice of Laser Dentistry.* 2nd ed. St. Louis: Mosby Elsevier; 2015. p. 12 – 26.
- Taylor R, Shklar G, Roeber F. The effects of laser radiation on teeth, dental pulp, and oral mucosa of experimental animals. *Oral Surg Oral Med Oral Pathol.* 1965;19(6):786-795.
- Hamblin MR, Huand YY. *Handbook of Photomedicine.* Boca Raton: CRC Press; 2013.
- Shanelec DA, Tibbetts LS, Ishikawa I, Butler B, Akira Aoki, McGregor A, et al. *Recent Advances in Surgical Technology.* In: Newman MG, Takei HH, Klokkevold PR, Carranza FA, editors.

Carranza's Clinical Periodontology. St. Louis: Elsevier; 2012. p. 606.

- The phonetics dictionary. 43rd ed. Pittsfield: Laurin Publishing; 1997.
- Myers TD. Lasers in dentistry. *J Am Dent Assoc.* 1991;122(1): 46-50.
- Parker S. Surgical lasers and hard dental tissue. *Br Dent J.* 2007;202(8):445-54. [DOI](#)

Howard Gluckman BDS, MChD (OMP)
Specialist in periodontics and oral medicine, director of the Implant and Aesthetic Academy
Contact email: docg@theimplantclinic.co.za
Telephone: +27 21-426-2300
Website URL: www.implantacademy.co.za

Jonathan Du Toit BChD, Dipl. Implantol., Dip Oral Surg, MSc Dent Department of Periodontics and Oral Medicine, School of Dentistry, Faculty of Health Sciences, University of Pretoria

mCME SELF INSTRUCTION PROGRAM

CAPPmea together with Dental Tribune provides the opportunity with its mCME - Self Instruction Program a quick and simple way to meet your continuing education needs. mCME offers you the flexibility to work at your own pace through the material from any location at any time. The content is international, drawn from the upper echelon of dental medicine, but also presents a regional outlook in terms of perspective and subject matter.

Membership

Yearly membership subscription for mCME: 1,100 AED
One Time article newspaper subscription: 250 AED per issue. After the payment, you will receive your membership number and allowing you to start the program.

Completion of mCME

- mCME participants are required to read the continuing medical education (CME) articles published in each issue.
- Each article offers 2 CME Credit and are followed by a quiz Questionnaire online, which is available on www.cappmea.com/mCME/questionnaires.html.
- Each quiz has to be returned to events@cappmea.com or faxed to: +97143686883 in three months from the publication date.
- A minimum passing score of 80% must be achieved in order to claim credit.
- No more than two answered questions can be submitted at the same time
- Validity of the article – 3 months
- Validity of the subscription – 1 year
- Collection of Credit hours: You will receive the summary report with Certificate, maximum one month after the expiry date of your membership. For single subscription certificates and summary reports will be sent one month after the publication of the article.

The answers and critiques published herein have been checked carefully and represent authoritative opinions about the questions concerned.

Articles are available on www.cappmea.com after the publication. For more information please contact events@cappmea.com or +971 4 3616174

FOR INTERACTION WITH THE AUTHORS FIND THE CONTACT DETAILS AT THE END OF EACH ARTICLE.