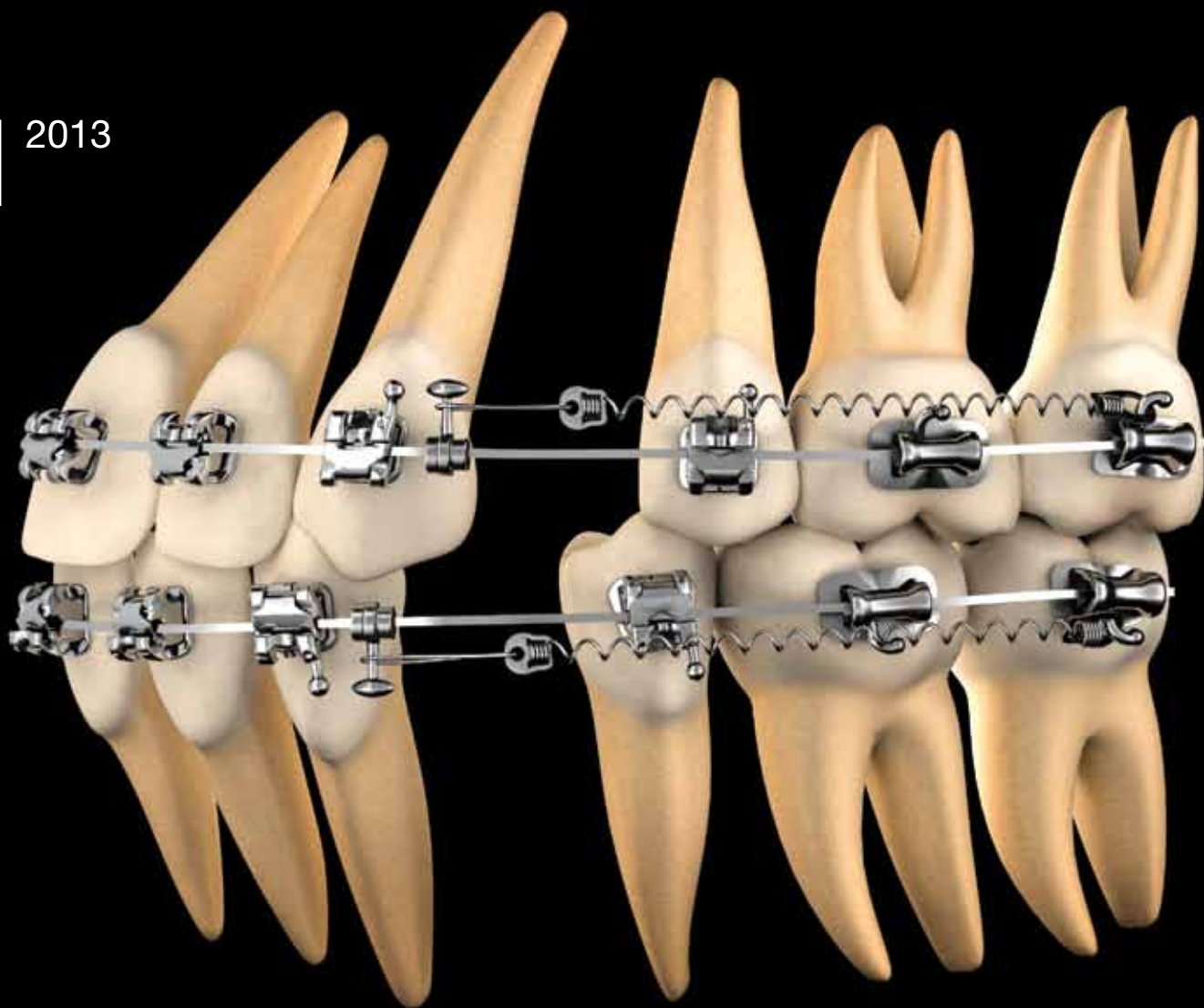


ortho

the international C.E. magazine of orthodontics

1 2013



_C.E. article

Concepts, goals and techniques for successful orthognathic surgery cases

_clinical

Orthodontics and esthetics: A multidisciplinary approach

_technique

How 'a penguin' can help your practice (really!)

For better dentistry

DENTSPLY
GAC

Touch the Future with the NEW DENTSPLY GAC

VISIT BOOTH 1325

See How Far Vision Can Take You

As an orthodontist, your vision is the most valuable talent you possess. It's the unification of your artistic and scientific expertise, manifested in every individual you treat.

To celebrate your orthodontic vision, you are cordially invited to join DENTSPLY GAC at Booth 1325 for the 2013 AAO in Philadelphia! This visionary experience will feature masterful educators, world-class practice-building programs and all new practice-shaping products.

Stop by the booth to meet up with some trusted old friends while you check out some cool new products.

Everyone who completes the interactive GAC Visionary Experience will receive a FREE GAC AAO t-shirt!

DENTSPLY GAC | 800.645.5530 | www.newdentsplygac.com

Why orthodontics?

In a profession dedicated to the tiniest of movements, it seems as if orthodontics is in constant motion. There is always something new to catch the eye and capture the imagination: new brackets and bands, new techniques and treatments, new ways to treat and diagnose patients. Even when we reread classic orthodontic books or articles, we are able to pick up some new tidbit or detail that we weren't prepared to understand the first time we went through them. It never ceases to amaze me how much there is to learn once we graduate from school.

As orthodontists, we typically perform full-mouth rehabilitation cases every day. Canines and molars in Class I, a correct overbite and overjet and the completion of the six keys of occlusion are typically our main goal.

In a perfect world, every case would conclude with picture-perfect results. Unfortunately, there are times when the result doesn't look as beautiful as we hoped it would. As clinical beings, we need to ask ourselves what is the problem in these cases, and how can we eliminate these problems in the future.

To me, the answer starts with this: a multidisciplinary knowledge is essential from the beginning of our treatments. Just like a sculptor, we must have a comprehensive understanding of facial proportions and how these proportions relate to the teeth.

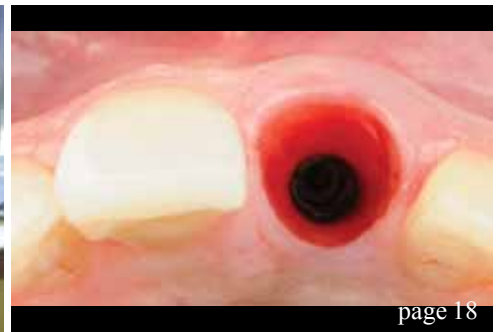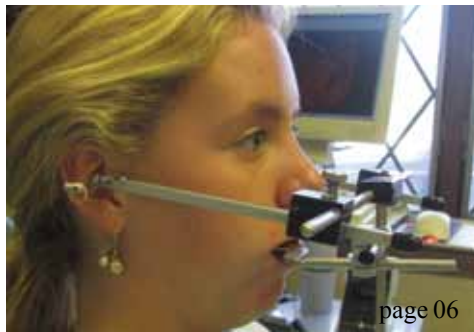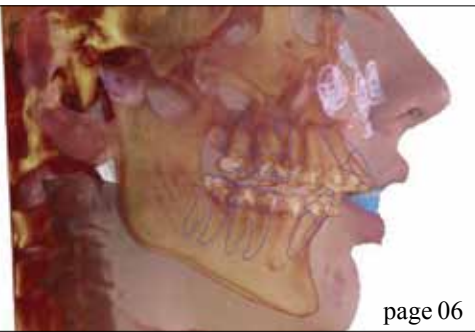Just as important, we also need the cooperation and input of an esthetic dental specialist to customize each smile. Working in conjunction, these two elements will help us elevate our results so that they attain more than just average results, and achieve a natural smile that reflects the beauty of our patient's personality.

So getting back to the overriding question that we started with: why orthodontics? For me, the answer comes down to a single word — joy. Because in orthodontics as in life, the final destination is important, but how we get there is what makes life worth living.

Best Regards,
Julia Garcia Baeza, DMD





Julia Garcia Baeza, DMD




C.E. article

- 06  Concepts, goals and techniques for successful **orthognathic surgery cases**
_Theodore D. Freeland, DDS, MS

clinical

- 18   Orthodontics and **esthetics**: A multidisciplinary approach
_Julia Garcia Baeza, DMD, and David Garcia Baeza, DMD

technique

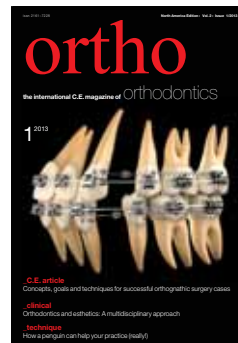
- 26  How **'a penguin'** can help your practice (really!)
_Jerry R. Clark, DDS, MS

industry

- 41 Managing your practice's **online reputation**
_Diana P. Friedman, MA, MBA
- 42 **Powering up** your practice
_DENTSPLY GAC

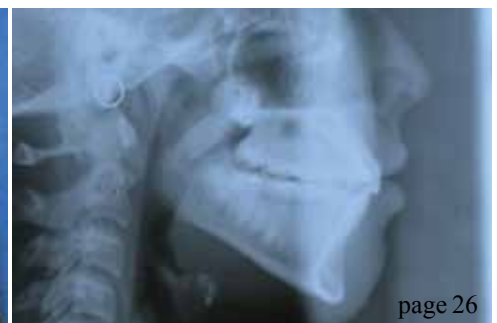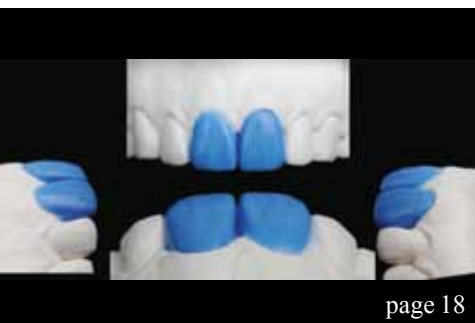about the publisher

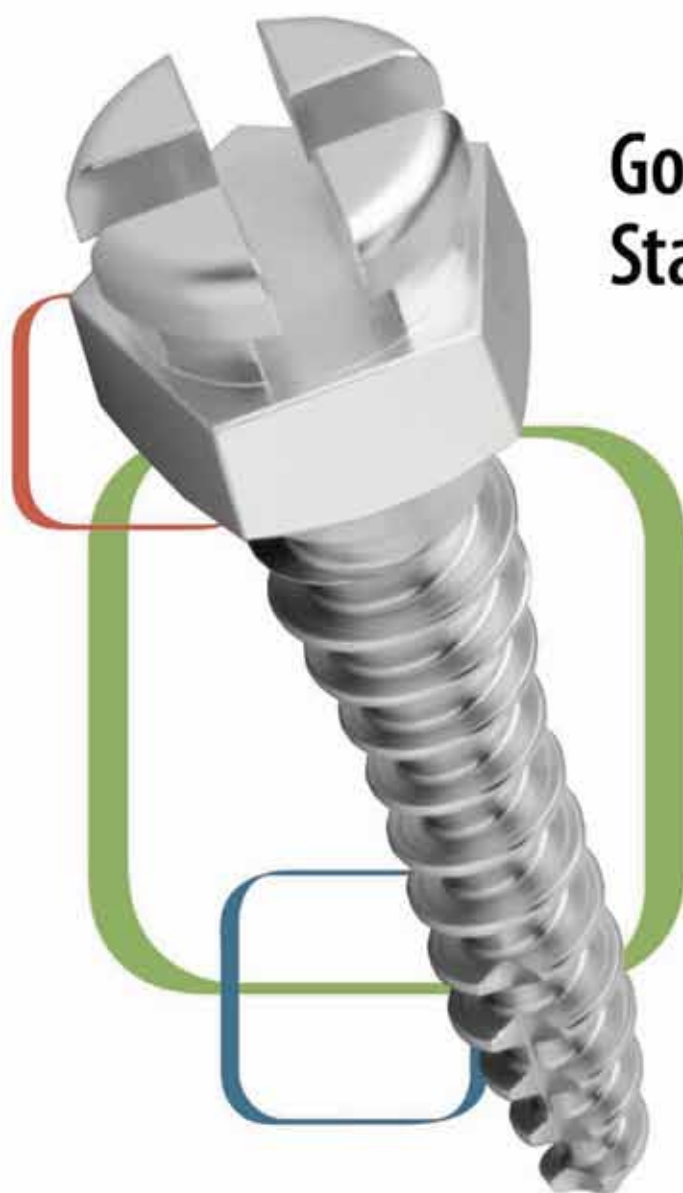- 49 _submissions
- 50 _imprint



on the cover

Cover image provided by DENTSPLY GAC





Goes Where You Want It. Stays Where You Place It.

Why is the Infinitas® Temporary Anchorage Device (TAD) System becoming the system of choice of orthodontic professionals?

- It utilizes a universal head design for direct attachment of many forms of traction
- It offers a low profile, comfortable head design
- Its unique Guidance System facilitates TAD placement and minimizes contact with tooth roots
- It features a self-drilling design to ease insertion and promote maximum stability

For precision, stability and reliability, the Infinitas is the only name you need to know. It's the anchorage system designed by an orthodontist, for orthodontists.

 **infinitas**TM
mini implant system

Concepts, goals and techniques for successful orthognathic surgery cases

Author_Theodore D. Freeland, DDS, MS

_c.e. credit

This article qualifies for C.E. credit. To take the C.E. quiz, log on to www.dtstudyclub.com. Subscribers to the magazine may take this quiz for free and will be emailed an access code after the magazine's release. If you do not receive the code, please write to support@dtstudyclub.com. Non-subscribers may take the quiz for \$20. You can access the quiz by using the QR code below.



_In this article, you will be introduced to the concepts, goals and techniques needed to diagnosis surgical cases, when surgical cases should be started and how to gain the knowledge needed to create successful results.

We'll delve into joint status, soft-tissue analysis, surgical treatment objectives, pre-treatment surgical setups and surgical setups. We'll then follow-up by looking at the concepts of natural head position, the axis-horizontal plane and the true vertical line will be introduced. By the end of this article, you should have:

- An overview of the knowledge needed for successful treatment.
- An introduction into what, when and how to perform successful cases.
- An overview of joint health.
- A summary of the soft-tissue analysis.
- An outline of the surgical treatment objective.
- An overview of diagnostic and surgical setups.

Remember that this article is an introduction only; it's not intended to teach you how to do surgical cases. Advanced training will be needed to master successful orthognathic surgical cases. So with no further ado, let's get started.

_Functional occlusion

The goal is to obtain functional occlusion. Before treatment, you have to determine if you have an orthognathic surgery case. You don't want to begin orthodontic treatment with the idea that if orthodontics fails, we will do surgery.

You'll see in Figures 1–3 that this case involves every facet of dentistry. Changes occurred not only in the facial features, but also in the teeth themselves. It involved orthodontic and orthognathic surgery, but also lengthening the front teeth by the restora-

tive dentist to achieve the natural smile in balance (Figs. 1–3). To this end, we need to look at five areas:

- joint status,
- soft-tissue analysis,
- surgical treatment objective,
- pre-surgical setup/surgical setup technique,
- surgery.

We'll give you a brief overview of the goals for each of the areas, then do an in-depth look into each of them individually.

_Joint status

Starting with the first area, you need to know the joint status. Is the joint healthy, is it degenerating, is there a disc problem? This means you'll need to apply not only a good clinical exam, but also articulated models that can measure the difference between centric occlusion and centric relation.

_Soft-tissue analysis

You'll need to know how to analyze the soft tissue. You'll need this because you are looking at everything from a soft-tissue standpoint, or put another way, you're recording the basic measurements that come from soft tissue, not hard tissue. If you deal with hard tissue only, then you will come up short in the soft tissue. Ignoring the soft tissue will result in a face that's not improved, just different.

_Surgical treatment objective

You need to know how to do a surgical treatment objective. You'll need to know the technique, and you'll need to know how to apply it because the surgical treatment objective allows you to treat the face, the occlusion, in a two-dimensional medium.

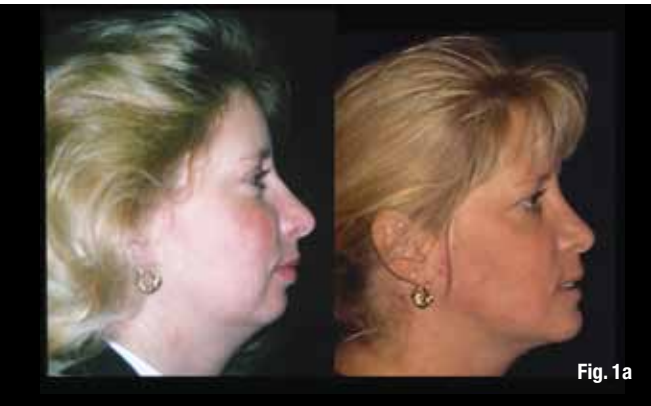

Fig. 1a



Fig. 1b



Fig. 1c

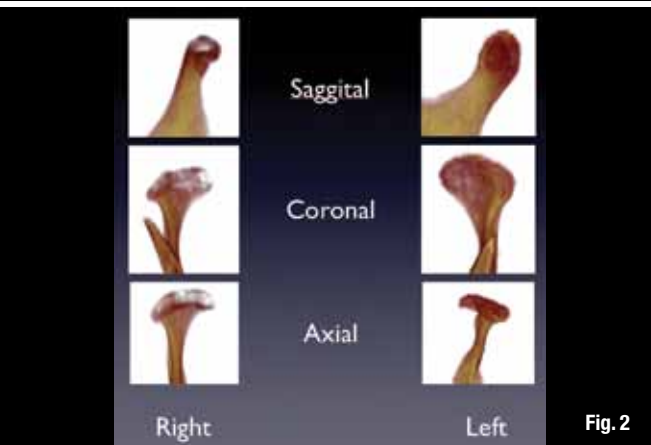


Fig. 2

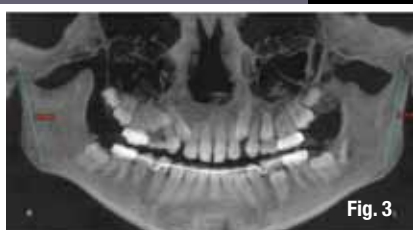

Fig. 3

Pre-surgical setup/surgical setup technique

Once you have established what you'll need to do from the surgical treatment objective, you will need to do what we call a pre-surgical setup. Otherwise you'll need to apply the knowledge you've gained from the patient, soft-tissue analysis and the surgical treatment objective, and perform a three-dimensional workup to make sure what you have planned will work with the joints, muscles and nervous system.

Surgery

Finally, you need to know surgery. I recommend that the orthodontist be in the operating room so you know what the surgeon is doing, and how the surgery goes. It's very important to know that the surgeon gets the joints seated in a passive manner. If the joint is stressed, then there's a good chance that we'll have some surgical relapse.

Joint status

Joint analysis will include three portions: history, a clinical examination and imaging.

Building a history will be similar to traditional patient assessment. We need to know if there are any family members who exhibit TMJ problems. If yes, then there's a good chance the patient will develop significant joint issues that will affect the outcome of treatment.

After an oral investigation, a thorough clinical examination of the joints will need to occur. We'll be on the lookout for any type of injuries to the mandible. If the patient has had any injury that involves the chin, there's a good chance that the joint may have been damaged.

Finally, we need to look into any past treatment. Has the patient had orthodontics before? Has the patient had a lot of restorative dentistry? This is important because all of the above have a tendency to affect joint status.

Clinical examination

Next is the clinical examination. Clinical examination includes the following:

- range of motion,
- symmetry of jaw motion,
- palpation,
- auscultation,
- muscle splinting,
- CR position.

Fig. 1a_Patient profile. (Photos/ Provided by Dr. Theodore D. Freeland)

Fig. 1b_Patient frontal.

Fig. 1c_Patient oral casting.

Fig. 2_Joint degeneration.

Fig. 3_Panoramic X-ray of the soft tissue on top of the hard tissue.

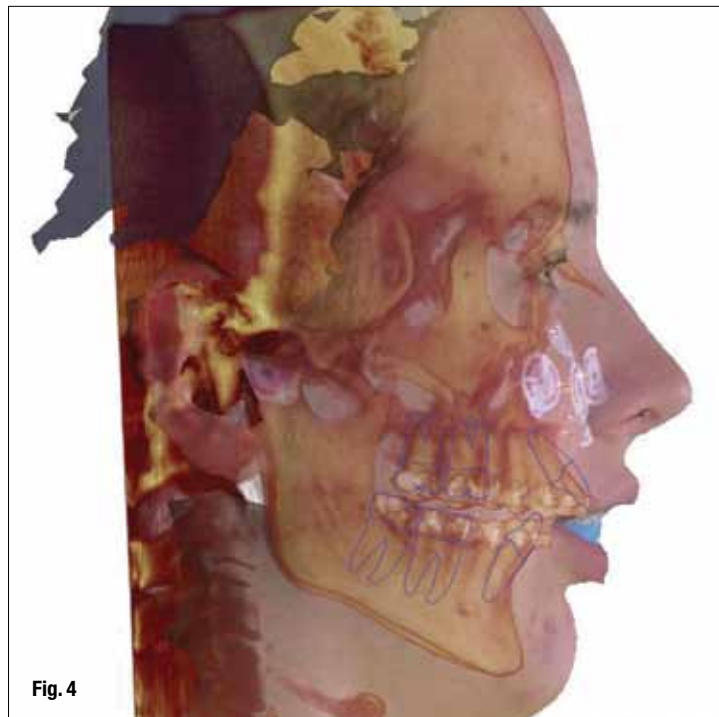


Fig. 4 A state of degeneration: a condyle that is actually changing.

Range of motion should be between 45 mm and 55 mm on opening and includes assessing movement. We're looking for a symmetrical mandible motion — meaning the chin should not deviate to the left or right on opening — and it should be relatively free of dental interference.

Now check for palpation of the muscles of mastication. If you don't check the muscles that move the mandible, then there's a good chance that you'll miss some sort of functional bite issue.

We also listen to the joint with a stethoscope, and we apply some anterior pressure to the disc through external auditory meatus to make sure the disc is functioning properly.

When trying to manipulate the mandible, one can feel the muscles. If the muscles will not let you obtain a centric joint position, then we cannot do a diagnosis because the muscles aren't holding the condyle out of the socket. This is usually due to some inflammation.

Finally, we'll check what we call the centric relation position, which you should be able to feel. It should feel solid and the patient should be able to open from this position with relative ease, and there should be no noises.

Imaging

The clinical examination will tell us a lot about the joint status. The use of imaging will help us build our base of case-specific intelligence. We'll use two types of imaging: MRI and cone beam.

LCBCT

Most of the time, we start with cone beam because it's easy to obtain a 3-D image of the joints. Thanks to the work of Rickets and Dr. Ikeda, we have a way to measure joint position and get an idea if the condyle is basically seated. With cone beam, we can measure the health of the condyles.

Our imaging showed a joint that is in a state of degeneration. The condylar head has changed in vertical height. Therefore, we would expect to see an asymmetrical opening where the chin deviates to the affected side. In all three views (sagittal, coronal and axial), we have a condyle that is actually changing, especially when you make a comparison to the left condyle (Fig. 4).

In a side-by-side presentation, you can see that the left side is definitely in a lot better shape, having a more rounded effect to it. The size of the coronal view is one that shows a definite symmetric outline to it as compared to the other side. The axial view confirms this; you see that the shape is better and has a more dense outline.

Thus, our basic imaging system helps us determine that, in this case, one side is going to be the problem side, especially as it pertains to orthognathic surgery.

If we go to the two-dimensional images created in the cone beam, we can see that the right joint has definitely lost vertical height, and we definitely have a joint spacer that is excessive (Figs. 5, 6).

In the coronal view, we can even see that there may be some sort of cyst formation. When you compare the right side to the left side in the coronal view, you get a more traditional image, which is what we'd like to see. However, there have been some changes that have occurred, because we're starting to see a "bird-beaking" effect in the left joint. The images of the joint are ones that are important in determining if we should proceed with any kind of a surgical correction.

In the sagittal view, the right side, the joint looks pretty normal. However, if we look at it in a transverse direction, you'll see less joint space laterally than you do medially, something we see in both the left and right joints (a much bigger joint space). That's why it's important that you not only look at a sagittal view, but you also need to look at the coronal view to see if you have a transverse problem occurring in the joints.

Soft-tissue analysis

When we're trained in orthodontics, we're trained in hard-tissue analysis, otherwise all of our cephalometric analysis are based on hard structures. If you use hard structure to determine soft-tissue corrections, then you'll come up short of good facial esthetics. That's why a soft-tissue analysis is so important.

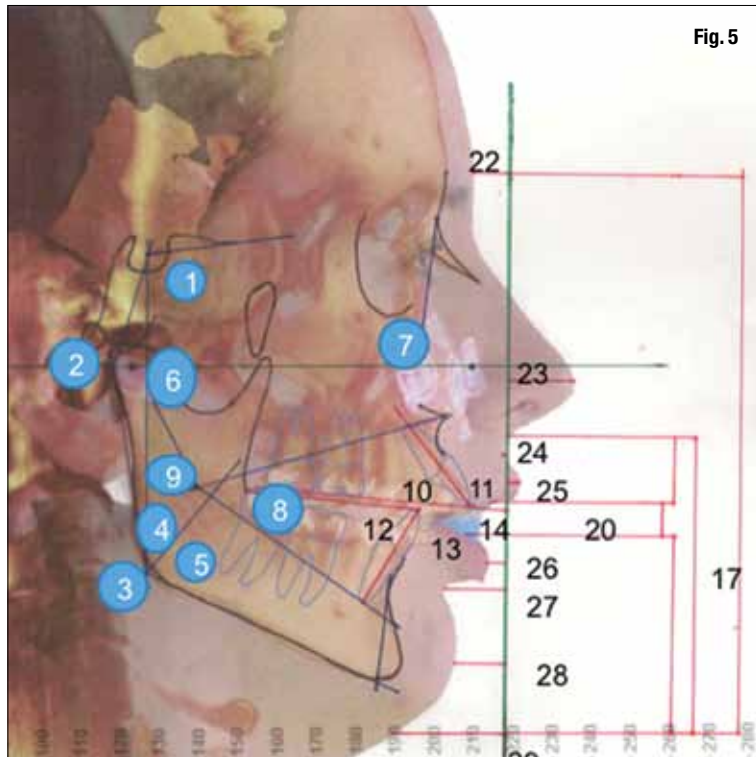


Fig. 5



Fig. 6

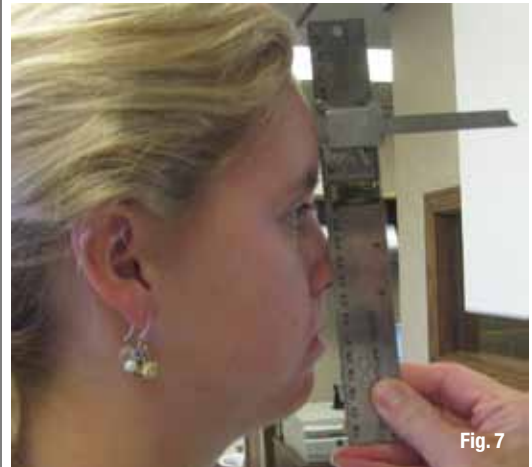

Fig. 7

Using soft-tissue markers with 3-D facial mapping, we are able to diagnose the soft tissue, and we can also relate it to the hard tissue.

In Figure 5, we've overlaid the soft tissue on top of the hard tissue. With the markers on, after we convert it to a two-dimensional X-ray, we can see where the sub-pupal area is, where the cheekbones are and where the alar base is. In addition, you will see a marker that we call a hinge access marker, which comes from establishing the true hinge axis of the patient. There is also a marker that's placed on the nose that we call the horizontal point.

We are going to analyze everything from a basic coordinate system of a true vertical to an axis horizontal.

The image is orientated from the axis horizontal plane and the true vertical plane, which is based on the patient's natural head position.

Figure 6 shows how these two corners are at 90 degrees from each other. In this analysis, we're going to record all the soft-tissue measurements, both horizontal and vertical, and we're going to base them on the line that runs through the subnasale (SN). This establishes the true vertical line based on natural head position.

Furthermore, we're including a few hard-tissue measurements that will tell us about the architecture of the mandible. These come from Ricketts and from the Jarabak analysis. With this analysis, we can cover the basis that we need for orthodontics, but we can also cover what we need in a surgical workup.

We also need a frontal analysis, which is taken from the patient's face. Most of the frontal workup is done in examining the patient clinically. This enables us to look at the orbital rim, cheekbone, sub-pupil, alar bases, nasal bases and canthus of the eyes.

All of this enables us to assess if we have transverse asymmetries, where the occlusal plane is canted instead of level. This also holds true with the mandibular plane, which we may also find is canted. This is especially true in cases where there's a degenerative process happening in one joint.

Head position, profile and frontal analysis

The natural head position is different for each individual patient. This will make the distance recorded for glabella to the true vertical line different.

To measure how far glabella is from SN (true vertical line), we first need to establish the patient's natural head position (Fig. 7). To do so, we have the patient stand in front of a mirror. First, the patient is asked to close his eyes and bob his head up and down three times.

After this is complete, the patient is asked to open his eyes and look himself directly in the eyes in the mirror. After we have established the natural head position, we then use the measurement gauge. Our goal is to make sure the leveling bubble is in the lines. This will allow us to take a measurement from the true vertical line to glabella.

Fig. 5_ Overlaid soft tissue on top of hard tissue.

Fig. 6_ Establishing the true vertical line based on natural head position.

Fig. 7_ Glabella to subnasale (SN).