



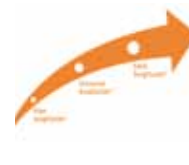**ITI celebrates 30 years**  
World Symposium taking  
place in April in Switzerland

►Page 2



**AO's 25 anniversary**  
Learn and have fun in Orlando  
this month at annual meeting

►Page 8



**SurgiGuide by Materialise**  
Drill guides provide link  
between planning, treatment

►Page 20

## Scientists develop smart coating for implants

By Daniel Zimmerman, DTI Group Editor

Osseointegration remains one of the biggest challenges in implant dentistry. Scientists from North Carolina State University are now reporting to have developed a "smart" coating that could help hip, knee and tooth replacements bond more closely with bone and ward off infections. Their research, which received funding by the U.S. government, could open doors to much safer and functional implants in dentistry.

According to the researchers, the new coating is comprised mainly of hydroxylapatite, a naturally occurring mineral also found in dentin and dental enamel. When applied to an implant it creates an amorphous outer layer touching the surrounding bone. This layer will dissolve over time, releasing calcium and phosphate, and encourage bone growth into the coating.

"We call it a smart coating because we can tailor the rate at which the amorphous layer dissolves to match the bone growth rate of each patient," said Dr. Afsaneh Rabiei, a North Carolina associate professor of mechanical and aerospace engineer-

→ **IT** page 2

## Immediate single-tooth replacement, provisionalization

By Dr. Graham Magee

With more than 40 years of clinical evidence, titanium endosseous implants have become an acceptable (evidence-based) form of treatment to replace natural teeth and should be considered as an alternative to either a partial denture or bridge.

Immediate implant placement with simultaneous immediate function or immediate loading has been gaining momentum during recent years and can be a very predictable method in providing implant treatment for our patients.

There have been various timeframes used for the definition of immediate implant placement. Hammerle et al. (2004) suggested that immediate implant placement was when an implant was placed following tooth extraction and as part of the same surgical procedure.

In the same paper, the consensus statements say, "implants should not be placed at the time of tooth extraction if the residual tooth morphology precludes attainment of primary stability."

It also states that, "If buccal plate integrity is lost, implant placement is not recommended at the time of tooth removal. Rather, augmentation therapy is performed."

The implant is then placed after healing, that being 12 to 16 weeks,

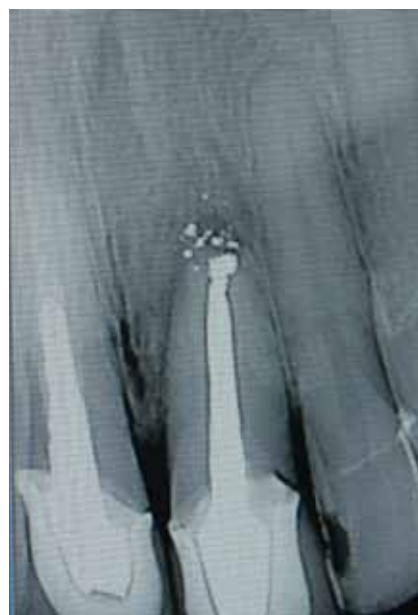

Fig. 1: Radiograph of failing upper left central incisor.

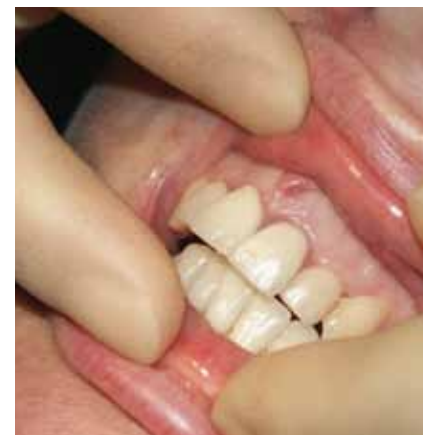

Fig. 2: Pre-operative view of UL1.

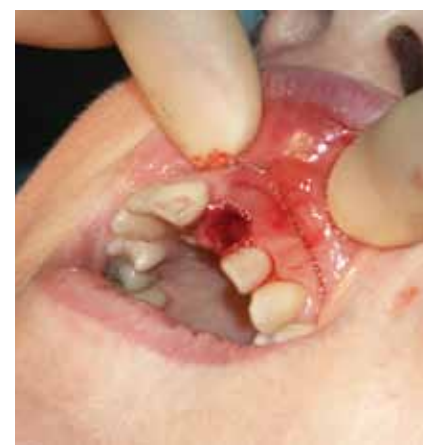

Fig. 3: Extraction of UL1.

or even longer than 16 weeks.

It has also been reported that infection adversely affects immediate implant placement (Rosenquist and Grenthe 1996; Grunder et al. 1999) and is a contraindication for immediate placement of an implant into an extraction socket.

→ **IT** page 4

AD

**OsteoCeL®**

The Future IS Now.

See page 3.

PRSRST STD  
U.S. Postage  
PAID  
Permit # 306  
Mechanicsburg, PA

Dental Tribune America  
213 West 35th Street  
Suite #801  
New York, NY 10001



Geneva,  
Switzerland

## ITI World Symposium 2010: 30 years of leadership, credibility

The International Team for Implantology (ITI), a leading academic organization dedicated to the promotion of evidence-based research and education in the field of implant dentistry, is hosting the 11th ITI World Symposium from April 15–17 in Geneva, Switzerland.

At the same time, the organization, which was founded in 1980, is celebrating its 30th anniversary.

Since the first ITI World Symposium in 1998, the meeting has developed into one of the most prestigious implant dentistry events worldwide. Under the heading “30 years of leadership and credibility”, a total of 104 experts from 25 countries will present on current themes and developments in the field. The following main areas will be explored at both a theoretical and practical level over the symposium’s three days:

- New clinical methods for diagnosis and treatment planning
- New and proven treatment procedures
- Complications in implant dentistry or dealing with reality

There will be simultaneous translation available for all the presentations in the main sessions from English into German, French, Italian, Spanish, Portuguese, Japanese, Korean, Mandarin Chinese, Russian, Turkish and Farsi.

For the first time, the ITI World Symposium is complementing its main sessions with two full-day pre-symposium courses on April 14 as well as an industry exhibition.

The attractive and historic city of Geneva at the heart of Europe is the ideal location for the event. The city’s excellent infrastructure in combination with the Palexpo Congress Center offers both exhibitors and participants excellent conditions.

For detailed information and to register, go to [www.iti.org](http://www.iti.org).

### About the ITI

The International Team for Implantology (ITI) unites professionals around the world from every field of implant dentistry and related tissue regeneration. As an independent academic association, it actively

promotes networking and exchange among its membership. ITI fellows and members, who now number more than 7,000 in total, regularly share their knowledge and expertise from research and clinical practice at meetings, courses and congresses with the objective of continuously improving treatment methods and outcomes to the benefit of their patients.

The ITI is active in three principal areas: research, development and education. In 30 years, the ITI has built a reputation for scientific rigor combined with concern for the welfare of patients. The organization focuses on the development of well-documented treatment guidelines backed by extensive clinical testing and the compilation of long-term results.

The ITI funds research as well as scholarships for young clinicians, organizes congresses and continuing-education events and also publishes reference books such as the ITI Treatment Guide series. For more information, see [www.iti.org](http://www.iti.org). ■

← ■ page 1

ing and co-author of a paper describing the research. “This is important because people have very different rates of bone growth.”

He added that his team also incorporated silver nanoparticles

throughout the coating to act as antimicrobial agents as the amorphous layer dissolves. This will not only limit the amount of antibiotics patients will need following surgery, but provide protection from infection at the implant site for the life of the implant, Rabiei said.

Current coating processes, involv-

ing hydroxyapatite and other forms of calcium phosphate, have shown several disadvantages and limited flexibility in controlling coating crystallinity.

Earlier studies also found that hydroxylapatite may not resorb quickly enough and may block the space for new bone tissue to grow. ■

**Tell us  
what  
you  
think!**

Do you have general comments or criticism you would like to share? Is there a particular topic you would like to see more articles about? Let us know by e-mailing us at [feedback@dental-tribune.com](mailto:feedback@dental-tribune.com). If you would like to make any change to your subscription (name, address or to opt out) please send us an e-mail at [database@dental-tribune.com](mailto:database@dental-tribune.com) and be sure to include which publication you are referring to. Also, please note that subscription changes can take up to 6 weeks to process.

### ■ Corrections

Implant Tribune strives to maintain the utmost accuracy in its news and clinical reports. If you find a factual error or content that requires clarification, please report the details to Managing Editor Sierra Rendon at [s.rendon@dental-tribune.com](mailto:s.rendon@dental-tribune.com).

## IMPLANT TRIBUNE

The World's Newspaper of Implantology · U.S. Edition

### Publisher & Chairman

Torsten Oemus  
[t.oemus@dental-tribune.com](mailto:t.oemus@dental-tribune.com)

### Vice President Global Sales

Peter Witteczek  
[p.witteczek@dental-tribune.com](mailto:p.witteczek@dental-tribune.com)

### Chief Operating Officer

Eric Seid  
[e.seid@dental-tribune.com](mailto:e.seid@dental-tribune.com)

### Group Editor & Designer

Robin Goodman  
[r.goodman@dental-tribune.com](mailto:r.goodman@dental-tribune.com)

### Editor in Chief

Sascha A. Jovanovic, DDS, MS  
[sascha@jovanoviconline.com](mailto:sascha@jovanoviconline.com)

### Managing Editor/Designer Implant & Endo Tribunes

Sierra Rendon  
[s.rendon@dental-tribune.com](mailto:s.rendon@dental-tribune.com)

### Managing Editor/Designer Ortho Tribune & Show Dailies

Kristine Colker  
[k.colker@dental-tribune.com](mailto:k.colker@dental-tribune.com)

### Online Editor

Fred Michmershuizen  
[fmichmershuizen@dental-tribune.com](mailto:fmichmershuizen@dental-tribune.com)

### Account Manager

Humberto Estrada  
[h.estrada@dental-tribune.com](mailto:h.estrada@dental-tribune.com)

### Marketing Manager

Anna Wlodarczyk  
[a.wlodarczyk@dental-tribune.com](mailto:a.wlodarczyk@dental-tribune.com)

### Marketing & Sales Assistant

Lorrie Young  
[l.young@dental-tribune.com](mailto:l.young@dental-tribune.com)

### C.E. Manager

Julia Wehkamp  
[j.wehkamp@dental-tribune.com](mailto:j.wehkamp@dental-tribune.com)

Dental Tribune America, LLC  
213 West 35th Street, Suite 801  
New York, NY 10001  
Phone: (212) 244-7181, Fax: (212) 244-7185



Published by  
Dental Tribune America

© 2010, Dental Tribune America, LLC.  
All rights reserved.

Dental Tribune makes every effort to report clinical information and manufacturer’s product news accurately, but cannot assume responsibility for the validity of product claims, or for typographical errors. The publishers also do not assume responsibility for product names or claims, or statements made by advertisers. Opinions expressed by authors are their own and may not reflect those of Dental Tribune International.

### Editorial Advisory Board

#### Dr. Sascha Jovanovic, Editor in Chief

Dr. Bernard Touati

Dr. Jack T. Krauser

Dr. Andre Saadoun

Dr. Gary Henkel

Dr. Doug Deporter

Dr. Michael Norton

Dr. Ken Serota

Dr. Axel Zoellner

Dr. Glen Liddelow

Dr. Marius Steigmann

25 Annual AO Meeting  
ORLANDO March 4-6

ACE

Visit ACE @ BOOTH #827

SURGICAL SUPPLY CO., INC.

OsteoGENESIS  
OsteoINDUCTION  
OsteoCONDUCTION  
**Osteo**cel®

**The  
Future  
Is Now.**

For more information  
or to place an order call **800.441.3100**

## A Bone Matrix Product Containing Stem Cells.

### The Properties of Autograft without Associated Risks

The proprietary processing technology that produces OsteoCel® results in a viable bone matrix product that preserves the native stem cells found in marrow rich bone. It is the only product available today that has the desired beneficial properties of autograft - osteoconduction, osteoinduction and osteogenesis — and that allows surgeons to provide their patients with optimal bone growth conditions without the added risk and cost of a secondary procedure.

### Low Immunogenicity

Mesenchymal stem cells are IMMUNE-PRIVILEGED cells that do not stimulate a cellular immune response. OsteoCel does not activate T cell proliferation, as shown *in vitro* from Mixed Lymphocyte Reaction (MLR) testing.

### Histologic Evidence

Positive clinical use of OsteoCel since 2005 demonstrates bone-forming ability. Histology from a human sinus augmentation study using OsteoCel shows substantial vital bone content at 16 weeks, with very low residual graft material.<sup>1</sup>

### Bone Formation

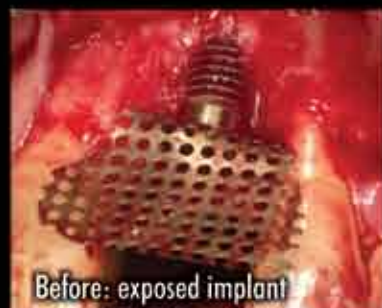Stem cells contained in OsteoCel are capable of differentiating into bone cells. Every lot of OsteoCel is tested for bone forming potential.

### Viable Cell Content

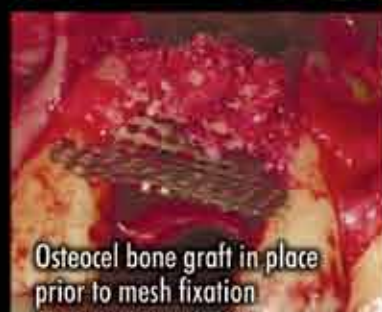The osteogenic potential arises from the stem cells in OsteoCel. Following processing of marrow-rich bone, release testing demonstrates osteogenic potential according to the following criteria:

- Rich supply of stem cells: Greater than 50,000 cells/cc
- Viability: Greater than 70% cell viability
- Positive osteogenesis: *In vitro* cell culture assay

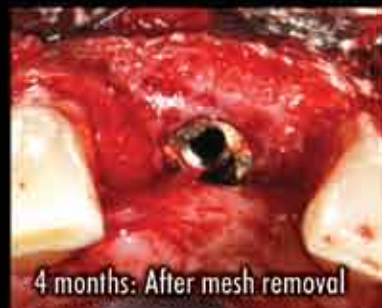<sup>1</sup> Histologic Evaluation of a Stem Cell Based Sinus Augmentation Procedure: A Case Series.  
— McAllister, Haghghat, Gonshor. — Journal of Perio., April 2009



Before: exposed implant



OsteoCel bone graft in place prior to mesh fixation



4 months: After mesh removal

Ridge Augmentation clinical case.

## An Evening Lecture Series

For details, visit [www.acesurgical.com](http://www.acesurgical.com)  
To register, call **800.441.3100**

March 1st • Fort Lauderdale, FL  
March 3rd • Tampa, FL  
\* March 4th • Orlando, FL  
March 11th • Atlanta, GA  
March 23rd • Chicago, IL  
March 25th • Washington, DC  
April 1st • Boston, MA

The 25th Annual Academy of Osseointegration Meeting  
**ACE CORPORATE FORUM**  
STEM CELL APPLICATIONS for Implant Site  
Preparation and for Around Natural Teeth  
presented by Bradley S. McAllister, DDS, PhD

Limited  
Availability\*  
Reserve  
today.

[www.acesurgical.com](http://www.acesurgical.com)

ACE Surgical Supply Company, Inc. • 1034 Pearl Street, Brockton, MA 02301

← page 1

**Predicable treatment concept**

Immediate implant placement and provisionalization is a predictable treatment concept (De Rouck et al. 2008). The success rate is at least com-

parable to data published for single-tooth implant placement using standard protocols in healed sites.

This happens providing careful appropriate patient selection is used and the surgeon is familiar with the techniques that differ from the standard two-stage protocol for implant

placement.

For the patient, the main advantage for immediate replacement and provisionalization is fewer surgical visits as well as providing immediate esthetics that are virtually indistinguishable to the original tooth. Sometimes, if the tooth being replaced is discolored due to non-vitality, the esthetics will provide an immediate improvement.

For the clinician, immediate replacement allows for minimal disruption of the soft tissue providing immediate peri-implant support through careful manufacture and design of the provisional restoration. This helps to maintain the stability of the gingival marginal tissues, which is necessary for a successful esthetic outcome.

**Root-filling failure**

The following is a case study of a 50-year-old female with a history of

a failing root-filled, upper-left central incisor. The root filling had been present for approximately 25 years and this had been apicected approximately 13 months before the tooth became problematic (Fig. 1).

The patient did not want another apicectomy and requested that the tooth should be extracted. The various options for restorations were discussed and as the neighboring central incisor was root filled and restored with a post crown, the lateral incisor was restored with a veneer due to microdontia, a bridge was not a viable option. The patient was adamant that she did not want a partial denture.

As the tooth was not infected and investigation had shown that the buccal plate was still intact, it was decided that the tooth could be extracted and immediately replaced with an implant fixture. This was to be utilized to support a Nobel Biocare immediate temporary abutment and a provisional crown.

**What the treatment involved**

Under local anaesthesia, a crevicular incision was used and no flap reflection. The upper left central incisor was extracted using a very careful (atraumatic) technique with a periosteal elevator to preserve the buccal plate of bone and careful manipulation of the gingival tissues.

Once the tooth was removed, the socket walls were curetted to remove any remnants of periodontal fibres or granulation tissue. The socket was inspected to ensure that the buccal plate was still intact (Fig. 5).

Using the standard protocol, the bone was first prepared by penetrating the palatal wall at the apical third. Great care needs to be taken in the osteotomy preparation as the palatal wall of the extraction socket is commonly very dense and difficult to prepare, which can cause "run-off" of the drill tip.

To achieve the initial perforation, the drill is held at an angle of approximately 45 degrees to the palatal wall. Once the drill has penetrated the pala-

→ page 6

**Quality Leader in 3D CBCT Imaging**

**PreXion**  
The World's Best Image Quality

Visit us at AO Booth #1920

The PreXion 3D Dental CBCT Scanner has the highest resolution of any Cone Beam System. Additional benefits include:

- **Soon:** Implant planning feature
- Upgraded panoramic view
- Generate more revenue
- Four different scanning modes
- User-friendly controls and software
- Powerful diagnostic 3D planning tools
- Proprietary XTrillion processor
- Ideal for implant planning
- Small foot print fits anywhere

Contact us today for an in-office demonstration at (650) 212-0300 | info@prexion.com | www.prexion.com



Fig. 4: Immediate provisional abutment (IPA).

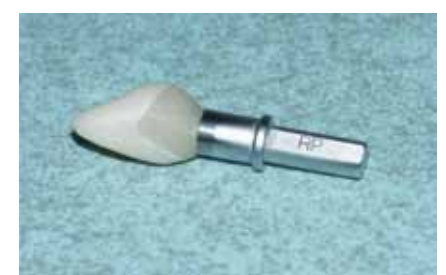

Fig. 5: Provisional crown being manufactured on IPA.

# The Experts Agree **Picasso** is #1

7 Watts for Only **\$4,995**

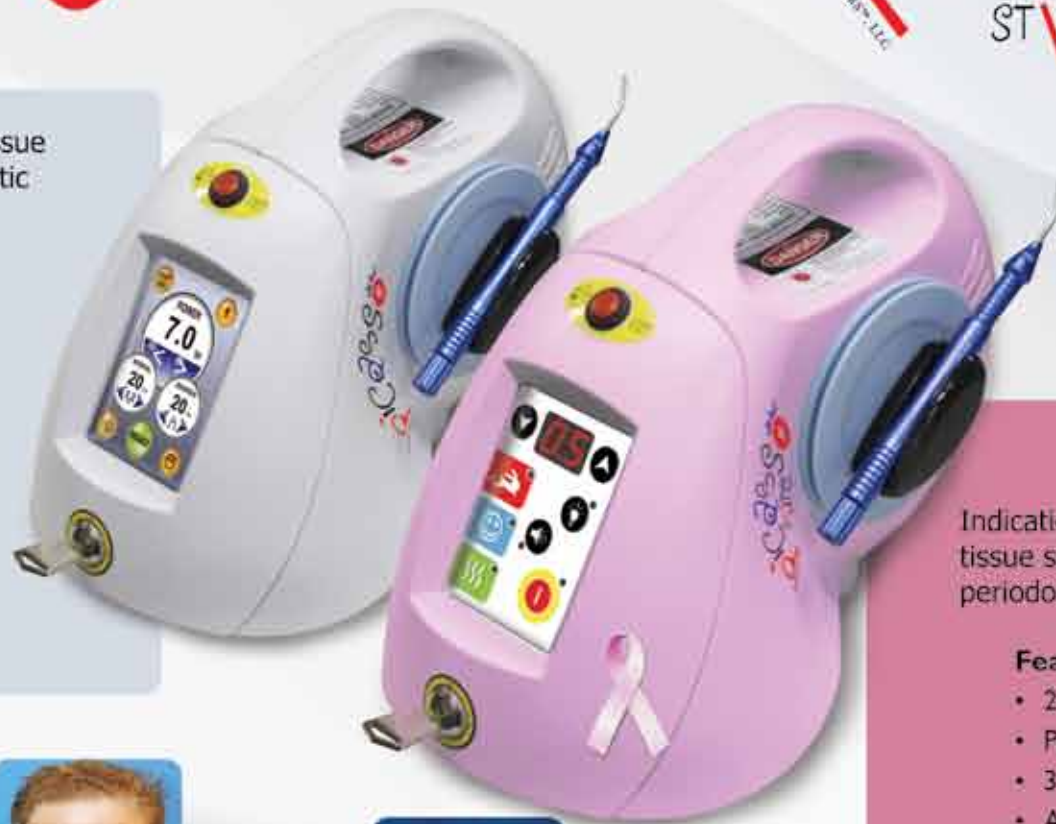2.5 Watts for Only **\$2,495**



Indications for use include soft tissue surgery, endodontic and periodontic treatments, and tooth whitening.

**Features:**

- 7 Watts of power
- Pulse/continuous modes
- 8 Customizable presets
- Color touchscreen
- Adjustable aiming beam
- Multiple language menu
- 3-year warranty
- Training DVD



**A Limited Edition (LE) Picasso Lite is available in pink.**

AMD LASERS proudly announces that we are "lasing for a cause" in the fight against breast cancer. Through June of 2010, we have pledged to donate \$15,000 to the National Breast Cancer Foundation.



Indications for use include soft tissue surgery, endodontic and periodontic treatment.

**Features:**

- 2.5 Watts of power
- Pulse/continuous modes
- 3 Customizable presets
- Adjustable aiming beam
- 2-year warranty
- Training DVD



**Ross Nash, DDS**  
Nash Institute  
Charlotte, NC



**Glenn van As, DMD**  
International Lecturer  
N. Vancouver, Canada



**Ron Kaminer, DDS**  
International Lecturer  
Master of Laser Dentistry  
Hewlett, NY



**Larry Rosenthal, DDS**  
Director, Aesthetic Advantage  
New York, NY



**Arun K. Garg, DMD**  
International Lecturer  
Aventura, FL



**James Jesse, DDS**  
International Lecturer  
Master of Laser Dentistry  
Colton, CA



**Jim Dunn, DDS**  
Associate Professor of  
Restorative Dentistry  
Loma Linda University  
Loma Linda, CA



**George Freedman, DDS**  
International Lecturer, Author  
Toronto, Canada



**Rodrick Loud, DDS**  
Private Practitioner  
Shreveport, LA



**Fay Goldstep, DMD**  
International Lecturer  
Toronto, Canada



7405 Westfield Blvd  
Indianapolis, IN 46240 USA  
www.amdlasers.com

Tel: (866) 999-2635  
Tel: +1 (317) 202-9530  
Fax: +1 (678) 868-4108



← **IT** page 4

tal wall, the angle is changed to then run more-or-less parallel to the angle produced by the buccal plate.

In the anterior maxilla, implant placement is typically toward the palatal aspect of the socket. Ideally, there

should be a space of 0.5 mm to 1 mm between the buccal plate and the anterior surface of the fixture. The site was further prepared using the standard drill sequence.

A Nobel Speedy Replace regular platform fixture (4 mm x 15 mm) was then placed, which stopped at a torque

value of 35 Ncm. It is recommended that if a torque value of 35 Ncm cannot be achieved, the implant should not be brought into immediate function.

A cover screw should be used and the implant submerged; therefore, some other temporary measure such as a Maryland Bridge should be used. In these conditions, the root could even be sectioned from the extracted tooth and the crown bonded to the adjacent tooth.

Primary stability is very important in this procedure as the bone support needs to be strong enough to support the fixture and prevent micromotion from exceeding the threshold above which fibrous encapsulation prevails over osseointegration (Szmukler-Moncler et al. 1998).

An immediate provisional abutment (IPA) (Fig. 4) was fitted to the implant and fastened down to 20 Ncm.

The abutment is non-engaging, screw-retained and inserted using a multi-unit abutment driver.

The abutment has a 1.5 mm depth of shoulder and comes with a plastic coating, which can be used with acrylic provisional materials. I find, however, that when using composite materials it is better to discard the coping and cement the composite to the IPA.

A provisional composite crown was pre-manufactured by the laboratory. A small amount of Tetric Flow composite (any flowable composite would also work) was placed in the provisional crown. A sufficient amount was used to engage with the metal of the IPA, but not spill out and touch the tissues. This was then light cured whilst the provisional was supported in the correct position.

The provisional was then removed and placed on another IPA connected to a protection analogue. The voids were then filled with more Tetric Flow.

The margins were then shaped and polished to ensure a smooth shoulder with no ledges or deficiencies against the IPA (Figs. 5, 6). The provisional crown was then cemented to the IPA with a very small amount of Tempbond, ensuring that no cement extruded into the tissues.

**Adjusting the provisional crown**

It is important at this stage to ensure that the provisional crown is adjusted to ensure that there is no contact with the lower teeth in centric occlusion (Fig. 7) and no contact in any protrusive or excursive movements (for example, not immediate loading).

The patient was advised to try to avoid the provisional crown and not to apply any forces while eating for the first four weeks.

The provisional crown was left in situ for six months (it is recommended that an absolute minimum of three months should be allowed for osseointegration before disturbing the immediately placed implant). The

→ **IT** page 7

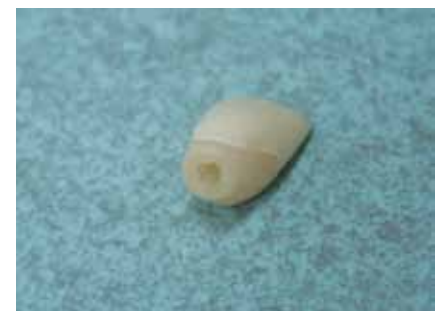

Fig. 6: Internal hex that has been created by curing flowable composite over the IPA.

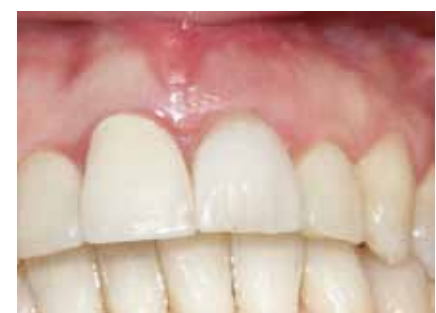

Fig. 7: Immediate provisional abutment (IPA).

← **IT** page 6

provisional crown was removed and a fixture-head impression taken of the implant.

The adjacent post crown (upper right central incisor) was also prepared for a new crown to ensure a good match for both central incisors.

A Procera zirconium abutment was connected to the fixture (Fig. 8). The abutment screw was fastened down at the recommended torque of 35 Ncm. Procera porcelain crowns were fitted to both central incisors (Fig. 9).

The implant-retained crown was cemented with Tempbond. It is recommended that the definitive restorations on implants should be cemented with temporary cement as this allows access to the implant, if necessary.

Immediate implant placement is gaining momentum. Clinicians should be aware, however, that this is a higher-risk procedure and should only be attempted by those surgeons with experience in dental implant surgery particularly when dealing with the esthetic zone. **IT**

**References**

- De Rouck T, Collys K, Cosyn J. 2008, "Single-Tooth Replacement in the Anterior Maxilla by Means of Immediate Implantation and Provisionalization: A Review." *Int. J. Oral Maxillofac. Impl.*, vol 23, no. 5, pp. 897-904.
- Grunder U, Polizzi G, Goene R, et al. 1999, "A 3-Year Prospective Multicentre Follow-up Report on the Immediate and Delayed-Immediate Placement of Implants." *Int. J. Oral Maxillofac. Impl.*, vol 14, no. 2, pp. 210-216.
- Hammerle, CHF, Chen, ST, Wilson, TG. 2004, "Consensus Statements and Recommended Clinical Procedures Regarding the Placement of Implants in Extraction Sockets." *Int. J. Oral Maxillofac. Impl.*, vol. 19, Suppl: 26-28.

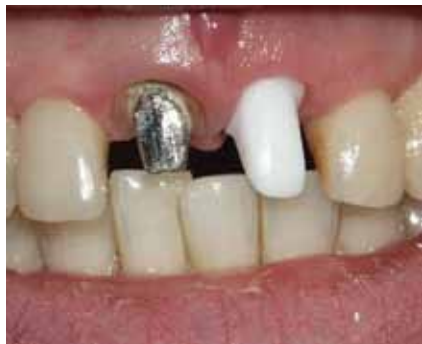

Fig. 8: Provisional crown being manufactured on IPA.

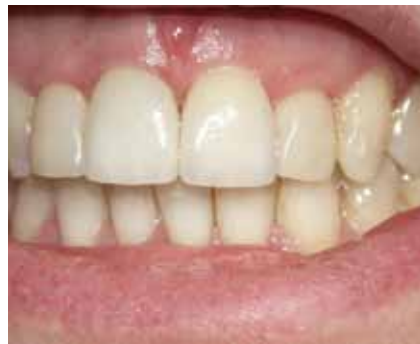

Fig. 9: Internal hex, which has been created by curing flowable composite over the IPA.

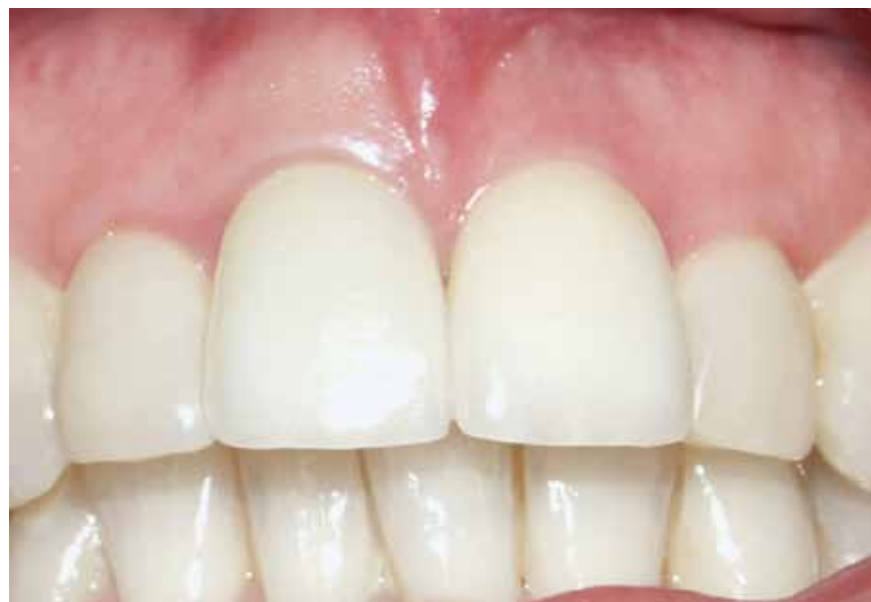

Fig. 10: Final restorations 18 months after fitting.

- Rosenquist B, Grenthe B. 1996, "Immediate Placement of Implants into Extraction Sockets: Implant Survival." *Int. J. Oral Maxillofac. Impl.*, vol. 11, no. 2, pp. 205-209.
- Szmukler-Moncler S, Salama H, Reingewirtz Y, and Dubruille JH. 1998, "Timing of Loading and Effect of Micromotion on Bone-Dental Implant Interface: Review of Experimental Literature." *J. Biomed. Mater. Res.*, vol. 43, no. 2, pp. 192-203.

**IT About the author**

Dr. Graham Magee qualified at Liverpool University in 1978 and in 1993 he created the Chester Dental Implant Centre within the general practice where he was a partner.



Graham has undergone extensive postgraduate training to develop his skills in dental implant surgery and cosmetic dentistry including a master's degree in dental implantology from Sheffield University. He continues with his postgraduate education regularly attending courses in Britain, Sweden, France and America and also gives lectures on the aspects of dental implantology and CT scanning and 3-D planning in advanced dental implant therapy. Graham also runs postgraduate training courses in implant dentistry for dental practitioners in his practice and is a member of the Association of Dental Implantology and of the American Academy of Osseointegration. To contact Graham or for further information on Chester Dental Implant Centre, call +44 (12) 44 340 177.

AD

**Send  
us  
your  
case  
study!**

Have an interesting implant case you would like to share with 15,000 of your peers? To have your case study considered for publication in *Implant Tribune*, send your 800- to 1,200-word case study and up to 12 high-resolution photos to Managing Editor Sierra Rendon at [s.rendon@dental-tribune.com](mailto:s.rendon@dental-tribune.com). Authors will be notified of publication and have an opportunity to review the designed case study prior to final publication. Cases will be published pending editor approval and space availability.




AD


**Dentatus**

**ANew** NARROW body implants

**DESIGNED TO FIT**

where **no** others can



Anew Implants in 1.8, 2.2 & 2.4mm are FDA indicated for long-term support of crowns and multi-unit restorations. Designed to fit in limited bone & narrow spaces.

The Anew Implant & Prosthetic System was developed in conjunction with NYU School of Dentistry.

For more information, visit us at [www.dentatus.com](http://www.dentatus.com) or call (800) 323-3136 and ask us about our March 2010 promotional offer for first time users.

©2010 DENTATUS USA, LTD. PATENTED PENDING




**Dental Collab** BETA

FINALLY A SOLUTION FOR MENTORING WITH EXPERTS & PEERS.

[WWW.DENTALCOLLAB.COM](http://WWW.DENTALCOLLAB.COM)

FIRST MONTH FREE CODE: ITDC09

IT'S NEW



The Walt Disney World  
Dolphin Resort

# AO celebrates 25 years by 'going to Disney World'

*Various approaches, complications among meeting highlights*

Different approaches to implant therapy and solutions to unexpected complications are among the highlights of the Academy of Osseointegration's 25th Anniversary Annual Meeting, March 4-6, at the Walt Disney World Dolphin Resort in Orlando.

tion's 25th Anniversary Annual Meeting, March 4-6, at the Walt Disney World Dolphin Resort in Orlando.

"Treatment Approaches: Controversies in Implant Dentistry," to be held Friday, March 5, and Saturday's "Unexpected Complications: Complications and Solutions," are key pillars of the meeting's overall theme, "The Formula for Predictable Implant Success."

"The 2010 meeting will serve as a celebration of everything we have learned in the past 25 years, and how that knowledge is applied for the benefit of our patients today," Annual Meeting Committee Chair Dr. Stuart Froum, New York, N.Y., explains.

## Approaches, controversies

Friday's implant therapy program gathers an international roster of experts to review the latest treatments and materials through an evidence-based approach. Saturday's session on complications will explore why problems occur, how to treat them and what we can do to prevent them.

The 25th anniversary annual meeting will kick off Thursday, March 4, with the opening symposium, "A Quarter Century of Experience: The Formula for Predictable Implant Success in the Esthetic Zone."

Other AO Annual Meeting highlights will include:

**Hands-on workshop:** This pre-meeting, daylong series of sessions will explore how 3-D imaging and navigation technology helps providers fabricate surgical templates, generate final prosthesis and place implants more effectively as part of the "team approach" concept.

**AO Corporate Forum:** AO's 2010 Corporate Forum features 36 manufacturer-hosted educational sessions that showcase the latest research, products and developments.

**"Two-Track" scientific program:** The surgical track will explore "Surgical Procedures to Enhance Implant Success in the Esthetic Zone." The restorative track, "Where, When, Why and How," will cover prosthetic considerations for restoring angled or tilted implants; endodontics vs. implants; and early predictors for biological and technical complications.

**Round table clinics:** Twelve separate sessions offer attendees the opportunity to discuss diverse topics.

**Limited attendance lectures:** Increase interaction between annual meeting attendees and world-class clinicians on a wide range of topics.

**Allied staff program:** The annual meeting's allied staff program offers concurrent sessions designed for dental lab technicians and hygienists.

For more information, see the 2010 annual meeting at the academy's Web site, [www.osseo.org](http://www.osseo.org). ■

AD

**OSADA ENAC** Quartz Crystal  
Piezoelectric Ultrasonic System

INTRODUCING

## Piezo powered ultrasonic scalpels

Utilizing the wonder of the piezoelectric ultrasonic system, surgical scalpels work like magic: separating soft tissue from the hard surface of bone or tooth with significantly reduced injuries to soft tissue, nerves and vessels, resulting in a faster recovery. Surgeons have better control of the instrument for precise cutting of the mineralized tissue with minimum force and pressure applied toward the patient. Fine ultrasonic oscillation (ENAC: 30kHz) with constant irrigation provides a continual antiseptic result.

Incisions are gently placed (like a laser) and users have a good control of precise incisions by adjusting the angle of the tips.

Osada tips are interchangeable with all Enac models



ENAC OEW10  
All in one with extra high power and peristaltic pump



Osada's New Surgical Tips designed by Dr. Golz:

**SWORD TIP (L)** for the upper jaw  
**SWORD TIP (S)** for the lower jaw

- Flap Operation (soft tissue)
- Osteotomy (bone dissection)
- Sinus window opening
- Osseous expansion (dilatation) on a very thin alveolar ridge
- Creation of insertion path for an implant

**HOE (SPADE) TIP**

- Sinus membrane separation
- Bone tissue collection (cortical & medullary)
- Soft tissue separation (flap operation)
- Apicoectomy preparation (removal of infected root apex & destructed osseous tissue)
- Adherent cyst separation from the bone
- Cleaning deep socket after extraction of the tooth

**BUGLE (TRUMPET) TIP**

- Sinus membrane separation
- Artificial bone filling
- Primary fixation of artificial membrane

**SPOON TIPS (RIGHT and LEFT)**

- Excavation & collection of infected tissue from small areas
- Collection of small amounts of medulla & spongy bone tissue
- Smoothing margin of bone & alveolar ridge

**Starter Kit: a Set of 6 SURGICAL TIPS by Dr. Golz**

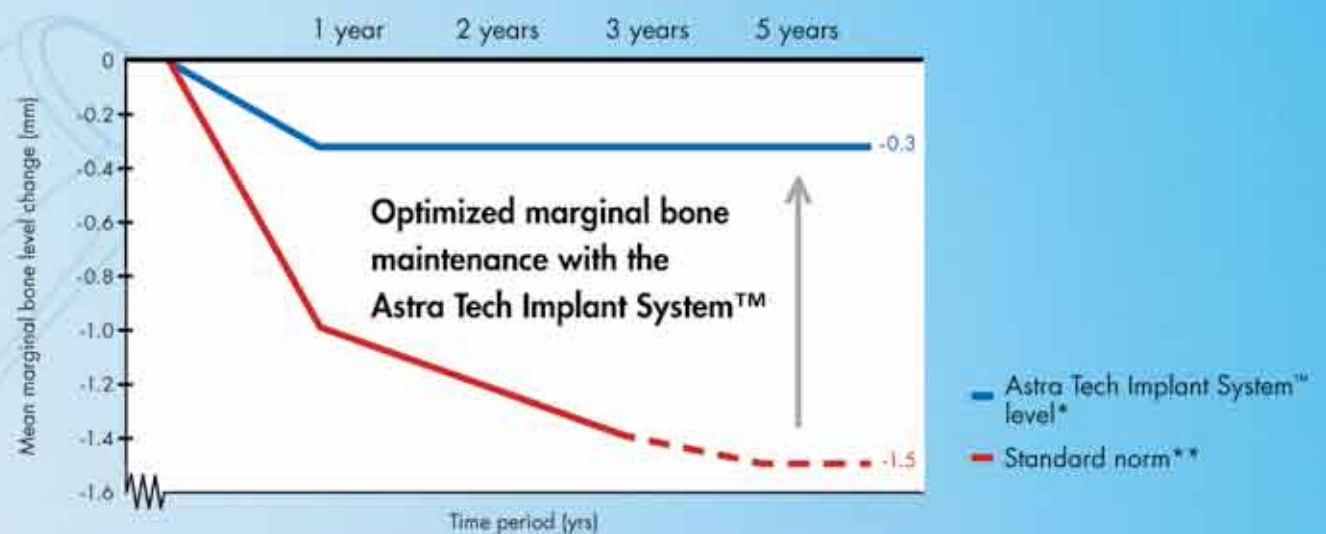


# Time to challenge old truths

## Astra Tech Implant System™ – setting a new standard

How do you achieve optimal long-term treatment outcomes for your patients? The standard norm regarding dental implant treatment success from 1986 does not reflect what is possible to achieve today. There are no reasons why the clinician or the patient

should accept a marginal bone loss of up to 1.5 millimeters based on a standard set 20 years ago. It has been proven in study after study that with the Astra Tech Implant System™ the mean marginal bone level reduction is only 0.3 millimeters over five years.



- \* Astra Tech Implant System™ level based on data from more than 40 published articles presenting radiological data; literature search April 2008
- \*\* Standard norm according to:  
Albrektsson T., et al., Int J Oral Maxillofac Implants 1986;1(1):11-25  
Albrektsson T. and Zarb G.A., Int J Prosthodont 1993;6(2):95-105  
Roos J., et al., Int J Oral Maxillofac Implants 1997;12(4):504-514

Visit us at booth #809  
at the AO Meeting.

**WHY  
SETTLE  
FOR LESS?**

**ASTRATECH  
DENTAL**  
*Get inspired*

**ASTRA**  
ASTRA TECH

 A company in the  
AstraZeneca Group

800-531-3481. [www.astratechdental.com](http://www.astratechdental.com)