

DENTAL TRIBUNE

The World's Dental Newspaper · U.S. Edition

JUNE 2013 — VOL. 8, NO. 6

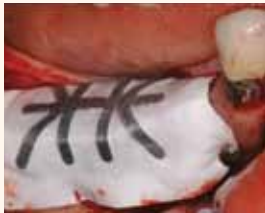www.dental-tribune.com

IMPLANT TRIBUNE

VERTICAL GUIDED BONE REGENERATION

Ensure success with precise surgical protocols for flap design and passivation.

► page B1



ENDO TRIBUNE

AAE MEETS IN HAWAII

The American Association of Endodontists held its annual meeting in April. Here's a review and photos.

► page C1



HYGIENE TRIBUNE

ADHA MEMBERS GATHER IN BOSTON

The American Dental Hygienists' Association meeting is this month.

► page D1



Dentistry in space

Interview with former NASA dentist Dr. Michael H. Hodapp

By Dental Tribune International

A toothbrush of Buzz Aldrin, a crew member of Apollo 11, was recently auctioned for \$22,705, prompting some renewed interest in dental hygiene in space. Interestingly, more than 40 years after that mission's historic moon landing, astronauts are using similar everyday oral care products in space. For an update, Dental Tribune spoke with former NASA dentist Dr. Michael H. Hodapp about potential dental emergencies in space and how astronauts will maintain oral health on multiyear missions in the future.



Dr. Michael H. Hodapp

budget, they have closed the NASA dental clinic, so there are no dentists contracted by the agency at this point. Astronauts seek dental care by private practitioners and are followed closely by NASA-employed flight physicians.

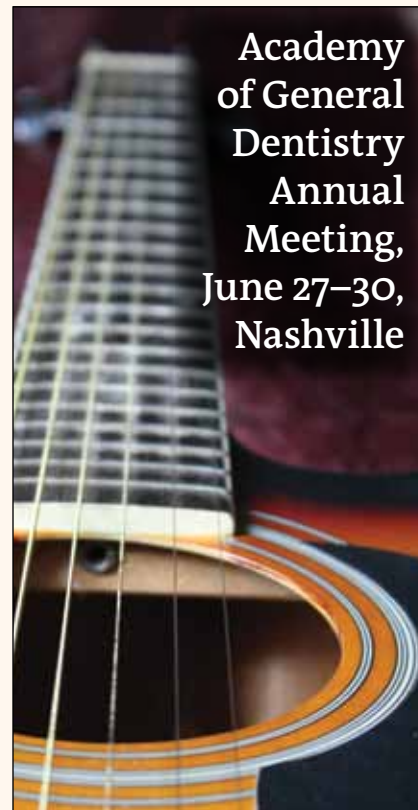How did you become involved with the agency?

In 1994, another dentist working for NASA informed me that a position had become available to care for the astronauts and their families at NASA and asked me if I would be interested. After a series of interviews, I was awarded the position. I served NASA as a contractor for over a decade before I went back into private practice in 2004.

Do you know how many dentists are employed by NASA?

Because of the recent cutbacks of NASA's

► See SPACE, page A2



Academy of General Dentistry Annual Meeting, June 27-30, Nashville

'Before great dentists practice, they tune up their skills,' is how AGD President Jeffrey M. Cole, DDS, MBA, FAG, explains the AGD's annual meeting tagline: 'Tune Up Your CE in Tennessee.' In addition to a comprehensive selection of C.E. courses, the event features a three-day exhibit hall and an abundance of family-friendly social events, many centered around Nashville's music scene. Photo/ Provided by www.pdphotos.com.

► See page A4

NEWS

A2

- Lunar toothbrush: \$22,705

MEETINGS

A4-A6

- Nashville's newest meeting facility hosts AGD annual meeting
- Greater New York Dental Meeting redesigns exhibit floor, adds tech pavilions
- Yankee Dental Congress expands team-development-day concept
- Pacific Dental Conference combines education, networking, scenic locale

INDUSTRY CLINICAL

A7-A8

- Review of the Er:YAG and Nd:YAG dual wavelength-optimized periodontal therapy protocol

INDUSTRY NEWS

A9-A14

- BEAUTIFIL Flow Plus now available in B1, B2 and C2
- Expert Dental CE instructors reflect international focus
- Aribex adds a color, upgrades features on NOMAD Pro 2
- New from DENTSPLY Caulk: Palodent Plus EZ Coat Matrices
- Dental marketing in 2013: Your website is your smile

AD

NO MORE SLUMPING OUT OF CLASS V'S!

[conventional flow]

GrandioSO
Heavy Flow

83% filled means up to 50% more fillers than weaker regular flowable composites. The new universal GrandioSO Heavy Flow gives you the high wear resistance only achieved by modern universal composites.

Learn more and order your **FREE SAMPLE**

at www.vocoamerica.com

Call 1-888-658-2584

GrandioSO
Flow

The first flowable composite that is strong enough for occlusal surfaces of class I and II restorations.

VOCO
THE DENTALISTS

PRSRT STD
 US POSTAGE
 PAID
 ORLANDO, FL
 PERMIT #1656

Dental Tribune America
 116 West 23rd Street
 Suite #500
 New York, N.Y. 10011

← SPACE, page A1

However, I am still called occasionally as a consultant for dental issues aboard the International Space Station, and future exploration-class missions.

How important is oral health for astronauts in general?

Oral health is a primary concern for astronauts and goes hand in hand with general health. All astronaut candidates are initially screened for dental issues prior to selection, and all those selected are expected to adhere to a meticulous oral hygiene routine and maintain good oral health. The primary goal is prevention. Yet, even with the highest standards in prevention, the potential for a dental emergency in space still exists. A recent analysis of all medical conditions determined that the one condition most likely to result in departure from the International Space Station is a dental abscess.

Russian cosmonaut Yuri Romanenko suffered two weeks of incapacitating tooth pain during the Salyut 6 mission in 1978. When were dental emergencies first included in mission protocol?

Unfortunately for Romanenko, according to reports, the Soviets did not have a dental contingency protocol at that time. The Russian space program has since made provision for such emergencies, however.

During the U.S. Mercury program, the flights were so short that there was no need for an in-flight dental emergency protocol, and prevention was the primary focus. Owing to the extended time spent in space during the Gemini program, a toothbrush was added to flight kits as a preventative measure. Apollo missions then incorporated a digestible dentifrice and floss, as well as antibiotics. Instrumentation like forceps and temporary filling materials was first introduced when the Skylab space station was launched into orbit in the early 1970s and has been part of the emergency kits ever since.

How frequently are astronauts given pre-flight checkups?

Once applicants are accepted, they undergo a thorough oral exam annually. The astronauts are classified into three categories: Class I astronauts have good oral health and are not expected to require dental treatment or re-evaluation for 12 months, Class II astronauts have some oral conditions that if left untreated are not expected to result in a dental emergency within 12 months, and Class III astronauts have an oral condition that if left untreated is expected to result in an emergency within a 12-month period. All astronauts are expected to retain a minimum Class II status, and only astronauts with Class I status prior to launch are considered for the International Space Station.

In addition to annual exams, astronauts undergo pre-flight exams 18 to 21 months before launch. During this exam, the astronaut undergoes a thorough clinical and radiographic exam, including bitewing and panoramic X-rays. All necessary treatment is then to be completed 90 days prior to launch. The astronaut undergoes an additional exam to rule out any hidden pathology or any unreported recent oral injuries

Lunar toothbrush: \$22,705

If you missed out on the bidding on a toothbrush Buzz Aldrin took to the moon, you can still make an offer: The winning bidder, who got the piece of space memorabilia for \$22,705 in the late-April auction, immediately put it up for resale.

Details are available through Heritage Auctions (www.ha.com). Here's how the auction house describes the item, which was among an extensive collection of space memorabilia auctioned from the estate of Steven R. Belasco, who was a top executive at Colgate for much of his business career: "A light blue Lactona S-19 model 'Tooth Tip' toothbrush, 6.5" long. Included also is the original 8" x 1.5" plastic pouch in which it flew with a piece of Velcro on the back for ease of storage. Used throughout the mission, including in the Lunar Module Eagle while on the moon. Copies of two pages from the Apollo Operations Handbook showing information on the contents of the Oral Hygiene Set are included. The very point of the rubber tip has broken off but is present in the case. Signs of use, otherwise very fine condition."

(Source: Heritage Auctions)



A toothbrush and pouch used by astronaut Buzz Aldrin's on the Apollo 11 moon-landing mission brings more than \$20,000 at auction. Photo/Provided by Heritage Auctions

30 to 90 days before launch. The astronaut is also expected to follow a meticulous oral hygiene routine during flight.

No in-flight dental emergency has ever been reported by NASA. What problems do you think are most likely to occur?

While the chances of a dental emergency occurring in space are low, the potential is always there. For instance, when astronauts move large objects, the inertia of mass and velocity can potentially cause facial injuries and result in either a medical or dental emergency or both. Besides breaking a tooth, other considerations include luxation, clenching, grinding, split teeth or the fracturing of a cusp while chewing. Even with the most meticulous dental exam and hygiene program, there is always a possibility that a tooth abscess could form due to trauma, hidden caries or a failing root canal.

Which dental emergencies are astronauts trained to handle by themselves?

There are two crew medical officers (CMOs) aboard every mission, and they are trained to perform a number of dental and medical emergency procedures. On board, CMOs have the capability to treat with antibiotics and analgesics, administer anesthetics, place temporary dental fillings, replace a crown with temporary cement, treat exposed pulp, and as a last resort, extract teeth.

Any emergency treatment would include communication with ground support flight physicians, as the CMOs are not necessarily physicians or dentists themselves. However, because the International Space Station is in low earth orbit, a true emergency situation would likely result in a return to earth for proper treatment.

Future missions will take astronauts to other planets, such as Mars. What are



A toothbrush and toothpaste float in a sky deck of a Shuttle orbiter. Toothpaste and floss were added during the Apollo missions. Today, U.S. astronauts can choose oral health care equipment to their liking. Photos/Provided by NASA and www.dvidshub.net.

the main challenges that these long-term flights pose regarding oral health?

We still do not know the long-term effects of space flight on the teeth, alveolar bone and periodontal health. It is well-documented that during space flight bone mineral density decreases in weight-bearing bones. It is not clear how this affects the teeth and alveolar bone and whether crew members will be more susceptible to tooth decay or periodontal disease.

Skylab oral health studies determined that there were increased counts of caries-producing bacteria

→ See SPACE, page A3

DENTAL TRIBUNE

The World's Dental Newspaper · US Edition

PUBLISHER & CHAIRMAN

Torsten Oemus t.oemus@dental-tribune.com

PRESIDENT & CHIEF EXECUTIVE OFFICER

Eric Seid e.seid@dental-tribune.com

GROUP EDITOR

Kristine Colker k.colker@dental-tribune.com

EDITOR IN CHIEF DENTAL TRIBUNE

Dr. David L. Hoexter feedback@dental-tribune.com

MANAGING EDITOR U.S. AND CANADA EDITIONS

Robert Selleck r.selleck@dental-tribune.com

MANAGING EDITOR

Fred Michmershuizen
f.michmershuizen@dental-tribune.com

MANAGING EDITOR

Sierra Rendon s.rendon@dental-tribune.com

PRODUCT/ACCOUNT MANAGER

Jan Agostaro
j.agostaro@dental-tribune.com

MARKETING DIRECTOR

Anna Kataoka-Wlodarczyk
a.wlodarczyk@dental-tribune.com

EDUCATION DIRECTOR

Christiane Ferret c.ferret@dtstudyclub.com

ACCOUNTING COORDINATOR

Nirmala Singh n.singh@dental-tribune.com

Tribune America, LLC

116 West 23rd St., Ste. #500
New York, N.Y. 10011
(212) 244-7181

Published by Tribune America

© 2013 Tribune America, LLC
All rights reserved.

Dental Tribune strives to maintain the utmost accuracy in its news and clinical reports. If you find a factual error or content that requires clarification, please contact Managing Editor Robert Selleck at r.selleck@dental-tribune.com.

Dental Tribune cannot assume responsibility for the validity of product claims or for typographical errors. The publisher also does not assume responsibility for product names or statements made by advertisers. Opinions expressed by authors are their own and may not reflect those of Tribune America.

EDITORIAL BOARD

Dr. Joel Berg
Dr. L. Stephen Buchanan
Dr. Arnaldo Castellucci
Dr. Gordon Christensen
Dr. Rella Christensen
Dr. William Dickerson
Hugh Doherty
Dr. James Doundoulakis
Dr. David Garber
Dr. Fay Goldstep
Dr. Howard Glazer
Dr. Harold Heymann
Dr. Karl Leinfelder
Dr. Roger Levin
Dr. Carl E. Misch
Dr. Dan Nathanson
Dr. Chester Redhead
Dr. Irwin Smigel
Dr. Jon Suzuki
Dr. Dennis Tartakow
Dr. Dan Ward

Tell us what you think!

Do you have general comments or criticism you would like to share? Is there a particular topic you would like to see articles about in Dental Tribune? Let us know by sending an email to feedback@dental-tribune.com. We look forward to hearing from you!

If you would like to make any change to your subscription (name, address or to opt out) please send us an email at database@dental-tribune.com and be sure to include which publication you are referring to. Also, please note that subscription changes can take up to six weeks to process.

←SPACE, page A2

such as *Streptococcus mutans* among crew members. It was concluded that this was due to the dehydrated diet that astronauts consume. This could be a potential contributor to oral health issues during extended missions, especially if a crew member begins to lapse in proper oral health care.

Dental emergencies in space would be challenging to handle as well. A mission to Mars would require a one-way flight duration of six to nine months. Owing to the alignment of earth and Mars, the nominal mission would spend either 30 days or a year and a half on the Martian surface. Were an oral emergency to occur during the outbound flight, there would not be a safe-return-to-earth capability. Not enough fuel could be carried to counteract all the forces of launch that propel the crew on their voyage. In essence, all emergencies would have to be handled by the CMOs either in flight or on a planet with a little more than one-third of the gravity of earth.

In space, "for every action, there is an opposite and equal reaction" has special meaning to the treating CMO and the crew member receiving treatment. Just the act of giving an injection would send the crew member and CMO darting away from each other if proper techniques were not followed. The luxury of gravity does not exist, and simple procedures can become major challenges without it. Consider for a moment trying to give CPR without the force of gravity holding you in place.

Working in the oral cavity poses special concerns, since the very act of breathing not counteracted by gravity would have a tendency to draw anything loosely held within the oral cavity back into the lungs.

There is also the concern of the limited medical skills of CMOs, and the one-way communication delay with ground support of 20 to 25 minutes. In other words, it could take 45 minutes for a flight physician to deliver instruction to the treating CMO. Prayers would be in order for the afflicted crew member.

What measures are being considered to overcome these problems?

Recent discussions in relation to exploration-class missions have proposed instrumentation for semi-annual dental exams and cleaning for each crew member, as well as additional equipment for the diagnosis and treatment of dental emergencies. Some of the equipment considerations include a high-definition intraoral camera system, a method for detecting interproximal decay and osseous infections while limiting radiation, as well as a battery-operated dental handpiece and headlight.

Material considerations include an intermediate restorative material that is easy to use, does not require special equipment for mixing or curing, releases fluoride, and could last for the duration of an exploration-class mission. The U.S. Navy is currently conducting research on a restorative material for field use that fits this description.

A glass ionomer restorative material is also under consideration, although this would require special packaging to allow for controlled mixture by hand in

a microgravity environment.

Discussion about medications indicated that all drugs would need to be freshly manufactured and would require special packaging to maximize shelf life, especially those medications that are sensitive to moisture and radiation. Software considerations include training videos for the crew members to review and train to keep abreast during their travel.

President Obama speaks of sending humans to Mars as early as 2030. Do you believe that these plans are realistic?

It is my understanding that there are no definitive plans for a manned mission to Mars in the near future. Recent cuts to NASA's budget have slowed progress for a manned mission to the red planet. Our closest neighbor is explored using robotics, and there is much to learn about Mars prior to risking the lives of

humans on such a distant journey.

However, planning and research for manned exploration-class missions is still being conducted, and the Orion project is still in progress. There are so many hurdles to overcome before such a journey could be undertaken.

Currently, NASA is formulating plans for a three-month mission to rendezvous with a near-earth asteroid. This would be a scientific mission requiring a one-month flight to rendezvous with the asteroid, conduct research and fly back to earth.

If NASA offered you the opportunity to go on a three-month mission like that, would you accept it?

Since I was a young boy I have looked to the heavens and been fascinated by its beauty and have always dreamed of going into space. Given the opportunity, I would go in a heartbeat.



A toothbrush and toothpaste in front of mission specialist Barbara Morgan on the flight deck of Shuttle Endeavour.

AD

Bringing the global community together...the journey never ends.

Discover a World of Difference with Williams Dental Laboratory Regional Events

- **Dr. Ed Suh**
September 6, 2013, Baton Rouge, Louisiana
- **Don't forget CORE I**
October 17, 18, 19, 2013, Dallas, Texas

- Create a constant revenue \$\$\$ stream WITHIN your office... NO NEED to refer out!
- Earn 13 units of CE credit (2 day session)
- Learn how to realize your dream future in dentistry
- Connect with the best dental community in the world
- Innovative techniques that will transform your practice
- Empower your patients beyond the limitations of their insurance

The instructors for these courses are hand-chosen clients of Williams Dental Laboratory and are REAL dentists in successful private practices... NOT consultants!

Register by visiting www.lviregionalevents.com or call 888.584.3237

800.713.5390 • 408.842.6269
 Bob@WilliamsDentalLab.com
 7510 Arroyo Circle • Gilroy, California 95020
www.WilliamsDentalLab.com
 Follow us on Facebook



Rendering of the newly opened Music City Center, Nashville's newest events facility and host to the Academy of General Dentistry annual meeting, June 27-30. Photo/Provided by Music City Center

Nashville's newest meeting facility hosts Academy of General Dentistry meeting

The Academy of General Dentistry 2013 Annual Meeting and Exhibits is one of the first major events being held at Nashville's 1.2-million-square-foot Music City Center, which just opened at the end of May.

The Music City Center bills itself as the city's "front porch." Located in the heart of downtown, it's steps from the historic Ryman Auditorium, Broadway honky tonks and other musical venues that have launched thousands of careers and given Nashville its "Music City" moniker.

Taking full advantage of the Music City Center's location, the AGD Presidential Concert is being held at the Ryman on Saturday, June 29. Described by event organizers as "an intimate evening of entertainment," the concert honors the AGD's latest Masters, Fellows and Lifelong Learning and Service Recognition (LLSR) recipients. Sponsored by the AGD Foundation, the Presidential Concert features musical guests T. G. Sheppard, Kelly Lang and Brinn Black. Tickets are \$50, with proceeds benefiting the Interfaith Dental Clinic's mission to provide comprehensive dental care to underserved communities.

Originally built as the Union Gospel Tabernacle in 1892, the Ryman is designated as a Nashville historic landmark. It is perhaps best known as the former home of the Grand Ole Opry and continues today as an iconic musical entertainment venue.

In addition to being so close to so many of Nashville's top attractions, musical and otherwise, the Music City Center has added its own contributions to the area's offerings. More than 70 interior and exterior locations at the complex were earmarked for display of public art as part of the master planning process. The center's governing body, the Nashville Convention Center Authority, budgeted \$2 million to finance the purchase of artworks for the convention center. The collection covers a broad spectrum of artistic media, such as paintings, suspended pieces, works on paper, new media, mosaics and light-based works.

The exhibit hall at the meeting is open from 4:30 to 7:30 p.m. on Thursday (welcome reception from 5:30-6:30 p.m.), 10 a.m. to 6 p.m. on Friday (networking reception from 5-6 p.m.) and from 10 a.m. to 3 p.m. on Saturday. Some of the exhibit hall hours are structured to be fully dedicated to the exhibit hall, with no competing events taking place during those time periods.

Thursday morning's keynote speaker at the opening general session is forensic anthropologist Bill Bass, PhD, with "Life as a Forensic Anthropologist." Bass is the founder and former director of the Forensic Anthropology Center (FAC) at the University of Tennessee, Knoxville. Known as "The Body Farm," the FAC is the world's only laboratory devoted to the study of human decomposition.

With Jon Jefferson, Bass is the author of the best-selling Body Farm mystery novels, the latest of which is "The Inquisitor's Key," released in May 2012. Bass is also the author or co-author of more than 200 scientific articles, as well as a critically acclaimed memoir about his career titled "Death's Acre."

Registration is now open for the Academy of General Dentistry 2013 Annual Meeting at www.agd.org.

(Source: Academy of General Dentistry, Music City Center)

AD

DENTISTRY BY DR. CHONG LEE, MCLAN, VA.

LVI can show you how to stay ahead of the curve

empower YOUR PRACTICE

invest *your time* IN YOUR FUTURE WITH CONTINUED EDUCATION

Discover a path that leads your practice to greater competitive power in the current marketplace. LVI will teach you techniques and procedures that will dramatically enhance the lives of you and your patients.

receive *education* CE CREDITS & COURSE INFO: 1 DAY SESSION

- Understand how 80% of your patients show signs of a poor bite.
- Discover where 90% of your patient's pain and discomfort comes from.
- Understand the impact of neuromuscular dentistry on esthetics and airway.
- Learn to take a neuromuscular bite.
- Live demonstration of proper jaw posture and bite taking with TENS.
- Educate patients about the true role and limitations of insurance.
- Help move past the insurance entitlement mentality.
- One day session provides 6 CE Credits.

register VISIT WWW.LVIREGIONALEVENTS.COM
OR CALL 888.584.3237

Palo Alto, CA 8/21 · Chicago, IL 8/16 · Denver, CO 9/13
Houston, TX 10/4 · Detroit, MI 10/11 · Boston, MA 10/18

LVI GLOBAL

LVI Regional Event
SPONSORED BY MICRODENTAL LABORATORIES

ADA CERP® Continuing Education Recognition Program

Oral Dental is an ADA CERP Recognized Provider. ADA CERP is a service of the American Dental Association to assist dental professionals in identifying quality providers of continuing dental education. ADA CERP does not accredit or endorse individual courses or instructors, nor does it imply acceptance of credit hours by boards of dentistry. Concerns or complaints about a CE provider may be directed to the provider or to ADA CERP at www.ada.org/cerp.

Academy of General Dentistry
Approved PACE Program Provider
FAJDMAGD Credit
6/20011 to 5/312015

Greater New York Dental Meeting redesigns exhibit floor, adds tech pavilions

Registration is now open for the 2013 Greater New York Dental Meeting (GNYDM). Organizers of the 89th annual meeting anticipate the largest attendance yet. New for the 2013 meeting will be a redesign of the exhibit floor — with the addition of new technology pavilions and a unique dental laboratory exhibition.

The exhibit floor and the diverse continuing education programs are the centerpiece of the expansive annual meeting. Attendees are able to walk the exhibit floor for free (no preregistration fee) and meet with more than 600 companies selling the newest products and advanced technologies.

The education program will include 300 full- and half-day seminars, essays and hands-on workshops. Among the specialty programs are topics including orthodontics, endodontics, cosmetic dentistry, pediatric dentistry and implant dentistry.

The GNYDM is introducing three new hands-on educational pavilions, including lasers, CAD/CAM and cone-beam/CT/X-rays. Each of these pavilions will house multiple companies providing information on the latest technologies that can be used in the dental office. Attendees will be able to instantly compare all the products in one location, while also becoming more familiar with the state-of-the-art technology by attending morning and afternoon educational programs presented at each pavilion.

The GNYDM and Aegis Publishing, Inside Dental Technology, have announced a ground-breaking partnership in laboratory technology. Collaboration 2013 will provide a designated laboratory exhibit area on the GNYDM exhibit floor, specialized education, demonstrations, digital dentistry and technology that will engage technicians and dentists side-by-side in an integrated, hands-on experience.

The GNYDM continues to offer a modern, high-tech free “live dentistry” arena daily from Sunday through Wednesday. The interactive “live” program features top clinicians performing dental procedures on actual patients on stage, in front of 600 attendees. It all takes place right on the exhibit floor. Attendees are encouraged to arrive early because seats fill quickly.

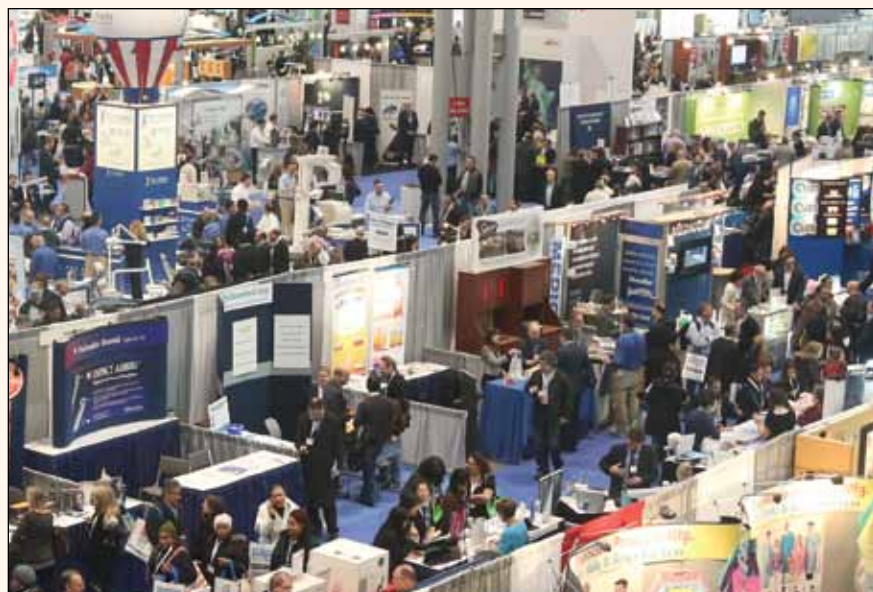The GNYDM is the largest dental congress and exhibition in the United States, registering 53,481 attendees from all 50 states and 130 countries in 2012.

There is never a pre-registration fee at the GNYDM. Dental profession-

als are invited to be part of the 2013 meeting to experience the energy of an event that draws top dental professionals from around the world. And you'll also get to see all that New York City has to offer during one of its most beautiful times of the year, Nov. 29 through Dec. 4.

Free registration is now open for the 2013 meeting at www.gnydm.com.

(Source: Greater New York Dental Meeting)



New on the exhibit floor at the 2013 Greater New York Dental Meeting will be three new hands-on pavilions showcasing the latest in lasers, CAD/CAM and cone-beam/CT/X-rays. Photo/Provided by GNYDM

AD

Explore Your Options...

Modern Advances, Techniques and Procedures designed to dramatically enhance the lives of you and your patients!

CALGARY, AB
September 20, 2013
VANCOUVER, BC
September 21, 2013
BRIDGEPORT, CT
September 27, 2013
HARTFORD, CT
September 28, 2013
TORONTO, ON
October 4, 2013
OTTAWA, ON
October 18, 2013
BALTIMORE, MD
November 1 & 2, 2013
HALIFAX, NS
November 8, 2013

Limited Seating Please register early to avoid disappointment. Dates and Locations subject to change. Please call to confirm dates.

Invest in yourself, your practice and your future by exploring “The Future of Dentistry” with Aurum Ceramic and LVI Global.

Learn, through lecture and discussion:

- Best procedures for diagnosis and treatment planning.
- Exciting options for smile design, restoration selection, preparation, temporization and cementation.
- Improved patient communication.
- Proven new concepts in practice marketing.

Presented by



Five ways to register:

Online: www.aurumgroup.com
Email: ce@aurumgroup.com
Phone: 1-800-661-9567
Fax: 1-800-361-5088
Mail: 115- 17th Avenue S.W.
Calgary, AB T2S 0A1

Tell us what you think!

Is there a topic you would like to see articles about in Dental Tribune U.S.? Let us know by emailing us at feedback@dental-tribune.com. We look forward to hearing from you!

Boston's Yankee Dental Congress expands on team-development day

28,000 expected at 2014 gathering

Organizers of the 2014 Yankee Dental Congress invite dental professionals to join 28,000 fellow professionals from Jan. 29 to Feb. 2 at the Boston Convention & Exhibition Center.

With a general theme centered on the concept of overall health starting with oral health, the YDC meeting offers the chance to explore and discover best practices, products and resources to improve your practice, increase your knowledge, and better serve your patients.

Organizers describe Yankee Dental Congress 2014 as being the best opportunity in New England for every member of the dental practice to participate in a wide variety of programs.

YDC 2014 highlights include:

- *The Ritz-Carlton Leadership Center* — Back by popular demand, this program promotes performance and practice excellence by developing your leadership skills and creating the best possible service for your patients. Courses include "The Fire Within — Igniting Passion for Ritz-Carlton Performance Excellence," and "Legendary Service with a Smile," both presented by Jennifer Blackmon.

- *Hands-On Cadaver Programs* — This unique opportunity enables participants to attend hands-on courses using cadavers while exploring topics that cover areas such as anesthesia,

crown lengthening and anatomy.

- *Evolutionary Dentistry* — Hear about the research and activities at the Manot Cave Dig in Israel and discuss the relationship of evolutionary biology to modern dental problems led by Mark Hans, DDS, and Bruce Latimer, PhD.

- *The Pankey Institute: Update 2014* — Discover new techniques and innovative approaches in treatment planning that will have a valuable impact on your practice. The series includes three courses featuring speakers Gregory Di Lauri, DDS, Matthew Messina, DDS, and Kenneth Myers, DDS.

- *Master the Skills of Marketing Your Practice in One Day* — A one-day symposium designed to help expand your practice with the power of marketing. Courses include "High Energy Marketing to Explode Your New Patient Numbers," "Secrets of Social Media Success and Online Marketing," "Get Noticed, Get Booked, and Grow Your Practice" and "Best Practices for Leveraging Social Media to Engage Patients."

- *Dental Team Playbook: Strategies for Success (an expansion on the popular team-development day)* — Your entire dental team can benefit from this one-day program with courses tailored to dental assistants, hygienists and office personnel. Team members can learn from experts in their respective fields.



The bustling exhibit hall at the 2013 Yankee Dental Congress reflects the meeting's strong attendance figures — nearly 30,000. Photo/Provided by Yankee Dental Congress

Presenters include Lois Banta, Amy Kirsch, RDH, Shannon Pace Brinker, CDA, Diane Peterson, RDH, and Anastasia Turchetta, RDH.

- *Social Media Hot Spot* — Learn how effectively utilizing social media such as Facebook, Instagram, LinkedIn and Twitter can help improve practice per-

formance by drawing new patients in and keeping current patients connected to your dental practice.

You can visit www.yankeedental.com for more information.

(Source: Yankee Dental Congress)

Pacific Dental Conference combines education, networking, scenic locale

Early booking recommended for conference hotels, which fill quickly



The Vancouver Convention Centre, its 'green' roof clearly visible, is host site of the 2014 Pacific Dental Conference. Photo/Provided by the Vancouver Convention Centre

The 2014 Pacific Dental Conference, from March 6–8 (Thursday, Friday, Saturday) in Vancouver, British Columbia, features a varied selection of open C.E. sessions, hands-on courses and a live dentistry stage.

The variety of topics covered by more than 130 speakers means the entire dental team can access the latest information on dental technology, techniques and materials. Speakers in the 2014 lineup include John Kois, Greg Psaltis and Glenn van As.

Highlights

With the University of British Columbia Faculty of Dentistry celebrating its 50th anniversary, the PDC will present the "UBC Speakers Series," featuring UBC alumni addressing a variety of topics.

The Live Dentistry Stage is back on the Exhibit Hall floor, with demonstra-

tions on Thursday and Friday. Saturday's "So You Think You Can Speak?" features 50-minute presentations by speakers who responded to the call for presentations and were accepted by the meeting's scientific committee.

The Exhibit Hall should be busy, with more than 300 companies projected to fill approximately 600 booths. Exhibit Hall hours are 8:30 a.m. to 6 p.m. on Thursday; 8:30 a.m. to 5:30 p.m., Friday.

Registration and lodging

Special hotel rates are available to PDC attendees, with early booking recommended to ensure availability. Reservations can be made directly with conference hotels through the links on www.pdconf.com. Registration opens Oct. 15 with early bird rates for all members of the dental team.

(Source: Pacific Dental Conference)

Er:YAG and Nd:YAG dual wavelength-optimized periodontal therapy protocol

Combination dramatically improves outcome of laser-assisted treatments

By Harvey S. Shiffman, DDS

This protocol involves using the Fotona Lightwalker/Powerlase (Lasers4Dentistry, www.T4Med.com, San Clemente, Calif.) family of lasers containing both Er:YAG and Nd:YAG laser wavelengths and the PIPS (photon-induced photoacoustic streaming) technology. PIPS^{6,11} is an Er:YAG photoacoustic wave that enables removal of calculus, destruction of bio-film and detoxification of the cemental root surfaces in an atraumatic manner. This allows for bone regrowth and reattachment.

History of lasers in dentistry

The possibilities for laser use in dentistry did not occur until 1989¹⁰ with the production of the American Dental Laser for commercial use. This laser, using an active medium of Nd:YAG, emitted pulsed light and was developed and marketed by Dr. Terry Myers.^{7,8}

Though inappropriate for use on dental hard tissue, the availability of a dedicated laser for oral use gained popularity among dentists. In 1989, experimental work by Keller and Hibst using a pulsed Er:YAG (2,940 nm) laser, demonstrated its effectiveness in cutting enamel, dentin and bone,⁹ and these then became commercially available soon after.

Of the currently available hard-tissue lasers, Er:YAG lasers have a significantly higher affinity for water versus Er,Cr:YSGG lasers and are much more effective in most dental procedures.^{1,5} Er:YAG lasers have proved beneficial in the removal of granulation tissue and calculus and are an effective tool in periodontal therapy.⁴

Treatment with Nd:YAG lasers is effective for connective tissue reattachment to cementum and periodontal regeneration.² The Nd:YAG wavelength is able to kill the bacteria that are a part of the pathogenesis of periodontal disease.³ The combination of the two wavelengths in a single treatment makes optimum use of the unique laser-tissue interaction characteristics of each wavelength.

Nd:YAG laser energy is superior for coagulation and deep disinfection, while Er:YAG is uniquely efficient at gently removing the infected tissue and calculus from the root surface, along with its bactericidal effects. Combined, they can dramatically improve the outcome of laser-assisted treatments.

Case study

Patients who consented to treatment during this case study ranged from 40 to 80 years of age. The patients were not specifically selected, but represented the population typically treated in the office, made up of approximately 75 percent adults.

These patients had a variety of preexisting health conditions, including high blood pressure, diabetes and coronary artery disease.

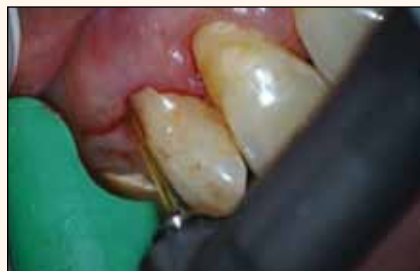

Fig. 1: Case 1 during treatment. Photos/Provided by Dr. Harvey S. Shiffman

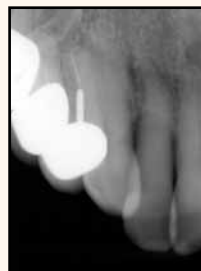

Fig. 2: Case 1 pre-operative X-ray.

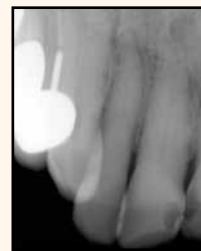

Fig. 3: Case 1 post-operative X-ray at five months.

Cases varied from single pockets to full-mouth treatments. Patients had pocketing ranging from 2 to 10 mm with moderate to severe horizontal and angular bone loss.

Pockets 6 mm deep had collagen placed while those more than 6 mm had Novabone™ (Novabone Products) placed with a liquid Atrisorb™ (Zila) membrane and sealed with Periacyrl™ (Glustitch). Occlusal discrepancies were addressed in all cases, and full-mouth cases had full coverage orthotic appliances fabricated (Glidewell Comfort hard/soft). Patients were instructed to avoid brushing or flossing the area treated and avoid granular foods such as strawberries, poppy seeds and sesame seeds, etc., for one week. Patients were given Peridex™ (3M ESPE) rinse and doxycycline 100 mg for seven days.

Follow-up appointments occurred at one and two weeks post-treatment for removal of Periacyrl™ and biostimulation. In addition, de-epithelializing the pockets was completed based on the initial pocket depth during these one- and/or two-week follow-up appointments. Patients were brought back for periodontal maintenance after two months.

At all follow-up appointments, there were limitations on sub-gingival scaling. No probing was permitted for a minimum of six months to avoid damage to the new attachment.

Case No. 1

A 74-year-old female presented with no known allergies. The patient had no history of significant medical conditions or habits and was taking no medications at the time of treatment. The patient had a Class I occlusion with significant crowding. Her chief complaint was her swollen and bleeding gums. She presented with a 7 mm pocket on the mesial buccal of #7, 6 mm on the direct lingual and 6 mm on the distal lingual. Pre-operative radiographs showed a significant osseous defect.

Eight months after "wavelength optimized periodontal therapy" (WPT) treatment, probings were 2 mm in the previous locations; and after one year, they were consistent at 2 mm, which was a gain of 4 to 5 mm of attachment. Post-operative radiographs showed significant bone fill of the previous defect.

HARVEY S. SHIFFMAN, DDS, is in general practice at the Laser Dental Center in Boynton Beach, Fla. He is a graduate of Georgetown University School of Dentistry and completed a general practice residency at Georgetown University Medical Center with an emphasis on treating medically compromised patients. Shiffman completed certification with the Academy of Laser Dentistry (ALD) in three types of laser systems and was recently awarded a fellowship in the ALD. He is personally involved in the use and development of cutting-edge technology and has performed thousands of laser dental procedures during the last decade. Shiffman also lectured at the 2012 Yankee Dental Congress on advances in laser dentistry.




Fig. 4: Case 2 pre-operative probings.




Fig. 5: Case 2 post-operative probings at 22 months.

Case No. 2

This 62-year-old male patient had a full-mouth case with pocketing ranging from 2 to 10 mm in multiple locations. The patient reported no known allergies and was taking prescription medications that included Metoprolol, Crestor, Ramipril and HCTZ. The patient's chief complaint was his bleeding and painful gums. The diagnosis was moderate to severe periodontal disease in all four quadrants and he consented to treatment.

Two-year postoperative probings and radiographs showed significant pocket reduction, reattachment and osseous fill in defects. Unfortunately, Dentrix periodontal charting only goes to 9 mm so the charts were modified for 10 mm pockets as needed. Pre-operative pocketing (Fig. 4) was as high as 10 mm in two locations. Figure 5 shows significant improvement at the 22-month post-operative follow up.

► See DUAL, page A8

◀ DUAL, page A7

The upper right 7 to 10 mm pockets regained 5 mm of attachment and bone fill; the upper left segments regained 4 to 7 mm; the lower left regained 5 to 6 mm; the lower right regained 3 to 5 mm.

Conclusion

Clinical, radiographic and probing evidence suggest that when followed correctly, WPT protocol is a strong and reliable tool for restoring periodontal health. However, it should be noted that occlusal considerations and orthotic appliances in full-mouth cases can have a great impact on outcomes. Patient maintenance and re-care can also dramatically affect the success of therapy.

The Lightwalker dual-wavelength laser has been proven to have strong benefits in periodontal therapy. Having the ability to offer patients a minimally invasive laser treatment with minimal bleeding, swelling and discomfort increases patient compliance and case acceptance versus traditional periodontal surgery. This seems to be especially true in patients who have had a history of traditional invasive periodontal surgery.

▶ **References**

1. Diaci J, Gaspirc B.. Comparison of Er:YAG and Er,Cr:YSGG lasers used in Dentistry, Journal of the Laser and Health Academy Vol. 2012, No. 6.
2. Yukna R.A, Carr R.L, Evans G.H. Histologic Evaluation of an Nd:YAG Laser-Assisted New Attachment Procedure in Humans,

3. The International Journal of Periodontics & Restorative Dentistry, Vol. 27, No. 6, 2007.
4. Harris D M, Yessik M, Laser antiseptis of Phorphyromonas gingivalis in vitro with dental lasers SPIE Proceedings 5313-5322, 2004, Lasers in Surgery and Medicine Vol. 35, Issue 3, Sept. 2004.
5. Ishikawa I, Aoki A, Takasaki AA, Potential applications of Erbium:YAG laser in periodontics. J Periodont Res 2004; 39:275-285. Ó Blackwell Munksgaard, 2004.
6. Yung F YW, The use of an Er:YAG laser in periodontal surgery. International Dentistry African edition, Vol. 1, No. 1, 2006.
7. Pedullà E, Genovese C, Campagna E, Tempa G, Rapisarda E, Decontamination efficacy of photon-initiated photoacoustic streaming (PIPS) of irrigants using low-energy laser settings: an ex vivo study. Int Endod J. 2012 Sep;45(9):865-870. doi: 10.1111/j.1365-2591.2012.02044.x. Epub 2012 Apr 5.
8. Myers TD, Lasers in dentistry, J Am Dent Assoc 1991;122(1):46-50.
9. Myers TD, Myers W D, Stone R M, First soft-tissue study utilising a pulsed Nd YAG dental laser. Northwest Dent 1989; 68:14-17.
10. Hibst R, Keller U, Experimental studies of the application of the Er:YAG laser on dental hard substances: 1. Measurement of ablation rate. Lasers Surg Med 1989; 9:338-344.
11. Parker S, Introduction, history of lasers and laser light production, British Dental Journal 202, 21-31 (2007).
12. Divito E, Lloyd A, Er:YAG Laser for 3-Dimensional Debridement of canal systems, Dentistry Today, Nov. 2012

Author disclosures

The author has no financial interest in any of the companies mentioned in this article and received no compensation for writing this article.

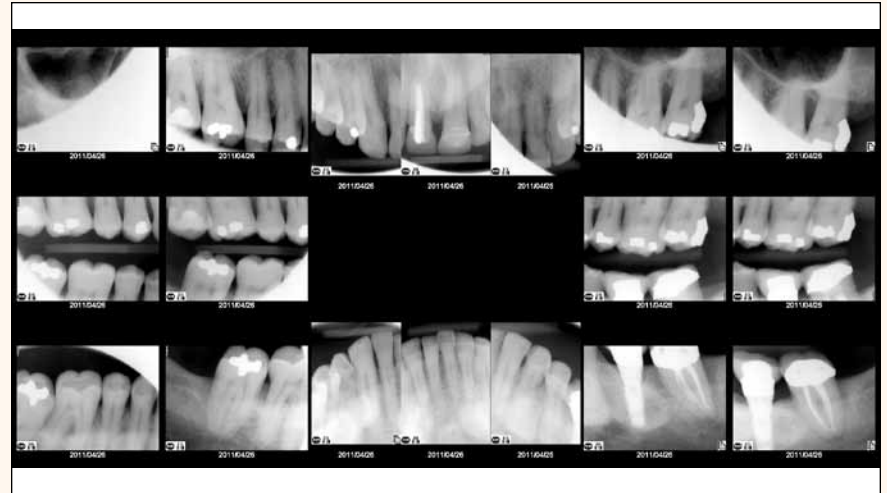

Fig. 6: Case 2 pre-operative full-mouth X-ray.

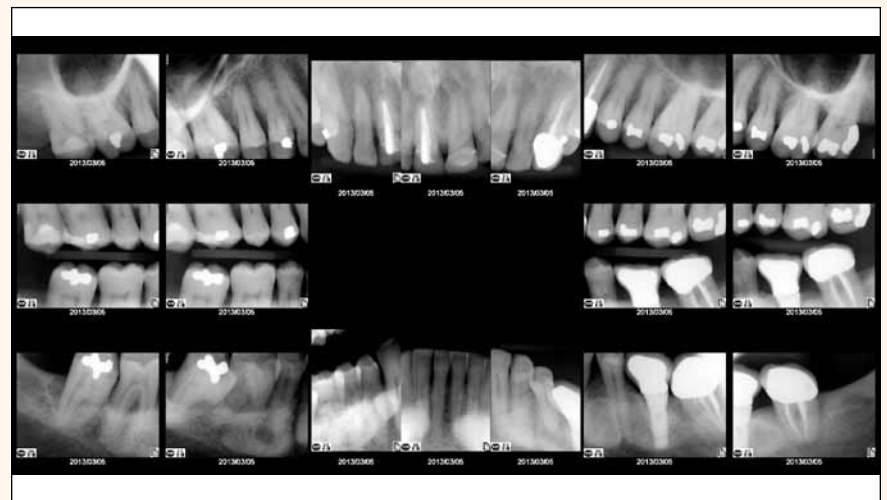



Fig. 7: Case 2 post-operative full-mouth X-ray.

AD



New Orleans
American Dental Association
ANNUAL SESSION
OCTOBER 31 - NOVEMBER 3, 2013

ADA American Dental Association®
America's leading advocate for oral health


Make the 2013 ADA Annual Session your first choice.

Education
Participate in challenging CE courses that fit into your schedule and budget

Exhibition
Research and purchase dental products and services at a discount

Connections
Mingle with colleagues from across the world

Registration is open now.
ADA.org/session



BEAUTIFIL Flow Plus now available in B1, B2 and C2

BEAUTIFIL Flow Plus restorative is 'changing dentistry for the better'

Shofu will be demonstrating its revolutionary product BEAUTIFIL Flow Plus during the Academy of General Dentistry Annual Meeting at booth No. 319 this year. This radiopaque injectable hybrid restorative is now available in three new shades — B1, B2, and C2 in both viscosities, giving dentists even more esthetic treatment options at their fingertips.

The product combines mechanical properties that rival leading hybrids, with the superior adaptation that can be achieved only with a flowable delivery. Approved for all indications (Class I–V), this new concept avails new clinical techniques that promise to revolutionize how restorations are performed, while at the same time, provide a host of benefits and advantages over traditional hybrid layering techniques.

All-in-one base, liner and restorative

Traditional methods of filling and packing hybrids can be time consuming, presenting technique-sensitive issues that may result in post-op sensitivity and/or failure of the restoration.

With BEAUTIFIL Flow Plus, material can be syringe-delivered where needed and cured in 2 mm increments all the way up to the occlusal surface. See Figures 2 and 3, Class I restoration, before and after. Using a single material not only simplifies the steps to perform restorations, it also reduces inventory needs and helps facilitate both setup and cleanup — making for a more productive office.

Flowable adaptation with the strength of a hybrid

The flowable consistency of BEAUTIFIL Flow Plus provides superior adaptation to tooth structure when compared with hybrids, according to the company. Because the material is flowed into the preparation, rather than being packed as with hybrids, dentists can achieve a tight marginal seal with minimal instrumentation. This helps reduce the occurrence of voids inherent in traditional hybrid packing techniques. Unlike other flowables, BEAUTIFIL Flow Plus is approved for all indications, making it perfectly suited for difficult to reach Class IIs.

In addition to superior adaptation, BEAUTIFIL Flow Plus was specifically designed to stand up to the rigors of the occlusal surface and marginal ridge, according to the company. High filler content and unique chemical properties ensure that clinicians have all of the material strength found in leading hybrids. Internal studies confirm that compressive strength, flexural strength, toothbrush wear and other mechanical properties are clinically equivalent to leading hybrids on the market. Using this new approach, dentists can achieve better adaptation, with a stronger

material and fewer, less-complicated steps.

It just stays put

One of the many distinguishing features of BEAUTIFIL Flow Plus is that it stays where you put it. Older-generation flowables tend to spill out of the prep; BEAUTIFIL Flow Plus provides precision stacking capabilities with no slump. This is particularly important when working at awkward angles or with fidgety patients.

Two distinct viscosities add to dentists' treatment options. See Figure 4, F00/F03 material. "F00" Zero Flow (0.0 mm of flow held vertically for one minute) is ideal for stacking, especially in the marginal ridge. "F03" Low Flow (3 mm of flow held vertically for one minute) handles more like a traditional base or liner. That said, the mechanical properties for both viscosities are similar and can be used interchangeably. Both F00 and F03 display self-leveling characteristics that make polishing easier than ever.

Clinically proven benefits

Shofu's proprietary GIOMER technology utilizes "Surface Pre-Reacted Glass" (S-PRG) filler, providing a wealth of benefits for high-caries-index patients, according to the company. Simply put, S-PRG filler is composed of a glass core with a surface-modified layer that protects the durability and esthetics of the glass from moisture, while still allowing beneficial ions to travel freely between the S-PRG filler and the oral environment.

Many competitive restoratives release fluoride initially, but deplete their charge within a matter of weeks. With S-PRG technology, fluoridated products, such as toothpaste and mouthwash, recharge the filler material, providing sustained preventative benefits over the life of the restoration.

Numerous independent clinical studies show S-PRG fillers to display biomimetic properties that help protect the restoration and surrounding tooth structure from harmful bacteria. Studies on BEAUTIFIL Flow Plus's sister product, BEAUTIFIL II, a hybrid restorative, highlight these results. As published in JADA, a University of Florida study found that restorations containing S-PRG filler showed no failures, no secondary caries and no post-op sensitivity during an eight-year period. A 13-year recall of these patients is under way.

Quality and durability

For decades, Shofu's "Brownies," "Greenie" and other polishes have been synonymous with quality and durability in dentistry. While many companies would be complacent as the "go-to" polishing company, Shofu has been on a mission to

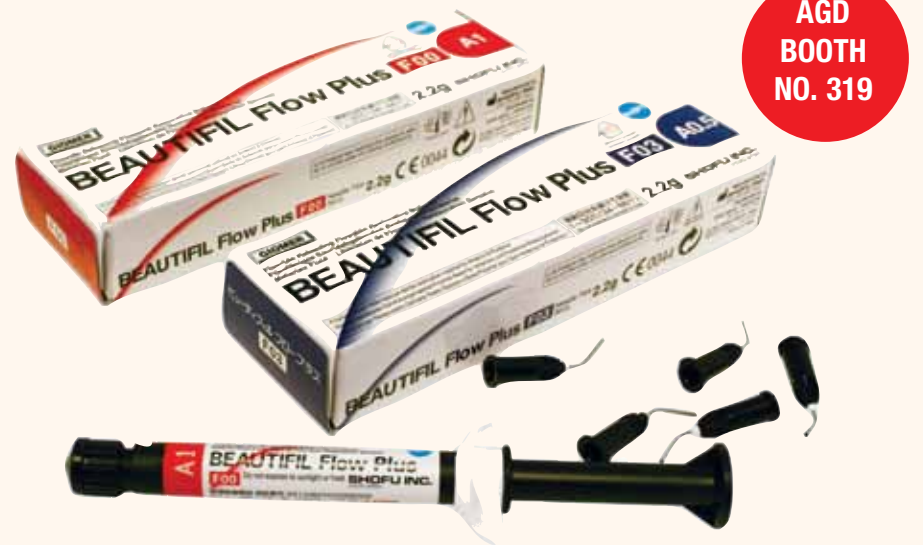
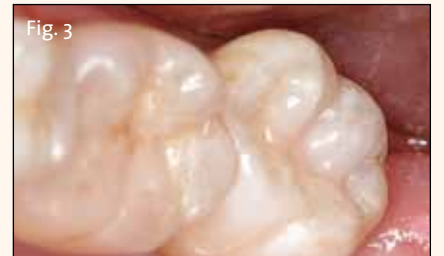
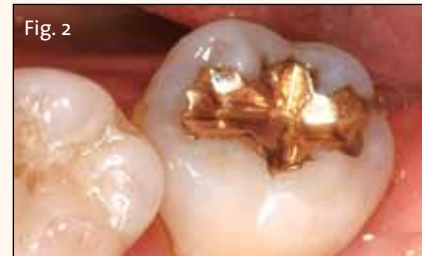Fig. 1: BEAUTIFIL Flow Plus radiopaque, an injectable hybrid restorative with mechanical properties rivaling leading hybrids, adds more shade choices. Photos/Provided by Shofu



Figs. 2, 3: Before (Fig. 2) and after (Fig. 3) Class I restoration shows BEAUTIFIL Flow Plus can be syringe-delivered where needed and cured in 2 mm increments all the way up to the occlusal surface.

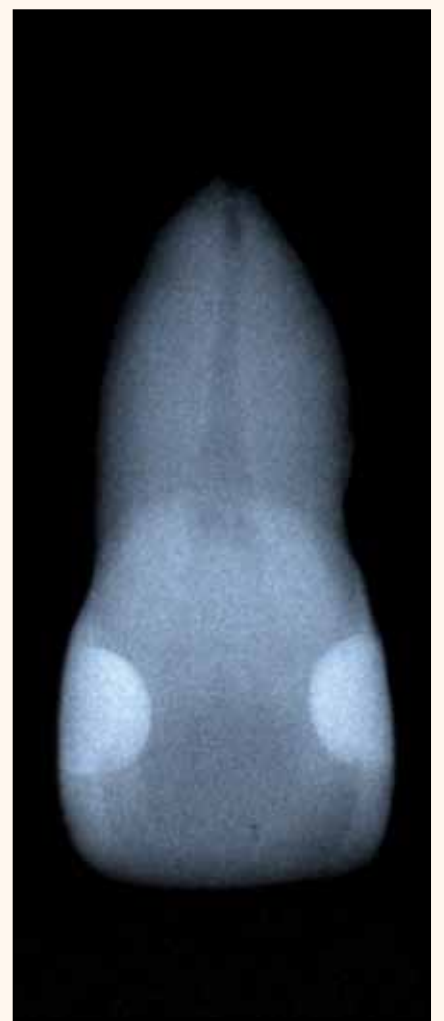

Fig. 4: 'F00' Zero Flow (0.0 mm of flow held vertically for one minute), left, is ideal for stacking, especially in the marginal ridge. 'F03' Low Flow (3 mm of flow held vertically for one minute), right, handles more like a traditional base or liner.

change dentistry for the better with innovative chemical restoratives such as BEAUTIFIL Flow Plus. Exceptional strength, handling and unique bioactive filler technology make it a product worth seeing for yourself.

Coming soon: pit-and-fissure sealant

Building on the GIOMER line of products, and coming soon from Shofu, is BeautiSealant Pit and Fissure Sealant. BeautiSealant is a tooth-colored, fluoride recharging, pit-and-fissure sealant that reduces treatment time by completely eliminating the need for phosphoric acid etch and rinse steps. Using an advanced, self-etching primer, BeautiSealant is gentle on teeth, yet delivers superior shear and tensile bond strength compared with leading phosphoric acid etched systems.



(Source: Shofu)

Fig. 5: Radiopacity of F00 and F03.

AGD
BOOTH
NO. 319