

DENTAL TRIBUNE

The World's Dental Newspaper • Asia Pacific Edition



PUBLISHED IN HONG KONG

www.dental-tribune.asia

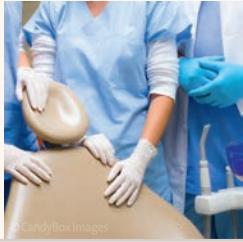VOL. 14, No. 3



BETWEEN BOPT & BTA

A case report on shaping the gingival contour around tooth-supported restorations by means of provisional resin crowns.

► Page 10



MANAGEMENT

Practice consultant Lina Craven, Dynamic Perceptions, explains what it takes to build the ultimate practice team.

► Page 14



today ADX16

18-20 March 2016 Sydney Exhibition Centre www.adx.org.au
Read all about Australia's largest dental show in Sydney in our *today* specialty section included in this issue.

► Page 17

Dental4Windows now has wings
Introducing D4W Cloud

D4Wcloud All the features of Dental4Windows. Now online for one fixed monthly fee.

Stand 222
ADX16
SEE BUY LEARN - SYDNEY

Study finds high urinary mercury levels in children with amalgam fillings

By DTI

DAEGU, South Korea: Although equivalent alternatives have become available over the past decade, dental amalgam remains in use as a restorative material for dental caries in children in many countries. The safety of dental amalgam, however, is still a controversial issue among experts, as it has been associated with developmental disorders

and systemic conditions. A Korean study has recently provided evidence that dental amalgam exposure can affect systemic mercury concentration in children.

In order to assess chronic exposure to elemental mercury, researchers at Kyungpook National University in South Korea evaluated mercury concentrations in urine samples from more than

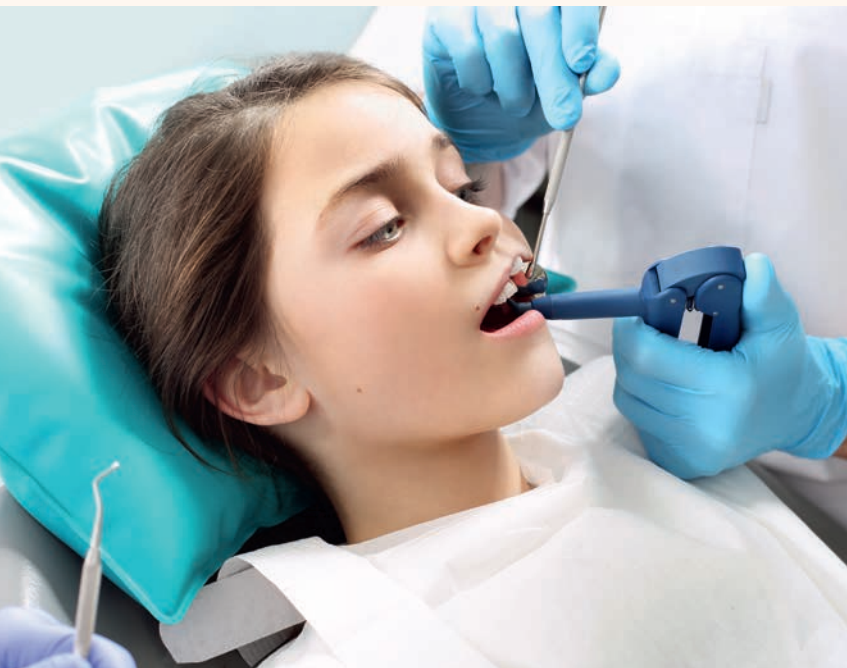
1,000 children aged 8–11, who also underwent oral examination.

They found that children with more than one amalgam-filled tooth surface exhibited significantly higher urinary mercury concentrations than those with none. The researchers thus concluded that dental amalgam exposure could affect systemic mercury concentration in children.

A number of studies have indicated that mercury exposure could be involved in problems in early brain development. Mercury has also been associated with adverse health effects relating to the digestive and immune systems, as well as the lungs, kidneys, skin and eyes. Awareness and recognition of these health and environmental implications have led to a ban on the use of dental amalgam in some high-income countries. However, dental amalgam restorations

are still taught in the dental curriculum in South-East Asia. In Myanmar, for example, about 50 per cent of fillings placed are of amalgam.

The study, titled "Dental amalgam exposure can elevate urinary mercury concentrations in children", was published online on 1 February in the *International Dental Journal*.



The use and toxic risk of dental amalgam fillings in children is a controversial issue among health care experts. © Robert Przybysz



Distinguished by innovation

Healthy teeth produce a radiant smile. We strive to achieve this goal on a daily basis. It inspires us to search for innovative, economic and esthetic solutions for direct filling procedures and the fabrication of indirect, fixed or removable restorations, so that you have quality products at your disposal to help people regain a beautiful smile.

www.ivoclarvivadent.com

Ivoclar Vivadent AG
Benderstr. 2 | FL-9494 Schaan | Liechtenstein | Tel.: +423 / 235 35 35 | Fax: +423 / 235 33 60

ivoclar vivadent!
passion vision innovation

Dental Tribune welcomes comments, suggestions and complaints at newsroom@dental-tribune.com.



For quick access to our contact form, you may also scan the following QR code.

Indian dental patients in favour of chairside medical screening

By DTI

MUMBAI, India: A number of international studies have already indicated that oral health professionals could play a greater role in detecting chronic disease. Given the high prevalence of cardiovascular disease, diabetes mellitus, tuberculosis, HIV/Aids and hepatitis B in India, researchers have now assessed patient attitudes towards and willingness to participate in medical screenings in dental settings in the country.

In the study, adult patients visiting five university-based dental clinics and one private practice were asked about their attitude towards and willingness to participate in chairside screening.

Almost 90 per cent of the study participants in the clinical group and about 95 per cent in the private practice group said that they believe that it is important for dentists to identify increased risk of developing certain medical conditions. The majority of patients



Indian family at Juhu Beach, Mumbai © Dapa Ward

were willing to have a dentist perform screenings for this purpose. Willingness was highest for screening for diabetes, with 85 per cent in the clinical group and 78 per cent in the private practice group. Over 70 per cent in both groups reported willingness to undergo HIV/Aids screenings in a dental setting.

In addition, the researchers found that the majority of patients were willing to pay 150 Indian rupees (56 per cent in the clinical group and 92 per cent in the private practice group; US\$ 2.25) for medical screenings. According to the World Bank statistics, the gross national income per capita in the country is 1,570 Indian rupees (US\$ 23.47).

According to a US study published in the *American Journal of Public Health* in 2014, chairside screenings in dental practices for the most common chronic diseases could save the health care system more than US\$100 million annually.

Roland DG announces changes in leadership

AD

By DTI

HAMAMATSU, Japan: Roland DG, which offers a range of milling machines for dental laboratories and technicians, has announced that Masahiro Tomioka is resigning as president of the company and will be succeeded by Hidenori Fujioka, current vice president. Tomioka, however, will continue as representative director and chairman. The change is subject to the resolutions at the upcoming shareholder and board of directors' meetings at the end of March.

The leadership change will be implemented as part of the mid-term business plan for 2016–2020 and a new organisational structure to facilitate new business development.

Tomioka has been the President of Roland DG for 30 years. Among other important projects, he spearheaded the transformation of the company from manufacturing pen plotters to producing 3-D desktop fabrication tools, vinyl cutters and wide-format inkjet printers while achieving worldwide sales leadership with high profitability. Only recently, the company invested in inkjet and 3-D technologies to expand into the on-demand digital print-

ing and health care industries under his management.

Fujioka, who joined the company in 2014, has broad experience in ink, inkjet print head, 3-D and UV technologies. His expertise will help the company quickly develop a variety of new products and solutions, Roland DG stated. Prior to his employment at Roland DG, Fujioka was a director at Riso Kagaku, a manufacturer of copy and printing machines, and before that he spent 25 years at Seiko Instruments, where he oversaw the integration of profitable service components into core offerings.

"These are exciting times at Roland DG and I am honoured to serve as President," Fujioka said. "Roland DG offers a sophisticated product line with a passionate culture and family spirit. While upholding its corporate culture and spirit, I intend to turn the company into a more progressive and innovative organisation to achieve sustainable growth," Fujioka added.

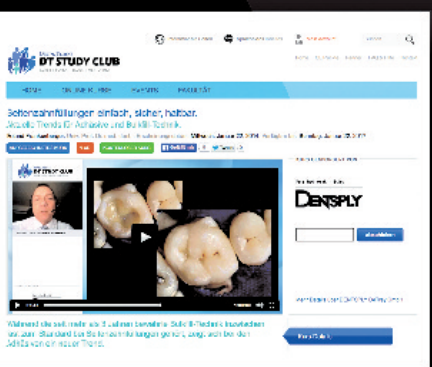"My goal is to shift our business to a new digital era model that will serve as a foundation for the next big leap in growth by capitalising on our GlobalOne business platform. Together, we will unlock the full potential of our employees worldwide in order to realise new market creation with products and services that exceed customer expectations."

Join the largest educational network in dentistry!



www.DTStudyClub.com

- education everywhere and anytime
- live and interactive webinars
- more than 500 archived courses
- a focused discussion forum
- free membership
- no travel costs
- no time away from the practice
- interaction with colleagues and experts across the globe
- a growing database of scientific articles and case reports
- ADA CERP-recognized credit administration



Register for
FREE!

IMPRINT

PUBLISHER:
Torsten OEMUS

GROUP EDITOR/MANAGING EDITOR DT AP & UK:
Daniel ZIMMERMANN
newsroom@dental-tribune.com

CLINICAL EDITOR:
Magda WOJTKIEWICZ

ONLINE EDITOR:
Claudia DUSCHEK

ASSISTANT EDITORS:
Anne FAULMANN, Kristin HÜBNER

COPY EDITORS:
Sabrina RAAFF, Hans MOTSCHMANN

PRESIDENT/CEO:
Torsten OEMUS

CFO/COO:
Dan WUNDERLICH

MEDIA SALES MANAGERS:
Matthias DIESSNER
Peter WITTECZEK
Maria KAISER
Melissa BROWN
Weridiana MAGESWKI
Hélène CARPENTIER
Antje KAHNT

MARKETING & SALES SERVICES:
Nicole ANDRAE

ACCOUNTING:
Karen HAMATSCHEK

BUSINESS DEVELOPMENT:
Claudia SALWICZEK

EXECUTIVE PRODUCER:
Gernot MEYER

AD PRODUCTION:
Marius MEZGER

DESIGNER:
Franziska DACHSEL

INTERNATIONAL EDITORIAL BOARD:
Dr Nasser Barghi, Ceramics, USA
Dr Karl Behr, Endodontics, Germany
Dr George Freedman, Esthetics, Canada
Dr Howard Glazer, Cariology, USA
Prof. Dr I. Krejci, Conservative Dentistry, Switzerland
Dr Edward Lynch, Restorative, Ireland
Dr Ziv Mazor, Implantology, Israel
Prof. Dr Georg Meyer, Restorative, Germany
Prof. Dr Rudolph Slavicek, Function, Austria
Dr Marius Steigmann, Implantology, Germany

Published by DT Asia Pacific Ltd.

DENTAL TRIBUNE INTERNATIONAL
Holbeinstr. 29, 04229, Leipzig, Germany
Tel.: +49 341 48474-302
Fax: +49 341 48474-173
info@dental-tribune.com
www.dental-tribune.com

Regional Offices:

DT ASIA PACIFIC LTD.
c/o Yonto Riso Communications Ltd,
20A, Harvard Commercial Building,
105–111 Thomson Road, Wanchai
Hong Kong
Tel.: +852 3113 6177
Fax: +852 3113 6199

UNITED KINGDOM
Baird House, 4th Floor, 15–17 St. Cross Street
London EC1N 8UW
www.dental-tribune.co.uk
info@dental-tribune.com

DENTAL TRIBUNE AMERICA, LLC
116 West 23rd Street, Suite 500, New York,
NY 10001, USA
Tel.: +1 212 244 7181
Fax: +1 212 244 7185

© 2016, Dental Tribune International GmbH

DENTAL TRIBUNE
The World's Dental Newspaper - United Kingdom Edition

All rights reserved. Dental Tribune makes every effort to report clinical information and manufacturer's product news accurately, but cannot assume responsibility for the validity of product claims, or for typographical errors. The publishers also do not assume responsibility for product names or claims, or statements made by advertisers. Opinions expressed by authors are their own and may not reflect those of Dental Tribune International.



Scan this code to subscribe our weekly *Dental Tribune AP* e-newsletter.

World Oral Health Day 2016: Healthy Mouth. Healthy Body.



World Oral
Health Day
20 March

By DTI

GENEVA, Switzerland: Every World Oral Health Day (WOHD), which is celebrated annually on 20 March around the world, is held under a new and specific theme. This

video, new smartphone game, media strategy and social media content have been designed to inspire people across the world to participate in the WOHD cam-

paigned and improve their oral health regime.

Dental professionals, companies and institutions that would like

to be involved in this year's WOHD activities are invited to e-mail WOHD@fdiworldental.org for a full campaign guide, which is available in English, French and Spanish and

includes materials for download, such as poster visuals, social meme designs and information on the WOHD video and smartphone game.

AD



year's WOHD will focus on raising awareness of the link between good oral health and overall well-being, with the slogan "It all starts here. Healthy mouth. Healthy body."

Oral disease affects 3.9 billion people worldwide, with between 60 per cent and 90 per cent of children globally suffering from tooth decay. Yet, poor oral health goes far beyond the initial implications of dental disease and tooth decay; it has been associated with a number of health conditions, such as heart disease, pancreatic cancer, pneumonia and lung disease. In a recent study, 40 per cent of people with serious periodontal disease also reported suffering from an additional chronic condition.

Despite these links, people are unaware of the long-lasting and wide-ranging effects of poor oral health. Therefore, WOHD 2016 will shed light on the importance of good oral health in a simple and engaging way, encouraging understanding that good oral health is fundamentally intertwined with overall well-being.

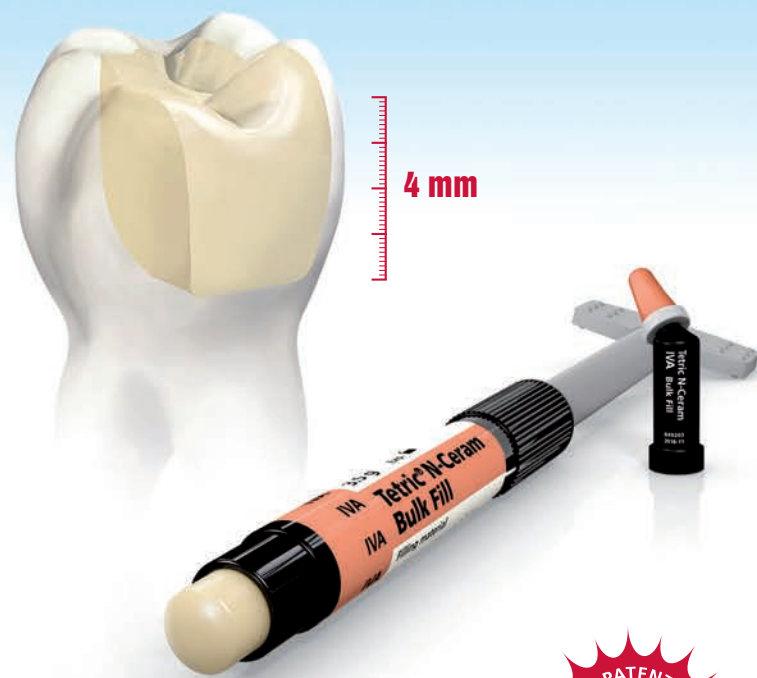The WOHD 2016 website, www.worldoralhealthday.org, focuses on communicating that prevention, early detection and treatment are key to ensuring the best outcomes and reducing oral disease and associated health complications.

A series of dynamic and engaging material, including a global

Tetric® N-Ceram Bulk Fill

The nano-optimized 4-mm composite

Discover the new
time-saving
composite



4 mm to success

- Bulk filling is possible due to Ivocerin®, the patented light initiator
- Special filler technology ensures low shrinkage stress
- Esthetic results are achieved quickly and efficiently in the posterior region

www.ivoclarvivadent.com

Ivoclar Vivadent AG
Bendererstr. 2 | 9494 Schaan | Liechtenstein | Tel.: +423 235 35 35 | Fax: +423 235 33 60

ivoclar
vivadent®
passion vision innovation

SHOFU: Fastest growth from China

By DTI

SINGAPORE: SHOFU Dental Asia-Pacific attended the UAE International Dental Conference and Arab Dental Exhibition (AEEDC) in Dubai this year to introduce its new abrasive

Iran and Iraq. This is a big market, especially for Asian companies, but the market needs to open more to ease import and export," stated Patrick Loke, Managing Director of SHOFU Dental Asia-Pacific, during AEEDC. Given the company's his-

touched despite SHOFU's geographical proximity.

SHOFU finally established a new subsidiary in Singapore in 1980. Since then, Shofu Dental Asia-Pacific has reached a number of milestones in the region. In 1985, Shofu began operating in China with the establishment of a worldwide sales network and opened a production facility and sales office 20 years later. Back then, the country had only 50,000 dentists and fewer than 200 dental clinics to serve its 1.3 billion people—about 440,000 dental professionals would have been needed to provide adequate oral health care according to Western standards.

In the last decade, the Chinese government has invested substantially in dental training facilities and schools. The result was an increase in dental clinics that led to double-digit growth in relatively new market segments, such as dental implants.

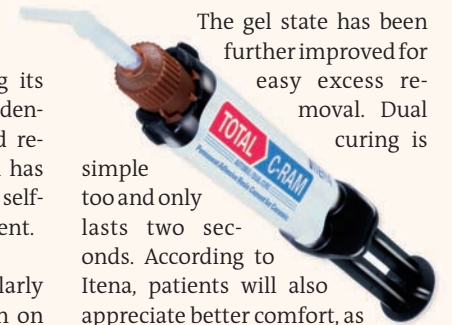Loke is very pleased with SHOFU's sales in China. "We see the fastest growth coming from China. For the most part, China is now a fully developed country with huge opportunities to conduct business. We have experienced a double-digit increase in Chinese sales and the nation remains our most important market in the region," he said during AEEDC. "Other countries in the South-East Asian region are also developed but growth is slower. However, India is coming up. SHOFU will start operating in India soon. There is growing awareness regarding dental health there."

New permanent resin cement

By DTI

PARIS, France: Complementing its bonding range with TOTALCEM, dental product manufacturer and restoration expert Itena Clinical has launched a new self-etching and self-adhesive permanent resin cement.

The TOTAL C-RAM is particularly indicated for the cementation on enamel, dentine, metal, ceramic, porcelain, zirconium & composites and features a bonding strength that is 50 per cent superior to that of CIVMAR on zirconia, the French company said.



The gel state has been further improved for easy excess removal. Dual curing is simple too and only lasts two seconds. According to Itena, patients will also appreciate better comfort, as the cement is odour and tasteless.

TOTAL C-RAM is available in two shades (translucent and opaque) and comes in automix syringes as well as with fine and extra-fine intra-oral tips.

Straumann, Anthogyr partner

By DTI

BASEL, Switzerland/SALLANCHES, France: Straumann and Anthogyr have announced that they have entered into a new partnership that will see Anthogyr's business activities in China being transferred to Straumann by the middle of the year. Furthermore, the Swiss dental implant company has acquired a 30 per cent stake in the French manufacturer.

The agreement, according to both parties, is to become effective by the end of March this year. Financial details of the deal were not disclosed.

Straumann said in a press release that the sales capabilities of the two companies are expected to provide the critical mass to compete and grow successfully in the premium segment, where they have already been active for a number of years.

In an effort to extend its leading market position, Straumann recently established a new country organisation and distributor network that is intended to cover all of the provinces of China. Anthogyr's dental implant system has been registered in and is established in China, where it is positioned as a high-quality, attractively priced option, according to the company.



SHOFU Dental Asia-Pacific's booth at AEEDC Dubai 2016.

and restorative materials to professionals in the Middle East. The global dental materials and equipment manufacturer has been eyeing the region for a long time, but ongoing market restrictions remain a challenge. However, SHOFU is also targeting countries in Asia Pacific that promise stronger growth.

While trade show attendees from the Middle East expressed great interest in Shofu's materials and digital dental cameras, the company feels that the market conditions do not facilitate foreign investment. "Our meetings were good—although the fair could have been stronger. We met dentists and dental students from the UAE, Kuwait,

tory, SHOFU is continuing its careful assessment of business opportunities before possibly opening a production facility or sales office in the Middle East.

SHOFU was founded in 1922 in Kyoto at the time when growing national debt and political uproar endangered Japan's strong economy. The company initially produced high-quality porcelain teeth for the local market, but soon added abrasives, silicone polishers, composites and amalgam fillings to its portfolio. The 1970s saw the opening of new manufacturing facilities in Japan and sales offices in the US and Germany, while Asia Pacific remained relatively un-

AD

PROMEDICA

Highest quality made in Germany

Light-curing micro-hybrid composite

- applicable for various indications and all cavity classes
- high translucency and a perfect colour adaption
- Polishable to a high gloss
- excellent physical properties for durable fillings
- high filler content
- packable consistency (also available as Composan LCM flow)

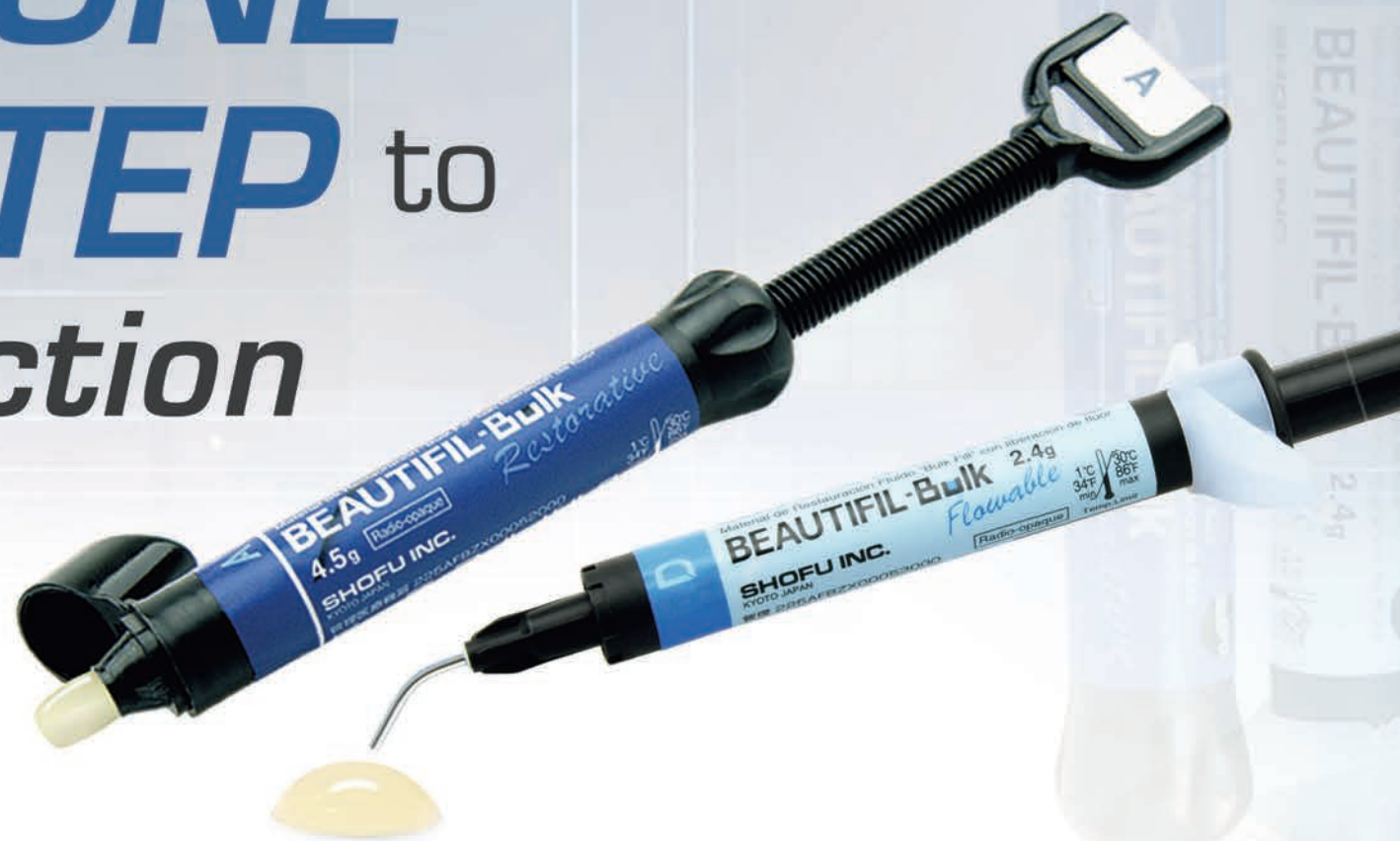





Dental Material GmbH
 24537 Neumünster / Germany
 Tel. +49 43 21 / 5 41 73
 Fax +49 43 21 / 5 19 08
 eMail info@promedica.de
 Internet www.promedica.de

Just **ONE**
STEP to
perfection



Bulk Fill

- *Deep Cure up to 4mm*
- *Low Shrinkage*
- *Remarkable Handling*
- *Anti-plaque*
- *Fluoride Release & Recharge*
- *Withstands Heavy Stress*

BEAUTIFIL-Bulk is formulated with a unique balance of filler-resin chemistry to maximize light penetration for optimum cure depth and low polymerisation shrinkage stress while assuring remarkable shade match and sustained fluoride protection.

For more information, simply contact your nearest **SHOFU** dealer.



SHOFU DENTAL ASIA-PACIFIC PTE. LTD.

Tel (65) 6377 2722 Fax (65) 6377 1121 eMail mailbx@shofu.com.sg website www.shofu.com.sg

Aesthetic composite layering of implant-supported restorations in an edentulous jaw

A good option for the lifelike recreation of gingival tissue

By Drs Patrice Margossian & Pierre Andrieu, France

Careful planning is indispensable in the treatment of an edentulous jaw with implant-supported restorations. The axes and positions of the implants must correspond to the given biological, mechanical and aesthetic conditions. In situations in which severe bone recession has occurred, the work of the dental team has to involve the reconstruction of the dental and the gingival tissue. The flawless reconstruction of gingival tissue requires sound teamwork, as well as excellent materials and exceptional skill. Layering with the light-curing laboratory composite SR Nexco (Ivoclar Vivadent) takes this procedure to a new level.

Surgical phase

Owing to the sufficient bone structure in the lower jaw, this part of the mouth could be restored at once with four immediately loadable implants. During the reconstructive phase, the upper jaw had to be treated with a provisional removable denture owing to the atrophied alveolar ridge. The tooth extractions from the upper and lower jaw were performed on one day. At the same time, four mandibular implants were placed and loaded. An immediate denture was seated in the upper jaw.

The determination of the occlusal plane and the ideal incisal line allows the dental arches to be integrated more easily in terms of aesthetics and function. Open-tray impressions were taken with a special plaster (Snow White, Kerr Dental) and unsplinted impression posts. The considerable stiffness of the impression material completely immobilised the impression posts, thereby preventing any errors in the casting of the study models.

An articulator allows the kinematics of the jaw to be correctly simulated. The goal of this part of

loaded provisional restorations. For this purpose, however, the model has to be mounted in the articulator. In the present case, the masticatory model was positioned in correct relation to the hinge axis-orbital plane. Subsequently, we adjusted the bite patterns in order to record the vertical dimension of occlusion.

The centric relation is regarded as the reference position for adjusting the muscles to the centric and functional jaw relation. The mandibular model was mounted in the articulator with the help of an antagonist jaw relation record. If the centric relation

were marked on the plaster base of the model (vertical and horizontal). The vertical axis represents the midsagittal plane. From the front, the horizontal axis is aligned parallel to the interpupillary line and from the side to Camper's plane. These markings, which should be very close to the working area, function as a guide for the dental technician in setting up the teeth. Therefore, the incisal line has a predictable parallel alignment with the interpupillary line. The incisal axis is aligned parallel with the midsagittal plane. The Camper's plane markings indicate the alignment of the occlusal plane. All these elements provide a sound rationale for the tooth set-up according to aesthetic and functional principles.

We selected the tooth shade and the teeth on the basis of the SR Phonares II tooth mould chart (Ivoclar Vivadent). Holding the teeth up against the lips of the patient quickly revealed whether they were in harmony with her facial features. The set-up of the teeth according to the Ditrax markings (Fig. 6) allows the situation to be clinically validated. In this case, attention was given in particular to the aesthetic integration of the dentogingival complex when the patient was smiling. The lip dynamics were shown with video clips. The functional criteria were also checked. The vertical dimension of occlusion had to be harmonious in order to achieve a balanced lower facial third and proper phonation.

We felt that a CAD/CAM-fabricated titanium framework (NobelProcera, Nobel Biocare) would best fulfil this indication. The double-scan technique allowed the implant model to be superimposed on the tooth set-up to construct the framework. In the next step, the framework was machined and then tried on the model and in the patient's mouth (Fig. 7). The cast impression and the high-performance processing systems significantly contributed to providing the optimal passive (tension-free) fit of the framework, which is decisive for the long-term success of the restoration.

The areas that needed to be built up with gingival materials were blasted with aluminium oxide at 200 to 300 kPa pressure. Subsequently, the SR Link bonding agent (Ivoclar Vivadent) was applied, followed by a thin layer of the light-curing SR Nexco Gingiva Opaquer to mask the metal framework. The Opaquer was polymerised and then a second coating was applied and polymerised. The resulting inhibition layer was removed.

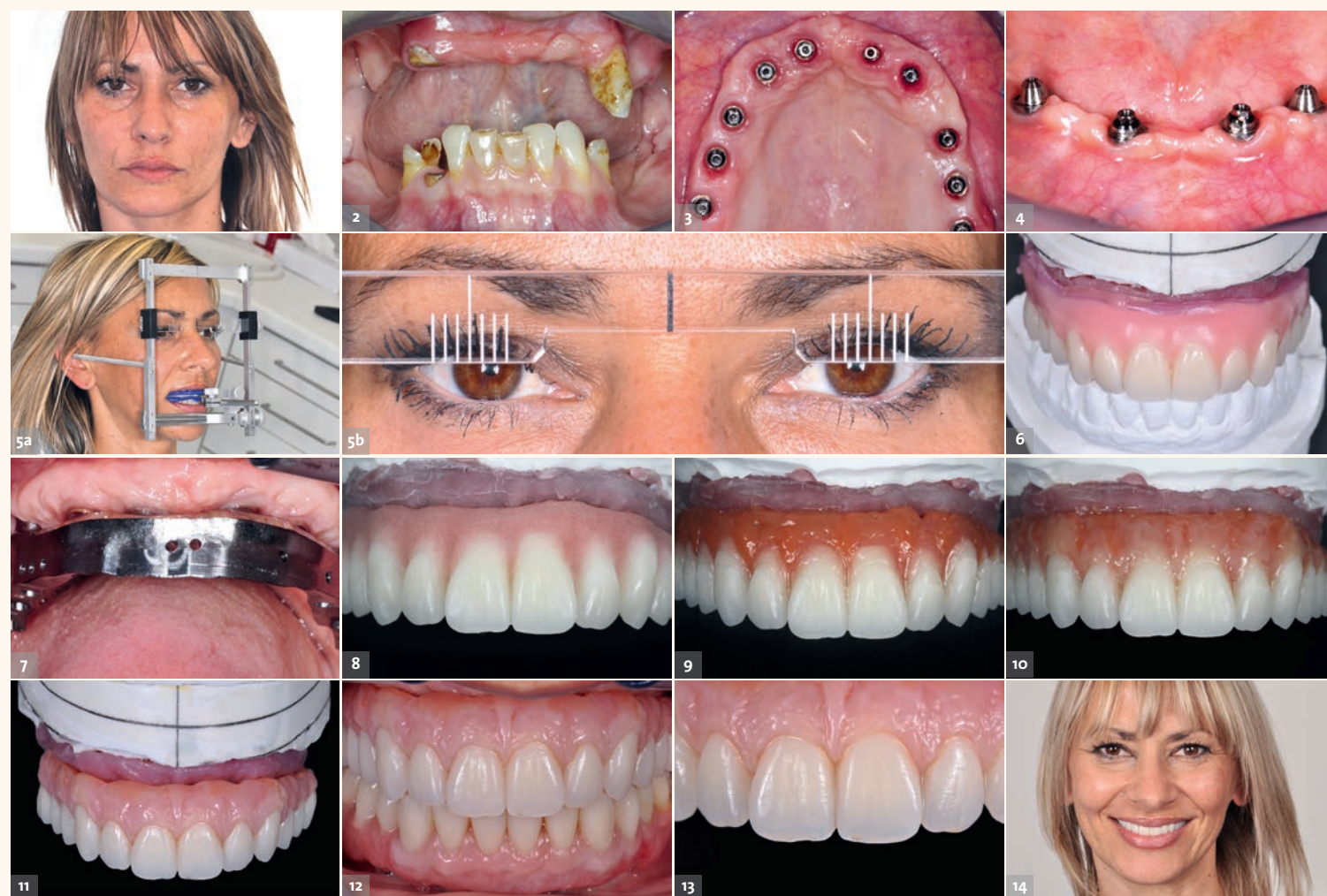


Fig. 1: Initial photograph of the patient.—Fig. 2: Extremely poor oral condition: The teeth could not be saved. The alveolar ridge in the upper jaw was considerably atrophied.—Fig. 3: After bone augmentation, ten implants were placed. The photograph shows the situation prior to the prosthetic phase.—Fig. 4: Four implants were placed in the lower jaw. Bone augmentation measures were not necessary in this case.—Figs. 5a & b: Recording of the aesthetic facial axes with the Ditrax system.—Fig. 6: The denture was set up with prefabricated teeth (SR Phonares II).—Fig. 7: Try-in of the CAD/CAM-fabricated titanium framework in the upper jaw.—Fig. 8: The ground-down composite resin areas were conditioned for receiving the light-curing laboratory composite SR Nexco.—Fig. 9: Application of the colour-saturated intensive gingiva materials (SR Nexco Paste Intensive Gingiva).—Fig. 10: The application of various translucent materials imparted the prosthetic gingiva with the desired depth effects.—Fig. 11: Lifelike, vital, aesthetic—the white and pink aesthetics were optimally imitated.—Fig. 12: The restorations on the implants in the upper and lower jaws.—Fig. 13: Close-up view: the macro- and microstructure of the teeth and the characteristic play of colour of the gingiva is clearly visible.—Fig. 14: The complex restoration gave the patient a new lease on life.

A 37-year-old female patient presented to our practice with her teeth and the surrounding bone structure in very poor condition (Figs. 1 & 2). Numerous teeth were missing from both the upper and lower jaws. In addition, the upper jaw showed considerable bone and gingival resorption. The patient wished to have her teeth restored to regain an attractive appearance. Owing to the extensive damage, complete restoration of both jaws with implants was indicated.

During the osseointegration period of the mandibular implants, the maxillary bone was reconstructed. The maxillary sinus and the alveolar ridge were augmented in one appointment. At a later appointment, ten implants were placed according to the treatment plan and exposed after six more months. As a result of well-planned soft-tissue management, adequate firm keratinised tissue had formed. The permanent restorations for the upper and lower jaws were fabricated two months later (Figs. 3 & 4).

the treatment is of a functional nature. It is intended to ensure optimal occlusal integration of the restorations and the proper jaw movements during mastication, speaking and swallowing. In this particular case, the maxillary model was positioned with the help of a facebow. Four impression posts were screwed on to the implants in order to provide strong support and enhanced reliability.

Alternatively, this step can take place directly on the immediately

and the vertical dimension of occlusion are correct, the immediately loaded provisional restorations can be used for this purpose. The restorations have to be immobilised when they are mounted in the articulator. The Artex system (Amann Gyrbach) allows the articulator of the dental practice and that of the laboratory to be synchronised.

The Ditrax system was used to transfer the precise data on the aesthetic facial axes to the maxillary model (Figs. 5a & b). Two axes

The absolute disinfection for Endodontics !

IRRIGATYS®

Come to our booth
**IDEM
2015**
Hall 4, E22

Irrigation

Disinfection

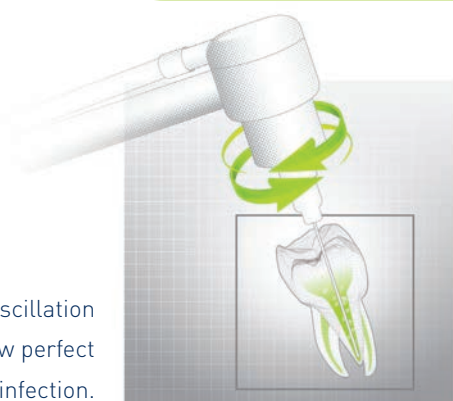
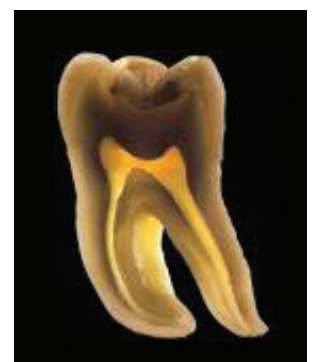EFFICIENT ROOT CANAL CLEANING

**PATENTED
CONCEPT**

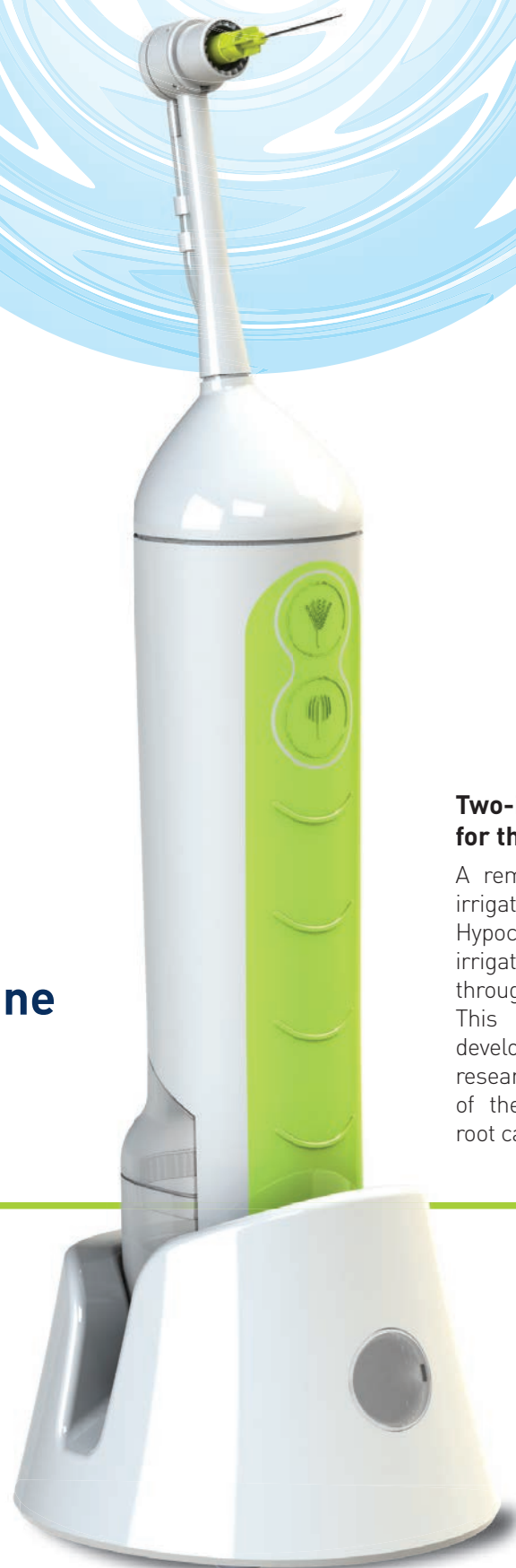IRRIGATYS :
the new two-in-one
handpiece with
dual functions

**Two-in-one system provides and activates liquid
for the perfect clean.**

A removable tank allows the irrigation of the root canal with Hypochlorite and EDTA. The irrigation line leads the solution through the Irriga-Tip®. This patented technology, developed after 6 years of research, optimizes the result of the complex procedure of root canal irrigation.



Tip oscillation
to allow perfect
disinfection.



ITENA®
CLINICAL PRODUCTS

ROOTS SUMMIT

30 NOVEMBER - 3 DECEMBER, 2016

THE MASTERS OF ENDODONTICS



Antonis Chaniotis
Greece



David E. Jaramillo
USA



Freddy Belliard
Dominican Republic/Spain



Oscar von Stetten
Germany



Rafaël Michiels
Belgium



Enrico DiVito
USA



Sergio Rosler
Argentina



Imran Cassim
South Africa



Siju Jacob
India



Bojidar Kafelov
Bulgaria



Mile Churlinov
Bulgaria



**Roberto Cristian
Cristescu**
Romania/Netherlands



**Luis Chávez
de Paz**
Peru/Sweden



**Ronald Ordinola
Zapata**
Peru



**Carlos Aznar
Portoles**
Spain/Netherlands



**Ahmed Abdel
Rahman Hashem**
Egypt

ARE MEETING IN DUBAI
WITH THE ROOTS COMMUNITY

DATE: 30 NOV - 3 DEC
LOCATION: CROWNE PLAZA, DUBAI

ROOTS
SUMMIT

30 NOVEMBER - 3 DECEMBER, 2016

EARLY BIRD 20% OFF
REGISTER AT WWW.ROOTS-SUMMIT.COM

The conventional flask technique with a heat-curing denture base material (ProBase Hot, Ivoclar Vivadent) was used to produce the denture. After the polymerisation process, the denture base was ground and space was made for building up the Gingiva composite. The surface was conditioned by blasting it with aluminium oxide (50 µm) at 200 kPa (Fig. 8). A bonding agent was then applied and left to react for three minutes before it was light cured.

In order to achieve very lifelike results in the layering of the gingival tissue, saturated (intensive) materials (SR Nexco Paste Intensive Gingiva) were used first (Fig. 9). Next, translucent, light-curing gingival materials (SR Nexco Paste Gingiva and SR Nexco Paste Basic Gingiva) were used to impart the gingival areas with the desired depth (Fig. 10). The colours of the Gingiva composites range from pale pink through reddish and orange to purple. A certain amount of time and effort are necessary to master the necessary mixing techniques and achieve a harmonious interplay of the intensive and the translucent materials. Practical experience is essential. With some technical skill, the gingival areas can be naturally reproduced in terms of shape, texture and shade.

All the individual layers were pre-cured (Quick curing light, Ivoclar Vivadent) in segments. A high-performance curing light was used for the final polymerisation. Prior to this step, a coating of glycerine gel (SR Gel, Ivoclar Vivadent) was applied to the surfaces to prevent oxygen inhibition, which could lead to an unattractive result that is difficult to polish. The surfaces of the teeth were characterised with a vertical and horizontal macrostructure. Particular attention was paid to mechanical polishing. Once the glycerine gel had been removed, the restorations were finished with different polishing instruments (various grit sizes, pumice, leather buffing wheels and universal polishing paste; Fig. 11). In the present case, mechanical polishing was preferred to glazing with a light-curing composite in order to prevent premature ageing of the surface.

The dentures were seated manually with the help of multi-unit

abutments from Nobel Biocare (Fig. 12). The screw channels were sealed with Teflon and light-curing composite resin. The position of maximum intercuspation was checked and the occlusal pathways were adjusted to the protrusive and laterotrusive movements. In addition, the restorations were checked in terms of the ability to clean them with interdental brushes, and the patient was given special instructions regarding her oral hygiene.

Conclusion

For a long time, ceramics were considered to be the aesthetic benchmark. With the introduction of state-of-the-art industrially fabricated acrylic teeth specially designed for implant applications, the bar for aesthetics has been raised in this category of materials. The teeth used in this case exhibit a true-to-nature morphology, which allows the restoration to be functionally integrated without any problems.

Using the laboratory composite SR Nexco to recreate gingival tissue is an effective restorative approach. In contrast to ceramic materials, the composite resin is easy to handle and delivers exceptionally aesthetic results (Fig. 13). The light weight of the material is an added benefit. An all-ceramic restoration (zirconium dioxide framework, layering ceramic, gingival mask) weighs almost twice as much as a titanium and composite resin denture. Another advantage of the type of restoration

described here is its long service life. The success of an implant-supported denture depends on the systematic coordination of all the surgical and prosthetic requirements. A strict procedure needs to be followed from the treatment plan to the final outcome. Layering gingival portions with a laboratory composite represents a genuine improvement on previous materials and methods with regard to aesthetics, handling and hygiene (Fig. 14).

AD

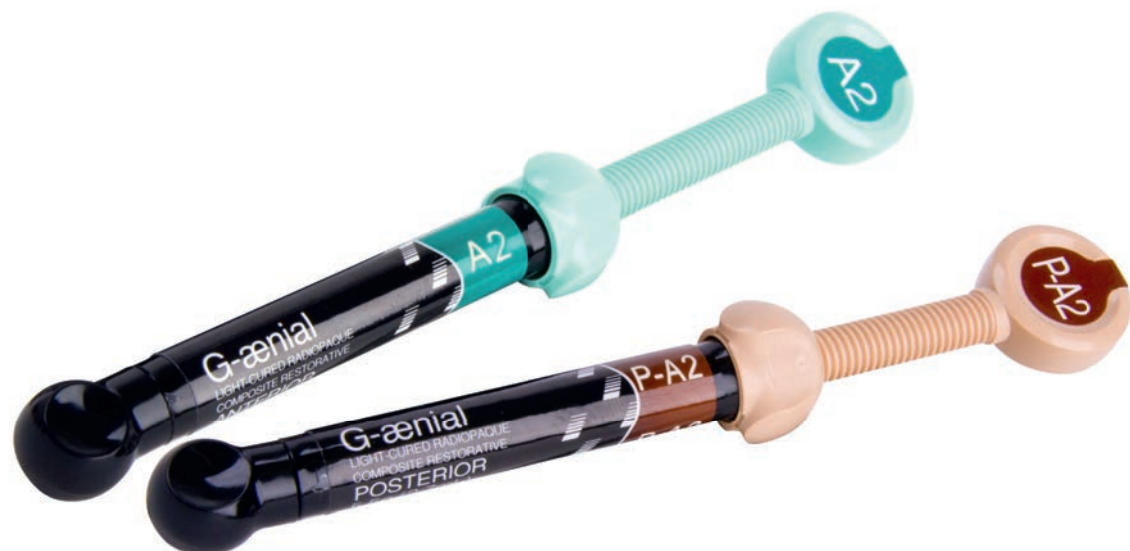

G-ænial ANTERIOR & POSTERIOR

Effortless Beauty

A universal composite that acknowledges that anterior and posterior teeth are different

- Exceptional handling for a total control
- Outstanding invisible aesthetics that blends seamlessly to the tooth
- Forward thinking shading concept: standard, inside and outside shades



Dr Patrice Margossian maintains a private practice specialising in implantology and prosthetics in Marseille in France. He can be contacted at pm@patricemargossian.com.



Dr Andrieu Pierre is a practising prosthodontist in Aix-en-Provence in France. He can be contacted at andrieupi@wanadoo.fr.

GC Asia Dental Pte Ltd
11 Tampines Concourse #03-05
Singapore 528729

T: +65 6546 7588
F: +65 6546 7577
www.gcasiadental.com