

IMPLANT TRIBUNE

The World's Dental Implant Newspaper · U.S. Edition

DECEMBER 2008

www.implant-tribune.com

VOL. 3, No. 12

Inside this issue

An implant treatment coordinator can help



Consider hiring an implant treatment coordinator to drastically increase the effectiveness of your practice.

Page 15

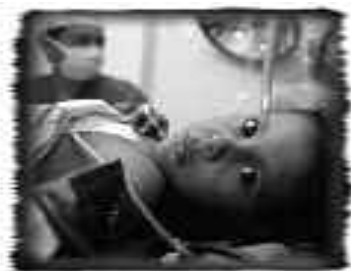Workshop focuses on narrow implants



Dr. Sang-Choon Cho teaches on "Advanced Narrow Diameter Implant Technologies for Replacement of Patients' Missing Teeth in Narrow Bone and Limiting Spaces" at NYU workshop hosted by Dentatus.

Page 19

AD



Make a difference in her life... the lives of her children... and her grandchildren.

TEACH • TRAVEL • LEARN
www.hvusa.org

Health Volunteers Overseas
Improving Global Health Through Education
Tel: 202-296-0026 • E-mail: info@hvusa.org

AAID: Use of mini dental implants on the rise but questions linger

There is spirited debate in the field of implant dentistry about proper use of mini dental implants.

Proponents are urging wider use of the shorter, less costly procedure while others advocate a more conservative approach until several long-term outcomes studies are published, according to the American Academy of Implant Dentistry (AAID).

Concerns also have been raised about whether general dentists who adopt mini implants receive sufficient implant training. Though mini-implant companies provide weekend training sessions, AAID believes such instruction falls short of what dentists must know before adding

implants to their practices.

"Dentists need to be well versed in implant dentistry before using mini implants," said Kim Govey, DDS, a past AAID president. "Without extensive implant knowledge, they will not know proper surgical techniques and all the basics about bone healing critical for implant success. If you want to practice implant dentistry, there are no shortcuts for gaining the necessary knowledge and training."

In a plenary-session presentation at the recent AAID annual scientific meeting in San Diego, Todd Shatkin, DDS, said mini implants are half the diameter of traditional implants — almost toothpick size — and the

insertion procedure is less invasive and half the cost of traditional implants.

"Mini implants made from titanium alloys are strong enough to withstand normal chewing force and can be used confidently for immediate-load, long-term restorations," Shatkin said. He added that he now uses mini implants for stabilizing dentures, single-tooth implants and even full-arch restorations.

"The FDA has approved some mini implant systems for long-term use, and patients can have a denture stabilized in about an hour or get a

→ **IT** page 2

Radiographic evaluation of the implant site

By Pankaj Singh, DDS, DICOI, DABOI/ID

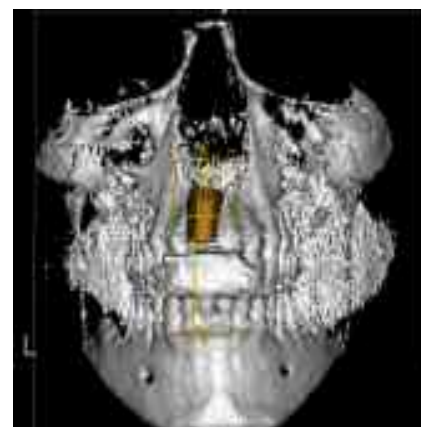Since Dr. Bränemark's historic lecture at the Toronto symposium in 1981, implant dentistry has not been the same. The biggest challenge in my opinion has not been so much performing the surgical procedure, but in the diagnosis, treatment planning and accurate evaluation of the potential implant site.

Traditional 2-D radiography had been used in dentistry for decades, and is still being used today with

great success. The ease of use, interpretation and low cost make it a very affordable and routine diagnostic tool for most general dentistry.

When it comes to advanced dental therapies like implants, 2-D radiographic assessment of the implant site is just not enough as the buccal-lingual (cross section) view of the site is often the missing critical third dimension.

First came spiral CTs and dentists used them sparingly, mostly for oral-maxillofacial procedures or for ruling out pathology that wasn't visible on the traditional 2-D radiographs. Off site, high radiation dose exposure and high cost and not being insurance reimbursable, these referrals often met with resistance from the patient.



AP view of the proposed #8 site.

In May 2001, cone beam volumetric tomography (CBVT) imaging specifically for the use in dentistry in the United States was first introduced by QR SRL of Verona, Italy, the manufacturer of Newton (April 2008 CDA Journal). Since then, several different CBVT manufacturers and software developers

→ **IT** page 6

Address Service Requested

PRSRT STD
U.S. Postage
PAID
Permit # 306
Mechanicsburg, PA

Adult patients with cleft lip or palate often require continuing care

A greater number of specialized or centralized care options may be needed for adults with cleft lip or palate, according to a new study, because these patients continue to face health and mental problems that often require the assistance of more than one specialist.

The patients include those continuing their care from childhood and others seeking new advice or intervention, according to authors Cher Bing Chuo, Yvonne Searle, Alison Jeremy, Bruce M. Richard, Ian Sharp and Rona Slato. Their article, "The Continuing Multidisciplinary Needs of Adult Patients with Cleft Lip and/or Palate," appeared in the October 2008 issue of *The Cleft Palate-Craniofacial Journal*, published by the American Cleft Palate-Craniofacial Association.

"Some adult patients of all ages and all cleft types continue to have problems related to their cleft lip and/or palate and want intervention

for those problems," according to the authors. The most common problem is persistent nasal deformity. Other issues include problems related to hearing, speech, teeth and social life, plus concerns about social skills and social withdrawal.

The study examined patients who have been treated at adult multidisciplinary cleft clinics in the West Midlands, U.K., since June 2000. The researchers reviewed the number and nature of the patients' problems and the types of treatment they required in 2004.

A total of 145 patients were seen in the adult cleft clinic. Of those, 55 patients attended as part of their continuing care. Ninety were newly referred as adults to the cleft service. Patients ranged in age from 15 to 70 years and had, on average, three clinical problems each.

According to the authors, "Intervention for the patients reviewed in this study included varied types of

surgery, dental rehabilitation, psychological assessment and support, and speech assessment and therapy."

The authors conclude: "The problems of adults with cleft lip and/or palate may be changing. Our study supports the need for a specialist multidisciplinary cleft clinic to provide continuing care for patients who have a history of cleft lip and/or palate."

To read the entire study, visit: <http://www.allenpress.com/pdf/> and click on *cpcj-45-03-15.pdf*.

(Source: *The Cleft Palate-Craniofacial Journal* is an international, interdisciplinary journal reporting on clinical and research activities in cleft lip/palate and other craniofacial anomalies, together with research in related laboratory sciences. For more information about the journal, see <http://cpcj.allenpress.com/cpcjonline/?request=index-html>.)

← II page 1

single-tooth implant in 30 minutes," Shatkin said. He reported findings from his February 2007 article published in *Compendium Dental Journal* showing his overall success rate with mini implants was 95 percent. He noted implants are now widely accepted in the dental profession for denture stabilization and crown and bridge applications.

For stabilizing dentures, Shatkin explained that four mini implants are inserted in the front of the patient's lower jaw. It requires mild anesthesia. The dentist adjusts the denture to snap on to the implants and secure it. Denture wearers also can remove the prosthesis for cleaning and snap it back in place.

Concerns about research

Italian dental researcher and practitioner Matteo Chiapasco, MD, presented a more conservative view to AAID meeting attendees, stressing there is inadequate scientific literature supporting long-term use of mini implants and no well-defined protocols to determine clinical situations for which they should be indicated.

"Adopting any procedure without

sufficient research would bring us away from practicing evidence-based dentistry and back to the 1970s and '80s when decisions were made from clinical experimentation," Govey said.

According to AAID President Jaime Lozada, DDS, there is concurrence for using mini implants to stabilize a denture and for insertion in tight spaces between teeth, but many implant dentists do not use them for single tooth or multiple implant placements.

"For placing implants in an extraction site, in most cases, it's in the patient's best interest to use a traditional implant to help preserve the bone and promote better osseointegration," he said.

Olivia Palmer, DMD, an AAID Fellow practicing in Charleston, S.C., believes mini-implants aren't designed to support normal-size crowns for single-tooth implants.

"The chewing force applied from a crown could overwhelm a mini implant and put way too much pressure on the bone. This can lead to bone loss and eventual implant failure," she said.

AAID credentialing program

For general dentists and specialists alike, the AAID credentialing

program is an excellent investment in the future as the popularity and success of implants continues to rise.

The exam for the associate fellow credential consists of a written test and an oral examination, which includes defense of three clinical cases that the candidate completed. Applicants must be licensed dentists who have at least 300 hours of post-doctoral or continuing education in implant dentistry, divided between the sciences related to implant dentistry (such as anatomy, immunology and pharmacology) and clinical implant education. Candidates must pass the written exam before applying to take the oral/case part, and both must be completed successfully within four years.

About AAID

AAID can help consumers find a local credentialed implant dentist at www.aaid.com. AAID is based in Chicago and has more than 3,500 members. It is the first organization dedicated to maintaining the highest standards of implant dentistry by supporting research and education to advance comprehensive implant knowledge.

(Source: AAID)

IMPLANT TRIBUNE

The World's Newspaper of Implantology - U.S. Edition

Publisher
Torsten Oemus
t.oemus@dtamerica.com

President
Eric Seid
e.seid@dtamerica.com

Group Editor
Robin Goodman
r.goodman@dtamerica.com

Editor in Chief
Sascha A. Jovanovic, DDS, MS
sahara@jovanoviconline.com

Managing Editor/Designer
Sierra J. Rendon
s.rendon@dtamerica.com

Managing Editor Endo Tribune
Fred Michmershuizen
f.michmershuizen@dtamerica.com

Managing Editor Ortho Tribune
Kristine Colker
k.colker@dtamerica.com

Account Manager
Humberto Estrada
h.estrada@dtamerica.com

Marketing Manager
Anna Wlodarczyk
a.wlodarczyk@dtamerica.com

Marketing & Sales Assistant
Lorrie Young
l.young@dtamerica.com

C.E. Manager
Julia Wehkamp
j.wehkamp@dtamerica.com

Design Support
Yodit Tesfaye
y.tesfaye@dtamerica.com

Dental Tribune America, LLC
215 West 55th Street, Suite 801
New York, NY 10001
Phone: (212) 244-7181, Fax: (212) 244-7185



Published by Dental Tribune America

© 2008, Dental Tribune International GmbH. All rights reserved.

Dental Tribune makes every effort to report clinical information and manufacturer's product news accurately, but cannot assume responsibility for the validity of product claims, or for typographical errors. The publishers also do not assume responsibility for product names or claims, or statements made by advertisers. Opinions expressed by authors are their own and may not reflect those of Dental Tribune International.

Editorial Advisory Board

Dr. Sascha Jovanovic, Editor in Chief

Dr. Bernard Touati

Dr. J.T. Krauser

Dr. Andre Saadoun

Dr. Gary Henkel

Dr. Doug Deporter

Dr. Michael Norton

Dr. Ken Serota

Dr. Axel Zoellner

Dr. Glen Liddelow

Dr. Marius Steigmann

II Corrections

Implant Tribune strives to maintain the utmost accuracy in its news and clinical reports. If you find a factual error or content that requires clarification, please report the details to Managing Editor Sierra Rendon at s.rendon@dtamerica.com.

**Tell us
what you
think!**

Do you have general comments or criticism you would like to share? Is there a particular topic you would like to see more articles about? Let us know by e-mailing us at feedback@dtamerica.com. If you would like to make any change to your subscription (name, address or to opt out) please send us an e-mail at database@dtamerica.com and be sure to include which publication you are referring to. Also, please note that subscription changes can take up to six weeks to process.



SURGICAL SUPPLY CO., INC.

A POWER TRIO

FOR ALL YOUR GRAFTING NEEDS



Power-up your
in-office performance
with an ACE seminar!

ADVANCED TISSUE GRAFTING 2-DAY HANDS-ON CADAVER WORKSHOP

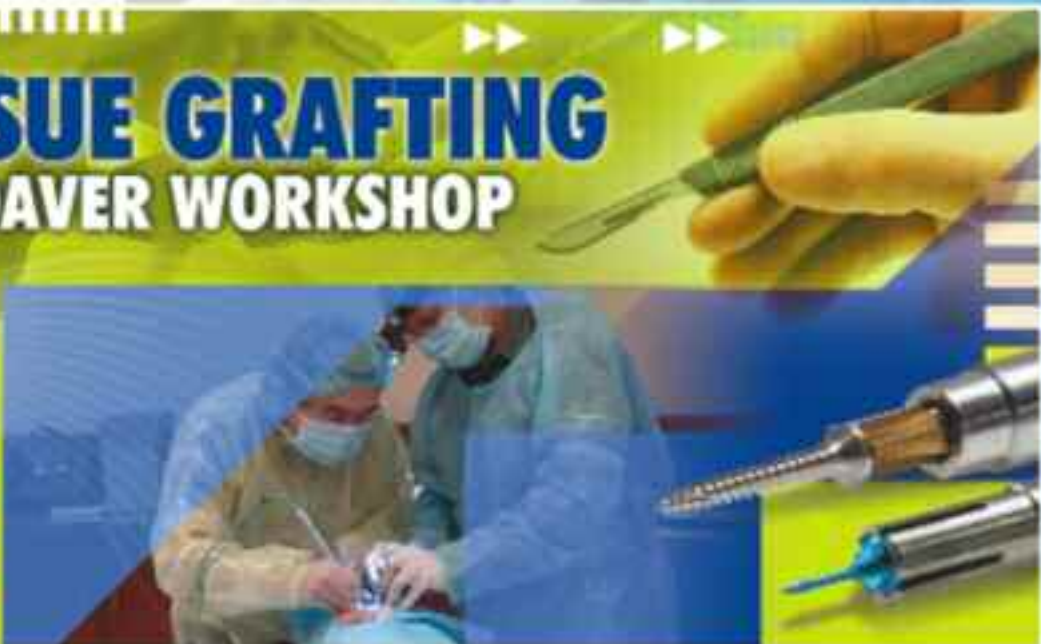ORLANDO, FL

April 25-26, 2009

Featured Speakers:
Arnon Gonen, PhD, DDS, FRCD(C), FRCO

Course Locations:
Walt Disney World Swan and Dolphin

Course Registration:
www.acesurgical.com/cadaver.html



800.441.3100

www.acesurgical.com

ACE Surgical Supply Company, Inc.
17001 P.O. Box 15000 - Jacksonville, FL 32218

AAID: Implants effective for orthodontic treatment

Orthodontists have been straightening teeth for decades relying on the ancient physics principle “every action has a reaction,” in which tooth displacement in one part of the jaw causes movement on the other as well.

Use of dental implants as orthodontic anchors, however, is changing that principle by expediting treatment times and expanding possibilities for previously untreatable cases, according to research presented at the American Academy of Implant Dentistry Annual Scientific Meeting in San Diego.

“Dental implants are changing the way orthodontics is being practiced,” said Frank Celenza, DDS, associate clinical professor, New

York University College of Dentistry. “In conventional orthodontics, teeth are used to move other teeth, but implants can serve as excellent anchors from which force is applied to move the targeted teeth without causing shifts in other teeth.”

In his plenary session presentation, Celenza explained that the use of implants as sources of orthodontic anchorage is a powerful technique that has just begun to be explored.

“In our studies, we’re already seeing cases in which implants simplify and streamline orthodontic therapy, decrease treatment times, and eliminate dependence on patient compliance in making adjustments and wearing orthodontic appliances,” Celenza said. “Because the anchor

systems are so much more predictable and stronger when implants are incorporated, the temporal sequencing of tooth movements is eliminated and teeth can be moved en masse or all together. Consequently, treatment times easily can be reduced by a third.”

Celenza added implants can be used in any orthodontic case that requires tooth replacement, as well as for fully dentate patients.

“Cases progress faster when implants are used as anchorage but not because teeth are subject to higher force levels. Rather, it is the result of a more efficient appliance design that provides the ability to move multiple teeth simultaneously rather than individually, as is neces-

sary in conventional orthodontics.”

Dental implants also make it possible for some patients to receive orthodontic treatment that previously would not be feasible.

“Patients with severe orthodontic deformities now can be reevaluated to determine if orthodontic dental implants could provide successful outcomes,” Celenza said.

Commenting on the significance of the research, AAID President Jaime Lozada, DDS, said the orthodontic implant application further underscores the versatility of dental implants for both restorative and cosmetic dental procedures.

(Source: American Academy of Implant Dentistry)

Inflammation: Connecting the mouth and body?

Research suggests chronic inflammation links gum disease to other disease states

Brush after every meal. Floss daily. See your dental professional regularly. These instructions make sense coming from your dentist to help you sustain your oral health. But now not only dentists, but also many physicians, are stressing the importance of maintaining oral health in an effort to keep the rest of the body healthy.

Research has long suggested an association between gum disease and other health issues, including heart disease, stroke and diabetes, but now scientists are beginning to shift their focus to understanding why these connections exist. An emerging theory, and one gaining support from researchers worldwide, is that inflammation may link the mouth to the body.

Inflammation is the body’s instinctive reaction to fight off infection, guard against injury or shield against irritation. Inflammation is often characterized by swelling, redness, heat and pain around the affected area. While inflammation initially intends to heal the body, over time, chronic inflammation can lead to dysfunction of the infected tissues, and therefore more severe health complications.

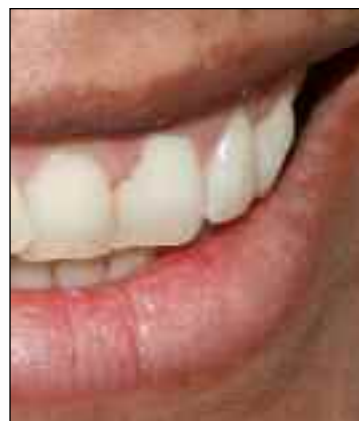According to Dr. Susan Karabin, past president of the American Academy of Periodontology (AAP) and a practicing periodontist in New York City, periodontal disease is a textbook example of an inflammatory disorder.

“For many years, dental professionals believed that gum disease was solely the result of a bacterial infection caused by a build-up of

‘... gum disease sufferers are at a higher risk for other diseases, making it more critical than ever to maintain periodontal health in order to achieve overall health.’

plaque between the teeth and under the gums. While plaque accumulation is still a factor in the development and progression of gum disease, researchers now suspect that the more severe symptoms, namely swollen, bleeding gums; recession around the gum line, and loss of the bone that holds the teeth in place, may be caused by the chronic inflammatory response to the bacterial infection, rather than the bacteria itself.”

Periodontists hypothesize that this inflammatory response to bacteria in the mouth may be the cause behind the periodontal-systemic health link. Many of the diseases associated with periodontal disease are also considered to be systemic inflammatory disorders, including cardiovascular disease, diabetes, rheumatoid arthritis, chronic kidney disease and even certain forms of cancer, suggesting that inflammation itself may be the basis for the connection.



“More research is needed to pinpoint the precise biological mechanisms responsible for the relationship between gum disease and other disease states,” Karabin said. “However, previous findings have indicated that gum disease sufferers are at a higher risk for other diseases, making it more critical than ever to maintain periodontal health in order to achieve overall health.”

To avoid gum disease, Karabin recommends comprehensive daily oral care, including regular brushing and flossing, and routine visits to the dentist. If gum disease develops, a consultation with a dental professional, such as a periodontist, can lead to effective treatment. Patients diagnosed with gum disease should also disclose all health conditions to their dental professionals, and be sure to update other health care professionals on their periodontal health.

A recent supplement to the Journal of Periodontology highlighted current discussions between dental professionals and health care professionals on the role of oral inflammation in the progression of other disease states. As research continues to emerge that supports the mouth-body connection, the more vital it becomes that both dentists and physicians work together to ensure the most comprehensive wellbeing for their patients.

(Source: American Academy of Periodontology)

BIOMET 3i announces 2009 evening programs

New Solutions for Enhanced Aesthetic Restorations will present clinical solutions to meet aesthetic demands including soft tissue management, the utilization of transitional abutments to achieve non-surgical tissue sculpting, final abutment choices from prefabricated to customized and the selection of ideal abutment materials to achieve enhanced aesthetics and long-term function.

The program will be held from 5:30–8:30 p.m. at various locations around the country:

Feb. 4, Milbrae, Calif.; Feb. 5, Bellevue, Wash.; Feb. 5, Los Angeles; Feb. 18, Houston, Texas; Feb. 19, Irving, Texas; March 12, San Diego, Calif.; March 18, Baltimore, Md.; March 26, Atlanta, Ga.; April 16, Newton, Mass.; April 22, Southfield, Mich.; and April 23, Chicago.

To register, call (800) 717-4143 or visit www.biomet3i.com and click on Education Programs.

BIOMET 3i is a leading manufacturer of dental implants, abutments and related products. Since its inception in 1987, BIOMET 3i has been at the forefront in developing, manufacturing and distributing oral reconstructive products, including dental implant components and bone and tissue regenerative materials. The company also provides educational programs and seminars for dental professionals around the world. BIOMET 3i is based in Palm Beach Gardens, Fla., with operations throughout North America, Latin America, Europe and the Pacific Rim.

(Source: BIOMET 3i)

REVOLUTIONARY

FOR EXPERIENCED USERS

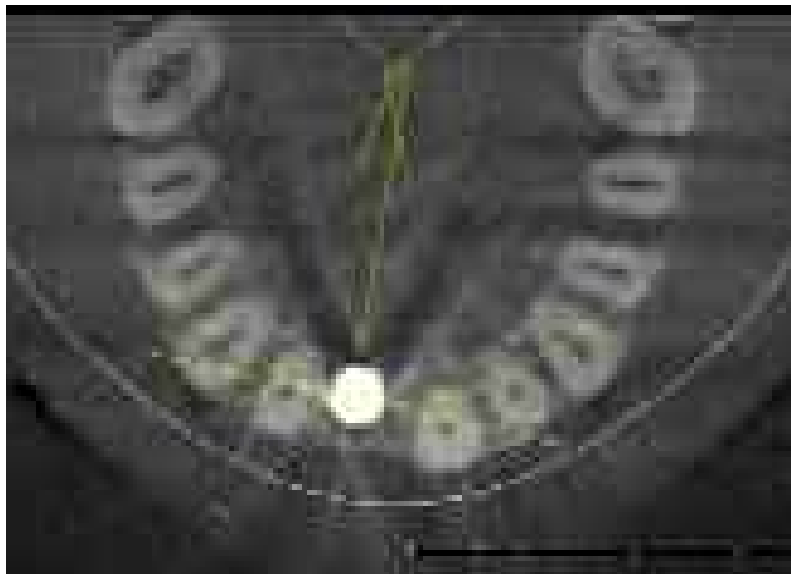


NobelActive™

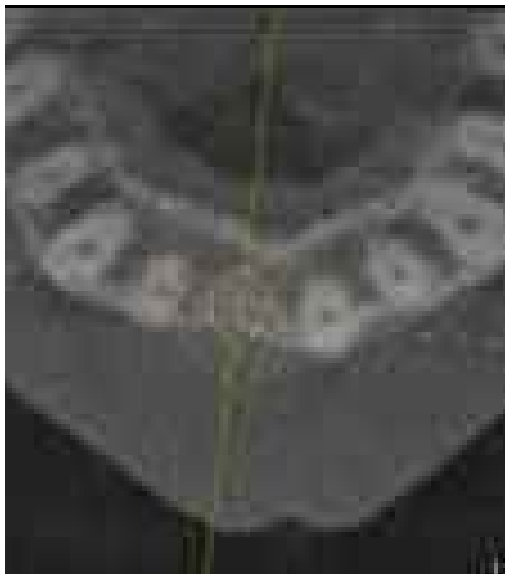Featuring a unique tip-and-thread design, NobelActive™ slices through bone while progressively condensing and repositioning it. This revolutionary implant provides high initial stability and conical abutment connection that enables predictable platform shifting. The result is rapid, accurate implant placement with fewer drilling steps and optimal restorative orientation.

For more information, contact your Nobel Biocare Representative, call Customer Support at 1.800.322.5001 or visit www.nobelbiocare.com.





Axial view of the implant #8 with expanded buccal plate.



Axial view of the planned implant #8 position.

← II page 1

have significantly contributed to the advancement and adoption of the technologies (see references 1 and 2 of the April 2008 CDA Journal), allowing clinicians to practice prosthetic-driven implant dentistry.

The ever so important and multifaceted task of determining the accurate placement of implants and assessing bone-grafting procedures (guided bone regeneration) prior to surgery is paramount.

Two-dimensional images such as a panoramic and periapical (PA) films have inherent shape and size distortion, along with changes in magnification. In order to minimize potential surgical complications, one of the most important steps is obtaining appropriate radiographs utilizing the data from a CBVT and combining the images with an interactive 3-D implant treatment planning software, which can significantly increase the accuracy of the implant placement for an ideal prosthetic result.

The accuracy of the CBVT results from the size of a voxel, which is short for volume pixel. The smaller the voxel size, the more accurate the resulting scan, and the better the resolution. A voxel is to a CBVT as a pixel is to a digital PA. The ability to assess an area of interest in three dimensions can benefit both novice and experienced clinicians alike.

High resolution limited CBVTs have been designed for dental applications, as opposed to sliced-image data of conventional CT imaging. CBVT captures a cylindrical volume of data that offers advantages over CT that include increased accuracy, higher resolution and decreased radiation dose exposure.

I will try to illustrate through the report of a case involving a missing maxillary central incisor that this concept can also be applied for multiple implants. The use of planning tools allows the clinician to effectively communicate the plan with the other members of the implant team as well as with the patient.

Case study

A 58-year-old male presented as a new patient to our office. His chief complaint was he was unhappy with the esthetics and the stability of the three-unit Maryland bridge that was constructed to replace a maxillary right central incisor (tooth #8) that was extracted secondary to sustaining a fractured root during post and core insertion after endodontic therapy approximately 20 years ago.

Since then he has had to have the bridge recemented numerous times. His medical history revealed no significance findings. The retracted antero-posterior (frontal)

AD

**Always
in control**

SimPlant[®] CompatAbility

Imagine a set of tools that gives you the confidence to perform every step of implant treatment with pinpoint predictability and accuracy. Now imagine all of this at the time of surgery. You've embraced SimPlant[®] CompatAbility, a cost-effective, highly profitable and user-friendly system that gives you the freedom to work with any implant brand available on the market today. For more information on the latest version of SimPlant visit www.materialisedental.com.

Come see us at:
AAOMS Chicago Booth #427

SimPlant[®] SurgiGuide[®] Immediate Smile[®]

www.materialisedental.com

**Materialise
Dental**

→ II page 8

Academy of Osseointegration Annual Meeting

February 26-28, 2009

San Diego Convention Center

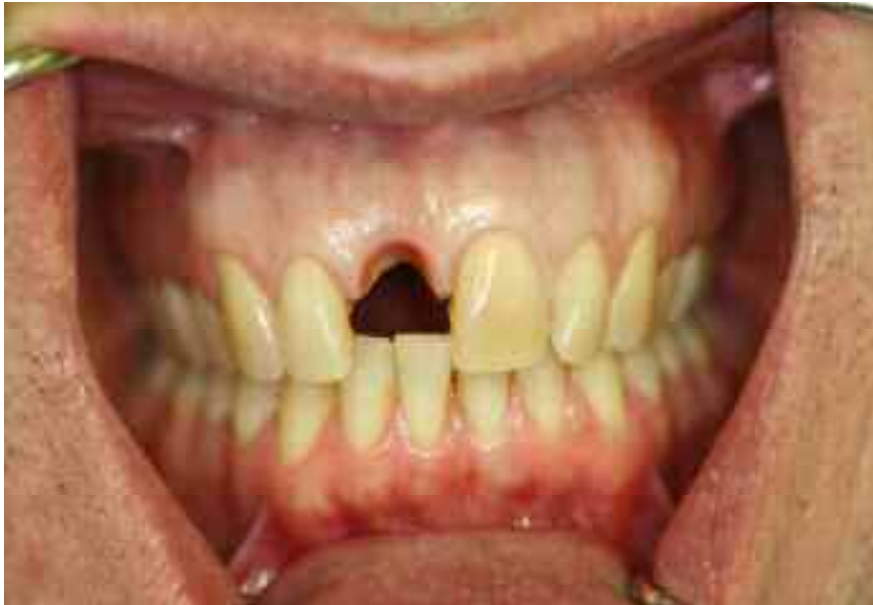San Diego



Highlights include:

- Opening Symposium: *"A New Wave in Implant Therapy: Is there a New Gold Standard? Current Clinical Controversies"*
- Round Table Clinics
- Limited Attendance Lectures
- Two Track Program (Surgical & Restorative)
- Commercial Exhibits
- Failure Festival
- Dental Hygiene/Assistant Program
- Laboratory Technician Program





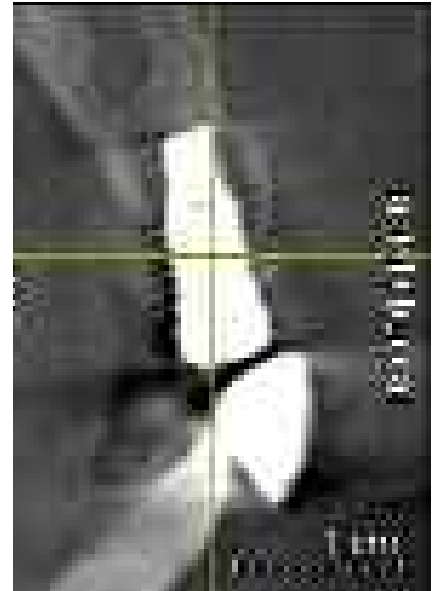
Pre-surgical frontal view #8 without the Maryland bridge.

← **II** page 6

view shows the prosthesis in place and the gingival recession coronopically as compared to the adjacent natural teeth, resulting from years of absence of a root and a resorbed socket supporting the overlying soft tissue. The axial (occlusal) view shows the severe buccal recession resulting in a concavity and an inadequately contoured buccal plate in the area of tooth #8.

The 2-D PA of tooth #8 revealed adequate interdental space needed to place a wide enough diameter that would provide for a properly contoured crown with the appropriate amount of interproximal emergence profile.

It also provided us with the



Cross section view of the implant.

AD

Come Ahead
YANKEE
 Dental Congress[®] 34
 Boston Convention & Exhibition Center
 January 28 - February 1, 2009 • Lobby January 29 - 31, 2009

Chart a New Course for Learning and Discovery in Dentistry

- Fixed-Implant Rehabilitations of the Edentulous Jaws**
 German Galluci, DMD
- Problem Solving For Fixed, Removeable and Implant Procedures**
 Jerry Tanaka, DDS
- New Paradigms in Implant Dentistry**
 David Gills, DDS
- Predictability and Simplification: Implant Overdentures and Implant Retained Partial Dentures**
 Rafael Vespel, DDS

Friday, January 30, 2009
Be Prepared to Laugh Yourself Silly at the First-Ever Yankee Comedy Night
 Featuring
Frank Coliando
 Star of Frank TV and Host of the FOX NFL Pre-Game Show
 and
Kathleen Madigan
 Winner of American Comedy Award for Best Female Stand up

Prosthodontic Specialty Symposium

- The Standard of Care for Fixed vs. Removable Implant Prostheses**
 Joseph Carpentier, DDS
- Successful Implant Prosthodontics in the Esthetic Zone**
 Richard Smith, DDS

Register Now!
WWW.YANKEEDENTAL.COM

height of the alveolar crest in the implant site and the amount of corono-apical resorption of the alveolar crest, allowing us to plan for a straight-walled implant long enough to provide enough osseointegrated surface area to resist and allow for the long-term loading effects on the implant.

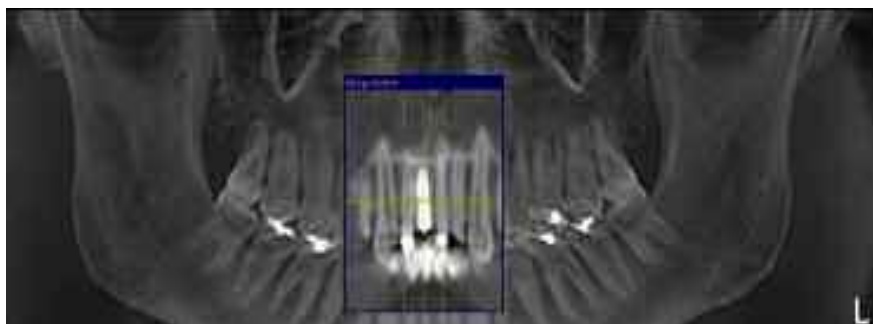From the PA we weren't able to determine the buccal-palatal dimension of the alveolus or do an accurate virtual implant planning, so after explaining the limitations of the PA to the patient and receiving his consent, we scanned him using our in-office Galileos CBVT (Sirona Dental Systems GmbH).

Utilizing the highly interactive viewing software (Galaxis [SiCat]), which is the software component of Galileos, not only visualization of the proposed implant site simultaneously in all three dimensions was possible, but also ruling out of any pathology in the general vicinity that might affect the prognosis of the initial healing process or osseointegration.

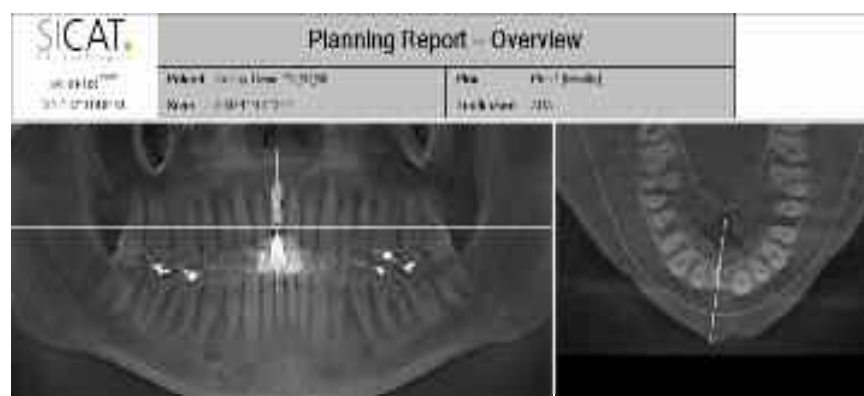
It's also possible to import from a library of implants in the implant planning module that is native in Galaxis and virtually place the appropriately sized implant (Certain straight walled, internal hex implant [BIOMET 5I]) using the existing pontic as a guide that would result in an ideal prosthetic result and conservatively manageable periodontal sulcus depth.

We were also able to determine the need for implant site development at the time of the implant placement, which included an internal socket ridge expansion with bone grafting and coronal advancement of the gingival margin along with a sub-epithelial connective tissue graft to increase the zone of keratinized tissue.

When planning for an implant, it is important to consider the available bone volume, bone density, proximity to vital anatomic structures like roots of adjacent teeth, in the mandible the mental foramen and its anterior loop and inferior

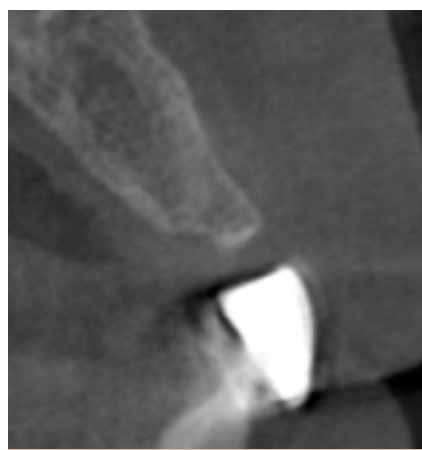


Panoramic view of #8.

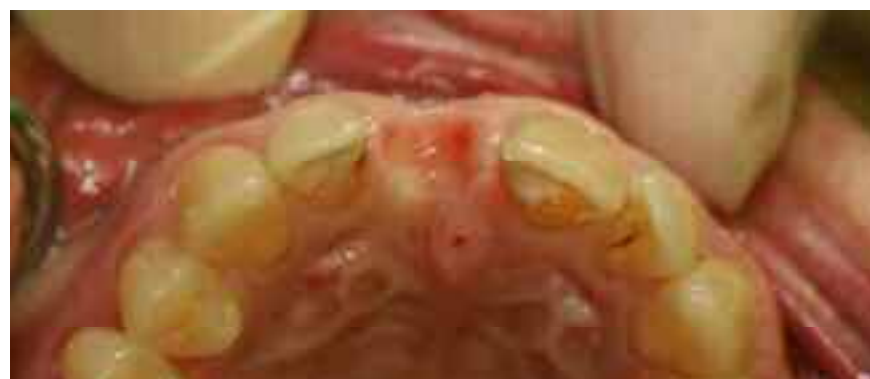

Implant planning report.

‘the acceptance and utilization of CT and CBVT has helped clinicians expand beyond their conventional imaging modalities to understanding the 3-D anatomic presentations and the importance of this technology.’



Cross section view of pre-op site #8.



Pre-surgical occlusal view.

← II page 8

alveolar nerve canal, in the maxilla and the nasal and sinus floor.

The cross-sectional views are the most critical as they show the available bone area and aid in determining the available bone volume, the ratio of cortical bone vs. medullary bone and the thickness and integrity and continuity of the cortical plates surrounding the trabecular bone.

As we were keeping the implant prosthetic position the same as the existing pontic and not changing the occlusion, from the initial study model a vacuum-formed surgical guide was fabricated and used at the time of the surgery.

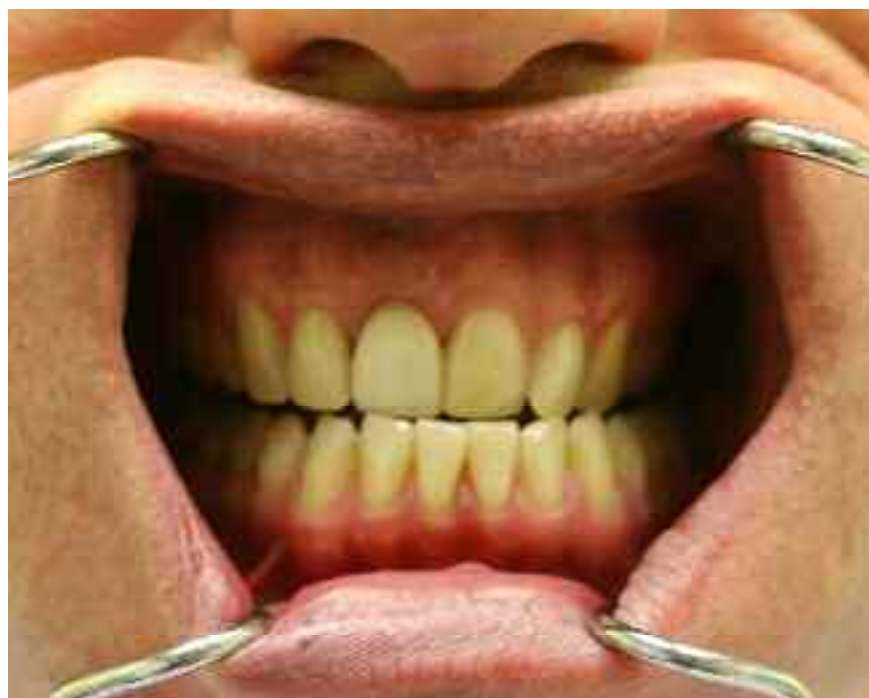The 3-D model can be rotated in any position, allowing for the ultimate inspection and appreciation of the implant site.

The body and thread design of the implant was fully visualized and an accurate assessment of apical and implant body proximity to vital anatomic structures was determined to be non-critical.

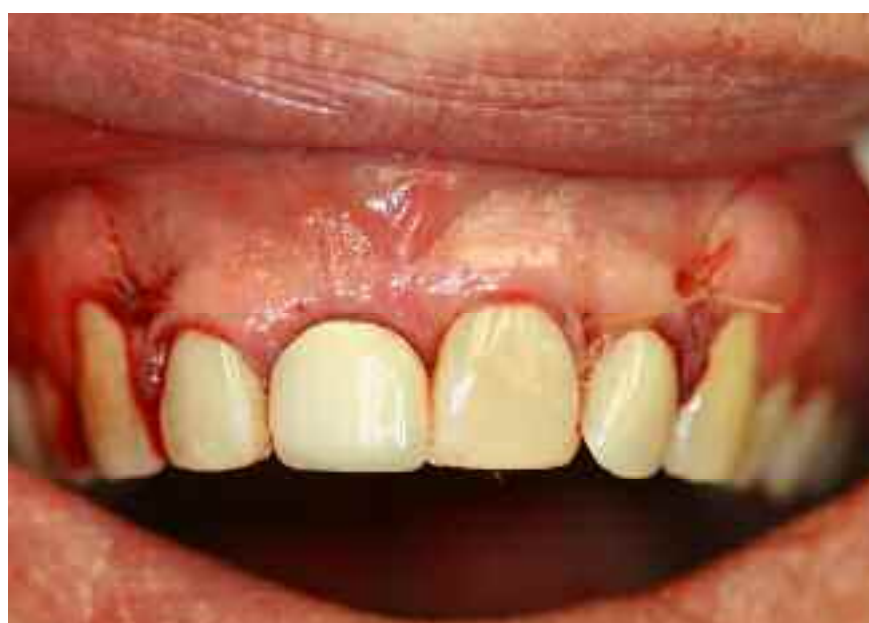The images from the scan and implant planning were incorporated into a CASEY (Patterson Dental) presentation helping the patient understand the recommended treatment.

Conclusion

In the past, 2-D imaging was the only way to help diagnose a potential implant site, especially for a single tooth replacement. However, the acceptance and utilization of CT and CBVT have helped clinicians expand beyond their conventional imaging modalities to understanding the 3-D anatomic presentations and the importance of this technology.



Pre-treatment frontal view with Maryland bridge in place.



Immediate post-surgical frontal now with modified Maryland bridge in place.

II About the author



Dr. Pankaj Singh is the founder of Arch Dental Associates and Le Visage Cosmetic & Implant Dentistry with offices in New York City, Huntington and Garden City, Long Island. A graduate of New York University’s School of Dentistry, he received his advanced training in dental implants at Brookdale Hospital and NYU. Singh has been in private practice for over 15 years, specializing in implant, cosmetic, restorative and laser dentistry. His use of 3-D imaging in planning dental implant procedures and restorations is regarded as a unique and fresh approach to traditional techniques. He is a dual Diplomate of the International Congress of Oral Implantology and the American Board of Oral Implantology. He is also an active member of the Academy of Sleep Medicine. He has received advanced certification in I.V. and Oral Sedation from Montifiore Medical Center. Singh lectures nationally on implant, sleep and aesthetic dentistry.