

DENTAL TRIBUNE

The World's Dental Newspaper · U.S. Edition

JANUARY/FEBRUARY 2011

www.dental-tribune.com

VOL. 6, No. 2

ENDO TRIBUNE

The World's Endodontic Newspaper · U.S. Edition

A new paradigm for endo?

Dr. Barry L. Musikant ponders whether rotary NiTi deserves the title.

▶ page 1B

COSMETIC TRIBUNE

The World's Cosmetic Dentistry Newspaper · U.S. Edition

PFM crowns

'Metal-free' may be a mantra, but all-ceramics do have limitations.

▶ page 1C

HYGIENE TRIBUNE

The World's Dental Hygiene Newspaper · U.S. Edition

What's new in CAMBRA?

The 2010 Western CAMBRA meeting refines the language of dentistry.

▶ page 1D

Koelbl appointed dean of College of Dental Medicine at University of New England

University of New England (UNE) President Danielle N. Ripich, PhD, has announced the appointment of new Dean of the College of Dental Medicine James J. Koelbl, DDS, MS, MJ, of Claremont, Calif. Koelbl is the founding dean of the College of Dental Medicine at Western University of Health Sciences, Pomona, Calif., and will join UNE in April.

The college must be accredited by the Commission on Dental Accreditation (CODA) prior to opening and a dean must be in place for the accreditation process. UNE's publicly stated intent is to open the college in the fall of 2012, and an aggressive fundraising campaign is under way.

To date, \$6.8 million has been raised with a lead gift of \$2.3 million from Northeast Delta Dental and donations from Unum Life Insurance Company of America, New Hampshire's Endowment for Health, Dr. Robert Card and other major contributors. In November 2008, the UNE board of trustees approved the academic program for the doctor of dental medicine degree.

In the recent election, a \$5 million bond to increase access to dental care in Maine was approved. This will help to address the lack of a dental school in the region and

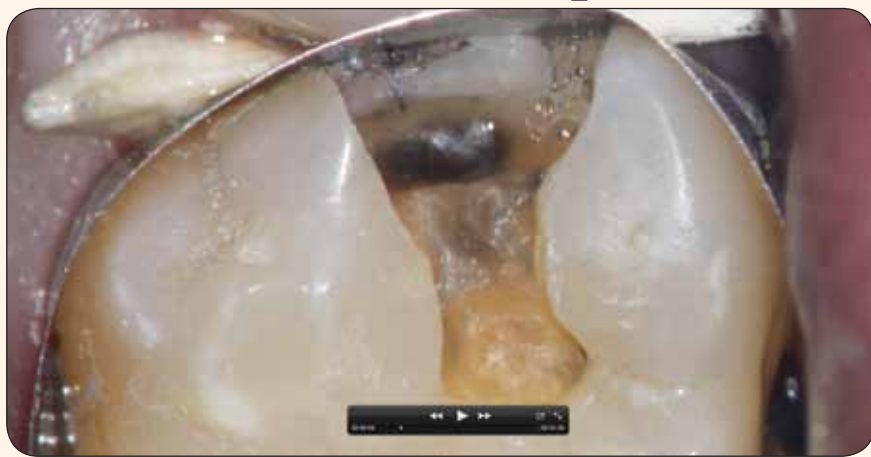the critical shortage of dentists in Maine and Northern New England. The \$5 million bond allocates \$3.5 million to establish a dental school's community-based teaching clinic, which UNE will apply for through a competitive bid process and as part of its effort to raise money for the UNE College of Dental Medicine.

Prior to his current position at Western University, Koelbl served as the dean of the School of Dentistry at West Virginia University from 1999–2007; he held several senior positions at the American Dental Association from 1994–1999, including the position of associate executive director, served as associate dean for clinical affairs and professor at the University of Louisville School of Dentistry from 1992–1994, and held several administrative and faculty positions at the Loyola University School of Dentistry from 1977–1992, including: director, general practice residency; chair, operative dentistry; assistant dean for admissions and student affairs; and associate dean for academic affairs.

Koelbl was an instructor at the University of Illinois College of Dentistry from 1975 to 1977, has received numerous awards and honors and

→ DT page 2A, KOELBL

The dental microscope for GPs



Do you use a dental microscope? If not, read along as Dr. Craig S. Kohler illustrates its effectiveness for general dentistry and you might just be inspired to get one for yourself.

→ See page 5A

Dental school takes aim at neck and back pain

In response to a high prevalence of neck and back pain among working dentists and dental hygienists, the dean of the University of Maryland Dental School, Christian S. Stohler, DMD, DrMedDent, has launched an initiative to bring renewed attention to ergonomics into dental education.

Starting with the current semester, every incoming student must take the school's course "Ergonomics in Dentistry," before he or she can prac-

tice simulations or live-patient dental work. The school wants to be the place where dentists and dental hygienists learn to practice ergonomically correct practices, says Stohler.

"Three out of every five dentists live with the pain," due to years of practicing with poor posture and other unwise positioning, guest lecturer Lance Rucker, DDS, director of clini-

→ DT page 2A, DENTAL SCHOOL

AD

What reaction do you want?

Learn more and order your FREE SAMPLE
www.vocoamerica.com

VOCO Profluorid Varnish
Single Dose
5% NaF

The thin and white transparent 5% Sodium Fluoride Varnish
in a non-messy new delivery system

VOCO America, Inc. - 555 Pleasantville Rd Suite 120 NB - Briarcliff Manor, NY 10510

Call 1-888-658-2584 www.vocoamerica.com - infousa@voco.com

VOCO
THE DENTALISTS

PRSRRT STD
U.S. Postage
PAID
Permit #764
South Florida, FL

Dental Tribune America
116 West 23rd Street
Suite #500
New York, N.Y. 10011

← **DT** page 1A, KOELBL

has written multiple publications and articles during his career.

Koelbl received his DDS from the University of Illinois College of Dentistry, his MJ in health law from the Loyola University School of Law and an MS in oral biology from Loyola University. He received his undergraduate degree from John Carroll University.

"I am very pleased that Dr. Koelbl is joining us at the University of New England," said Ripich. "UNE will benefit greatly from his extensive experience in dental medicine and as the dean of two dental schools. I am confident Dr. Koelbl will enable UNE to expedite the accreditation of the College of Dental Medicine and will also greatly assist in our fundraising efforts for the college."

"I am honored to be selected as the founding dean for the UNE College of Dental Medicine, and appreciate all of the hard work that has been accomplished to date," Koelbl said.

"We have the opportunity to create a modern, innovative and technologically advanced dental education program at UNE where a rich environment for collaboration exists, both internally and externally.

"I appreciate the support that has already been provided by the dental community, and look forward to

meeting and getting to know the dentists throughout the New England area."

Koelbl noted that while many details are yet to be developed, the UNE dental program will focus on a strong foundation in science and research, realistic simulation, early and extensive clinical experiences, interprofessional education and significant community-based education.

"We recognize our strong obligation for the college and its graduates to help improve the health of individuals, families and communities in New England and beyond," Koelbl added.

Named one of the best regional universities in America by U.S. News & World Report, UNE is a leader in health sciences education, biomedical research and the liberal arts.

It offers student-centered, interdisciplinary programs in the College of Osteopathic Medicine, the Westbrook College of Health Professions, the College of Arts and Sciences, the College of Pharmacy and the College of Graduate Studies and graduates more health-care professionals than any other institution of higher learning in Maine.

For more information, visit www.une.edu. **DT**

(Source: University of New England)



Norman Bartner, DDS, clinical assistant professor, leads a new ergonomics course at the University of Maryland Dental School. (Photo/Steve Berberich, UMD News Bureau)

← **DT** page 1A, DENTAL SCHOOL

cal ergonomics and simulation at the University of British Columbia, told this year's incoming class.

Stohler recruited Rucker as the world's leading authority on dentistry ergonomics to kick off its course with a lecture and workshops. He greeted the new students with, "If you want to be a healthy, well-postured individual, statistically you have chosen the wrong profession. However, you do have a choice."

Studies in the United States and in Canada over the past 37 years have underscored the need for dentists to adopt more ergonomically correct equipment and positioning, Rucker explained. He said that two-thirds of dentists lose days of practice each year by avoidable muscular skeletal pain.

Retired professor Michael Belenky, DDS, MPH, has taught what he refers to as human center ergonomics at the school for many years. "We first ask a student to identify how he or she would like to stand or sit for optimal visual and physical comfort and effectiveness," says Belenky.

"Many dentists eventually need years of physical therapy, go to a chiropractor or even have surgery, but seldom do you hear about the need for preventive solutions, the etiology of the problem."

Norman Bartner, DDS, a clinical assistant professor who leads the upgraded course, says, "We are widely recognized as the No. 1 dental school in the country. Now we want to be known as the school that graduates students with the longest careers, greatest earning capacity and who enjoy the most leisure time because they are healthy."

Bartner added, "This should increase alumni financial support for the school as well."

Bartner and Belenky have created an instructional video that begins with dentists who have been forced from the profession with musculoskeletal problems, due to poor ergonomic working conditions.

Bartner said: "I don't want students developing musculoskeletal problems from chronic stress on the neck, shoulder, high back and low back. We start all the dental students off with knowing the proper posture as a dentist for avoiding such career-limiting problems." **DT**

(Source: University of Maryland Baltimore)

DENTAL TRIBUNE

The World's Dental Newspaper - US Edition

Publisher & Chairman

Torsten Oemus
t.oemus@dental-tribune.com

Chief Operating Officer

Eric Seid
e.seid@dental-tribune.com

Group Editor & Designer

Robin Goodman
r.goodman@dental-tribune.com

Editor in Chief Dental Tribune

Dr. David L. Hoexter
d.hoexter@dental-tribune.com

Managing Editor/Designer

Implant, Endo & Lab Tribunes
Sierra Rendon
s.rendon@dental-tribune.com

Managing Editor/Designer

Ortho Tribune & Show Dailies
Kristine Colker
k.colker@dental-tribune.com

Online Editor

Fred Michmershuizen
f.michmershuizen@dental-tribune.com

Product & Account Manager

Mark Eisen
m.eisen@dental-tribune.com

Marketing Manager

Anna Wlodarczyk
a.wlodarczyk@dental-tribune.com

Sales & Marketing Assistant

Lorrie Young
l.young@dental-tribune.com

C.E. Manager

Julia E. Wehkamp
j.wehkamp@dental-tribune.com

C.E. International Sales Manager

Christiane Ferret
c.ferret@dtstudyclub.com

Dental Tribune America, LLC
116 West 23rd Street, Suite 500
New York, NY 10011
Tel.: (212) 244-7181
Fax: (212) 244-7185

Published by Dental Tribune America
© 2011 Dental Tribune America, LLC
All rights reserved.

Dental Tribune strives to maintain the utmost accuracy in its news and clinical reports. If you find a factual error or content that requires clarification, please contact Group Editor Robin Goodman at r.goodman@dental-tribune.com.

Dental Tribune cannot assume responsibility for the validity of product claims or for typographical errors. The publisher also does not assume responsibility for product names or statements made by advertisers. Opinions expressed by authors are their own and may not reflect those of Dental Tribune America.

Editorial Board

Dr. Joel Berg
Dr. L. Stephen Buchanan
Dr. Arnaldo Castellucci
Dr. Gordon Christensen
Dr. Rella Christensen
Dr. William Dickerson
Hugh Doherty
Dr. James Doundoulakis
Dr. David Garber
Dr. Fay Goldstep
Dr. Howard Glazer
Dr. Harold Heymann
Dr. Karl Leinfelder
Dr. Roger Levin
Dr. Carl E. Misch
Dr. Dan Nathanson
Dr. Chester Redhead
Dr. Irwin Smigel
Dr. Jon Suzuki
Dr. Dennis Tartakow
Dr. Dan Ward

Tell us what you think!

Do you have general comments or criticism you would like to share? Is there a particular topic you would like to see more articles about? Let us know by e-mailing us at feedback@dental-tribune.com. If you would like to make any change to your subscription (name, address or to opt out) please send us an e-mail at database@dental-tribune.com and be sure to include which publication you are referring to. Also, please note that subscription changes can take up to 6 weeks to process.

www.dental-tribune.com

What's your specialty? Whichever area of dentistry you practice in, you will find articles of interest at www.dental-tribune.com:

Endodontics

The continuous wave of obturation technique for enhanced precision, by Dr. L. Stephen Buchanan

www.dental-tribune.com/articles/content/scope/specialities/section/endodontics/id/3236

Predictable apical microsurgery, by Dr. John J. Stropko

www.dental-tribune.com/articles/content/scope/specialities/region/usa/id/929

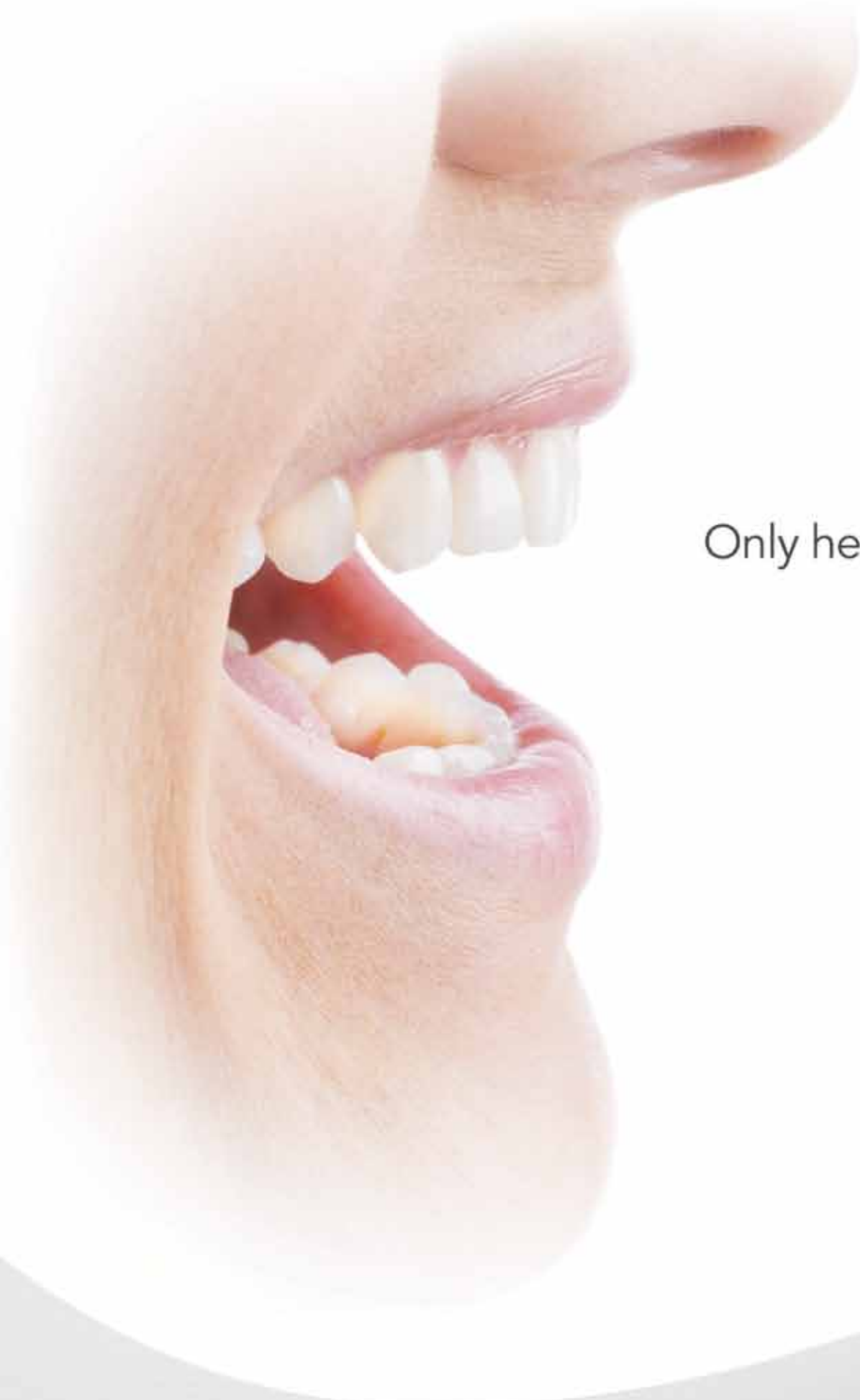Implantology

Implant fracture: A look at the physical mechanisms for failure, by Dr. Dov M. Almog, Dr. Odalys Hector, Dr. Samuel Melcer and Dr. Kenneth Cheng

www.dental-tribune.com/articles/content/scope/specialities/section/implantology/id/2975

CBCT and implants: a career-altering experience, by Dr. Steven A. Guttenberg

www.dental-tribune.com/articles/content/scope/specialities/section/implantology/id/2981



Only her dentist knows.

Restorations as real as the real thing.

Esthet•X® HD Restorative gives you the power to mimic nature. Our TruMatch® Shade Guide offers unmatched ability to predict and control the esthetic outcome of every restoration. And optimized handling and excellent polishability deliver life-like results for a beautiful smile that's as real as the real thing.

visit www.eshetxhd.com



ESTHET•X® HD
HIGH DEFINITION MICRO MATRIX RESTORATIVE

GET REAL.

Top 10 suggestions for 2011

By Sally McKenzie, CEO

The best thing about a new year is the host of new opportunities it offers. It presents the chance to create a new mindset and the occasion to renew your commitment to making the most of your career, your relationships, your strengths, your team and your practice.

There is no better time to ask yourself, what are you going to do to make 2011 a perfect 10? I have a few suggestions to making this your most successful year in dentistry yet.

No. 10: If you can see it, you can create it

It's called creating your vision and goals. In terms of the growth and success of your practice, as well as your own professional satisfaction, where do you want to be one year from today?

Share this with your entire staff and involve them directly in spelling out the plan to ensure that everyone is aiming for the same target, namely, total practice success. Over the coming weeks and months, you and your team should work through various aspects, including:

- improving communication skills and establishing dialogue,
- providing a non-threatening forum for the team to evaluate strengths and weaknesses,
- clearly defining jobs and responsibilities of every staff member,
- assessing individual roles in the group and understanding how each contributes to the practice's objectives,
- developing specific team processes, such as decision-making and conflict management,
- improving problem-solving strategies,
- creating a culture of accountability.

In addition, schedule a two-hour team meeting for every month this year to identify the vision, goals and the strategy for advancing practice success in the coming year.

No. 9: Take the broad goals and objectives and translate them into specific priorities that are individualized for each person

For example, define the priorities of the business team. Spell out how each person's responsibilities and objectives help to achieve those priorities and how they fit into the larger practice goals.

No. 8: Open the lines of communication wide

Feedback, celebrating progress, group problem solving and troubleshooting all involve ongoing constructive communication.

Yet, it is more than keeping everyone informed. A culture of accountability is built on a culture of open communication in which the cornerstone is a culture of respect and

trust. Encourage staff to offer ongoing constructive suggestions, input and insights aimed at moving the practice forward.

No. 7: Set the example for your team

Pay close attention to your daily actions, behaviors and decisions to ensure they are consistent with practice values and priorities.

Do not expect your team to follow you if you are not willing to live by the same principles and uphold the same standards that you require of others.

No. 6: Cut the deadwood and enjoy smooth sailing

Deal with the problem performers on your team. These are the people that you and your star performers have been carrying for far too long and at far too great an expense.

There are few things more demoralizing to top-flight employees than a boss who looks the other way when one or more members of the team consistently disregard office policies, bring poor attitudes to work, generate conflict, make excuse after excuse for why they were late, why they were sick and why they simply cannot get their jobs done.

Yet, the deadwood workers that everyone is stepping over and is forced to just "deal with" get the same pay raises, same vacation time and the same perks as top performers on your team. Understandably, your capable staff will only tolerate this for so long.

As Vince Lombardi once said, "There is nothing more unequal than the equal treatment of unequals." You want a team of people eager to help you and your practice reach the pinnacle this year, not derail your efforts.

Next, take a close look at practice numbers, starting with establishing a realistic financial goal for your practice.

Let's say you want to achieve \$700,000 in clinical production. This calculates to \$14,583 per week (taking four weeks out for vacation).

Working 40 hours per week means you'll need to produce about \$364 per hour. If you want to work fewer hours, obviously per hour production will need to be higher. Follow the steps below to get there.

No. 5: Create a clear plan of action for production

Establish daily production goals and schedule to meet those goals. Make certain that your scheduling coordinator fully understands exactly how much time is needed for each procedure.

You would be stunned how many business employees simply have to guess the number of units that should be allocated for procedures.

Prescribe a treatment plan for patients that includes everything

that needs to be done: appointments necessary, the cost of treatment, an estimated length of treatment time and any treatment options.

Designate a treatment coordinator who is responsible for presenting treatment plans to patients and is expected to secure at least 85 percent case acceptance.

- Implement an interceptive periodontal therapy program.

- Provide superior customer service that will encourage patients to refer friends and family.

- Each month run the year-to-date practice analysis report and compare it to the same period last year.

Now consider what needs to happen in the treatment room, which brings us to tip No. 4.

No. 4: The patient needs what the patient needs, regardless of his/her circumstances

Continue to diagnose patients' needs and wants according to your practice philosophy, not on what you perceive they can afford. Present treatment plans that convey to patients that you are presenting options to address immediate needs, long-term needs and patient desires.

In addition to recommending treatment according to both patient needs and wants, continue to educate patients. Emphasizing the importance of oral health and its impact on overall health has never been more important.

No. 3: Monitor and measure the individual areas as a team and study practice reports

Regularly review key reports including the accounts receivables and outstanding insurance claims reports to monitor exactly how much money is owed to your practice.

In addition, watch the details of your production, new patient flow and patient retention using the production report. Depending on your software system, this report may be called production by provider, practice analysis or production by ADA Code. It is very useful for tracking new patient comprehensive exams.

The production by provider report should also enable you to monitor individual provider production for each dentist and hygienist. It is important to track individual production numbers to determine productivity.

Some systems will allow you to run a production forecast report that can be an excellent tool in determining slow periods so that you can develop a plan of action to address the potential production shortfalls.

In monitoring each area and discussing the results, staff better comprehend the impact of one system on another and on the success of the practice as a whole. They are then far less likely to sit back and watch problems continue, further strength-

If you want to work fewer hours, your per hour production will need to be higher.

ening the culture of accountability and minimizing the "it's not my job" mentality.

No. 2: Watch overhead carefully

The industry standard for overhead is 55 percent of collections. If you are currently at 60 to 65 percent, you are comfortably within reach. If yours is higher, take action.

Some practices report their overhead as high as 85 percent. They are making a mere 15 cents on the dollar! The first step in controlling overhead is to establish the following budget targets:

- *Dental supplies:* 5 percent
- *Office supplies:* 2 percent
- *Rent:* 5 percent
- *Laboratory:* 10 percent
- *Payroll:* 20 percent
- *Payroll taxes/benefits:* 5 percent
- *Miscellaneous:* more than 10 percent

No. 1: Make this your best year yet

Invest in your success. Consider working with a management consultant. I know of at least one consulting firm that has enabled practices to realize significant financial return throughout the recession, including major gains in collections, case acceptance, perio production and patient retention.

Do your homework and pick the one with a proven track record. ■

About the author



Sally McKenzie is CEO of McKenzie Management, which provides success-proven management solutions to dental practitioners nationwide. She is also editor of The Dentist's Network Newsletter at www.the dentists network.net; the e-Management Newsletter from www.mckenzie mgmt.com; and The New Dentist™ magazine, www.thenew dentist.net. She can be reached at (877) 777-6151 or sallymck@mckenziemgmt.com.

The dental microscope for general dentistry

By Craig S. Kohler, DDS, MBA, MAGD

The dental microscope is an outstanding tool. Every general dentist should consider incorporating the ability to have multiple magnifications in his or her office. The following case studies illustrate their effectiveness.

I use the microscope every time I touch a tooth with a burr. The photos shown here are snapshots of procedures that have been videotaped.

The videos have been edited and can be found on www.YouTube.com under the case name. Go to www.YouTube.com and search for "craigs kohler" and the name of the case.

Case No. 1: Removal of amalgam stain and micro crack discovery

Summary of original treatment expectations: Patient needs a simple two-surface silver amalgam filling, #3 MO replaced. The patient would like to have a tooth-colored restoration.

The silver amalgam is removed and carious tooth structure is found as well as extensive staining from the old silver filling (Fig. 1a). An intra-oral sandblaster (Danville Engineering MicroEtcher IIA) was used to remove the stain and decay.

The stain at the gingival margin was more difficult to remove and a second application of the sandblaster removed it (Fig. 1b). Upon close inspection of the preparation, there was a small crack found in the enamel at the gingival margin and another crack under the mesial buccal cusp (Figs. 1c, 1d).

The dentist can evaluate and discuss the options that the patient has regarding the restoration of the tooth. If the patient can see the situation, he or she can make a more informed decision.

Possible future problems can be traced back to the original stress fractures in the tooth if the patient elects to have a simple filling placed.

This patient decided to have the simple filling and was willing to risk possible tooth fracture and sensitivity. In my office, a full crown is considered over treatment, but a conservative ceramic onlay with proper occlusal guidance may be the best enduring restoration (Figs. 1e, 1f).

A gold onlay has the clinical history to last the longest, but it would not satisfy the esthetic demands of most patients' in my demographic area.

Case No. 2: Removal of an old tooth colored filling that had severe decay

Summary of original treatment expectations: A 14-year-old female with a history of bad dental experiences at her pediatric dentist has decay on her lower right molar (#30).

The tooth has a silver amalgam

with decalcification on the margins, and there is a large occlusal composite that appears intact visually. She is apprehensive about treatment (Fig. 2a).

The silver filling is removed and there is extensive decay (Fig. 2b). The tooth-colored composite is difficult to distinguish from dentin. The dental microscope enlarges the area so that

all of the old composite and decay can be removed.

As more dentists are using composite that blends with the dentin, the removal of the entire old filling is getting more difficult to discern. In this case, there was decay behind most of the composite filling. A sandblaster and a slow-speed round burr removed the composite. Decay detector identi-

fied the active caries and illustrated to the patient and her mother the seriousness of the situation (Fig. 2c).

The final filling was a temporary measure and the patient can expect endodontic therapy someday in her future (Fig. 2d).

The necessity of vigilant recalls is

→ [DT](#) page 6A

AD

FINALLY, AN INJECTABLE HYBRID RESTORATIVE FOR ALL INDICATIONS

BEAUTIFIL Flow Plus

- Indicated in classes I, II, III, IV & V
- Physical properties rival hybrids
- Stackable & sculptable; stays put
- Self-polishing "leveling-effect"
- High radiopacity, beyond enamel

BEAUTIFIL Flow Plus is the next step in the evolution of restorative materials, combining the delivery of a flowable and the strength, durability, and aesthetics equal to or better than leading hybrid composites.

Visit www.shofu.com or call 800.827.4638

SHOFU

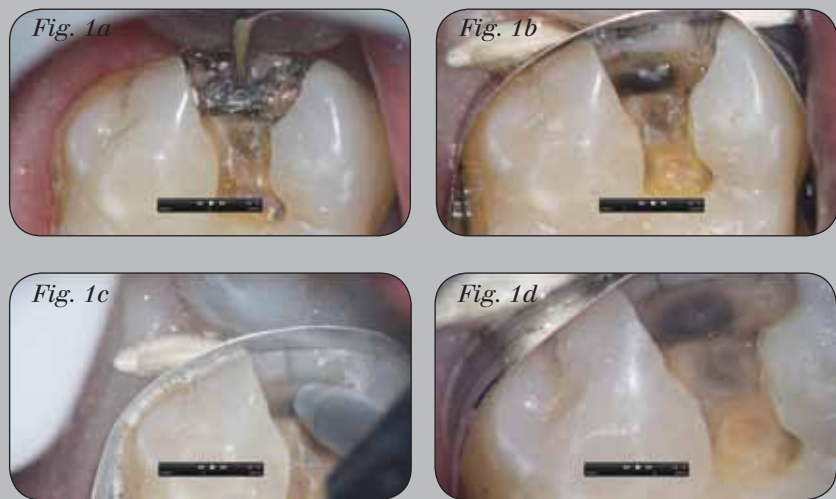
**TRIAL OFFER \$99.95
A \$160.00 VALUE!**
Order now www.shofu.com
Enter code: DTRFP2-11

F00 Zero Flow
Stackable

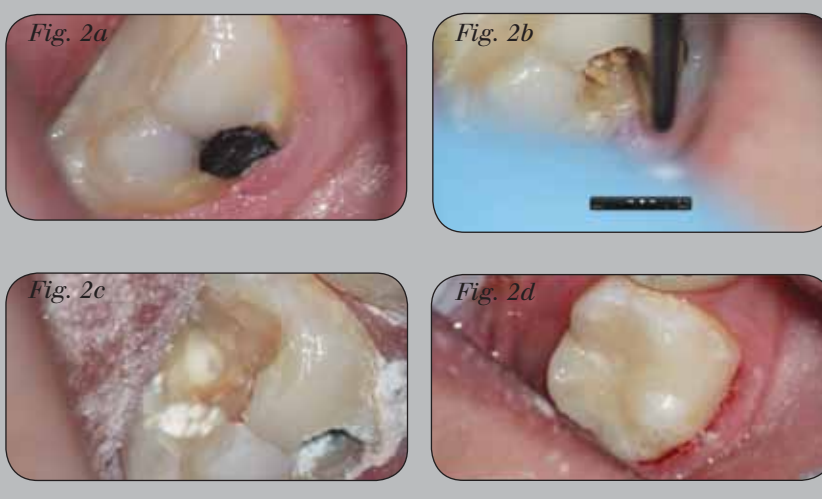F03 Low Flow
Self-leveling

Shofu Dental Corporation • San Marcos, CA

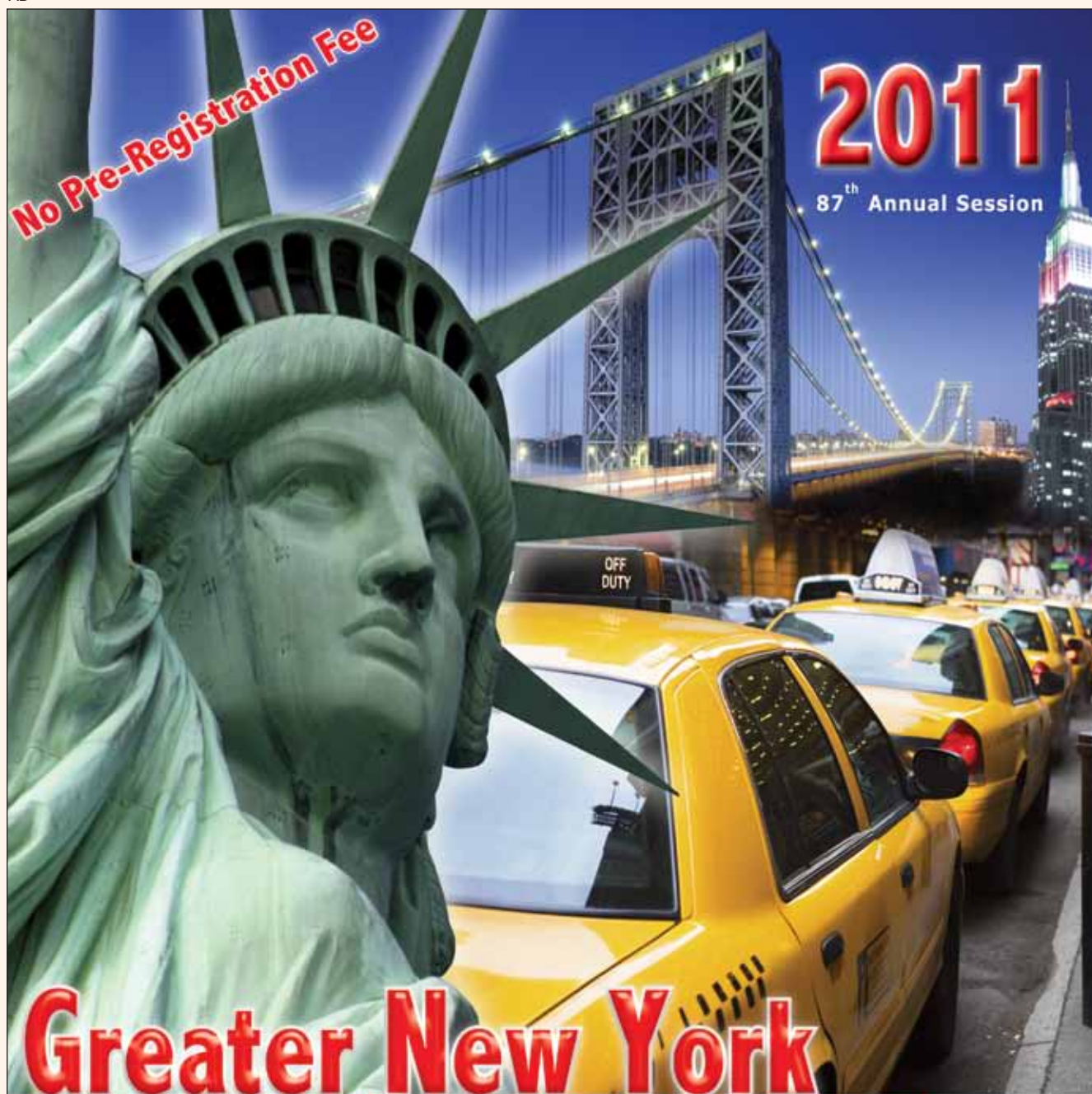
Case No. 1: Removal of amalgam stain and micro crack discovery



Case No. 2: Removal of an old tooth-colored filling that had severe decay



AD



Scientific Meeting:
Friday, November 25 -
Wednesday, November 30



Exhibits:
Sunday, November 27 -
Wednesday, November 30

The Largest Dental Meeting/Exhibition/Congress in the United States

← DT page 5A

understood and the patient returns to the office for three other similar problems on her other first molars. This case is an example of a patient who was a difficult management problem; however, she learned to appreciate the value of a dentist and patient working together to get a good result.

The dental microscope enlarged the field of view for treatment and documented the experience so the patient could take ownership of her dental problems.

Case No. 3: Crown buildup and preparation for a gold crown

Summary of original treatment expectations: The upper left molar, #15, had the palatal margin of a gold onlay breakdown (Fig. 3a). There was extensive decay. The onlay was removed and a core buildup placed. Then the tooth was prepared for a future gold crown, which was seated.

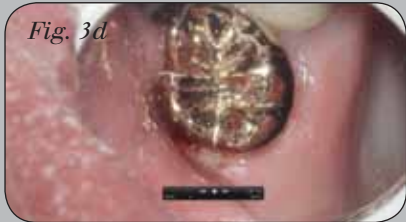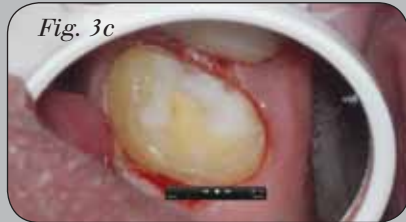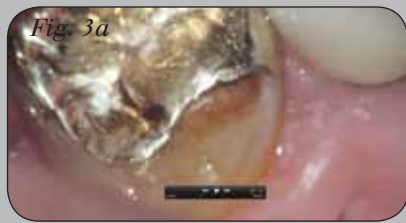The extensive decay under a filling led to the need for a core build up. The dental microscope was used to refine the margins of the preparations. Notice the magnification (10x to 12x) that allowed the buildup tooth margin to be refined. The white buildup material could clearly be seen, which allowed the margin of the buildup to be placed above the crown margin (Fig. 3b).

The preparation was also adjusted at similar high magnification and two slots were placed in the buildup to increase retention for the crown. The impression was sent to the dental laboratory, Opus One Laboratories in Agoura Hills, Calif.

At the delivery appointment, the temporary was removed and the residual temporary cement was sandblasted away. The crown was checked for fit and occlusion and was cemented with Relyx Unicem cement by 3M ESPE. The delivery appointment took about 15 to 20 minutes.

In my office, a tooth that needs an extensive buildup typically takes 30 minutes. The preparation and impression appointment time is 45 to 60 minutes. My initial learning curve took about two months to feel comfortable in using the microscope for most dental procedures.

Case No. 3: Crown buildup and preparation for a gold crown



Case No. 4: #31, severely cracked tooth with no pain

Summary of problem: A patient had an ordinary Class I filling on the lower right second molar, #31. There was a stress fracture line on the distal marginal ridge, and there was no pain. The initial filling can be seen on *www.YouTube.com* under the title for this case.

Upon removal of the silver amalgam, there was a stress fracture that could be seen under high magnification, 10x to 12x (Fig. 4). This fracture line originated on the distal marginal ridge, but continued on the floor of the dentin until 1/3 of the tooth was involved.

The patient understood the need to restore the tooth with a crown. There was a discussion about other occlusal issues that may have led to the cre-

ation of the crack in the first place.

The patient understood the possibility of tooth loss or need for endodontic therapy even with a crown. He was fully informed and understood that the crack could get worse with a simple filling, which could lead to tooth loss.

A final word

The dental microscope was introduced to dentistry in the late 1970s.

The cost, ergonomics and the perception of a steep learning curve has kept this useful tool from being implemented by the general dentist.

The four simple cases presented here illustrate how using multiple magnifications allows the general dentist to exceed his or her ability to see beyond one's eyesight or loop magnification. **■**

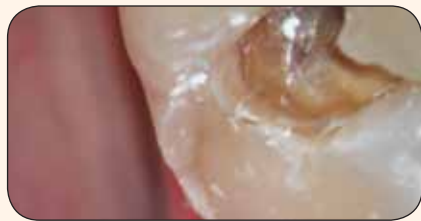

Fig. 4: Case No. 4, #31, severely cracked tooth with no pain.

(All photos were provided by Dr. Kohler)

About the author

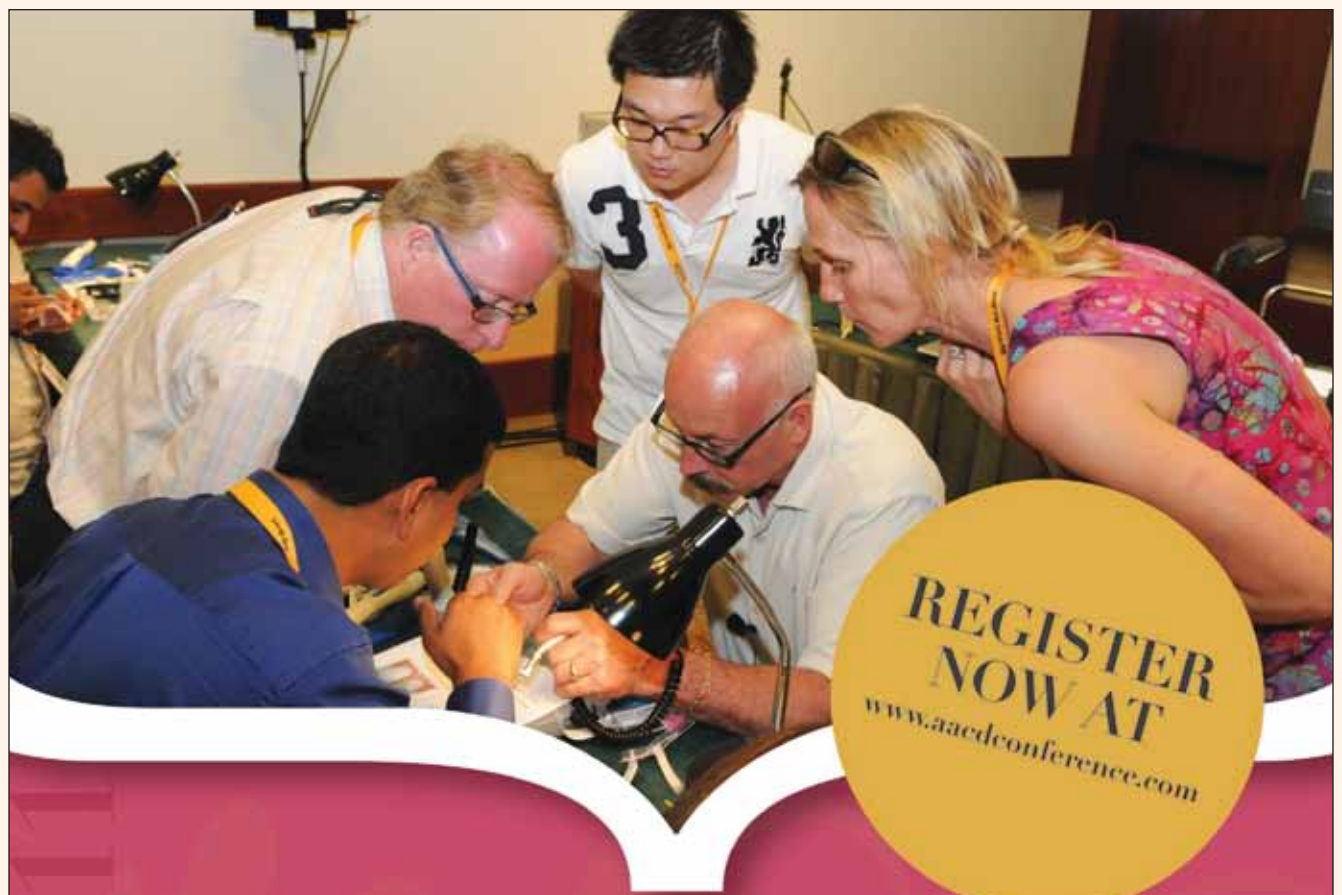Craig S. Kohler, D D S , M B A , M A G D , has a full-time private practice in Wilmette, Ill., which is a suburb of Chicago. He has used surgical dental microscopes for 15 years.



He owns a five-stage Seiler Instrument & Manufacturing Company, a dental surgical microscope and a motorized zoom OPMI PROergo manufactured by Carl Zeiss Meditec.

He has been an instructor at NorthShore University Health-care System General Hospital Residency program for 10 years, where he has taught dentists how to use the dental surgical microscope. In addition, Kohler has been a visiting faculty member for the Spear Institute in Scottsdale, Ariz., where he mentors dentists in occlusion and cosmetic dentistry with the aid of dental surgical microscopes.

Kohler will be teaching a one-day hands-on microscope course April 8 and 9 in Kansas City. Please contact him at craigskohler@comcast.net for more information.



REGISTER NOW AT www.aacdconference.com

Discovering the latest techniques and materials
TAKES COLLABORATION

Find it at the 27th Annual AACD Scientific Session, May 18-21, 2011

The RISE of COLLABORATION: Feel it!



Giuseppe Allais, DDS



Stephen Chu, DMD



Newton Fahl, Jr., DDS



Willi Geller, MDT



Harald Heymann, DDS, MEd



Frank Spear, DDS, MSD



Dennis Tarnow, DDS



Dennis Wells, DDS

*Educators are subject to change. View the complete program online.



AD

Diagnose this: red soft-tissue lesions

By Monica Malhotra, India

A 25-year-old male patient consulted in the department of oral pathology for the treatment of the tongue and lower lip swelling that has lasted for 20 years, and lead to difficulty in oral

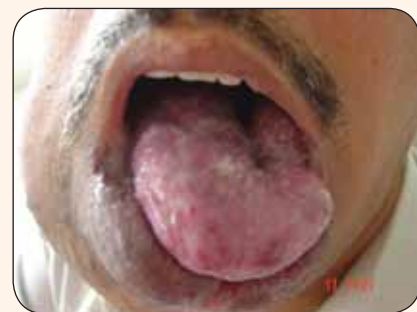function.

The patient gave a history of temporary regression of the lesion following prolonged bleeding due to trauma from the teeth.

Movement of the tongue provoked pain in the swelling region.

Enlargement was diffuse, fleshy and erythematous in appearance with foci of ulceration, involving almost two-thirds of the tongue anteriorly with a deviation toward the left side.

Similar swelling involved the lip on the right side.



(Photo/Provided by Dr. Madhumi Kumra, Department of Oral Pathology, Sudha Rustagi Dental College, Faridabad, India)

AD

The 2011 pacific northwest dental conference invites you to

PLUG IN!

Educate yourself: it's the best way to top the competition

new this year:

Live Demonstrations
During this year, live demonstrations in the Exhibit Hall will showcase the latest advances in digital impression software by (Iris, Lava 3D, T40 and CEREC, used to acquire digital impressions needed for CAD/CAM fabrication of restorations). Come and learn how restorations created digitally can benefit your practice, patient satisfaction and profitability.
This will provide a unique opportunity to compare the systems and learn from expert clinicians while they perform the procedures. This will be an interactive format and attendees are encouraged to ask questions.

Table Clinics
Six stage graduate residents in the Advanced Education in General Dentistry program at Joint Base Lewis-McChord (JBLM), will present table clinics inside the Exhibit Hall. These clinics, or popular way to learn from peers, will debut this year in the Exhibit Hall. Subjects will include caries detection, irrigation, whitening, and more.

Expanded Tracks
Choosing interesting, dynamic tracks for your team members is important to all. We make it easy for them by featuring sessions best suited to their position — and we make it easy for you to attract the lecturers and workshops you think they should attend.

register online • wsda.org/pndc

It's fast, easy & secure. Save money when you register before April 15
Early Bird Full Conference Badge Fees: ADA Member Dentists: \$165/\$205 • Staff: \$115
Canadian/Foreign Dentists: \$205 • Non-ADA Member Dentists: \$1,850
Members buying full conference badges have their choice of more than 50 reviews at no additional cost!

speakers

Dr. Joseph Albert
Ms. Jenny Allen
Dr. Tobin Bellamy
Dr. Charles Blair
Ms. Vivi Bakbot
Dr. Lisa Ann Brady
Dr. Bobby Butler
Dr. Steve Carstensen
Dr. David Chan
Mr. Art Cole
Mr. David Cook &
Dr. Daniel Cook
Dr. Bruce Cooper
Dr. Gabriel Dan Singh
Dr. Mark Donaldson &
Dr. Jason H. Goodchild
Ms. Melissa Dyches
Dr. Albert Gearing
Dr. Robert Gottlieb
Mr. Scott M. Henderson
Ms. Niki Henson

Shrey Armon
Ergonomics
Oral Surgery
Coding, Productivity
Implants
Esthetics
Implants
Sleep/Breath
Esthetics/Composites
Basic life Support, First Aid
Practice Sales

Digital Impressions
Restorative
Pharmacology

Dentist
Practice Management
Residentia Therapy
Prosthodonty
Temporaries, Impressions,
Infection Control, Inventory
Control
Inkjet Restoration
Adolescent Oral Health
Dental Assisting (Aligner
Impressions)
Passionate the
Implant Dentistry
Pediatric Behavior
Management
Kosmetology
Esthetics Treatment Planning
Composites
Radiography
Periodontics
Social Media
Asset Protection
Team Motivation
Communication
Insurance, Communication
Health, Ergonomics
Oral Systemic Connection
NSCA, Women's Health
Healthy/Fitness
Sports Dentistry
Crown Lengthening
Implants
Lasers/ Dental Hygiene/
Periodontics
Esthetics, Occlusion
Communication
Implants
Oral Pathology & Medicine,
Oral & Maxillofacial
Pathology, Oral Disease
Management
Emotional Intelligence
Implant Restoration
Periodontics/ Dental
Hygiene, Diabetes Screening
Team Motivation
Endodontics

Dr. Timothy Hess
Dr. Sally Hewett

Ms. Cicci Homer
Dr. Joe Hong
Dr. Ronald Hsu

Ms. Mary Johnson
Dr. Gregory Kinzer
Dr. Doug Lambert
Liberman, Houser, Johnson
Dr. Samuel Low
Ms. Barbi Jacobucci
Mr. G. Kent Mangelsen
Ms. Judy Kay Mastoff

Ms. Joy Mills
Ms. Jill Moore
Dr. Uche Odiafu
Ms. Kary Odiafu
Dr. Uche Odiafu
Dr. Ray Padilla
Perio Institute
Dr. Allison Pinyera
Ms. Janet Press

Dr. Steve Ratcliff
Ms. Sandy Roth
Dr. Husin "Todd" Su
Dr. John Svirsky

Ms. Shari Tostad
Dr. Chandur Wadhwan
Ms. Pamela Wood

Dr. Grace Wu

PNDC
pacific northwest
dental conference
june 16 & 17 - seattle, washington

WSDA PNDC
WASHINGTON STATE PACIFIC NORTHWEST
DENTAL ASSOCIATION DENTAL CONFERENCE

The Pacific Northwest Dental Conference is sponsored
by the Washington State Dental Association.
Earn up to 14 CDE credits over two days!
Call for more: 800-448-3368

ADA CERP

1) What is your diagnosis?

- Lymphangioma
- Hereditary macroglossia
- Hemangioma
- Amyloidosis
- Squamous cell carcinoma

Part I

Let's go step by step from the patient's detail and assemble all the clues together.

Clue No. 1: Age, site and duration: 25-year old, tongue (majorly right side) and lower lip swelling for approximately the last 20 years, leading to difficulty in the functions associated.

Conclusion: Doesn't appear to be squamous cell carcinoma as it started at around 2 to 5 years of age.

Clue No. 2: History — Patient gave a history of temporary regression of the lesion following prolonged bleeding due to trauma from the teeth. Movement of the tongue provoked pain in the swelling region.

As such, it's a swelling that bleeds easily and shows a fluctuating growth pattern.

Conclusion: Apparently a soft and vascular lesion with phases of regression with bleeding. This again rules out squamous cell carcinoma, hereditary macroglossia and amyloidosis because these are supposedly firm lesions.

(Note: These can also have superficial ulcerations and supra-infections to look erythematous with ulcerations.)

Clue No. 3: Appearance — Enlargement was diffuse, fleshy and erythematous in appearance with foci of ulceration, involving almost two-thirds of the tongue anteriorly with a deviation toward left side. Similar swelling involved the lip.

Conclusion: This can help us rule out hereditary macroglossia; the reason being it's a muscular hypertrophy, most often bilateral, doesn't show fluctuations and generally not erythematous and doesn't bleed often

until traumatized.

Narrowing down the diagnosis

- Lymphangioma
- Hemangioma
- Amyloidosis

Ruling out amyloidosis

The tongue generally becomes smooth or may possess a variety of polypoid appendages that form as the tongue grows against gaps in the teeth.

In addition to its large size, the tongue becomes adynamic, firm and friable and may cause problems with deglutition, speech and breathing. The tongue tissue may break down and haemorrhage due to the size. There are two types of amyloidosis:

- Organ-limited amyloidosis rarely shows up in oral soft tissues.
- Systemic amyloidosis show various other systemic signs and symptoms.

Thus, complete systemic examination and probably a biopsy is required before making a diagnosis of amyloidosis.

Ruling out lymphangioma

When seen in the denser tissue such as the tongue, lymphangioma is confined and histologically it presents as a microcystic lesion unlike a macrocystic lesion in the looser tissues.

The tongue presents superficially as “pebbly” with a vesicle-like feature and a so-called “frog-egg” or “tapioca-pudding” appearance. If located deeper, lymphangioma may present as a submucosal mass.

About 50 percent of the lesions are noted at birth and around 90 percent develop by 2 years of age.

Other causes of macroglossia:

- Cretinism
- Downs Syndrome
- Mucopolysaccharidoses
- Neurofibromatosis
- Edentulous patients
- Myxedema
- Acromegaly
- Angioedema
- Carcinoma and other tumors

Part II: Hemangiomas

2) Check your knowledge of hemangiomas by marking true or false next to each of the following.

a) A hemangioma is a benign, self-involving tumor of endothelial cells (the cells that line blood vessels) leading to an abnormal proliferation of blood vessels that may occur in any vascularized tissue.

b) Hemangiomas are one of the most common birthmarks in newborns.

c) The appearance depends on location. Superficials appear reddish; however, if they are just under the skin they present as a bluish swelling.

d) Some are formed during gestation while others (the most common) are not present at birth but appear during the first few weeks of life.

e) Histologically, subclassified as capillary or cavernous depending on the size of the vascular channels.

f) Show giant cell inflammatory reaction.

The development cycle of heman-

giomas includes three stages of development and decay.

- In the proliferation stage, a hemangioma grows very quickly. This stage can last up to 12 months.

- In the rest stage, there is very little change in a hemangioma's appearance. This usually lasts until the infant is 1 to 2 years old.

- In the involution phase, a hemangioma finally begins to diminish in size. Fifty percent of lesions will have disappeared by 5 years of age and the vast majority will have disappeared by 10 years of age.

3) Which of the following complications can a hemangioma show?

- Bleeding
- Breathing and eating difficulties
- Secondary infections
- Vision problems

e) All of the above

4) Which of the following is a recommended form of treatment?

a) Generally regresses on its own, especially the superficial one; so no treatment required.

b) In some cases, a surgical treatment or lasers may be used to remove the small vessels.

c) Cavernous hemangiomas are generally treated with steroid injections or laser treatments or combination treatment.

d) All of the above are correct.

(Answers are below.)

- 1) c (hemangioma)
 2) a = true, b = true, c = true,
 d = true, e = true, f = false
 3) e (all of the above)
 4) d (all of the above)

About the author



Dr. Monica Malhotra is an assistant professor at the Sudha Rustagi Dental College in India and also maintains a private practice.

In 2008 she was presented with a national award for the best scientific study presentation by the Indian Association of Oral and Maxillofacial Pathology.

Malhotra completed her master's in oral pathology at the Manipal Institute, India, in 2009. You may contact her at drmonicamalhotra@yahoo.com.

AD

EMS-SWISSQUALITY.COM

EMS
ELECTRO MEDICAL SYSTEMS

THE NEW PIEZON

PIEZON MASTER 700 - THE ORIGINAL PIEZON METHOD IN THE LEAD WITH INTELLIGENT i.PIEZON TECHNOLOGY

NO PAIN for the patient – what the inventor of the Original Piezon Method had in mind when he developed the new Piezon Master 700.

The result is a treatment which irritates neither teeth nor gingiva – and which delivers extra smooth tooth surfaces without abrading the oral epithelium.

It is a symbiosis of intelligent technology and unequalled precision. A perfect match between the Original Piezon LED handpieces and the i.Piezon module for instrument movements perfectly aligned with the tooth. An incomparable fit when used with EMS Swiss Instruments made of ultrafine biocompatible surgical steel.

With its modern touch panel, the new Piezon Master 700 sets new standards for ease of operation and hygiene. Everyone benefits, all feel good – patient, practitioner, the whole practice.

For more information > welcome@ems-ih.com

PIEZON[®]
NO PAIN

> A new brochure – everything about the Original Piezon Method and the new Piezon Master 700

"I FEEL GOOD"