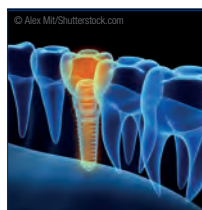

# today

TO  
11  
12

EAO 27<sup>th</sup> Annual Scientific Meeting Vienna • 11-13 October 2018



## Business

The EAO Junior Committee has established guidelines to improve the development of implant dentistry in the next ten years.

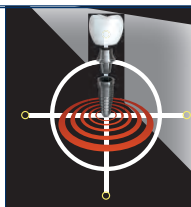
» page 2



## Interview

Dr Francisco Teixeira Barbosa gives insight into resonance frequency analysis and how digital dentistry is influencing implantology.

» page 6



## Dental products in focus

The 2018 EAO congress offers an opportunity to see and try out the most current innovations in implant dentistry.

» page 14

## Possibilities and boundaries of implantology to be discussed at EAO 2018

■ For the next three days, dental professionals have the opportunity to enhance their scientific knowledge and to share clinical experiences at the 27<sup>th</sup> annual congress of the European Association for Osseointegration (EAO). From 11 to 13 October, attendees are welcome to immerse themselves in the rich programme of the scientific meeting that is set to take place at the Messe Wien Exhibition Congress Centre in the Austrian capital.

The programme covers various stages of dental treatment and is presented under the motto “Dreams and reality in implant dentistry”. It aims to explore the clinical possibilities and boundaries of implantology, emerging techniques and patient expectations. Each of the three days of the congress is focused on a specific topic: the first, on diagnostics, the second, on surgical treatments and the final day, on prosthetics. Furthermore, the programme features 70 renowned speakers from all over the world, hands-on workshops and surgical video sessions. For the first time, the EAO will introduce live surgery sessions that will



be directly broadcast into the main auditorium.

The EAO congress provides a forum for dentists to share the latest scientific advances, to meet old friends and make new ones, and to build connections all over the world. At this year's congress, Russia and the Baltic countries will be hosted as the guest region. With that, a “Russia and Baltic countries corner” is showcased in the exhibition area. In addition, cultural events will be organised to encourage exchange and networking between attendees from different countries. While the majority of pres-

entations are held in English, the Austrian society sessions will be translated into English and the plenary sessions into Russian.

Attendees can furthermore seize the opportunity to learn about the newest innovations at the accompanying industry trade exhibition, where 120 companies will present their products, among them Nobel Biocare, Straumann and Dentsply Sirona. Aside from the main programme, EAO visitors can learn about the most recent clinical solutions in more detail at ten industry symposia.

Founded in 1991 in Munich, the EAO has become one of the leading associations within the art and science of osteointegration. The EAO was created as an international and independent exchange forum for all dentists interested in the science of implant dentistry. The very first congress was held in Leuven in Belgium in 1992.

The congress website, as well as the EAO 2018 congress app (see additional information on the last page of the *EAO today*) offer information

about the scientific meeting and programme. Current news, interviews, photo galleries and an e-paper version of this *today* will be available at [www.dental-tribune.com](http://www.dental-tribune.com) or on the Dental Tribune International Facebook page. ◀

AD



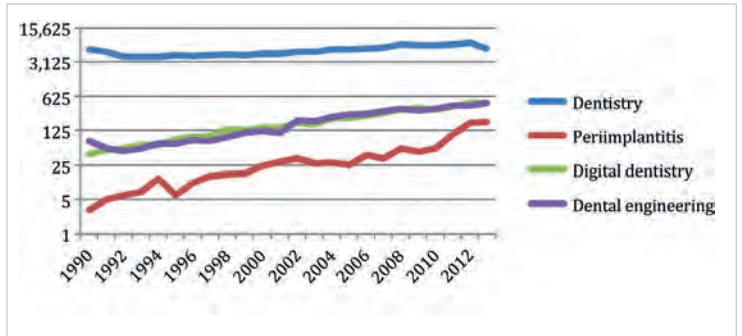
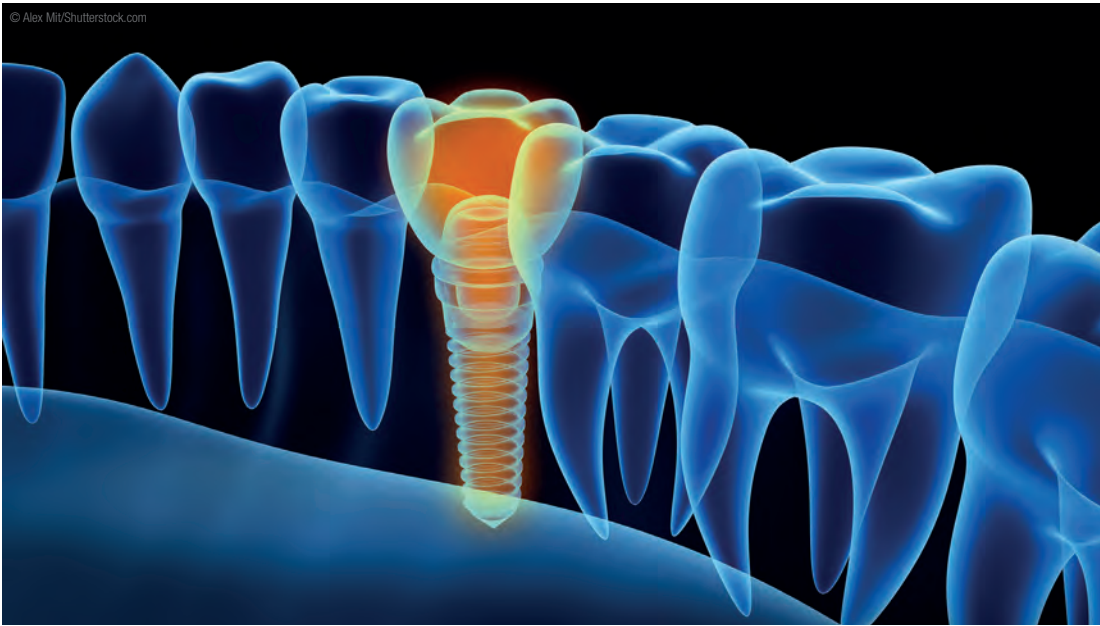
## Dental Tribune International ESSENTIAL DENTAL MEDIA

[www.dental-tribune.com](http://www.dental-tribune.com)

dti Dental Tribune International



# EAO Junior Committee presents guidelines for development of implant dentistry in the next decade



▲ Bibliometric analysis of the scientific literature published from 1990 to 2013 concerning the number of publications on periimplantitis, digital dentistry and dental engineering. Upper line is the reference with the total number of scientific publications in dentistry.

▲ The EAO Junior Committee has established guidelines to improve the development of implantology in the coming years.

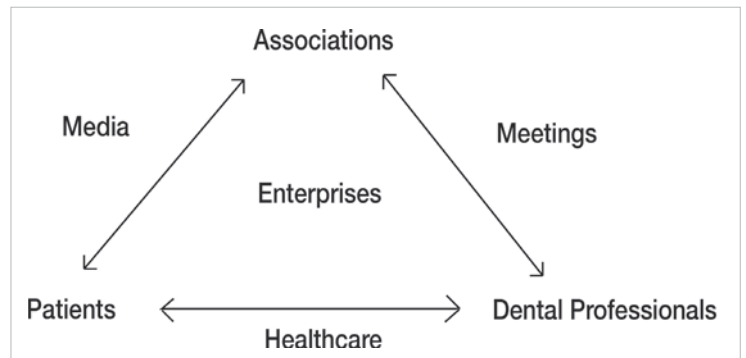
■ The third summer camp of the Junior Committee of the European Association for Osseointegration (JC EAO) brought together 40 scientists and clinicians in the field of dental implantology. The aim of the meeting

was to discuss four major topics concerning the development of the discipline: certification, societies and associations, continuing education and innovation. Four working groups outlined the present state and problems

of the respective area with the objective of recommending solutions to be implemented in the following ten years.

Since the evolution of new dental treatment techniques and modalities has led to the development of various dental specialties, recognition and certification of dental specialties are important in order to ensure educational standards and clinical skills. Therefore, the JC EAO has proposed the establishment of a certification programme for implant dentistry and the accreditation of training programmes. These regulations would lead to an improved quality of care, benefiting patients.

Concerning dental associations and societies, the JC EAO has suggested improvements in communication with dental students, professionals and patients. The guidelines furthermore involve the development of a positive partnership between dental associations and enterprises to ensure transparent communication,



▲ Diagram of communication links in a dental field between associations, dental professionals, patients and enterprises. Arrows indicate the preferred channels (media, meetings, healthcare system) of communication. Enterprises are a channel connected to all aspects of communication.

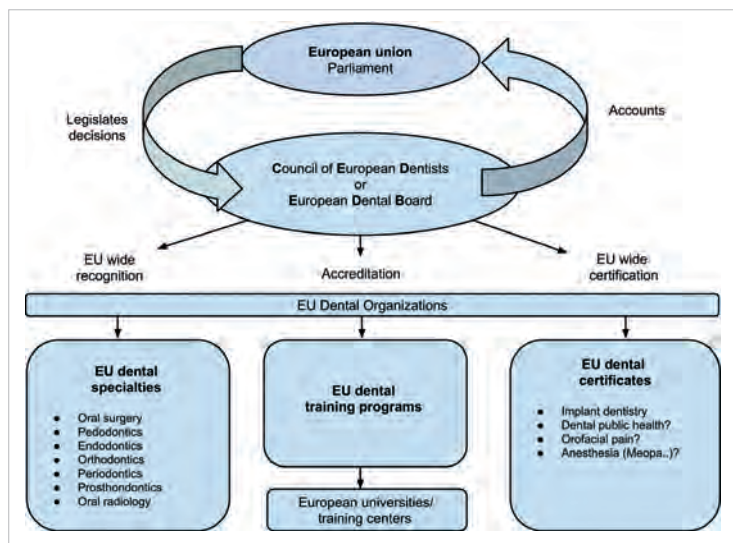
and increased support of independent research, the promotion of oral health and standard of care.

In order to ensure continuing dental education, a European dental board should be established and assume responsibility for supervision of continuing dental education, as well as continuing professional development. The board would establish a continuing dental education quality assessment, while junior committees of various societies could contribute to the process of annual consensus on new treatment techniques and relevant scientific outcomes.

The JC EAO found that dental professionals currently have limited

tools for dental procedures and these do not guarantee predictable results. Therefore, future innovations should focus on less-invasive techniques that make use of improved biomaterials and medications with local effects. The role of digital dentistry will be strengthened in the future, according to the committee, because increased efficiency in diagnosis and treatment will help to lower the costs of the healthcare sector.

The full recommendations, titled "Guidelines for development of implant dentistry in the next 10 years regarding innovation, education, certification, and associations", were published in the June 2018 issue of *Clinical Oral Implants Research*. ◀



▲ A model for management of work on creating certification regulations in dentistry.

## Why the rush?

Dr Scott D. Ganz

■ It's difficult to watch certain television commercials, read a newspaper, see an online advertisement, a webinar, social media content or a recorded video without hearing about "teeth in an hour", "teeth in a day", "teeth tomorrow", "immediate loading", "immediate restoration", or some variant. Patients are continually being told that they may be candidates for an "immediate" solution to their lifelong problems by having all of their "bad" teeth removed and replaced with an implant-supported restoration in one day, two days or a week. So, what is the rush? Are these concepts driven by science or strategic marketing by dental implant manufacturers, large group dental practices or individual practitioners, or due to patient demand?

Patients who have failing dentition generally have been in this condition for a long time. Certainly, there

are individual tooth failures that occur owing to various circumstances, but when it involves a complete maxillary or mandibular arch, or both, the process of bone loss, tooth mobility, abscess formation or soft-tissue inflammation must have been chronic. Are we clinicians to expect that we can solve all of these problems with advanced technologies that will deliver the magic wand of instant rehabilitation?

For the past several decades, the scientific literature has supported immediate treatment protocols that can deliver single-tooth to full-arch reconstructions with accuracy, consistency and predictability. Therefore, clinicians may want to deliver high-quality care to patients and significantly shorten the treatment time involved in dental implant procedures, but should these immediate implant-supported procedures be considered for every pa-

tient without consideration of conventional dental solutions such as root canal therapy, apicectomy, crown lengthening, or crown and bridge alternatives? Does the new digital workflow provide clinicians and dental laboratory technicians with improved tools to facilitate these accelerated treatment modalities? Is the rush justified?

Of course, these questions may relate mostly to an individual clinician's training and education in diagnosis,

treatment planning, and surgical and restorative skill set. Perhaps education is the key, and today there are many opportunities to gain the skills necessary to make decisions for each patient, to determine whether immediate or delayed implant protocols are warranted. ◀

*Editorial note: This article was originally published in CAD/CAM—international magazine of digital dentistry 3/18.*

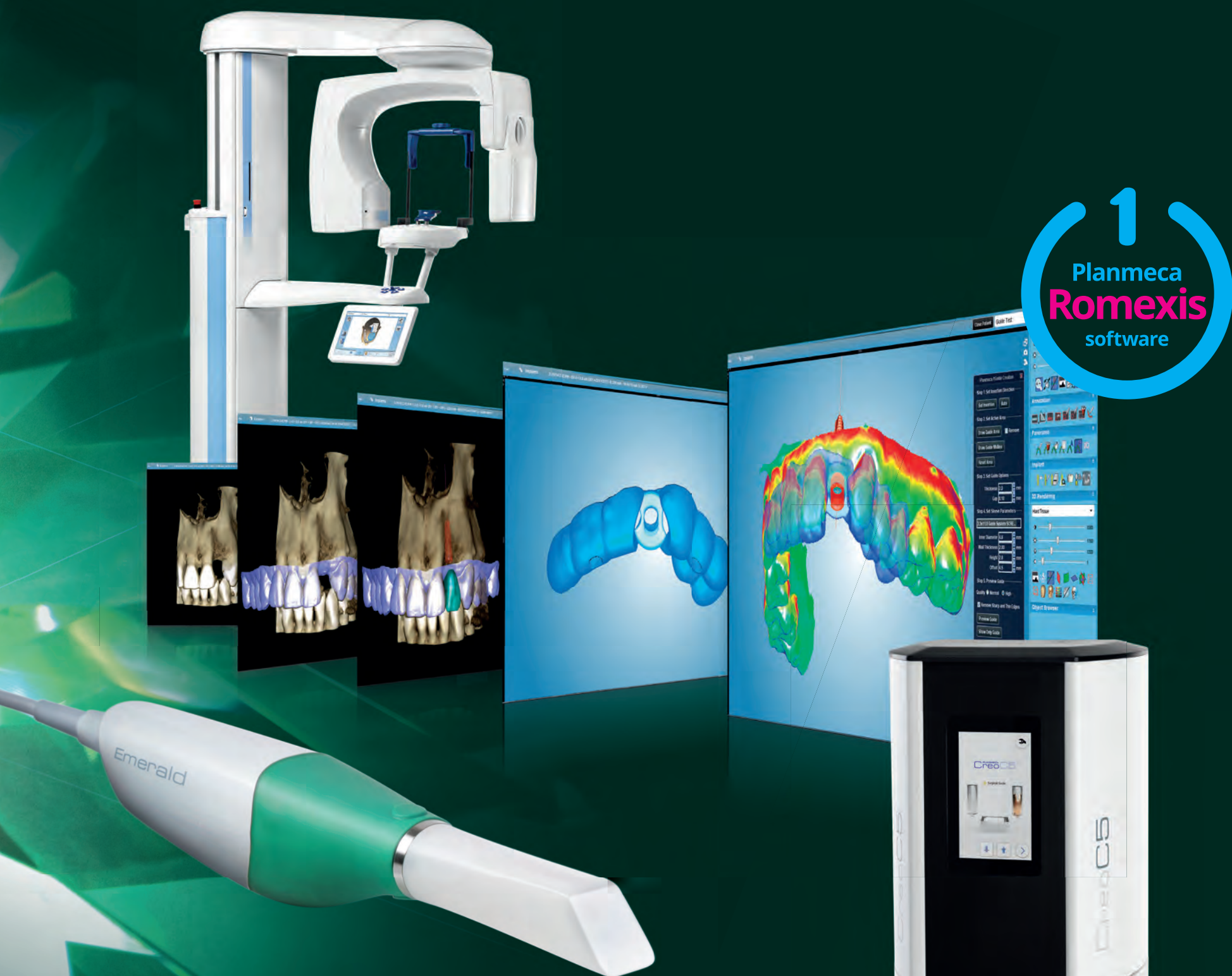

▶ Dr Scott D. Ganz



EAO  
Stand S18

# The complete implant workflow effortlessly with **one software**



Taking an implant plan to actual surgery is now easier than ever! From intraoral scanning and imaging to implant planning and guide design, all workflow steps can be controlled and completed in the **Planmeca Romexis®** software. Lastly, the guide can be easily and accurately created with our 3D printer.

Coming soon!  
**Planmeca  
Creo™ C5**  
fast 3D printer

Find more info and your local dealer!  
[www.planmeca.com](http://www.planmeca.com)



# PLANMECA

Planmeca Oy Asentajankatu 6, 00880 Helsinki, Finland. Tel. +358 20 7795 500, fax +358 20 7795 555, sales@planmeca.com

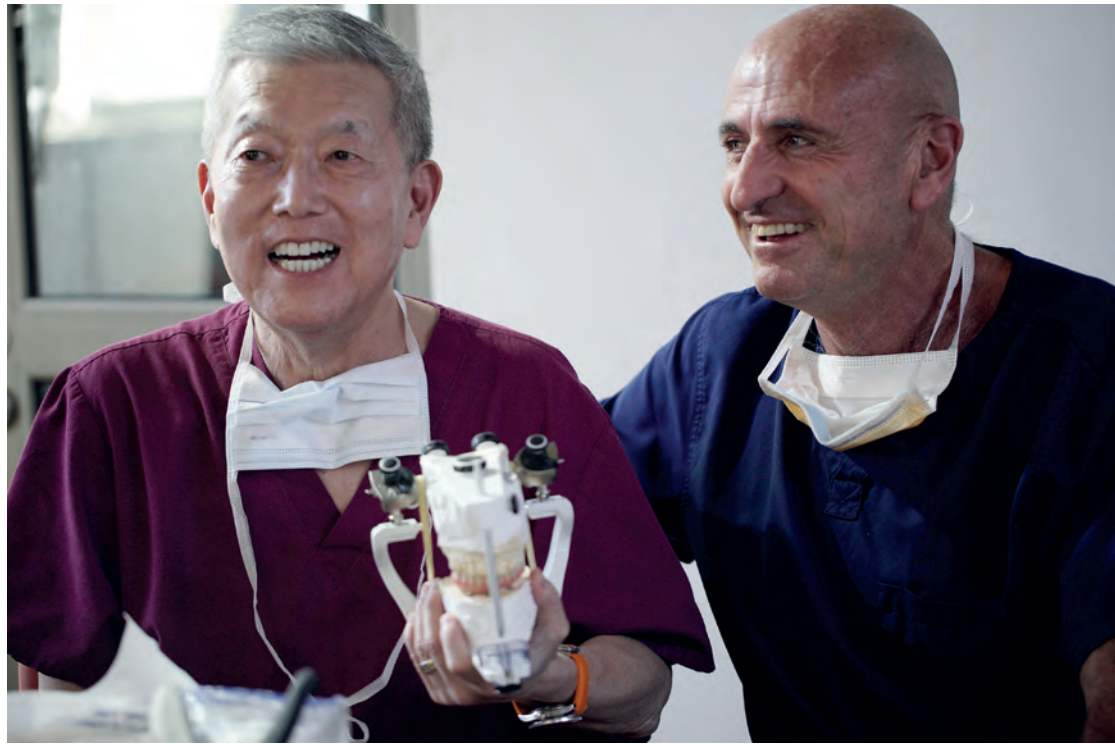

## Innovative dental implant treatment taken to Easter Island on a humanitarian mission

■ Dental implantology experts and the Foundation for Oral Rehabilitation (FOR) have taken a new treatment solution for edentulism to Rapa Nui, one of the most isolated inhabited locations in the world, also known as Easter Island. The island is home to a population of less than 8,000 and primarily one resident dentist serves the community. Consequently, dental services are limited, and many inhabitants are faced with severe financial restrictions too. In response to this need for care, Dr Rubén Rosenberg partnered with FOR expert network member Dr Kenji Higuchi to initiate this project.

In the weeklong mission led by these two surgeons, 11 Easter Island patients with mandibular edentulism underwent definitive treatment with a fixed full-arch solution. Higuchi is the innovator behind this treatment, the recently launched Trefoil system. Introduced by Nobel Biocare in 2017, it features a premanufactured bar placed on three dental implants. The final screw-retained bridge can be placed on the day of surgery.

In Rapa Nui's small local hospital, a volunteer team of surgeons, prosthodontists, laboratory technicians, nurses, support staff, and the island's primary resident dentist, Dr



▲ Through their mission, Drs Kenji Higuchi (left) and Rubén Rosenberg have dramatically improved the quality of life of 11 edentulous patients. (Photograph: FOR, Switzerland)

Felipe Collao, performed the treatments. The surgeries were completed within two days, and all patients received their final prostheses by the third. Utilising only the Trefoil protocol, the treatments were performed in

a small, basic clinical setting without the help of sophisticated dental equipment and technology. With surgery and restoration now complete for all 11 patients, Collao will provide follow-up services along with Rosenberg

and the rest of the team, who intend to provide ongoing support and care for all 11 patients in the years ahead.

FOR Executive Director Michael Hotze said, "We are deeply honored to have taken part in this project, reach-

ing out to an underserved population in providing their much-needed treatment. It is part of our long-term mission to support better implant treatment around the globe, and I look forward to seeing their successful follow-ups in the months and years to come."

Higuchi added, "With a chair time of only three days, I am very proud to report that our team completed the Trefoil surgical, restorative and laboratory protocols for 11 patients. While we achieved an unimaginable accomplishment, the appreciation and gratitude from the patients humbled our entire clinical team. The improvement in their quality of life will be witnessed by the community for years to come."

FOR is an independent, international initiative that unites professionals from various disciplines to improve oral healthcare and support humanitarian leadership. Since its inception in 2013, FOR's mission has been to help treat more patients in a humanitarian manner that best reflects innovation and the highest standards of scientifically based treatment. To record this project, a professional film crew followed the progress at every step for a video documentary. ◀

## Nanostructured surface fights bacteria growing on dental implants

■ Micro- and nanotechnology are gaining importance in the medical field and particularly in implantology. Dental implants provide a great way of improving patients' quality of life. However, the risk of inflammation still exists and could,

does not properly grow onto the abutment, pockets may form through which bacteria can reach the jawbone and cause inflammation. If this occurs, the whole implant has to be removed. KIT's Bio-medical Microtechnology (BioMEMS)

structures, which were then used to carry out adhesion experiments with typical test bacteria. Moreover, the structures were constantly varied. The results demonstrated that, depending on the distance and arrangement of the columns, adhesion

"We think that our structural approach is very promising," emphasised Doll. The production of the silicon-based nanostructures is accurate and reproducible. In the course of the project, the researchers also developed methods for the transfer to tita-

"Microtechnology can sustainably improve dental implants," concluded Prof. Andreas Guber and Dr Ralf Ahrens, who head the BioMEMS research group.

The project was funded by the Federal Ministry for Economic Af-



KIT  
Karlsruher Institut für Technologie


at worst, lead to the removal of a patient's implant. To address this issue, researchers at the Karlsruhe Institute of Technology (KIT), together with experts in dental implants, have now developed a nanostructured surface that reduces the growth of bacteria to accelerate wound healing after implantation.

Titanium is the material of choice for implants because it is biocompatible and ensures good osseointegration. So far, optimisation of dental implants has focused mainly on the titanium surface in order to further improve this process. However, tissue around dental implants may become inflamed even after successful osseointegration.

The main target for bacteria is the abutment. If the gingival tissue

team at the Institute of Microstructure Technology (IMT) wanted to solve this problem. Their research is based on an optimised abutment developed by the implant manufacturer Abutments4life, a partner of the project. Grooves smaller than the width of a hair run around the abutment and guide the cells responsible for wound healing in the right direction. In this way, tissue repair is accelerated. "This system is our point of departure," said Patrick Doll, a PhD student at the IMT. Further development focuses on two aspects: more precise structuring of the grooves for better guidance of the cells, and the search for an optimal nanosurface to which bacteria cannot attach.

With an electron beam lithography system, Doll produced columnar



▲ Scanning electron microscopy image: *Escherichia coli* bacteria attempting to adhere to a nanostructured model surface. (Photograph: Patrick Doll/KIT)

of bacteria was reduced and formation of a biofilm was delayed. Hence, recovering cells would have more time to close the wound, an effect that could otherwise be achieved by antibiotics only.

nium. After concluding the first phase in the laboratory, preclinical tests will follow. Apart from dentistry, the experts see application potential for bone plates, cochlea implants and artificial joints, among others.

fairs and Energy. Biological investigations were carried out by the Department of Operative Dentistry and Periodontology at the Medical Centre of the University of Freiburg in Germany. ◀



## Revenue of global dental implant market expected to further increase

■ A new report on the global dental implant market features key industry trends across the product, material, end-use, and regional landscapes. The report was compiled by research and consulting provider Global Market Insights and projects that the market's revenue will exceed \$5.2 billion by 2024.

The surging prevalence of oral health issues such as dental caries and periodontal disease, coupled with the soaring geriatric population base susceptible to tooth loss, has significantly fueled the dental implant market growth. In addition, rapid developments in implant technology and the increasing rate of

The US implant market grew to over \$1.1 billion last year, owing to a rapid rise in the number of baby boomers reaching geriatric age along with an increase in prevalence of oral disorders in the country. The Canadian implants industry size was valued at over \$84 million in 2017 and is projected to register a commendable compound annual growth rate (CAGR) over the next six years. The regional growth can be attributed to the presence of a favourable reimbursement scenario in the country coupled with the rising geriatric populace.

For the Asia Pacific region, a rapid CAGR of 6.5 per cent is forecast over the projected time frame. Emerging

© brovkin/Shutterstock.com



\* According to a recent report, the global dental implant market will continue to rise in value for the next six years.

dental and cosmetic surgery for aesthetic reasons have positively influenced the industry share in the recent years.

Dental implant supply to clinics accounted for the largest revenue share in 2017, followed by hospitals. The availability of advanced technological procedures for dental implantation surgeries in clinics and hospitals has been responsible for driving this segment.

According to the report, the German market held the largest share in Europe, accounting for \$289.6 million in 2017, owing to a large edentulous geriatric patient base generating high demand for dental implants across the country.

markets in India and China will grow at a robust rate because of the expanding geriatric population, rising dental tourism, and increasing disposable income and healthcare expenditure.

The report, titled *Dental Implants Market Size by Product (Tapered Implants, Parallel Walled Implants), by Material (Titanium, Zirconium), by End-use (Hospitals, Dental Clinics), Industry Analysis Report, Regional Outlook (U.S., Canada, Germany, UK, France, Italy, Spain, Russia, China, India, Japan, Australia, South Korea, Brazil, Mexico, Argentina, South Africa, Saudi Arabia, Israel), Application Potential, Competitive Market Share & Forecast, 2018-2024*, was published online on 20 August 2018. ◀

## prosthetic.line

### Abutments4life

Aesthetics simplified and predictable. Implantology has never been easier.

EAO booth B43





## “We now have clear guidelines to practise much more predictable implant dentistry”

One of the speakers at the Osstell Scientific Symposium at the 2018 EAO congress is Dr Francisco Teixeira Barbosa, who will be presenting on e-learning. In an interview with Dental Tribune International, he gave insight into educational models in dentistry, how resonance frequency analysis (RFA) facilitates clinical decision-making and the influence of digital dentistry on implant surgery.

**Dr Barbosa, you will be giving a lecture titled “Educational models and online platforms” at the Osstell symposium. What topics will you be emphasising during your presentation?**

Well, since the appearance of the Internet, educational models have been undergoing changes compared with the models we were used to in the past, which mainly took place in a classroom or an auditorium. Nowadays, information is everywhere; we are just a click away from receiving a flood of articles, webinars, guides, books and other content that is available worldwide on the Internet.

During my presentation, I will be focusing mainly on what kind of content is essential for our field and how we should be aware of whether that information is reliable and trustworthy. We have to keep in mind that what we learn online has to be evidence-based and the credibility of the author has to be verified. This way, we can implement the acquired knowledge in our daily practice with patients.

Furthermore, I will be demonstrating Osstell’s educational offering such as how they create and provide online content to educate their audience. They explain from the basics what osseointegration or primary stability means and how Osstell is linked with implant dentistry biology. In addition, I will be highlighting Osstell’s vision and commitment to helping clinicians by creating clear guidelines to obtain predictable results in the daily practice.

**The theme of the Osstell Scientific Symposium is “Confidence and predictability in implant treatments and empowering new treatment techniques”. What are your expectations of the symposium?**

Well, it’s a great theme, as we read more and more articles about implant treatments with substantial follow-up periods with high survival and success rates. Of course, these publications and trials are performed according to strict and controlled criteria that sometimes are not the reality of a typical dental office. Every day, we treat patients who have systemic disease, are smokers, or take medication that can jeopardise the whole implant treatment. We do not have exclusion criteria as some of these publications do, and we are much more exposed to failure.

**How does RFA guide and facilitate clinical decision-making in dental implantology?**

Using RFA helps clinicians to understand “what is going on down there” once an implant is placed. It is a way of objectively quantifying how likely the implant’s survival is, and RFA helps dentists to make decisions. With more than 900 articles published on RFA, we now have clear guidelines to practise much more predictable implant dentistry and avoid unpleasant situations.

**How does the ISQ (Implant Stability Quotient) measurement unit help clinicians to improve implant treatment?**

ISQ is a number that an RFA device provides at any time when it is measured. Knowing that this number yields critical information, we immediately translate it to a specific clinical protocol. Nowadays, we all know what the minimum ISQ should be to perform an immediate loading and what to do if that ISQ drops over time. And we gained something even more important: the meaning of the number from a biological point of view.



\* Dr Francisco Teixeira Barbosa performing prophylactic treatment on San Andres Island in Colombia. (Photograph: Francisco Teixeira Barbosa)

**You have contributed to the Osstell Implant Stability blog, and your entry was one of the most read last year. To whom is this blog directed and on what topic did you report in your post?**

Anytime I create an article or a piece of content, I always think about who the potential audience is. This article was about a technique that has not yet been validated by scientific literature, but has been widely commented on by dental practitioners: progressive loading.

As it is an almost “forbidden” topic to mention in scientific meetings because it has not yet been proven reliable and we still do not

have a clear protocol for implementing it, I just tried to open Pandora’s box and create a discussion about it. Thankfully, I survived the public opinion. At times, you have to take risks and talk about difficult topics if you want your content to be disseminated.

**You have written articles on digital dentistry. How is digital dentistry going to influence implantology in the future?**

I think that digital dentistry is already influencing implantology. If we look at the Rogers diagram and how a technology spreads among the population, we can say that today digital dentistry is not only for early adop-

ters anymore. The majority has already implemented digital dentistry in their daily practice, and this number is growing day by day.

Digital protocols are providing much more predictable and easier workflows for clinicians. Communication with the lab technician is clearly an asset when we use a digital workflow, and also the interaction with the patient is improved by digital dentistry. After the use of anaesthetics and osseointegration, digital dentistry is without doubt the third most crucial revolution in modern dentistry.

**Thank you very much for the interview. ◀**

## Henry Schein expands its global dental implant business

Henry Schein, the world’s largest provider of healthcare products and services to office-based dental, animal health, and medical practitioners, has announced three separate investments that will advance the company’s dental implant business strategy.

The company’s acquisition of Intra-Lock, a US-based dental implant manufacturing and sales business, is intended to enhance Henry Schein’s position in the premium implant segment. Its expansion into the lower-priced segment of the dental implant market, on the other hand, has been made clear through the

planned acquisition of a majority interest in Medentis Medical, a dental implant manufacturer based in Ger-

the Netherlands. Financial terms for these acquisitions were not disclosed.

Research and Development at Intra-Lock.

“We look forward to joining forces with the Henry Schein team to accelerate our growth and to develop and identify technologies that can be leveraged to create next-generation products for BioHorizons and CAMLOG product lines,” continued Giorno.

“With this new ownership position by Henry Schein, Medentis will accelerate several important, ongoing strategic initiatives including expanding our position in the fast-growing emerging markets,” commented Medentis founder and CEO, Alexander Scholz. “My father ran a dental laboratory and I have spent my entire career in the dental industry, including serving as Practice Manager of an implant center in Cologne. As such, I fully appreciate the importance of quality products, value and excellent customer service. I am delighted to be

aligning Medentis with the global dental leader Henry Schein, and look forward to the many opportunities to advance the practice of dentistry.”

Stanley M. Bergman, Chairman of the Board and Chief Executive Officer of Henry Schein, added, “The dental implant category has become increasingly important and we are committed to offering customers a wide array of the products and services associated with implant dentistry, thereby providing a complete solution for the benefit of the dental practice.”

Bergman continued, “We believe that with the investments we have made in CAMLOG, BioHorizons and now Intra-Lock, Medentis Medical and Pro-Cam Implants, we are well positioned to compete in the high growth global dental implant market. We welcome our new colleagues to Team Schein and look forward to continued success together.” ◀



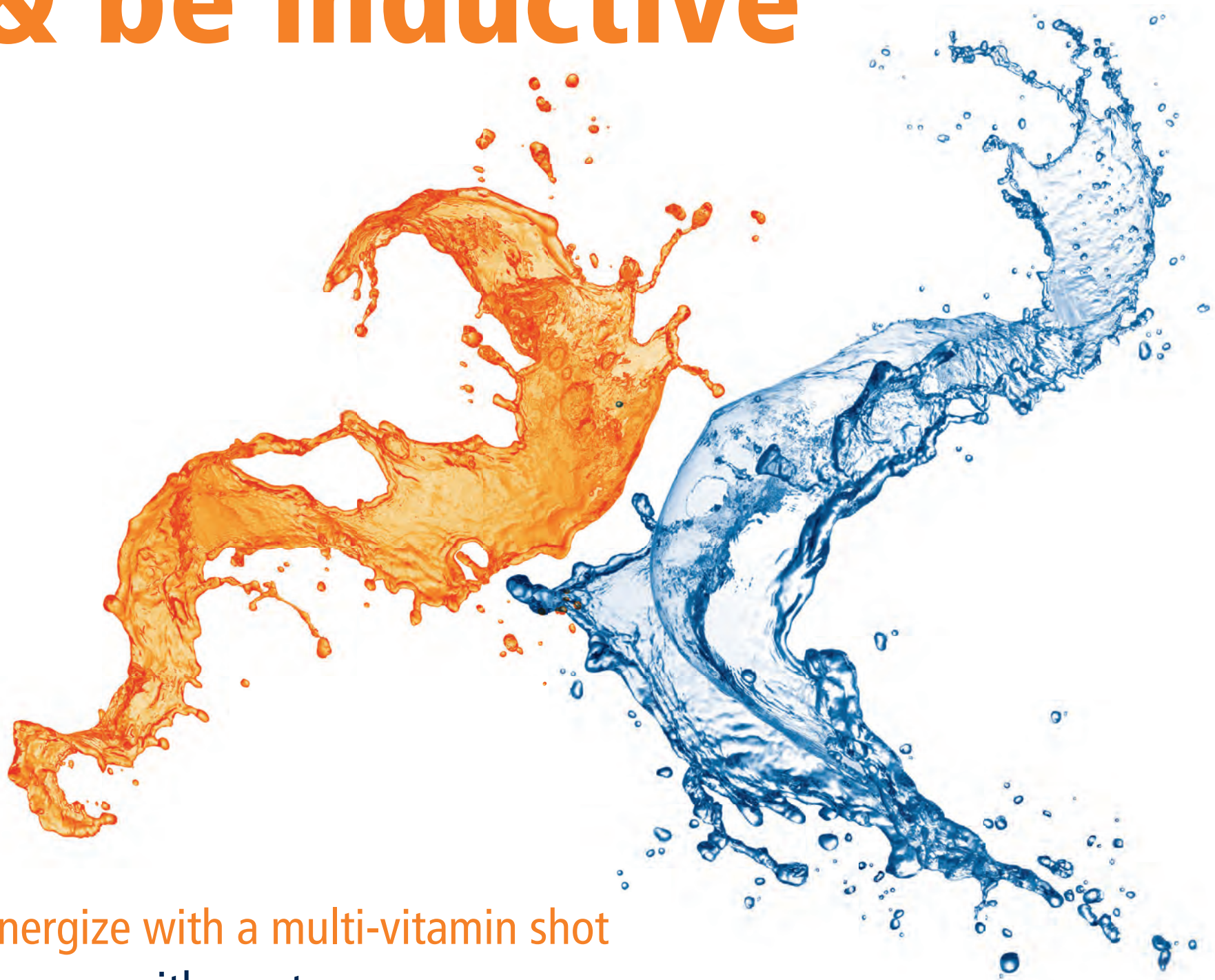\* Henry Schein has announced three separate investments designed to improve its positioning in the global dental implant market.

many. Henry Schein also strengthens its geographic footprint in Europe with the acquisition of a majority interest in Pro-Cam Implants B.V., CAMLOG’s exclusive distributor in

“As a member of the Henry Schein family, we see tremendous opportunities to continue our legacy of product innovation,” said Dr Thierry Giorno, CEO and Director of



# Stay hydrated & be inductive



Energize with a multi-vitamin shot  
Engage with our team  
Find out about our innovative solutions  
**Booth G11 & G12**

**PARTICIPATE  
IN OUR SURVEY  
& CHOOSE YOUR  
SMALL PRESENT**

BioHorizons® and  
CAMLOG Biotechnologies GmbH  
are Gold Sponsors.

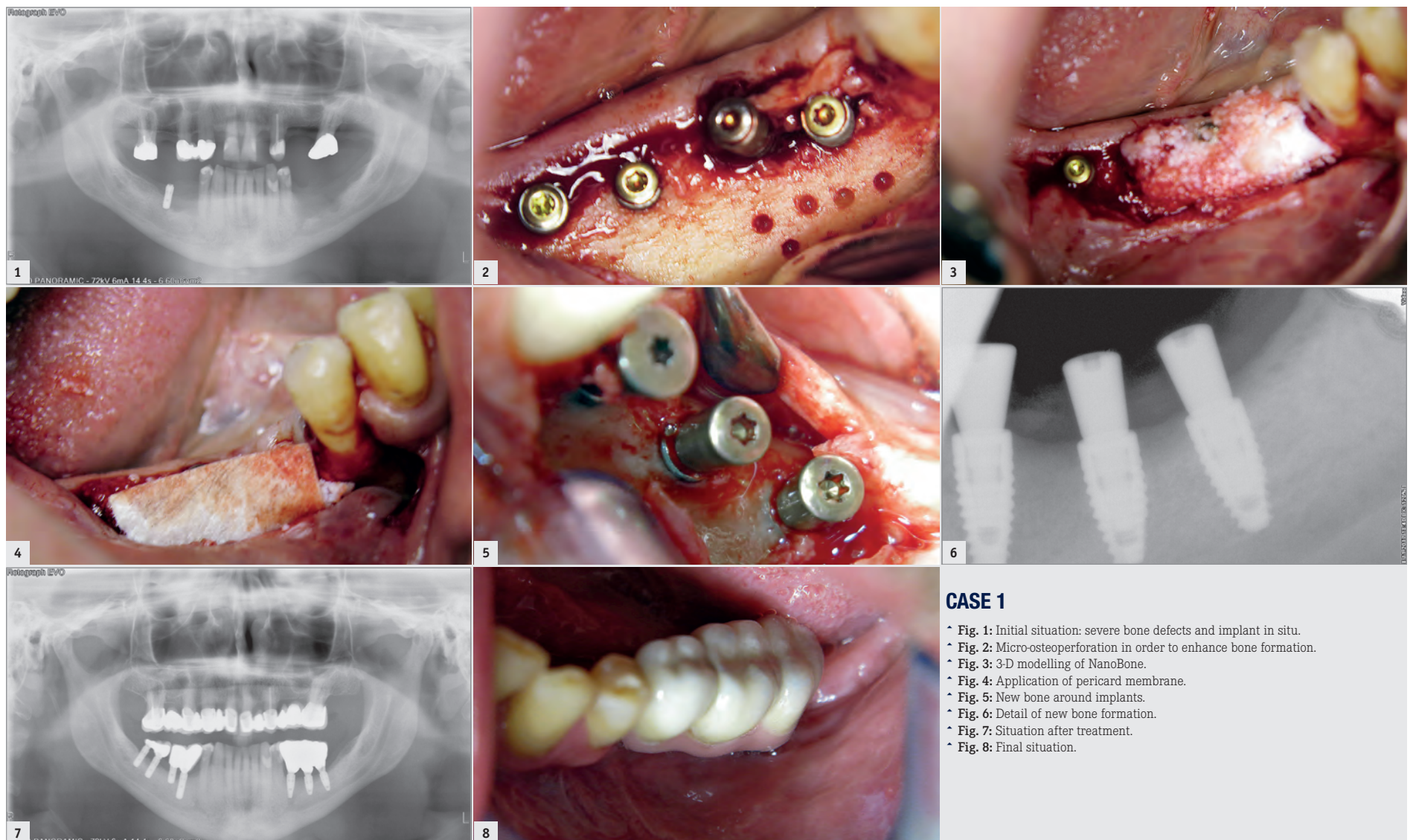
[www.biohorizons.com](http://www.biohorizons.com)  
[www.camlog.com](http://www.camlog.com)

**camlog**



# Guided bone regeneration in smokers—Use of synthetic bone blocks

Dr Dr Branislav Fatori & Dr Inge Schmitz, Germany



## CASE 1

- Fig. 1: Initial situation: severe bone defects and implant in situ.
- Fig. 2: Micro-osteoperforation in order to enhance bone formation.
- Fig. 3: 3-D modelling of NanoBone.
- Fig. 4: Application of pericard membrane.
- Fig. 5: New bone around implants.
- Fig. 6: Detail of new bone formation.
- Fig. 7: Situation after treatment.
- Fig. 8: Final situation.

■ Bone grafts are used as a filler and scaffold to facilitate bone formation and promote wound healing if necessary. Bone grafting is possible because bone tissue has the ability to regenerate completely if the space into which it has to grow is provided.

Today, guided bone regeneration (GBR) has become more predictable owing to advanced augmentation techniques and is a standard in dental implantology. Success depends on the defect morphology, but the importance of ridge morphology must not be underestimated. An adequate therapy has to be used in every individual case, and critical factors must be assessed and controlled. Primary wound closure, clot stability and angiogenesis are important factors that influence implant healing. Complications can occur in late and early stages of treatment and may be based on biomechanical, prosthetic and biological reasons. Even contaminations found on implants increase the risk of implant failure.

GBR is in general critical for use in smokers owing to reduced wound healing and vascularisation. Three case reports in which we used GBR in heavy smokers are presented here. Additionally, vertical, horizontal or 3-D mandibular augmentation in the posterior mandible was done, and this required particular experience and increased the risk of failure. The rate of implant failure is greater among smokers than in non-smokers and there is a tendency to a higher failure rate with the increasing number of cigarettes per day. One of the

authors has substantial experience in treating smokers and has well-founded knowledge of placing dental implants for more than 30 years with a low rate of implant failure.

## Smoking

Reports in the literature show lower survivability of dental implants in smokers.<sup>1,2</sup> One possible mechanism by which smoking might affect osseointegration is a lower blood flow rate owing to increased peripheral resistance and platelet aggregation. Tobacco directly affects osteoblast function. In general, smoking is a main risk factor for failure. If smokers are treated with implants, good bone quality is necessary. Excellent primary stability was gained in all the cases reported on here.

## Case presentation

Three patient cases are presented here in detail. The patients were treated according to our new protocol that we developed especially for extreme smokers between August 2015 and July 2017. In total, 12 implants were inserted. The patients were all heavy smokers, but were in good physical condition and had very good oral hygiene.

The first was a 51-year-old patient who smoked 30 cigarettes per day and suffered from diabetes and stress (Figs. 1-8). The second was a 76-year-old male patient in good physical condition who smoked 40 cigarettes per day. He underwent reconstruction of the premaxilla (Figs. 9-13). The third was a healthy female patient of 24

years of age who smoked 20 cigarettes per day. She required a sinus lift in region #25 (Figs. 14-21). The patients were informed of the intended process in detail and signed the surgical protocol containing information concerning possible risks of failure and complications, as well as information on the alloplastic and synthetic materials to be used.

## Patient diagnostics

The smokers were treated owing to atraumatic age-related root fractures, advanced caries, periodontitis, trauma or failed endodontic treatment. The patients were treated in our private practice by the same surgeon. None of the patients had uncontrolled severe diabetes, drug addiction or alcoholism. Pre-implantation diagnostics was performed in all three cases.

## Surgical phase

Implant placement was performed under local anaesthesia after pre-medication with antibiotics. The osteotomy was extended gradually, according to the intended implant diameter. After the incision, the site was cleaned and necrotic or inflammatory tissue was removed. Osteotomy sites were prepared with a sequential order of drills as recommended by the manufacturer. Implants were inserted into the prepared osteotomy sites at an insertion torque of 45 Ncm and adequate primary stability was obtained. Suturing was performed with a 4/0 thread (RESORBA Medical).

After four weeks, a site-specific full-thickness flap was raised buccally in Case 3 by vertical releasing incisions without including the papillae of the adjacent teeth (Figs. 16-19). In the aesthetic zones, no vertical incisions were made. In order to optimise the situation of the soft tissue, we placed a pedicle flap (connective tissue graft from the palate). After atraumatic flap elevation, the granulation tissue was removed.

The patients were treated with HELBO light laser therapy (bredent medical) in order to minimise bacteria (Fig. 9). The tapered implants (Hager & Meisinger) were placed in the optimal positions. After placing the cover screws, augmentation was performed using resorbable alloplastic material.

In two cases, a thickness flap was raised after 12 weeks in order to access the cover screw. In 85% of cases implant stability was evaluated using resonance frequency analysis (Osstell ISQ). A healing abutment was placed and the flap was sutured using 4/0 sutures (RESORBA Medical). Finally, after nearly two weeks, a titanium abutment was placed and a cemented metal-ceramic restoration was fabricated.

## Medication

After microbiological examination, antibiotics (Clindamycin Aristo 600, Aristo Pharma) were given t.i.d. and later b.d. until surgery. Mouth rinsing with Chlorhexamed (GlaxoSmithKline) was performed.

Local anaesthesia was performed with Ultracain D-S forte (Hoechst).

Each implant was wet with hyaluronic acid or the patient's own plasma. After completion of the surgery 40mg of Dexamethasone (Ratiopharm, IM) was injected.

After surgery, 20mg of Prednisolone (Jenapharm) was prescribed (one tablet t.i.d., then half a tablet t.i.d. and finally a quarter of a tablet t.i.d.). In order to minimise swelling five arnica globules were given.

## Postoperative treatment

Postoperative intraoral periapical radiographs were taken, to confirm the accuracy of the implant placement. Postoperative medications included antibiotics.

Digital radiographic images were taken at the time of surgery, 24 hours postoperatively and one month later in order to evaluate implant success (Figs. 6, 7, 11, 13, 15 & 20). In none of the patients inflammatory processes were found and all implants remained stable.

Abstinence from smoking should be extended at least eight weeks after the implantation in order to permit the healing phase of the osteoblasts to take place.

## Follow-up examination

Follow-up examinations were performed according to the criteria of Albrektsson et al. and Buser et al.<sup>3-5</sup> These success criteria for implants are widely cited and generally accepted. A lack of osseointegration is commonly distinguished by implant mobility and radiolucency. The criteria used describe the absence of






Meet us  
in booth  
S42

We help make  
dental implant  
treatments  
more predictable



## Let ISQ Guide You

Osstell helps you to objectively determine implant stability and to assess the progress of osseointegration – without jeopardizing the healing process.

-  Manage patients with risk factors
-  Avoid unnecessarily long treatment times
-  Achieve more predictable outcomes

 **OSSTELL**  
A  COMPANY