

## Surgical predictability of vertical GBR in the posterior mandible

*Flap design, management and passivation of soft tissues as principal keys for success*

By Drs. Marco Ronda and Claudio Stacchi

The effectiveness of guided bone regeneration (GBR), a technique used to promote horizontal or vertical bone regeneration, has been well-documented since the early 1990s.<sup>1-4</sup> The stability of the regenerated bone and its positive response in time, once functioning, has also been well-demonstrated.<sup>5-8</sup>

Vertical GBR is a technique with great potential but one that requires both the precise adherence to surgical protocols and application by operators with the appropriate knowledge and manual skills to ensure optimum management of soft tissues. In addition to achieving primary closure of the flaps, maintaining this closure during the entire period necessary for the formation and maturation of the new bone is a pre-requisite for the avoidance of membrane exposure, which inevitably leads not only to bacterial contamination but, nearly always, to the impairment of the surgical procedure of regeneration.<sup>9,10</sup>

Numerous studies have described various clinical protocols regarding the management of soft tissues in both the upper and lower arches.<sup>11-17</sup>

This retrospective analysis describes the surgical technique of the management of soft tissues applied during GBR with non-resorbable membranes in 127 cases of vertical defects of the posterior mandible and evaluates the clinical results obtained.

### Materials and techniques

Between 2000 and 2012, a total of 127 cases of vertical bone defects in edentulous posterior mandibles were treated with the use of GBR with non-resorbable membranes.

The technique was applied by following a surgical protocol, which has undergone few variations during the years.

From 2000 to 2008, expanded polytetrafluoroethylene (e-PTFE)

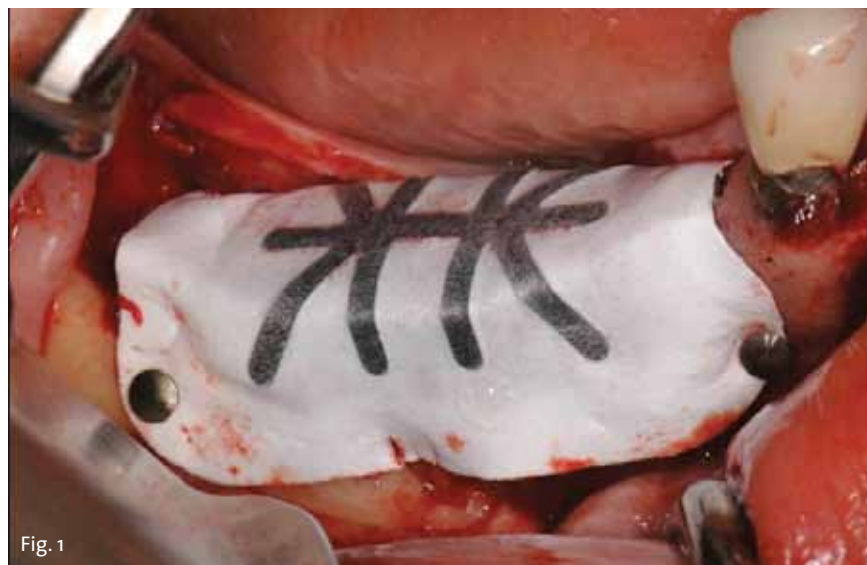

Fig. 1

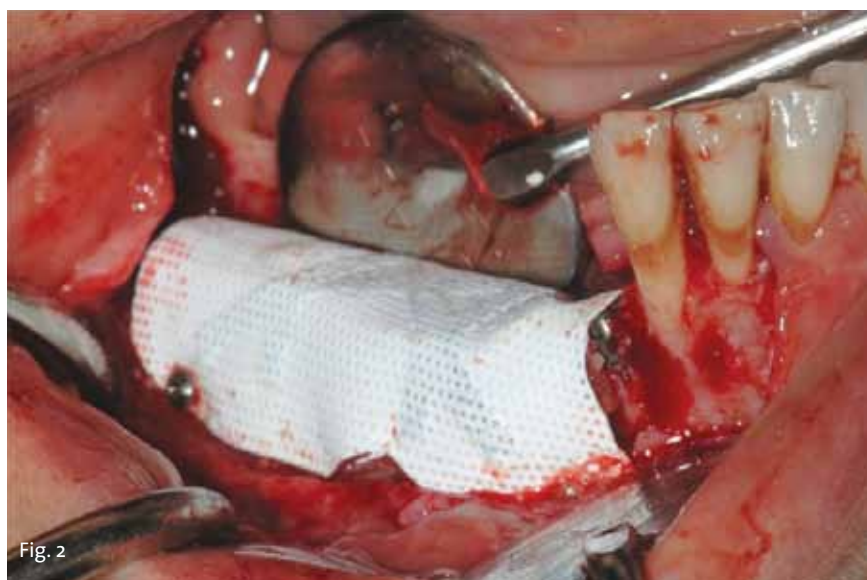

Fig. 2

Photos/Provided by Drs. Ronda Marco and Claudio Stacchi

titanium-reinforced non-resorbable membranes (Gore-Tex TR9, W.L. Gore & Associates, Flagstaff, Ariz.) were used as a barrier device in 72 cases (Fig. 1).

From 2009 to 2012, high-density polytetrafluoroethylene (d-PTFE) titanium-reinforced non-resorbable membranes (Cytoplast TI250XL, Osteogenics Biomedical, Lubbock,

Texas) were used as a barrier device in 55 cases (Fig. 2).

All the membranes were fixed mesially and distally on the lingual side with the use of titanium pins (Helmut Zepf Medizintechnik, Seitingen, Germany) or mini-screws (Pro-Fix, Osteogenics

• See GBR, page B2

## ICOI heats up spring in Vegas

*Group's annual symposium takes over the Bellagio Hotel with 'Maxilla'-focused sessions*

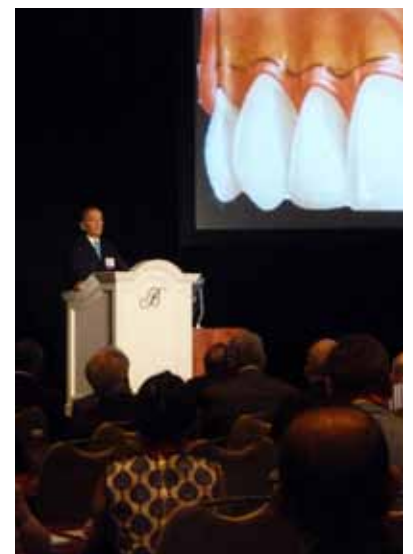By Sierra Rendon, Implant Tribune

More than 1,200 attendees, including 700 doctors and 250 auxiliaries, laboratory technicians, students and industry personnel, hit the Bellagio Hotel on the Las Vegas Strip for this year's Spring Symposium.

This event included an in-depth, challenging focus on "The Maxilla: Single Tooth to Full Arch Reconstruction" and welcomed main podium lecturers such as Dr. Jaime Lozada, Dr. Giuseppe Cardaropoli, Dr. Joseph Kan and Dr. Michael Sonick.

For implant doctors or team members who came looking to stock up on supplies or to look for products to bring home to the office, the exhibit hall was brimming with new technology and other treats. More than 100 exhibitors brought the industry's latest and greatest options for implantologists to use in their practices.

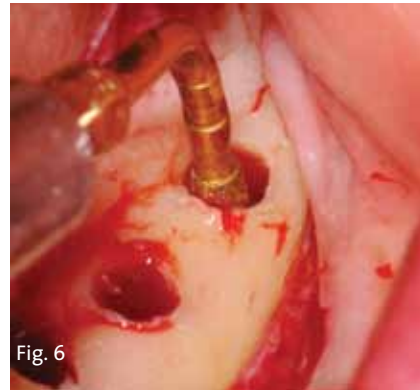
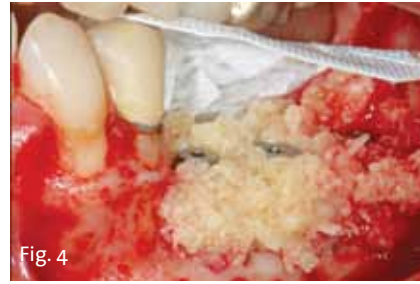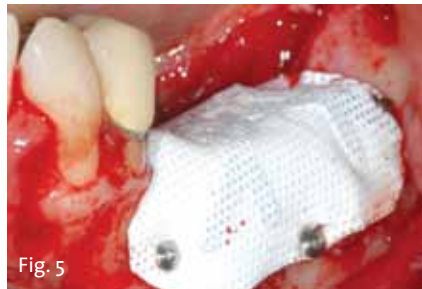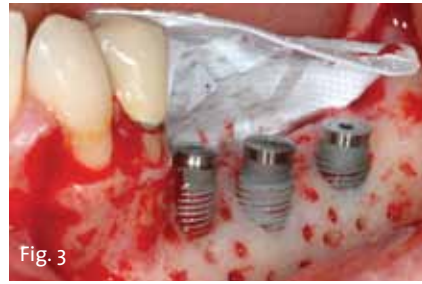See pages B10 and B11 for more scenes and stories from the ICOI's Spring Symposium.



Dr. Jaime Lozada provides the first main podium lecture on the first day of the ICOI's Spring Symposium in Las Vegas. Lozada's session focused on 'Extraction Site Management' and, more specifically, the IDR technique. Photo/Sierra Rendon, Managing Editor

← GBR, Page B1

Biomedical, Lubbock, Texas) (Fig. 3). After positioning the graft material around the implants, which were left protruding from the crest (Fig. 4), the membranes were also stabilized on the buccal side with the same fixation devices (Fig. 5). Preparation of the implant sites, for the most coronal portion of the osteotomy, involved the use of twist drills and, for the most apical portion, near the mandibular nerve, a piezoelectric OT4 insert (Piezosurgery, Mectron, Carasco, Italy) (Fig. 6). Implants (Spline Twist and Tapered Screw-Vent, Zimmer Dental, Carlsbad, Calif.) were inserted leaving their most coronal portion protruding from the crest for a length equivalent to the vertical bone regeneration planned. In certain cases — those in which it was not possible to obtain adequate primary stability in low quantities of residual bone — the




→ See GBR, page B4


AD

**PHOENIX, ARIZONA**  
**OCTOBER 23-26 2013**


**TECHNOLOGY & BIOLOGY**  
**CONVERGE**  
IN THE VALLEY OF THE SUN



**AMERICAN ACADEMY OF IMPLANT DENTISTRY**  
62nd AAID Annual Meeting | [aaid.com](http://aaid.com)  
Practical Education for the Practicing Implant Dentist



**ADA CERP** Continuing Education  
Approved Provider  
The American Academy of Implant Dentistry is an ADA CERP Accredited Provider. ADA CERP is a service of the American Dental Association to assist dental professionals in identifying quality providers of continuing dental education. ADA CERP does not guarantee or endorse individual courses or instructors, nor does it imply acceptance of credit hours by sponsors of dentistry. American Academy of Implant Dentistry designates the ability for CE accreditation.



**PACE**  
Academy of General Dentistry  
Approved PACE Program Provider  
ADA CERP Accredited  
Dentists who do not meet standards for a high degree of continuing education in dentistry are not recommended. June 1, 2012 to May 31, 2013. Phone: 618-371-0888.

## IMPLANT TRIBUNE

**PUBLISHER & CHAIRMAN**  
Torsten Oemus [t.oemus@dental-tribune.com](mailto:t.oemus@dental-tribune.com)

**PRESIDENT/CHIEF EXECUTIVE OFFICER**  
Eric Seid [e.seid@dental-tribune.com](mailto:e.seid@dental-tribune.com)

**GROUP EDITOR**  
Kristine Colker [k.colker@dental-tribune.com](mailto:k.colker@dental-tribune.com)

**MANAGING EDITOR IMPLANT TRIBUNE**  
Sierra Rendon [s.rendon@dental-tribune.com](mailto:s.rendon@dental-tribune.com)

**MANAGING EDITOR**  
Fred Michmershuizen  
[f.michmershuizen@dental-tribune.com](mailto:f.michmershuizen@dental-tribune.com)

**MANAGING EDITOR**  
Robert Selleck, [r.selleck@dental-tribune.com](mailto:r.selleck@dental-tribune.com)

**PRODUCT/ACCOUNT MANAGER**  
Humberto Estrada [h.estrada@dental-tribune.com](mailto:h.estrada@dental-tribune.com)

**PRODUCT/ACCOUNT MANAGER**  
Jan Agostaro [j.agostaro@dental-tribune.com](mailto:j.agostaro@dental-tribune.com)

**PRODUCT/ACCOUNT MANAGER**  
Will Kenyon [w.kenyon@dental-tribune.com](mailto:w.kenyon@dental-tribune.com)

**MARKETING DIRECTOR**  
Anna Wlodarczyk-Kataoka  
[a.wlodarczyk@dental-tribune.com](mailto:a.wlodarczyk@dental-tribune.com)

**EDUCATION DIRECTOR**  
Christiane Ferret [c.ferret@dtstudyclub.com](mailto:c.ferret@dtstudyclub.com)

Tribune America, LLC  
116 West 23rd Street, Suite 500  
New York, NY 10011  
Phone (212) 244-7181  
Fax (212) 244-7185

Published by Tribune America  
© 2013 Tribune America, LLC  
All rights reserved.

Tribune America strives to maintain the utmost accuracy in its news and clinical reports. If you find a factual error or content that requires clarification, please contact Managing Editor Sierra Rendon at [s.rendon@dental-tribune.com](mailto:s.rendon@dental-tribune.com).

Tribune America cannot assume responsibility for the validity of product claims or for typographical errors. The publisher also does not assume responsibility for product names or statements made by advertisers. Opinions expressed by authors are their own and may not reflect those of Tribune America.

**EDITORIAL BOARD**

- Dr. Pankaj Singh
- Dr. Bernard Touati
- Dr. Jack T. Krauser
- Dr. Andre Saadoun
- Dr. Gary Henkel
- Dr. Doug Deporter
- Dr. Michael Norton
- Dr. Ken Serota
- Dr. Axel Zoellner
- Dr. Glen Liddelov
- Dr. Marius Steigmann

### Corrections

Implant Tribune strives to maintain the utmost accuracy in its news and clinical reports. If you find a factual error or content that requires clarification, please report the details to Managing Editor Sierra Rendon at [s.rendon@dental-tribune.com](mailto:s.rendon@dental-tribune.com).

Tell us what you think!

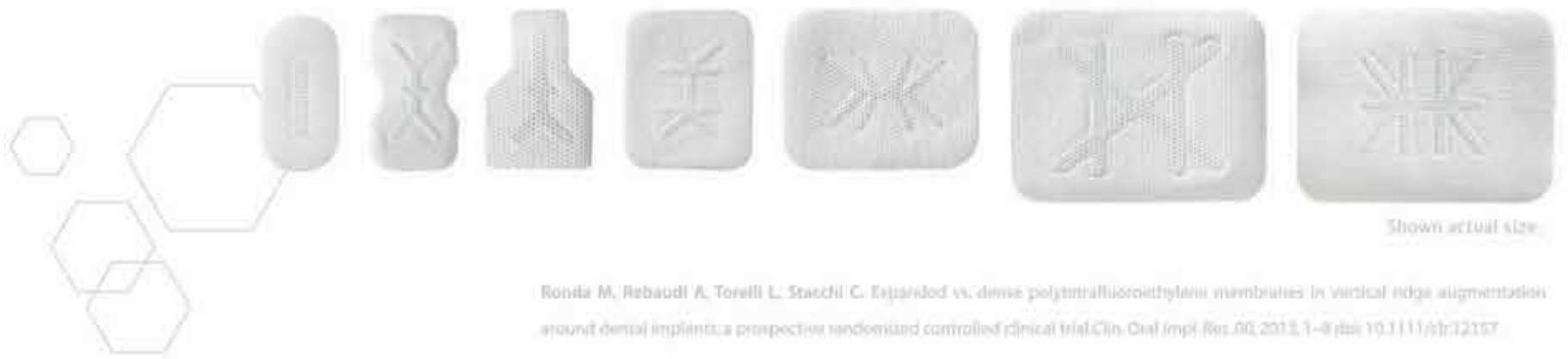Do you have general comments or criticism you would like to share? Is there a particular topic you would like to see articles about in Implant Tribune? Let us know by e-mailing [feedback@dentaltribune.com](mailto:feedback@dentaltribune.com). We look forward to hearing from you! If you would like to make any change to your subscription (name, address or to opt out) please send us an e-mail at [database@dental-tribune.com](mailto:database@dental-tribune.com) and be sure to include which publication you are referring to. Also, please note that subscription changes can take up to six weeks to process.

**OSTEOGENICS**

B I O M E D I C A L

# CYTOPLAST<sup>™</sup> Titanium-Reinforced

**Create the space and shape you need** when performing vertical and horizontal ridge augmentations with Cytoplast<sup>™</sup> titanium-reinforced PTFE membranes.



Ronita M, Rebaudi A, Torelli L, Stacchi C. Expanded vs. dense polytetrafluoroethylene membranes in vertical ridge augmentation around dental implants: a prospective randomized controlled clinical trial. Clin. Oral Implants Res. 00, 2013, 1-8 | doi: 10.1111/clr.12107

## IDEAL PARTNERS

for ridge augmentation procedures

**CYTOPLAST<sup>™</sup>**  
PTFE Suture  
the *soft* monofilament



**pro-fix**  
precision fixation system



osteogenics.com | **888.796.1923**

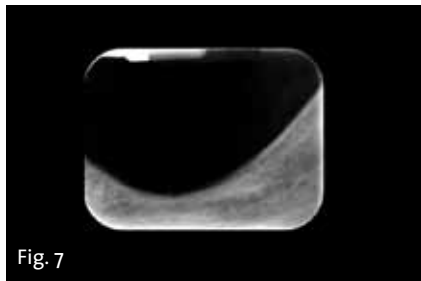


Fig. 7

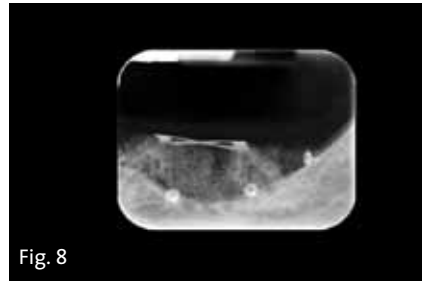


Fig. 8

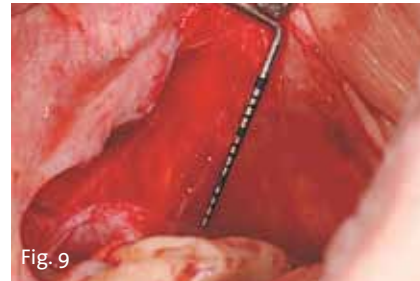

Fig. 9

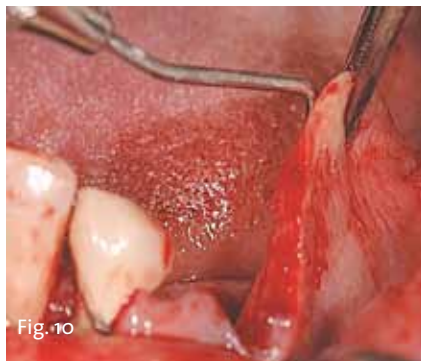

Fig. 10

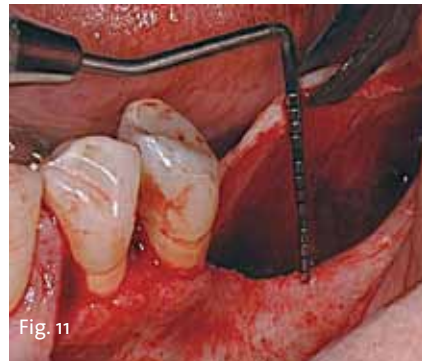


Fig. 11

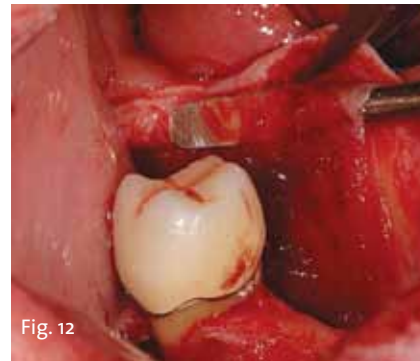


Fig. 12

- GBR, Page B2

vertical bone regeneration preceded the positioning of the implants (Figs. 7, 8).

Multiple cortical perforations, which created openings for osteopromotion, were then made with a piezoelectric OP5 insert (Piezosurgery, Mectron, Carasco, Italy) in order to stimulate blood and cell migration from the bone marrow spaces to the regeneration area.<sup>18,19</sup>

During the period of time analyzed, various graft materials, alone or combined, were used together with the membranes: autologous bone; tricalcium phosphate; DBM (Dynagraft, Keystone Dental, Burlington, Mass.); MFDBA (Puros, Zimmer Dental, Carlsbad, Calif.); or combinations of mineralized and demineralized allograft bone (MFDBA & DFDBA, enCore, Osteogenics Biomedical).

**Surgical management of soft tissue**

All surgeries as well as postoperative care are carried out by a single operator. For each patient, treatment includes the analysis of a diagnostic wax-up and CT or CBCT scan performed with a template. The objective is not only to position the implants where the quantity of residual bone allows but to position their platforms on the ideal line situated approximately 2 mm under the cement-enamel junction of the adjacent teeth.

After performing local anesthesia, (articaine hydrochloride 4 percent with epinephrine 1:100.000, Septanest, Ognà, Muggiò, Italy), a horizontal, mid-crestal, full thickness incision is performed in keratinized tissue. The incision extends from the distal margin of the last tooth adjacent to the treatment area to the ramus of the mandible, ending with a releasing incision on its buccal surface.

In the second molar area, to preserve the integrity of the lingual nerve, the scalpel should be inclined at an approximately 45 degree angle with the tip in vestibular direction, and the blade should touch the external oblique line while the incision is made in distal and buccal direction.

In the proximal vestibular zone, the incision continues intrasulcularly involving the last two teeth adjacent to the area to be treated and concludes with a vertical hockey stick releasing incision.

Lingually, the incision continues intrasulcularly until the gingival zenith of the last tooth and continues along the crest of the ridge for approximately 1 cm in the thickness of the keratinized gingiva. Full thickness flaps is then elevated and the mental nerve is isolated. The mobilization and release of the buccal flap is obtained with a horizontal periosteal incision performed with a new blade for the entire length of the flap, from the distal to the mesial release.

This longitudinal incision is performed approximately 5 mm apically from the crestal incision and should only affect the periosteal fibers. The passivation of the vestibular flap, thus obtained, allows for a mean coronal elevation of the flap of approximately 20 mm: this is the sum of the amount of tissue present above the periosteal line of incision (5 mm) and the stretching of the flap following the periosteal incision (15 mm) (Figs. 9, 10).

The lingual flap is also full thickness elevated until the mylohyoid line is reached. This maneuver allows for the obtaining of a mean coronal elevation

AD

educate | inspire | connect



AACD 2014  
Orlando

April 30 - May 3, 2014

30<sup>th</sup> Annual AACD Scientific Session

Visit [www.AACDconference.com](http://www.AACDconference.com)



of approximately 15 mm (Fig. 11). At this point, following the technique previously described by Ronda and Stacchi<sup>17</sup>, the mylohyoid muscle insertion on the inner surface of the lingual flap is identified, approximately 5 mm apically from the crestal line of incision.

This insertion, with the use of a blunt instrument, is first isolated (Fig. 12), and then separated from the flap by applying light tensile force. This maneuver allows for the near doubling of the lingual flap passivation and brings the coronal elevation from approximately 15 mm to approximately 30 mm (Figs. 13, 14).

The flaps thus passivated can be sutured covering the membrane without tension, using two different suture lines: one horizontal mattress suture with 3-0 PTFE approximately 5 mm apically from the crestal line of incision (Cytoplast Suture, Osteogenics Biomedical) and a series of interrupted sutures with 4-0 PTFE to complete the flap closure. The releasing incisions are closed with resorbable sutures (6-0, 7-0) (Serafit, Serag Wiessner, Naila, Germany).

The sutures are removed after approximately 12-15 days and, during this period, the patient uses a chlorhexidine 0.2 percent mouthrinse twice a day for one minute. In addition, antibiotics (amoxicillin/clavulanic acid 875+125mg) and NSAIDs (ibuprofen 600 mg) are prescribed for one week.

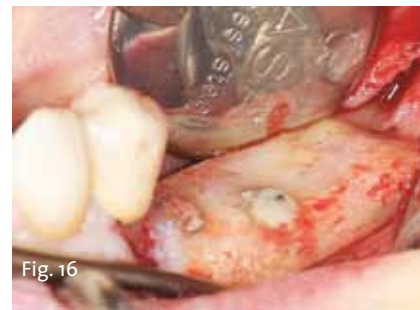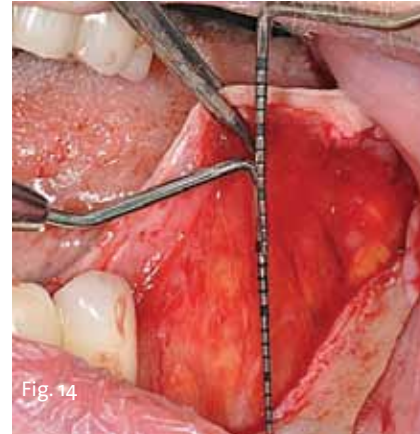
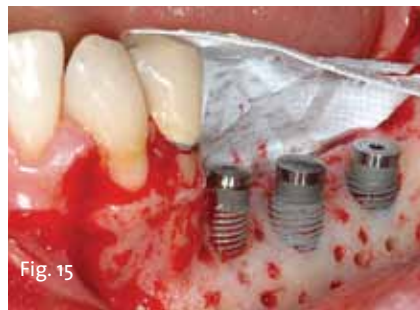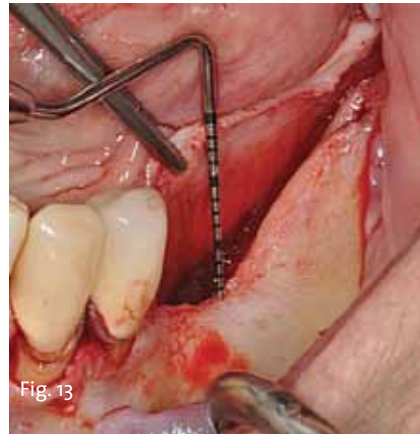
After a period of approximately six months, during which new bone formation is obtained and completed, the patient undergoes a second procedure for the removal of the membrane and fixation system, completing soft-tissue management (Figs. 15, 16).

## Results

The goal of this study was to describe the results and complications that occurred both during and after surgery in 127 cases of vertical GBR with non-resorbable membranes, until their removal. Certain complications in a considerable percentage of cases can lead to the failure of the entire regenerative procedure. In order to list and analyze them, the classification proposed by Fontana et al. (2011)<sup>20</sup> was used.

Beyond the normal sequelae associated with surgery (edema, blood extravasation and hematoma), neurological complications (B, Fontana 2011) occurred in three cases (2.4 percent). Paresthesia is believed to have been related to the release and elevation of the vestibular flap, which most likely caused the stretching of mental nerve fibers. In all three cases, the symptoms of paresthesia subsided one month after the surgery.

During the healing period, no membrane exposure occurred in any of the cases (no Class I, II or III complications, Fontana 2011). In nine cases (7.1 percent), graft sepsis occurred in the absence of membrane exposure (Class IV, Fontana 2011). All Class IV complications occurred during the first month after the regenerative procedure.



## Discussion

The objective of this retrospective analysis is to focus on the complications associated with the surgical technique of vertical regeneration with non-resorbable membranes in order to evaluate the level of surgical predictability associated with this procedure in view of the complexity and difficulty in augmenting the posterior ridge.

From the analysis of the results described, the general percentage of failure was 7.1 percent.

However, it is evident that with the application of conventional passivation techniques, and the introduction of the new lingual flap management technique, the extent of coronal displacement of the flaps guarantees the specialist a sufficient quantity of tissue to perform a tension-free suture above the regeneration area.

This is confirmed by the fact that no membrane exposure occurred in the 127 cases analyzed. The primary cause of failure of this technique, from the analysis of our data, is the bacterial contamination of the graft-membrane-implant complex in its entirety.

Contamination can already occur during surgery (inappropriate handling of surgical instruments, graft contamination as a result of bacteria present in saliva) or during the postoperative phase (failed primary closure of the flaps or early exposure of the membrane). As seen, the appropriate management of soft tissue allows for an entirely passive and hermetic primary closure of the flaps, as well as its maintenance, for the entire duration of the healing period.

The problem yet unresolved is that of the cases in which graft sepsis occurs, despite flap closure being perfectly maintained.

In this situation, which always mani-

fest itself during the first month after the procedure, intra-operative graft contamination plays a fundamental role. Given the difficulty in keeping the surgical area completely isolated from salivary contamination during the GBR procedure (above all, in the posterior mandible), the reduction of surgical time is one of the keys for minimizing the risk of infection.

In this regard, it could be useful to harvest autologous bone from a donor site, which is not from the actual area of regeneration, prior to the GBR procedure (with an inevitable increase in morbidity), or the use of commercial bone grafts alone, with the objective of entirely eliminating both autologous bone harvesting and the risk of infection associated with prolonged operating times.<sup>21</sup>

## Conclusions

The current flap passivation techniques available to the specialist have significantly reduced the percentage of failure associated with early exposure of the membrane.

Therefore, we can surmise that vertical GBR is a realistically feasible solution in regard to surgical success (treatment results' stability over time has already been extensively demonstrated), despite the technique being considered highly "operator-sensitive."

The fact that vertical GBR is a difficult procedure is not, by any means, to be underestimated. It requires extensive knowledge and should be carried out after appropriate training, which must enable the specialist to acquire a complete theoretical and practical knowledge both in the fields of periodontology and implant dentistry.

References are available upon request from the publisher.

## About the authors



**DR. MARCO RONDA** graduated with a degree in medicine from the University of Verona. A one-year course in advanced surgery, taught by Dr. Massimo Simion, and a Masters course in Regenerative Surgical Techniques at the University of Pennsylvania are among the many specialization courses he has attended. Ronda periodically gives lectures and provides practical training courses in implantology and bone-regeneration techniques at his practice in Genoa. He is also invited to speak at many national and international meetings and cooperates with several Italian universities including Milan, Trieste, Modena, Genoa and Pisa, and he is an adjunct professor at Bologna University.

The International Journal of Periodontics & Restorative Dentistry has published his study regarding a new surgical technique of lingual flap management that has been proven to increase bone volume in all cases. He is also the author of an article that was published in the Clinical Oral Implants Research journal that compares expanded PTFE and dense PTFE in guided bone regeneration. He may be contacted at [mronda@panet.it](mailto:mronda@panet.it).



**DR. CLAUDIO STACCHI** graduated in dentistry (DDS) and specialized in oral surgery (MSc) at the University of Trieste (Italy). He is contract professor in oral implantology since 2007 at the School of Dentistry and at the Master Program in Oral Surgery at the University of Trieste. He is an active founding member of the International Piezosurgery Academy, active member of the Academy of Osseointegration, member of the International Team for Implantology (ITI), member of the Italian Society of Osseointegrated Implantology (SIO) and member of the Italian Society of Oral Surgery and Implantology (SICOI).

Stacchi is a reviewer of the International Journal of Periodontics and Restorative Dentistry and of the Journal of Oral Implantology. He is also author of several publications on indexed journals and a speaker at national and international congresses on oral surgery and implantology topics. His professional practice is limited to periodontology and implantology at the Dental Clinic of the University of Trieste and at his private office in Gorizia.

*'The current flap passivation techniques available to the specialist have significantly reduced the percentage of failure associated with early exposure of the membrane.'*



# Introducing



# CAD Milled Bars & Abutments

Select from a wide-range of bars and abutments for Implant Direct's popular industry-compatible implant interfaces below. Custom Direct bars are also available for Implant Direct and Nobel Biocare multi-unit, screw-receiving abutments as well as Implant Direct's proprietary 1-piece ScrewIndirect® implant. CustomDirect abutments may be fabricated in titanium or one of five different zirconia shades for optimal function and esthetics.

CustomDirect™ bars made using the industry's only robotic and full automation machining centers for unsurpassed precision and efficiency. Select bar design and order online at [www.custom-direct.com](http://www.custom-direct.com)

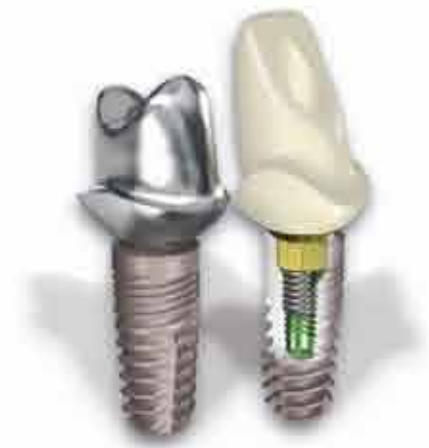


**ScrewIndirect®  
Implant**

Receive \$100 off bars fabricated on four or more Implant Direct ScrewIndirect 1-piece implants or multi-unit abutments

GPS™ Titanium Bar for 4-6 implants includes screws plus up to 4 male and female attachments - \$995



Hybrid Titanium Bar for 4-6 implants includes screws - \$795



Custom Titanium Abutment  
Lab designed- \$100  
Implant Direct designed - \$130

Custom Zirconia/Ti Abutment  
Lab designed - \$120  
Implant Direct designed - \$150

## Joining our full line of industry-compatible prosthetics



**RePlant®**  
Internal Tri-Lobe Connection  
Compatible with NobelReplace™



**Legacy™**  
45° Conical Hex Connection  
Compatible with Zimmer, BioHorizons® MIS®



**InterActive™**  
78° Conical Hex Connection  
Compatible with NobelActive™ & NobelReplace CC



**Swish™**  
Internal Octagon Connection  
Compatible with Straumann Tissue Level



	Laboratory Abutment	Straight Snap-On	Straight Contoured	15° Angled Contoured	Gold/Plastic	Zirconia/Ti Abutment	Angled Zirconia/Ti Abutment	Plastic Temporary Abutment	Ball Attachment	GPS™ Attachment	Angled GPS™ Attachment	Multiple-Unit w/Cap & Transfer	Straight	Angled
<b>Our price</b>	\$85	\$100	\$100	\$100	\$120	\$120	\$120	\$40	\$112	\$100	\$120	\$100	\$120	
<b>Zimmer Dental®</b>	\$162	\$220	\$175	\$190	\$216	\$245	\$260	\$67	\$179	\$166	N/A	\$217	\$297	
<b>Straumann®</b>	N/A	\$202	\$210	\$210	\$265	\$374 <sup>2</sup>	\$374 <sup>2</sup>	\$70	\$297	\$196	N/A	\$191	N/A	
<b>Nobel Biocare™</b>	\$194	\$192	\$175	\$232	\$223	\$295	\$295	\$75	\$225	\$156	N/A	\$236	\$282	

Price comparison based upon US list prices as of January 2013. All trademarks are property of their respective companies.  
<sup>1</sup>Timing fees.  
<sup>2</sup>Comparison based upon Straumann's CAPES Custom Zirconia Abutment. Price varies depending upon the laboratory.  
<sup>3</sup>N/A list price for Tapered Screw-Vent® with nitro-grooves, healing collar & straight abutment.  
<sup>4</sup>US list price for SLActive Tapered Effect® implant, closure screw, healing abutment, solid abutment, transfer and comfort cap.  
<sup>5</sup>US list price for InterActive with cover screw, impression coping & abutment.  
 \*Terms and conditions apply.



Approved PACE Program Provider FAGD/MAGD Credit  
 Approval does not imply acceptance by a state or provincial board of dentistry or AGD endorsement  
 8/01/2012 to 7/31/2015  
 Provider ID# 316714

# Dare to Compare on Innovation, Quality, Service and Value



## Legacy™3 Implant

All-in-1 Packaging includes implant, abutment, transfer, cover screw & healing collar  
\$200 vs \$633<sup>3</sup> from Zimmer Dental

✓ **Reality Check** Zimmer Customers  
Save \$433 with Legacy3



## SwishPlant™ Implant

All-in-1 Packaging includes implant, abutment, transfer, cover screw, healing collar & comfort cap  
\$200 vs \$737<sup>4</sup> from Straumann®

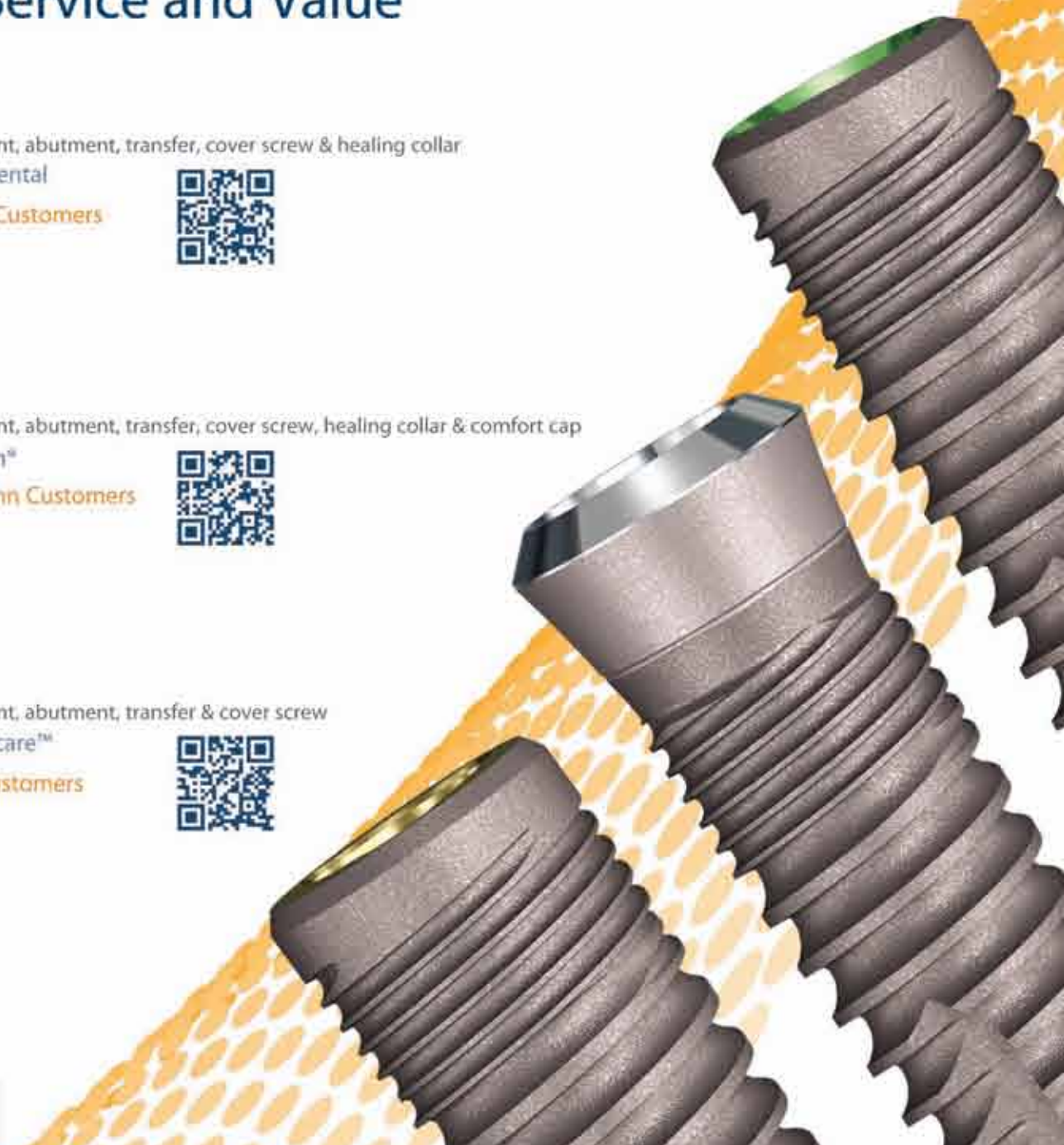
✓ **Reality Check** Straumann Customers  
Save \$537 with SwishPlant



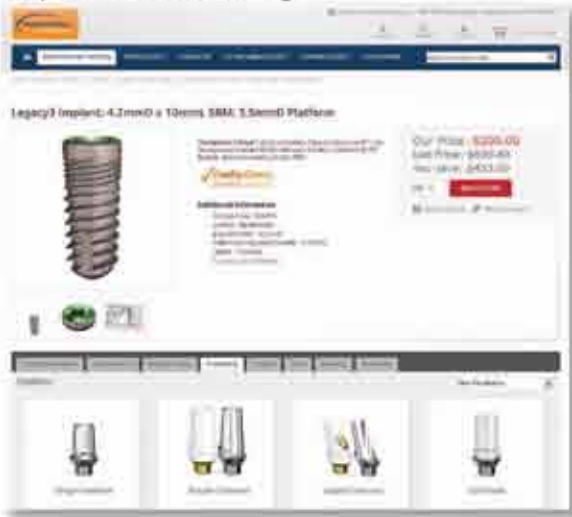## ReActive™ Implant

All-in-1 Packaging includes implant, abutment, transfer & cover screw  
\$200 vs \$718<sup>5</sup> from Nobel Biocare™

✓ **Reality Check** Nobel Customers  
Save \$518 with ReActive



### Implant Product Page



### All-in-1 Shopping

Visit our new online store, find the implant you want and the compatible components, abutments, instruments, biologics, literature are just a click away! There's no need to jump through different product categories or pages, you can find it all in one spot.



## Implantology Basics and Beyond

24 CE CREDITS

### Implant Dentistry 101

3 Day Introduction Course  
June 13-15 | July 18-20 | September 12-14



View Dr. Niznick's 2-hour lecture & earn 2 CE credits FREE

Dr. Gerald Niznick discusses how the latest implant design innovations are shaping the future of implantology.



12 CE CREDITS

### Laser Surgery: A Quantum Leap Forward

2 Day Certification Course  
June 28-29 | July 19-20 | September 20-21

# Implant position in the esthetic zone

## *Establishing a treatment plan is paramount*

By Siamak Abai, DDS, MMedSc

Since the advent of modern root form osseointegrated implant dentistry in 1952, clinicians have strived for improvements in implant positioning in the esthetic zone to achieve predictable restorative and esthetic results.

Years of clinical experience in congruence with controlled clinical studies have helped establish parameters as a guide for these results. Establishing a treatment plan and clinical protocol prior to implant placement is paramount.

Treatment planning traditionally begins with comprehensive medical and dental evaluations, articulated diagnostic casts, radiographs, cone-beam computed tomography (CBCT) scans and a diagnostic wax-up. Patient demands must be taken into consideration prior to surgery, and pre-surgical mockups may be necessary to convey the information to the patient.

The advancement of CBCT technology has led dentistry into a new realm of dimensional accuracy. In combination with the use of a surgical or guided stent, proper 3-D positioning of an implant has led to more accurate clinical results.

The importance of the implant position can be manifested in the four dimensionally sensitive positioning criteria: mesiodistal, labiolingual and apico-coronal location, as well as implant angulation.<sup>1</sup> The ultimate goal is not only to avoid sensitive structures, but to respect the established biological principles to achieve esthetic results.

### Mesiodistal criteria

Correct implant position in a mesiodistal orientation allows the clinician to avoid damaging adjacent critical structures. A minimum distance of 1.5 mm between implant and existing dentition prevents damage to the adjacent teeth and provides proper osseointegration and gingival contours<sup>2-4</sup> (Fig. 1a).

Distances of less than 3 mm between two adjacent implants leads to increased bone loss and can reduce the height of the inter-implant bone crest. A distance of more than 3 mm between two adjacent implants preserves the bone, giving a better chance of proper interproximal papillary height (Fig. 1b).

### Labiolingual criteria

An implant placed too far labially can cause bone dehiscence and gingival recession while an implant placed too far lingually can cause prosthetic difficulties. A thickness of 1.8 mm of labial bone is critical in maintaining an implant

soft-tissue profile<sup>5</sup> (Fig. 2).

Labially oriented implants compromise the subgingival emergence profile development, creating long crowns and misalignment of the collar with respect to the adjacent teeth.<sup>6</sup>

### Apico-coronal criteria

Peri-implant crestal bone stability plays a critical role in the presence of interdental papilla.<sup>7</sup> Implants placed too shallow may reveal the metal collar of the implant through the gingiva. Countersinking implants below the level of the crestal bone may give prosthetic advantages but can lead to crestal bone loss.

The ideal solution would be the placement of an implant equicrestal or subcrestal to the ridge. However, the existing microgap at the implant abutment junction leads to bone resorption because of peri-implant inflammation.<sup>8</sup> It is suggested an implant collar be located 2 mm apical to the CEJ of an adjacent tooth if no gingival recession is present<sup>9</sup> (Fig. 3).

### Implant angulation

Implant angulation is particularly important in treatment planning for screw-retained restorations. Implants angled too far labially compromise the placement of the restorative screw while implants angled too far lingually can result in unhygienic and unesthetic prosthetic design.

For every millimeter of lingual inclination, the implant should be placed an additional millimeter apically to create an optimal emergence profile.<sup>10</sup> In general, implant angulation should mimic angulation of adjacent teeth (Fig. 4). Furthermore, maxillary anterior regions require a subtle palatal angulation to increase labial soft-tissue bulk.<sup>11</sup>

### Inclusive Tooth Replacement Solution

The Inclusive<sup>®</sup> Tooth Replacement Solution was developed by Glidewell Laboratories as a complete, prosthetically driven method of restoring missing dentition. The solution is composed of treatment planning, implant placement, patient-specific temporization and the definitive restoration (Figs. 5a-5f).

When utilizing the comprehensive range of Inclusive Digital Treatment Planning services, the clinician has absolute and precise control of each step. The clinician has control of the four dimensions of implant placement in the esthetic zone, creating a consistently predictable result.

To read the full article, go to [www.inclusivemagazine.com](http://www.inclusivemagazine.com). References are available from the publisher.

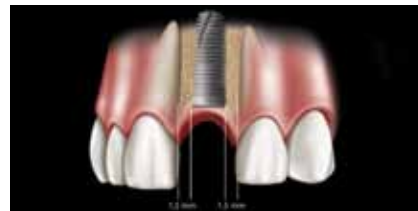


Fig. 1a: Minimum distance of 1.5 mm between implant and existing dentition. Photos/Provided by Glidewell Laboratories

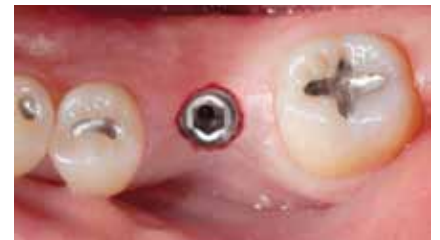

Fig. 5a: Inclusive Tapered Implant at placement.

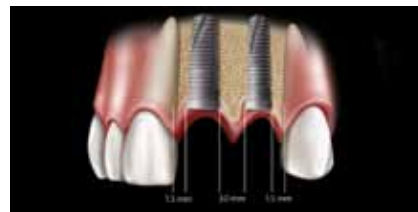


Fig. 1b: Minimum distance of 3 mm between two adjacent implants.

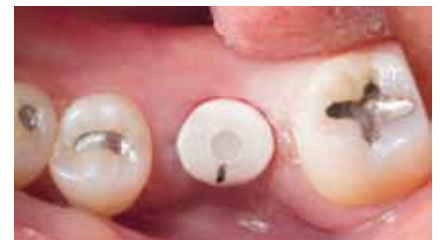

Fig. 5b: Inclusive custom healing abutment in place.

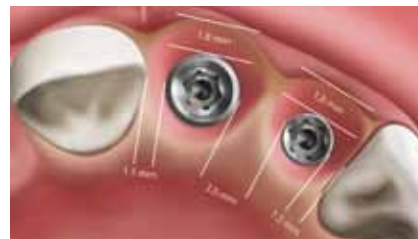

Fig. 2: Proper labiolingual placement with 1.8 mm thickness of labial bone.

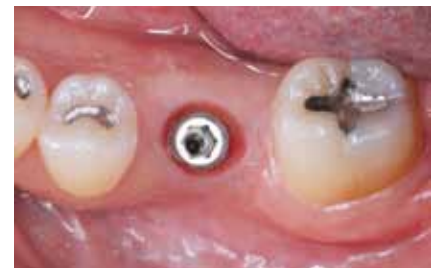

Fig. 5c: Contoured soft-tissue sulcus after healing.

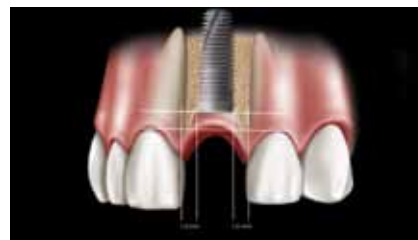


Fig. 3: Lateral view of implant placed with the collar at the level of crestal bone with adjacent teeth CEJ 2 mm coronal to the collar of the implant.

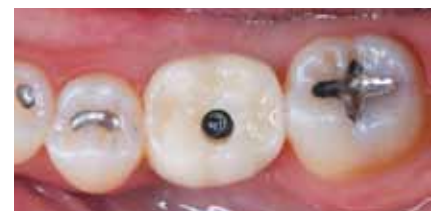

Fig. 5d: Screw-retained IPS e.max<sup>®</sup> crown (Ivoclar Vivadent; Amherst, N.Y.) in place.

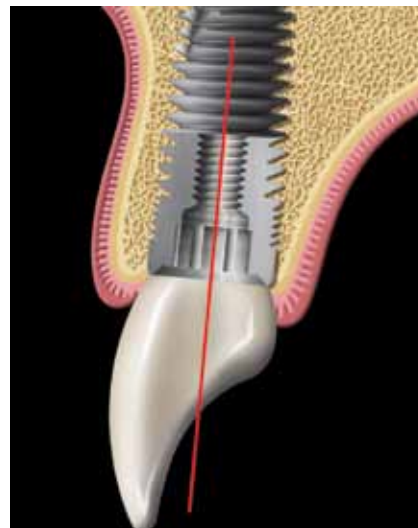


Fig. 4: Proper implant angulation with screw access in the cingulum area.

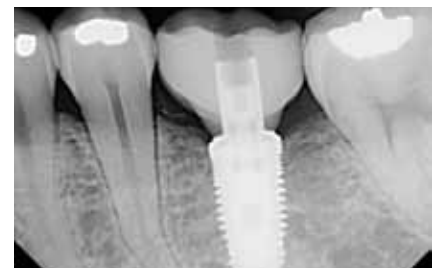

Fig. 5e: PA to verify seating of crown.

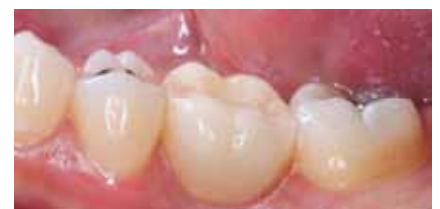
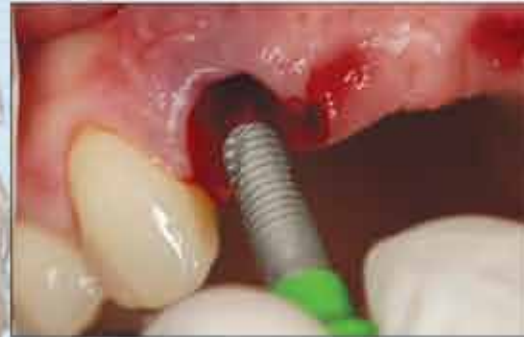
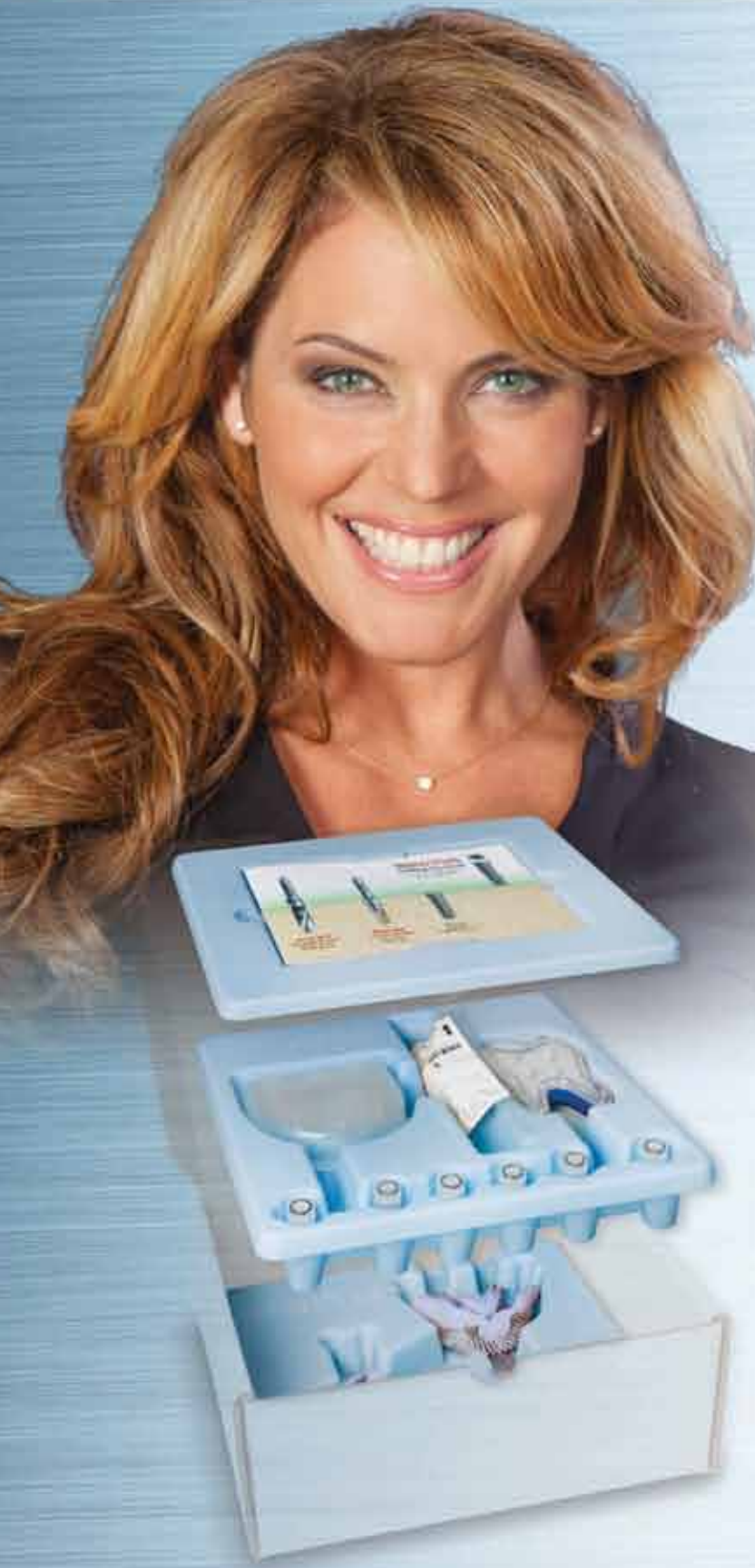Fig. 5f: Buccal view of final restoration at delivery.

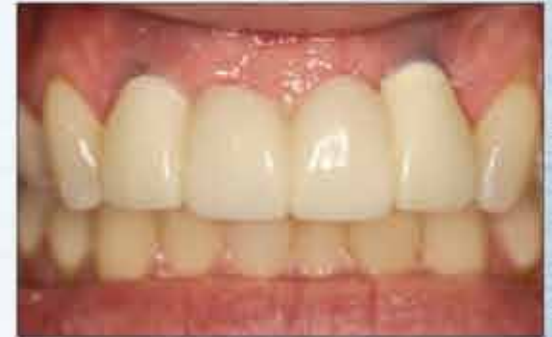

# Controlled tissue contouring for immediate loading including BioTemps® Provisionals

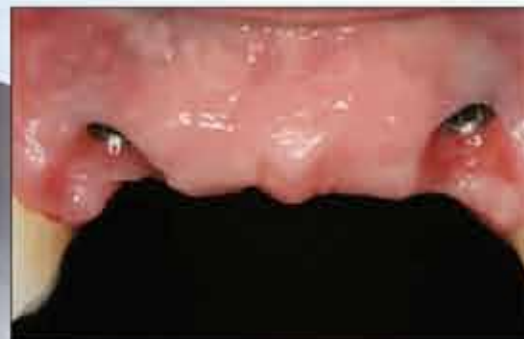## INCLUSIVE® Tooth Replacement System



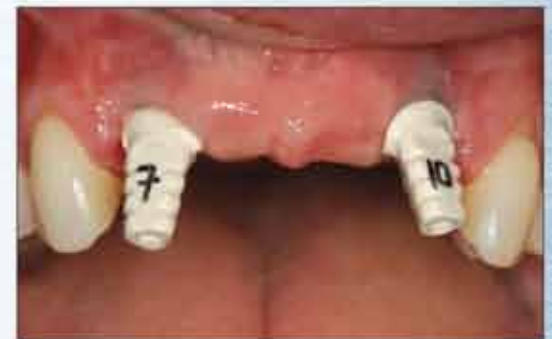A 3.7 mm X 11.5 mm Inclusive® Tapered Implant was placed in the surgical site for tooth #7, as well as tooth #10.



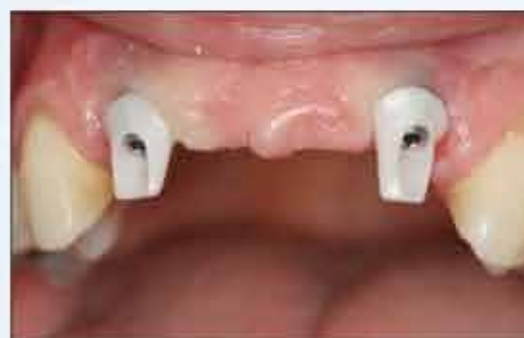BioTemps bridge #7-10 was seated, allowing for nice tissue healing prior to the final impressions.



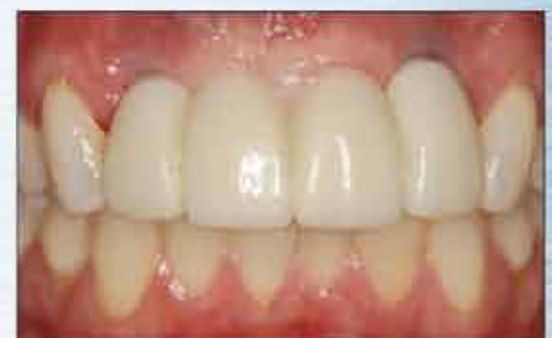After four months of integration, the BioTemps and patient-specific abutments were removed, revealing very healthy pink tissue with trained tissue contours.



The custom impression copings match the patient-specific soft tissue contours of the custom temporary components.



The final zirconia abutments were fabricated by the dental laboratory and torqued into place.



The final implant-retained bridge was cemented into place.

Clinical dentistry by Timothy F. Kosinski, DDS, MAGD

**\$695\*** Single Tooth Replacement  
(Case as shown: \$1,646\*)

**System includes: implant, drills, custom healing abutment, custom temporary abutment, BioTemps Provisional, custom impression coping, final custom abutment and ceramic crown.**

\*Price does not include shipping or applicable taxes.

For more information

**888-786-2177**

[www.inclusivedental.com](http://www.inclusivedental.com)



All Inclusive implants, abutments and components are manufactured in our Irvine, Calif., facility.



**GLIDEWELL  
LABORATORIES**

*Premium Products - Outstanding Value*

The Inclusive Tooth Replacement System is a convenient and effective method of promoting and preserving the ideal tissue contours throughout the implant treatment process. It includes treatment options for these clinical situations:

- ◆ Immediate loading with custom temporary abutment and BioTemps® Provisional
- ◆ Single-stage implant placement with custom healing abutment