

AUGUST 2010

www.implant-tribune.com

Vol. 5, No. 8



**AAID's annual meeting**  
Group to focus on implant complications, solutions

►Page 4



**Allograft products**  
How best to utilize the materials in your dental cases

►Page 6



**Astra Tech adds options**  
Atlantis abutments now include Dentsply, Straumann

►Page 21

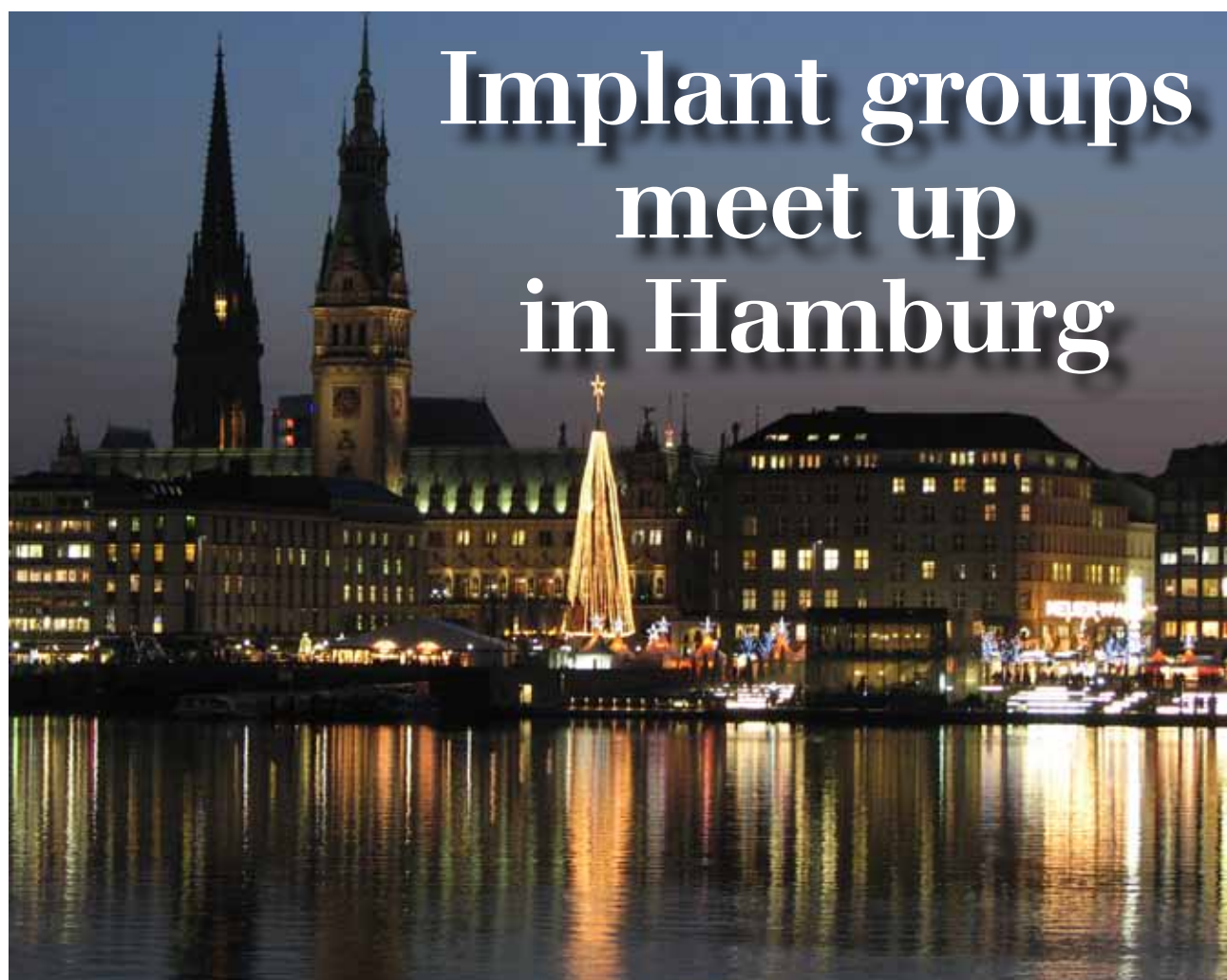

*Study indicates that weight control and physical fitness may help reduce the risk of severe gum disease. (Photo/Christy Thompson, stock.xchng)*

## Weight control could affect gums

The health complications of being overweight, such as increased risk of heart disease, Type 2 diabetes and certain cancers, have long been reported. Health-care professionals often urge patients to manage their weight and strive to get physical exercise each day to achieve and maintain overall health. And now, researchers have uncovered another benefit of maintaining a fit lifestyle: healthy teeth and gums.

In a study published in the August issue of the *Journal of Periodontology*, researchers found that subjects who maintained a healthy weight and had high levels of physical fitness had a lower incidence of severe periodontitis. Using body

→ **T** page 2

*The ICOI and DGOI will join forces from Aug. 26–28 at the Hamburg Convention Center. (Photo/stock.xchng)*

## ICOI, DGOI join up for implant program in Germany

**T**his year, the International Congress of Oral Implantologists (ICOI) will be holding its 27th World Congress in cooperation with the

German Society for Oral Implantology (DGOI) for the second time in only five years.

From Aug. 26–28, leading international members of the implant scene will get together at the Hamburg Convention Center for the 7th International Annual Congress of the DGOI and the 27th World Congress of the ICOI.

This joint congress once again shows the closeness between the German Society for Oral Implantology and its international parent organization.

The scientific directors of the main podium for 2010 will be Dr. Hom-Lay Wang from the United States, representing the ICOI, and Dr. Georg Bayer from Germany, president of the DGOI.

The program will cover the following topics: "Digital Planning for Exact Implant Positioning," "Complications and Problem Man-

agement," "Innovations in Implant Therapy," "Growth Factors and Predictable Bone Regeneration" and "Predictable Aesthetics: Concepts For Success."

More than 30 international speakers will be presenting evidence-based assessments and introducing new developments in oral implantology.

In addition to the main podium schedule, the congress will: devote Saturday morning to young implantologists; have a two-day auxiliary program for staff members; allow for many international members to participate in the congress via an extensive table clinic and poster presentation competition; and feature several workshops compliments of sponsors on Thursday morning.

For more information, visit [www.icoi.org](http://www.icoi.org). **T**

PRSRT STD  
U.S. Postage  
PAID  
Permit # 306  
Mechanicsburg, PA

Dental Tribune America  
213 West 35th Street  
Suite #801  
New York, NY 10001

← **IT** page 1

mass index (BMI) and percent body fat as a measure of weight control, and maximal oxygen consumption (VO2max) as a measure of physical fitness, researchers compared subjects' weight and fitness variables with the results of a periodontal examination. Those with the lowest BMI and highest levels of fitness had significantly lower rates of severe periodontitis.

Periodontitis is a major cause of tooth loss in adults, and research has suggested gum disease is associated with other diseases, such as heart disease, diabetes and rheumatoid arthritis.

Samuel Low, DDS, MS, associate

dean and professor of periodontology at the University of Florida College of Dentistry and president of the American Academy of Periodontology (AAP), says that research connecting overall health and periodontal health should motivate people to maintain a healthy weight and get enough physical fitness.

"Research continues to demonstrate that our overall health and oral health are connected," Low said. "Weight management and physical fitness both contribute to overall health; and now we believe staying in shape may help lower your risk of developing gum disease."

"Since gum disease is related to other diseases, such as cardiovascular disease and diabetes, there is even more reason to take care

of yourself through diet and exercise."

Low also encourages comprehensive periodontal care through daily tooth brushing and flossing, and routine visits to a dental professional, such as a periodontist. **IT**

### About the AAP

The American Academy of Periodontology (AAP) is the professional organization for periodontists. Periodontists are also dentistry's experts in the treatment of oral inflammation. They receive three additional years of specialized training following dental school, and periodontics is one of the nine dental specialties recognized by the American Dental Association. The AAP has 8,000 members worldwide.

## 3-D congress a crowd-pleaser

The fourth International Congress on 3-D Dental Imaging, sponsored by Imaging Sciences International and Gendex Dental Systems, held this year in La Jolla, Calif., offered attendees and the dental media an ideal setting in which to learn about 3-D technology.

Experienced dental clinicians and professionals shared their considerable knowledge of 3-D's past, where it is today and where it's going in the future. Attendees were provided with a wealth of information from speakers and vendors that assisted them in their practical application of the everexpanding technology.

The two-day congress utilized lectures, panel discussions, break-out sessions and live demonstrations to allow for full participation and interaction among those gathered at the event.

Attendee Dr. Christopher Phelps of Charlotte, N.C., said: "There was definitely a myriad of course topics here, including detailed clinical information. And for those of us who already have the technology, it was helpful to have courses that focus on non-clinical aspects, as well, such as marketing and both medical and dental insurance reimbursement."

A new speaker at this year's congress, Dr. John Graham, focused on clinical findings not apparent with 2-D radiology and staying ahead of the curve when it comes to dentistry's evolving standard of care involving CB/CT.

"The dentists who attended the congress were looking to learn more about a technology that can help them advance patient care," he said. "I believe that they came away with



Attendees of the 4th International Congress on 3-D Dental Imaging pay close attention to the presentation. (Photo/Provided by Imaging Sciences/Gendex)

a greater understanding of this and more."

Returning speaker and moderator, Dr. Scott D. Ganz, presented on how the utilization of cone-beam data provides clinicians with a new sense of confidence to diagnose, plan, communicate and execute dental implant reconstruction and related procedures, such as bone grafting. As Ganz said, "It's not the scan, it's the plan!"

Commenting on the congress' other clinical courses, Ganz added: "Attendees benefited greatly from world-class speakers who illustrated a variety of applications for both general and specialty practices."

Dr. Sharnell Muir spoke on the use of CBCT in conjunction with CAD/CAM applications that, in part, covered the process of in-office milling of surgical guides and restorations.

Mark Hillebrandt, director of product management for ISI and Gendex, said: "Dr. Muir's presentation gets right to the heart of how dynamic 3-D technology is — the ability to simultaneously plan restorations and implants in a single piece of software is a game changer for how patient-

driven dentistry is accomplished. She very effectively illustrated the power of a brand new level of CBCT-CAD/CAM integration."

Also in attendance, Henrik Roos, president of Imaging Sciences and Gendex, noted the attendees were very eager to learn about the benefits of 3-D technology.

"We are proud to sponsor this comprehensive educational event that offers dentists the information they seek — how to better treat their patients and how to expand services in their practices," he said.

The companies also announced the upcoming fifth International Congress on 3-D Dental Imaging will be held in Dallas at the Gaylord Texan from Nov. 4–5, 2011.

The ISI and Gendex dedication to education is exemplified in their collaboration to deliver quality courses on 3-D imaging. Events include introductory webinars, interactive regional meetings and local training sessions provided by knowledgeable dental professionals. Visit [www.i-CAT3D.com](http://www.i-CAT3D.com) for a complete course listing and registration information. **IT**

## IMPLANT TRIBUNE

The World's Newspaper of Implantology - U.S. Edition

### Publisher & Chairman

Torsten Oemus  
[t.oemus@dental-tribune.com](mailto:t.oemus@dental-tribune.com)

### Vice President Global Sales

Peter Witteczek  
[p.witteczek@dental-tribune.com](mailto:p.witteczek@dental-tribune.com)

### Chief Operating Officer

Eric Seid  
[e.seid@dental-tribune.com](mailto:e.seid@dental-tribune.com)

### Group Editor & Designer

Robin Goodman  
[r.goodman@dental-tribune.com](mailto:r.goodman@dental-tribune.com)

### Editor in Chief

Sascha A. Jovanovic, DDS, MS  
[sascha@jovanoviconline.com](mailto:sascha@jovanoviconline.com)

### Managing Editor/Designer

Implant & Endo Tribunes  
Sierra Rendon  
[s.rendon@dental-tribune.com](mailto:s.rendon@dental-tribune.com)

### Managing Editor/Designer

Ortho Tribune & Show Dailies  
Kristine Colker  
[k.colker@dental-tribune.com](mailto:k.colker@dental-tribune.com)

### Online Editor

Fred Michmershuizen  
[f.michmershuizen@dental-tribune.com](mailto:f.michmershuizen@dental-tribune.com)

### Account Manager

Humberto Estrada  
[h.estrada@dental-tribune.com](mailto:h.estrada@dental-tribune.com)

### Marketing Manager

Anna Wlodarczyk  
[a.wlodarczyk@dental-tribune.com](mailto:a.wlodarczyk@dental-tribune.com)

### Marketing & Sales Assistant

Lorrie Young  
[l.young@dental-tribune.com](mailto:l.young@dental-tribune.com)

### C.E. Manager

Julia Wehkamp  
[j.wehkamp@dental-tribune.com](mailto:j.wehkamp@dental-tribune.com)

Dental Tribune America, LLC  
213 West 35th Street, Suite 801  
New York, NY 10001  
Phone: (212) 244-7181, Fax: (212) 244-7185



Published by  
Dental Tribune America

© 2010, Dental Tribune America, LLC  
All rights reserved.

Dental Tribune makes every effort to report clinical information and manufacturer's product news accurately, but cannot assume responsibility for the validity of product claims, or for typographical errors. The publishers also do not assume responsibility for product names or claims, or statements made by advertisers. Opinions expressed by authors are their own and may not reflect those of Dental Tribune International.

### Editorial Advisory Board

**Dr. Sascha Jovanovic, Editor in Chief**

Dr. Bernard Touati

Dr. Jack T. Krauser

Dr. Andre Saadoun

Dr. Gary Henkel

Dr. Doug Deporter

Dr. Michael Norton

Dr. Ken Serota

Dr. Axel Zoellner

Dr. Glen Liddelow

Dr. Marius Steigmann

### IT Corrections

Implant Tribune strives to maintain the utmost accuracy in its news and clinical reports. If you find a factual error or content that requires clarification, please report the details to Managing Editor Sierra Rendon at [s.rendon@dental-tribune.com](mailto:s.rendon@dental-tribune.com).

## Tell us what you think!

Do you have general comments or criticism you would like to share? Is there a particular topic you would like to see more articles about? Let us know by e-mailing us at [feedback@dental-tribune.com](mailto:feedback@dental-tribune.com). If you would like to make any change to your subscription (name, address or to opt out) please send us an e-mail at [database@dental-tribune.com](mailto:database@dental-tribune.com) and be sure to include which publication you are referring to. Also, please note that subscription changes can take up to 6 weeks to process.



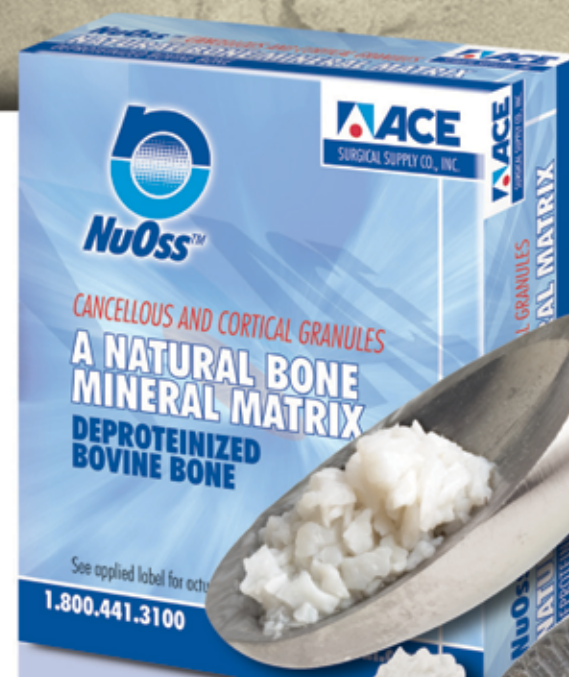# NuOss™

## The NU CHOICE IN BONE REGENERATION

### A NATURAL, POROUS BONE MINERAL MATRIX

**BUY ANY 5 NuOss  
VIALS or BLOCKS  
and GET 1 FREE\***

Offer good during September 2010.



### NuOss™ DEPROTEINIZED BOVINE BONE

**NuOss™** — A natural porous bone mineral matrix produced by the removal of all organic components from bovine bone. Due to its natural structure, NuOss™ is physically and chemically comparable to the mineralized matrix of human bone.

**NuOss™ Collagen** — A natural bone substitute that promotes bone growth in both periodontal and maxillofacial defects. NuOss™ Collagen is made up of cancellous granules mixed with approximately 5% of bovine collagen. Once moistened the NuOss Collagen is moldable and can be placed in most defects.

#### Typical Uses:

- Ridge Augmentation
- Filling of infrabony periodontal defects
- Filling of extraction sockets
- Elevating the maxillary sinus floor
- Filling of peri-implant defects





# AAID to navigate implant complications



*59th annual meeting  
will take place  
Oct. 20-23 in Boston*

Complications and how to identify and overcome them will be one focus of the American Academy of Implant Dentistry's 59th annual meeting, to be held Oct. 20-23 at the Boston Marriott Copley Place.

The theme for the meeting is "Navigate Zones of Implant Dentistry: Complications, Confidence, Comfort."

As always, the scientific program

will showcase an international cast of speakers and offer comprehensive implant dentistry continuing education.

According to organizers, the event is highly regarded in the dental profession as an innovative forum and valuable resource for continuing education, product demonstrations and networking. More than 1,600 dentists, allied staff and exhibitors are expected to attend.

Each AAID speaker will cover his or her topic from three different approaches — experience of the practitioner, what complications could be encountered and what solutions are available.

Surgical as well as restorative aspects of implant dentistry will be addressed. Hard- and soft-tissue challenges also will be covered.

The schedule of presentations and events for the AAID meeting is available at [www.aid.org](http://www.aid.org).

"Dental implant growth in the United States has been exceptional in recent years due to technology advances and increasing public awareness that implant procedures are more than 97 percent successful and are the preferred method for replacing lost teeth," said AAID President Joel Rosenlicht, DMD.

"As a result, the AAID annual meeting is the essential resource for dental implant practitioners for cutting-edge information from world-class experts in the field and practical knowledge they can apply every day in their practices." ■

## About AAID

The AAID is the leading professional society dedicated to maintaining the highest standards of implant dentistry through research and education. The annual meeting is the field's leading venue for cutting-edge, evidence-based implant research presentations and demonstrations of state-of-the-art implantation techniques.

The AAID can help consumers find a local credentialed implant dentist at [www.aid.com](http://www.aid.com). The AAID is based in Chicago and has more than 3,500 members. It is the first organization dedicated to maintaining the highest standards of implant dentistry by supporting research and education to advance comprehensive implant knowledge.

AD

**AAID** 59<sup>th</sup> Annual Meeting Boston October 20-23, 2010  
AMERICAN ACADEMY OF IMPLANT DENTISTRY

**NAVIGATE ZONES  
OF IMPLANT DENTISTRY**

**Complications  
Confidence  
Comfort**

**3 1/2 days of comprehensive  
implant dentistry education**

Register by September 20, 2010 and save \$100  
312.335.1550 or 877.335.AAID (2243) • [www.aid.com](http://www.aid.com)

**Looking for  
more dental  
news?**

See [www.dental-tribune.com](http://www.dental-tribune.com)  
for dental news and  
much more



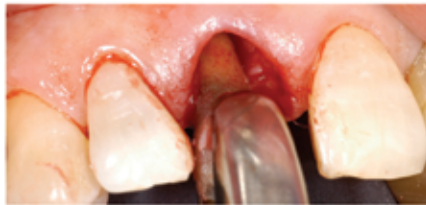
# CAN SOCKET GRAFTING WITHOUT PRIMARY CLOSURE BE PREDICTABLE?



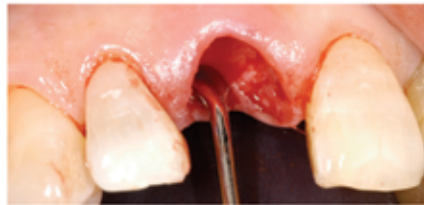**12 mm x 24 mm | Actual size**

For years, primary closure was considered a key principle for successfully grafting extraction sockets. However, with the introduction of the Cytoplast Technique for grafting extraction sites without primary closure, thousands of surgeons now prefer to use dense PTFE membranes left exposed to preserve soft tissue architecture, preserve keratinized tissue width and avoid infection.<sup>1,2</sup> In two separate studies treating a total of 696 extraction sites using Cytoplast® d-PTFE membranes in an exposed technique\*, there were no reported infections.<sup>1,3</sup>

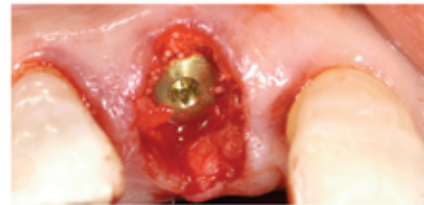1 Hoffman O, Bartee BK, Beaumont C, Kasaj A, Deli G, Zafiropoulos GG. Alveolar bone preservation in extraction sockets using non-resorbable dPTFE membranes: A retrospective non-randomized study. J Periodontol 2008; 79:1355-1369 2 Fotek PD, Neiva RF, Wang HL. Comparison of dermal matrix and Polytetrafluoroethylene membrane for socket bone augmentation: A clinical and histologic study. J Periodontol 2009; 80:776-785 3. Barboza EP, Stutz B, Ferreira VF, Carvalho W. Guided bone regeneration using non-expanded polytetrafluoroethylene membranes in preparation for dental implant placements-A report of 420 cases. Implant Dent 2010 19(1):2-7. \*Studies used no graft materials under membranes.



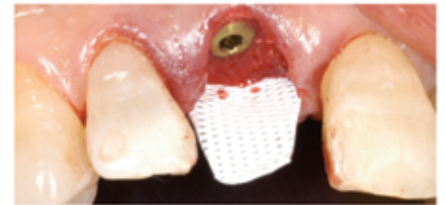
Due to a crown-root fracture, the right central incisor has to be extracted. Immediate implant placement is planned.



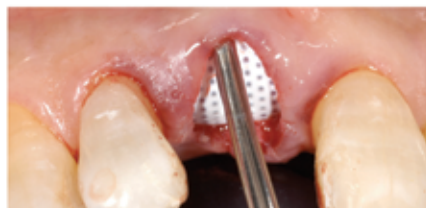The interdental papillae is carefully undermined and elevated. All remaining soft tissue is removed from the interior and margins of the socket.



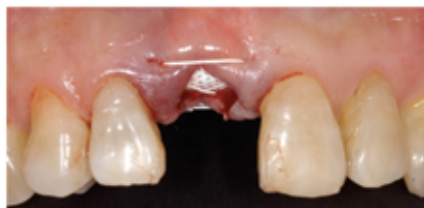The gap between the facial aspect of the implant and the buccal wall is filled with a combination of autogenous bone chips and allograft bone.



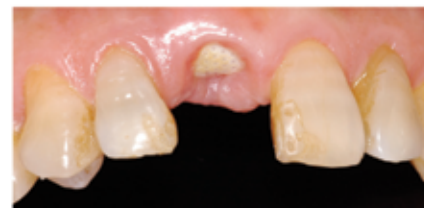A textured, high-density PTFE barrier membrane (Cytoplast® TXT-200 Single) is placed. The membrane is trimmed, then placed into the subperiosteal pocket on the palatal aspect.



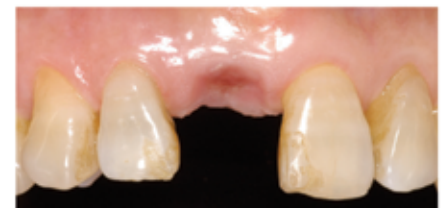The membrane is then tucked under the facial flap and the interdental papillae, taking care to keep the edge of the material a minimum of 1.0 mm away from adjacent tooth roots.



A single 3-0 PTFE suture (Cytoplast® PTFE Suture) is placed to further stabilize the membrane. The membrane is intentionally left exposed, as primary closure is not required in this technique.



At 3 weeks, the exposed membrane is easily removed by grasping with tissue forceps. Topical anesthesia may be used, but local anesthesia is not necessary.



At 6 weeks after implant placement (three weeks after membrane removal), keratinized mucosa is forming across the former extraction site.

**SPECIAL OFFER: \$50 OFF** each box of TXT-200 Singles.  
(10 per box, reg. \$400) **Mention Offer Code: IT810.** Offer expires September 30.

**BONUS: Free 2nd Day shipping** to the first 10 orders.

**FREE GIFT:** With every box, receive **TWO FREE PTFE SUTURE SAMPLES!**



# Biological allograft products applied to dentistry

By Jason Yamada, DDS, MS

The advent of human bone grafting has led to applications within the specialties of dental and sinus reconstructive surgery for corrections to maladies such as ridge augmentations, sinus elevations and repair of other bony defects.

There are a myriad of specialized allograft products for various dental, oral and sinus reconstruction. This article describes products for use by general practitioners, endodontists, oral surgeons, maxillofacial surgeons, periodontists and other related specialties.

The preparation of targeted bone grafts for the mandible and maxilla include the preservation of minerals and collagen while removing inactive pathogens, antigens, fatty tissues and other decayed materials.

The minerals and collagen become the building blocks to complete and rapid bone regeneration as the expected outcome for your patients.

Mandible and maxilla bone grafts can be applied to dental surgery procedures for needed graft areas to fill voids left by bone decay and loss, for sinus grafts or for implants.

Preservation of such grafts should

include at least a five-year shelf life at room temperature. Specific types of biological allografts for these uses are described next.

The block allograft eliminates the need for autogenous bone harvest-

ing as it includes implantable corticocancellous bone.

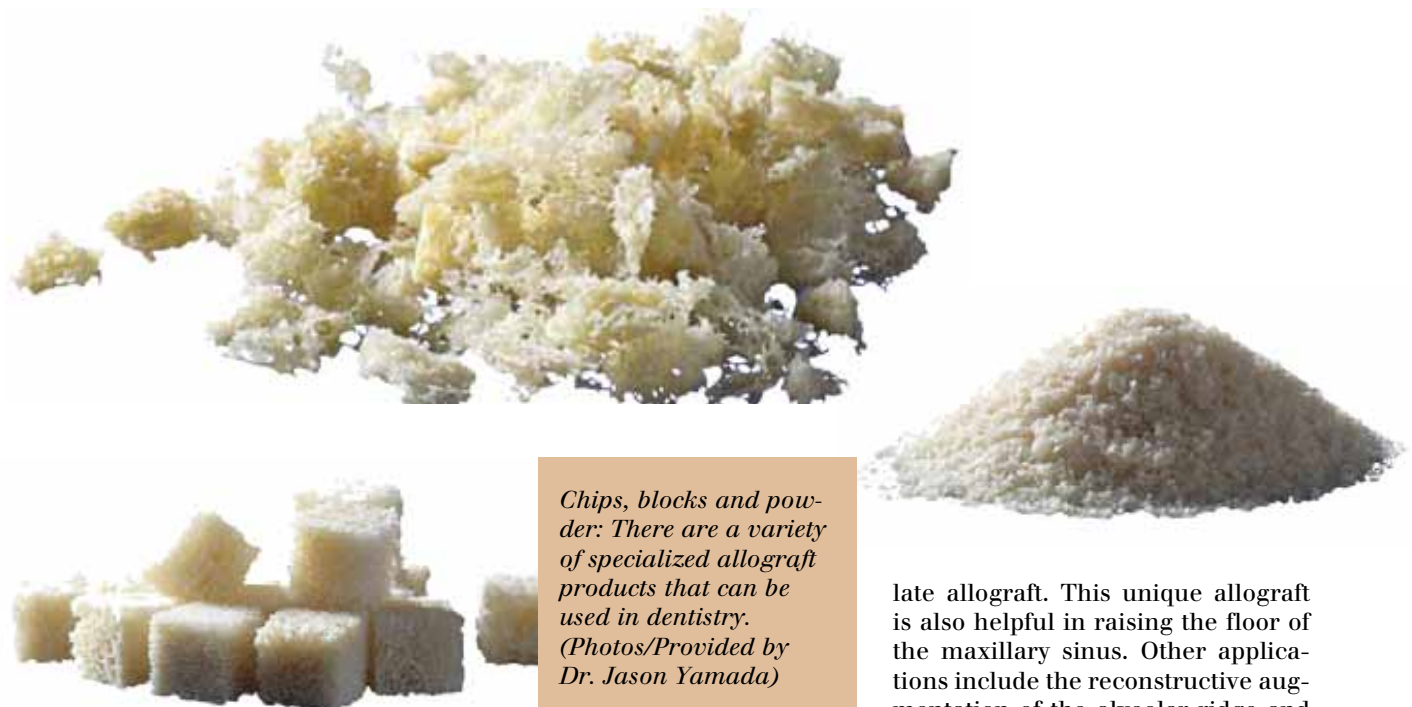A secondary benefit of this allograft is that it virtually eliminates the need for a follow-up surgery, improving efficiency and shortening the patient's rehabilitation time. The block allograft comes sterile and ready to use when needed. It makes a fine, stable ridge augmentation in preparation for subsequent implants in patients with verifiable loss of bone volume due to atrophy. Typical sizes are between 10 to 15 mm.

The cortical allograft includes a high-quality, malleable bony structure that can be used to effectively maintain spatial volume, such as the cases of sinus elevation, extraction sockets and augmented ridges. When implanted, it acts as a barrier membrane to bacteria and other decaying agents.

Subsequent dental implants are accomplished and supported by generation and remodeling of critical vascular bone tissues. Cortical allograft sizes range from 250 to 2,000 microns and volumes between 0.5 to 2.0.

The cancellous particulate allograft can absorb its own weight in fluid due to its malleability and elasticity. The allograft forms an exceptional biological incubation area via a demineralized matrix to allow the in-growth of red blood cells to aid the remodeling process. This allograft has been a reliable choice for many dental and oral surgeons as it is known for its effective and efficient bone regeneration properties.

During the regeneration process, healthy natural bone is incorporated into the remodeling. Future implantation for prosthetic therapy can be placed with great results due to the localized augmentation of the ridge. Extraction sockets with osseous defects are also effectively filled using the cancellous particu-




*Chips, blocks and powder: There are a variety of specialized allograft products that can be used in dentistry. (Photos/Provided by Dr. Jason Yamada)*

late allograft. This unique allograft is also helpful in raising the floor of the maxillary sinus. Other applications include the reconstructive augmentation of the alveolar ridge and the reparation of defective infrabony periodontal structures.

If you are in the market to purchase human bone allografts, select products with the American Association of Tissue Banks accreditation to ensure you get the best uniform quality and standards. ■


AD

plan and position implants  
**ACCURATELY**



**GENERATION 11**

Bending Tool

 **Guide Right™ by DePlaque**

System of Components

allowing YOU to

FABRICATE \* EVALUATE \* POSITION \* PLACE

guide sleeves in a surgical template  
can be used with 3D cone beam imaging  
in your office or by a lab  
designed and used by a dentist

FOR PRECISION IMPLANT PLACEMENT

Call and mention this ad for 1<sup>st</sup> order  
**20% DISCOUNT & INSTRUCTIONAL CD**  
**800.314.0065**

www.deplaque.com

## IT About the author



Jason M. Yamada, DDS, MS, was born and raised in Honolulu and received his DDS degree from the University of Southern California and his specialty degree in periodontics and a master of science in oral biology from Northwestern University. He is currently assistant clinical professor in the advanced graduate education program in periodontics and implant surgery at Loma Linda University Dental School and has been a guest lecturer at both USC Dental School and UCLA Dental School. Yamada currently practices in Torrance, Calif., and Irvine, Calif., with an emphasis on implant surgery and restoration, microsurgery and periodontal surgery. He is the founder of the Implant and Periodontal Institute of Torrance (IPI) and has taught many general dentists as well as specialists on the topics of periodontal, cosmetic and implant surgery.

# Quick and easy prosthetic planning

By Dr. Lieven Renier and Dr. Dominik Muylaert

The primary and most important complaint of this 17-year-old woman was lack of esthetics. She also complained about tooth mobility and limited functional comfort. She was afraid to lose her teeth at "any moment."

## Anamnesis

At the age of 4, an embryonic sarcoma of the naso-pharynx was diagnosed. The sarcoma was treated with chemotherapy, followed with radiotherapy.

As a result of this therapy in the very early stage of facial forming, growth of the maxilla and all structure in the field of view of radiotherapy were compromised.

## Clinical and radiological examination (Figs. 1-3)

- 1) Lack of an esthetically pleasing smile line, resulting in reduced self-confidence.
- 2) Pseudo Class III because of hypoplasia of the maxilla.
- 3) No root formation in the maxilla, causing tooth mobility and functional disorders.
- 4) No sinus formation.
- 5) Missing upper lateral incisors and lower canine.

## Initial treatment plan

The initial treatment plan was based on the clinical and basic radiological examination.

- Prophylaxis and oral hygiene instruction.
- Fixed orthodontic appliance in the lower jaw.
- At the age of 18, extraction of the upper teeth, except tooth #16 and #26.
- Removable temporary restoration.
- Three-month healing period.
- 3-D imaging and treatment planning with SimPlant® (Materialise Dental).
- 20 sessions of hyperbaric oxygen therapy.
- Flapless computer-guided implant surgery (Facilitate®, Astra Tech).
- 10 sessions of hyperbaric oxygen therapy and six-months healing period.

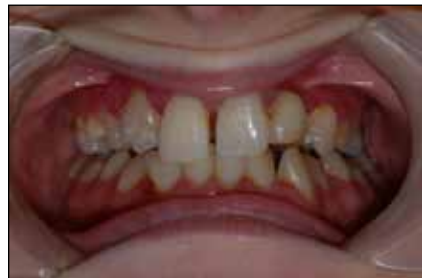

Fig. 1: Initial visit.

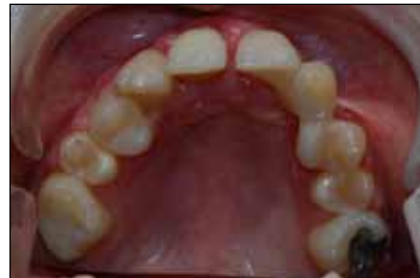

Fig. 2: Initial clinical exam.

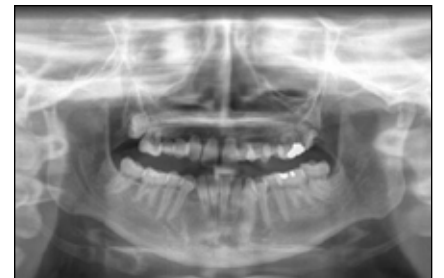

Fig. 3: Initial radiological exam.

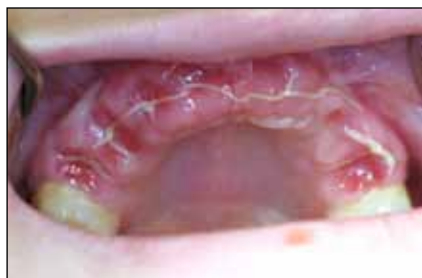

Fig. 4: Extraction of upper teeth.

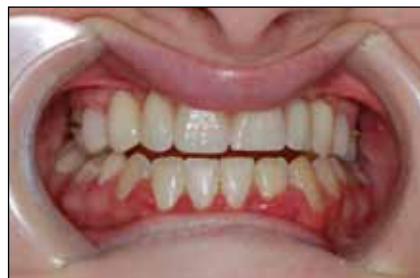

Fig. 5: Temporary prosthesis.

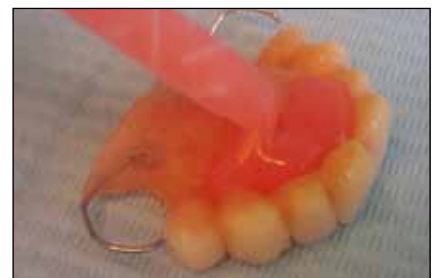

Fig. 6: Relining of prosthesis.

ing period.

- Final prosthetic restoration

## Pretreatment and preparation for guided surgery (Figs. 4,5)

Extraction of the upper teeth except tooth #16 and #26, which will be used as anchorage for the temporary restoration.

Before extraction of the teeth, a temporary removable prosthesis was made, which was seated the day of surgery, so the patient did not have to leave the hospital without teeth.

Original tooth set-up was compensated for and adapted to a more symmetric and esthetic appearance.

Lower teeth were already aligned using fixed orthodontics.

## Converting temporary prosthesis into a scan prosthesis (Figs. 6, 8-12)

The Dual Scan Package (Materialise Dental) includes all dental products that are necessary to convert an existing, radiolucent prosthesis into a scan prosthesis.

For each clinical procedure, there are clear guidelines to give instruction of how to use the prod-

ucts correctly.

## Relining of the temporary prosthesis

First step was to reline the prosthesis chair-side. It is very important to use suitable radiolucent relining material as some materials on

the market are radiopaque, thereby causing scatter and artifacts in the images. Relining will enhance patient comfort and accuracy of the additional steps.

The Dual Scan Package contains

→ [page 9](#)

AD

**Send  
us  
your  
case  
study!**

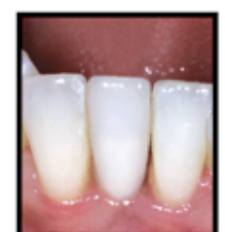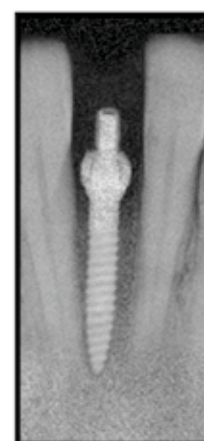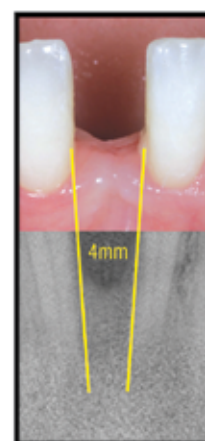
Have an interesting implant case you would like to share with 15,000 of your peers? To have your case study considered for publication in Implant Tribune, send your 800- to 1,200-word case study and up to 12 high-resolution photos to Managing Editor Sierra Rendon at [s.rendon@dental-tribune.com](mailto:s.rendon@dental-tribune.com). Authors will be notified of publication and have an opportunity to review the designed case study prior to final publication. Cases will be published pending editor approval and space availability.

**Dentatus**

**Anew** NARROW body implants

DESIGNED TO FIT

where **no** others can



Anew Implants in 1.8, 2.2 & 2.4mm are FDA indicated for long-term support of crowns and multi-unit restorations. Designed to fit in limited bone & narrow spaces.

The Anew Implant & Prosthetic System was developed in conjunction with NYU School of Dentistry.

For more information on upcoming courses visit us at [www.dentatus.com](http://www.dentatus.com) or call us at (800) 323-3136



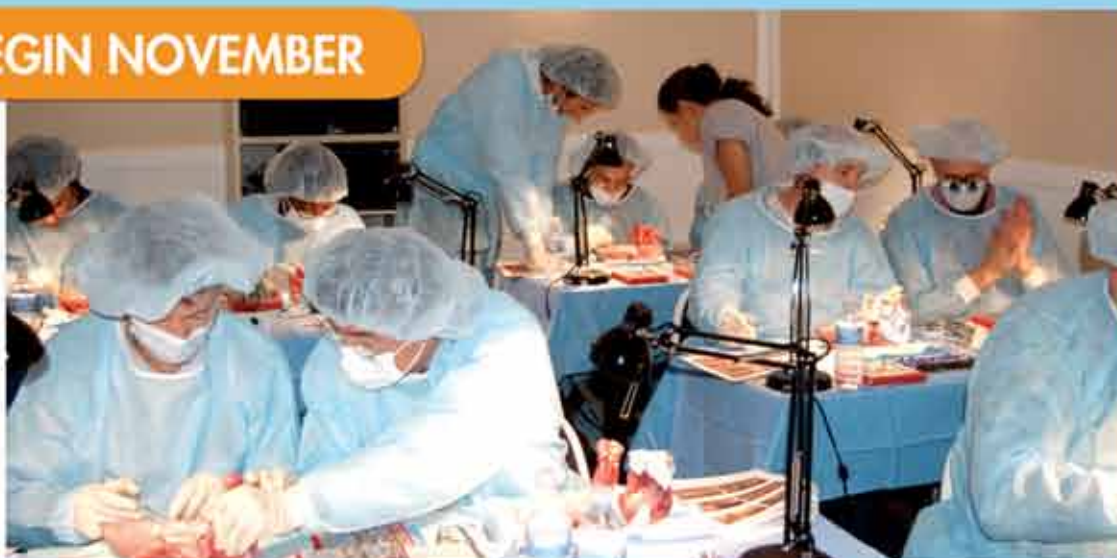gIDE / UCLA 2010  
2011

# NORTH AMERICA

## 1-YEAR MASTER CLINICIAN PROGRAM IN IMPLANT DENTISTRY

**REGISTER NOW - COURSES BEGIN NOVEMBER**

- Expert Faculty
- Live Surgery
- Case Presentations
- Hands-on
- 17 Days of Classroom
- 350 Total CE Hours



### MAIN PROGRAM OBJECTIVES:



- A proven surgical and restorative implant program combining classroom, live patient, hands-on, case planning plus leading self-study online material
- Learn to perform new and routine implant procedures in minimally-invasive, efficient and cost-effective ways
- Learn advanced esthetic implant therapy, full mouth reconstruction, ridge and sinus bone grafting
- Graduate with 2 world-class Certificates from gIDE Institute and UCLA CED

"I've put a lot of money into my dental practice and taken lots of courses and CE but the single most valuable thing I've done, with highest return on investment, is to take the gIDE Master Clinician Program. I would recommend it to everybody." - Dr. Joe Xantopoulos, Victoria, Australia, Australasia Master Clinician Program 2009-2010



Dr. Sascha Jovanovic  
Chair & Session I-III



Dr. George Perri  
Faculty Session I



Dr. Harel Simon  
Faculty Session II



Dr. Joseph Kan  
Faculty Session III



Dr. Henry Takei  
Faculty Session IV



Dr. Ed McLaren  
Faculty Session IV

Register Online at [gIDEdental.com](http://gIDEdental.com). Contact [info@gIDEdental.com](mailto:info@gIDEdental.com) or Call +1 310 696 9025

**ADA CERP**® | Continuing Education  
Recognition Program

gIDE Institute is an ADA CERP Recognized Provider. ADA CERP is a service of the American Dental Association to assist dental professionals in identifying quality providers of continuing dental education. ADA CERP does not approve or endorse individual courses or instructors, nor does it imply acceptance of credit hours by boards of dentistry. gIDE Institute designates this activity for 350 continuing education credits.



← page 7

a sample product of Triad® Dualine® (Trubyte).

### Fabrication of a bite index

A bite index ensures that the prosthesis remains well-positioned and the jaws stabilized at the time of scanning. Make sure to use a radio-lucent silicone material.

The Dual Scan Package contains a sample product of Aquasil Bite® (DENTSPLY Caulk).

### Integrating the Dual Scan Markers

Dual Scan Markers (Materialise Dental) are prefabricated markers and can be integrated in or glued on the surface of the prosthesis. The Dual Scan Markers do not cause scatter, even in CB/CT images, which allows for a correct registration in SimPlant.

It is very important to use a radio-lucent resin to fixate the markers; otherwise their visibility in the images will be disturbed. Exercise caution in product selection as most materials for fabrication of temporary restorations are radiopaque.

The surface was roughened a little bit and eight markers were glued on the outer surface of the prosthesis.

It is important to distribute the markers, some close to the outer border and others close to the tooth-gingiva border.

The same day after the scan was taken, the Dual Scan Markers were removed. When the surface is only roughened and no bonding agent is used, this process is very easy to follow.

The Dual Scan Package contains a sample product of Triad Dualine (Trubyte). It is a dual-cure resin, which allows for fast fixation of the markers when light cured.

### 3-D imaging and integration of the prosthetic information in SimPlant planning

Two scans were taken with the Scanora® (Soredex) cone-beam 3-D scanner.

The first scan was of the patient wearing the prosthesis with markers and bite index. The second scan was of the prosthesis alone.

It is very important that during the second scan, the prosthesis is positioned in the same way as in the first scan! Both scan data sets were named similarly and saved in a separate folder.

First, the scan images of the patient wearing the scan prosthesis were loaded into SimPlant Pro. Next, using the Dual Scan Module registration wizard, the scan images of the prosthesis were loaded into SimPlant Pro and automatically matched with the original patient data.

### Final treatment plan

Based on the prosthetic information and anatomy, the final treatment plan was made and communicated to the patient and her parents.

During evaluation of the patient's anatomy, it appeared as if implant

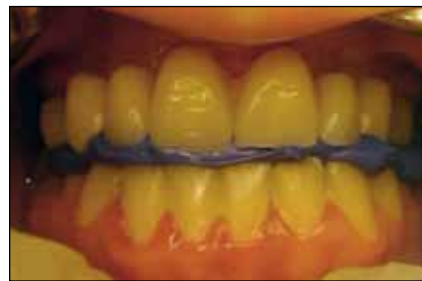

Fig. 8: Bite index.

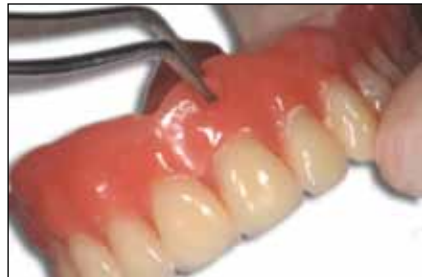

Fig. 11: Markers glued on the surface of the temporary prosthesis

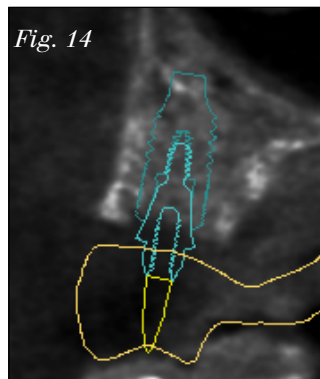


Fig. 14

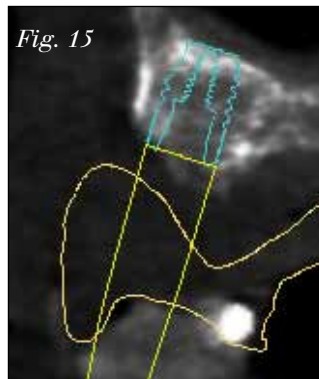


Fig. 15

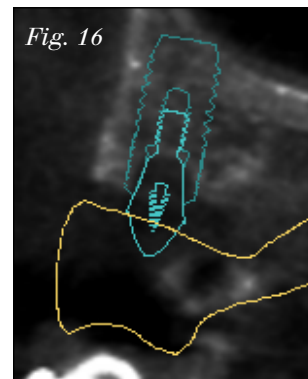


Fig. 16

Figs. 14–16: SimPlant Implant treatment planning. (Materialise Dental)

treatment would not be possible without an onlay bone augmentation procedure.

Taking into account the medical history, bone augmentation procedure was not advisable.

When combining the prosthetic information of the temporary prosthesis (which pleased the patient) from an esthetic point of view, the treatment plan needed to be reconsidered.

Taking into account the prosthetic set-up, implant treatment seemed more realistic despite the limited vertical bone height.

As can be seen in the images, this is a very small jaw with a short dental arch, which means that occlusal force will also be limited. Six Osseospeed® (Astra Tech) implants were planned; three of 6 mm, one of 8 mm and two of 9 mm.

At position #11 and #21, no implants were planned because of limited bone volume near the foramen and to avoid phonetic complaints. A pontic design in the frontal area allows for more prosthetic freedom.

Two fixation screws were planned, more or less in the same direction of the implants, to avoid tilting the guide. The more vestibular direction allows for placement during closure with the surgical guide.

### Implant surgery

A SAFE SurgiGuide® (Facilitate, AstraTech) was chosen to allow for

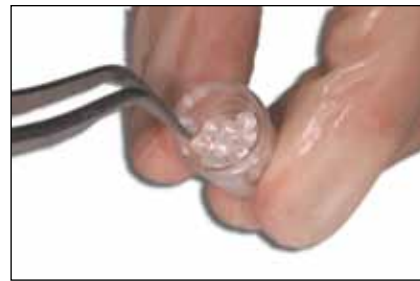

Fig. 9: Dual Scan Markers (Materialise Dental)

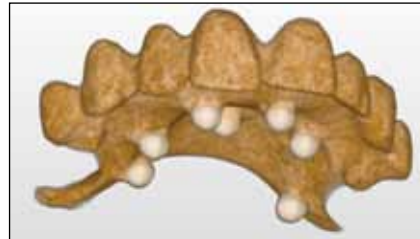

Fig. 12: Occlusal view of prosthesis with Dual Scan markers glued on the surface.



Fig. 10: Resin. (Triad Dualine, Trubyte)

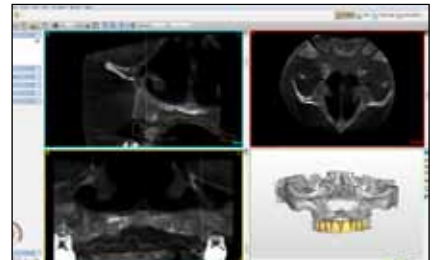



Fig. 13: SimPlant planning. (Materialise Dental)

AD



## 2010 GREATER NEW YORK DENTAL MEETING

**FREE  
REGISTRATION\***

MEETING DATES:  
NOVEMBER 26 -  
DECEMBER 1

EXHIBIT DATES:  
NOVEMBER 28 -  
DECEMBER 1

86th  
Annual Session

The  
Largest  
Dental  
Convention/  
Exhibition/  
Congress  
in the  
United  
States

Please send me more information about...

☐ Attending the Greater New York Dental Meeting

☐ Participating as a guest host and receiving free CE

☐ I speak \_\_\_\_\_ and am willing to assist international guests

Name \_\_\_\_\_

Address \_\_\_\_\_



City, State, Zip/Country Code \_\_\_\_\_

Telephone \_\_\_\_\_ E-mail \_\_\_\_\_

Fax or mail this to:  
Greater New York Dental Meeting or  
visit our website: [www.gnydm.com](http://www.gnydm.com) for more information.

\*Free registration before November 26

For More Information:  
Greater New York Dental Meeting™  
570 Seventh Avenue - Suite 800  
New York, NY 10018 USA  
Tel: +1 (212) 398-6922  
Fax: +1 (212) 398-6934  
E-mail: [info@gnydm.com](mailto:info@gnydm.com)  
Website: [www.gnydm.com](http://www.gnydm.com)

→ page 11