

# DENTAL TRIBUNE

—The World's Dental Newspaper • Middle East & Africa Edition—

PUBLISHED IN DUBAI


MARCH 2009

No. 1 Vol. 7



**Middle East  
AEEDC Dubai to launch  
its 13th edition**

► Page 2



**Media CME  
CDE Self Assessment in  
Clinical Dentistry**

► Page 6



**Trends & Applications  
Miniscrews—a focal point  
in practice**

► Page 10

## Dubai hosts the unique competition in Dentistry “Aesthetic Dentistry MENA Awards 2009”

For the first time for such event in the Middle East region, Dubai will host the “Aesthetic Dentistry MENA Awards 2009, to recognize the outstanding achievements of dental professionals and to focus the public attention to the quality and level of dentistry in the region for the well-being of the patients. The award is organized by Dental Association – UAE and Centre for Advance Professional Practices (CAPP). The ceremony will be held for the first time in the Middle East region with the invaluable hospitality of UAE, Dubai.

Dr. Aisha Sultan, president of the MENA Awards said; “Our vision is to create a platform that serves as a benchmark for dental care and industry players by recognizing exemplary performance in the Middle East region’s dentistry.”

The award will show the ultimate in health and beauty, the latest in science and the art of

dentistry - the beauty from the red carpet to the stage of knowledge and science. Not only to give the patients a great looking teeth and smile, but also to make them feel better.

An independent judging panel of well-known leading figures in dentistry- representatives of associations and professional organizations in the field of dental aesthetic will study all entries and select the three best cases from each category.

Dr. Wolfgang Richter, President European Society of Cosmetic Dentistry. Dr. Ninette Bandy, Head of Dental Services AHS – SEHA. Dr. Nadim Aboujaoude, Fellow of the International College of Dentists. Mohamed A Abdallah, Country Chairman Egypt European Society of Cosmetic Dentistry. Dr. Ramesh Bulbule, Associate fellow American Academy of Implant Dentistry. Dr. Mazen Tamimi, President of DGZI-International section. And Dr. Philippe Tardieu, Associate



Professor New York University. Are selected to be the jury panel.

All Dental Associations from Middle East region and Professional Organizations as DGZI (German Implantology Association), ESCD (European Society for Cosmetic Dentistry), will be involved in the project. [DT](#)

## New discovery may help to re-grow missing teeth, prevent cleft palate

In a breakthrough discovery, scientists have found that a system of opposing genetic forces determines why mammals develop a single row of teeth, while sharks sport several.

The study suggests that carefully understanding the genetic program may prove helpful for scientists to re-grow missing teeth and prevent cleft palate, one of the most common birth defects.

Gene expression is the process by which information stored in genes is converted into proteins that make up the body's structures, and carry its messages.

And gene expression determines the development of teeth and palate while the baby's face takes shape in the womb. Related abnormalities lead to the development of teeth outside of the normal row, missing teeth and cleft palate, and the new insights suggest ways to combat these malformations.

In the new study, it was found that turning off a single gene in mice resulted in development of

extra teeth, next to and inside of their first molars.

"This finding was exciting because extra teeth developed from tissue that normally does not give rise to teeth," said Dr. Rulang Jiang, associate professor of Biomedical Genetics in the Center for Oral Biology at the University of Rochester Medical Center.

He added: "It takes the concerted actions of hundreds of genes to build a tooth, so it was amazing to find that deleting one gene caused the activation of a complete tooth developmental program outside of the normal tooth row in those mice. Finding out how the extra teeth developed will reveal how nature makes a tooth from scratch, which will guide tooth regeneration research."

In the current study, Jiang and colleagues generated mice that lacked the oddskipped related-2 (Osr2) gene, which encodes one of many transcription factors that turn genes on or off. [DT](#)

AD


## PROMEDICA

Highest quality made in Germany

- high quality glass ionomer cements
- first class composites
- innovative compomers
- modern bonding systems
- materials for long-term prophylaxis
- temporary solutions
- bleaching products...

All our products convince by

- excellent physical properties
- perfect aesthetical results



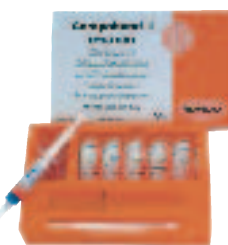**Flowable micro-hybrid composite**

- excellent flow and wetting capability
- high translucency and flexural strength



**Glass ionomer filling cement**

- perfect packable consistency
- excellent durable aesthetics
- also available as handmix version



**Light-curing universal one-component bonding**

- now in practical and hygienic Single Dose
- fast and easy application without spilling



**Glass ionomer luting cement**

- very low film thickness
- perfect occlusal accuracy



**Glass ceramic micro-hybrid composite**

- highly resistant long-lasting restorations
- perfectly invisible fillings

**PROMEDICA Dental Material GmbH**

Tel. +49 43 21 / 5 41 73 • Fax +49 43 21 / 5 19 08

Internet: <http://www.promedica.de> • eMail: [info@promedica.de](mailto:info@promedica.de)

**PROMEDICA**



# AEEDC Dubai to launch its 13th edition with the participation of 700 companies


Dubai- United Arab Emirates, February 24th, 2009. Under the patronage of H.H Sheikh Hamdan Bin Rashid Al Maktoum, Deputy Ruler of Dubai, Minister of Finance, President of the Dubai Health Authority, the 13th UAE International Dental Conference and Arab Dental Exhibition AEEDC Dubai, is scheduled to be held from March 10th -12th, 2009 at the Dubai International Convention and Exhibition Centre.

press conference was presided by Mr. Abdul Salam Al Madani - Executive Chairman - AEEDC Dubai and Dr. Nasser Malik - Chairman of the conference.

Mr. Abdul Salam Al Madani the Executive Chairman of AEEDC Dubai added that "every year we strive to add new records to AEEDC conference and exhibition, this year the number of specialist speakers, and exhibitors participating in AEEDC

Dr. Nasser Malik - The Conference Chairman said at the press conference; "In 2009, AEEDC will take a major shift in its focus, as we are including topics usually not covered in our

previous conferences, topics such as Para-dental professions and business aspects of dentistry. We are also showing our support to the dental education community by starting for the first time,

the AEEDC dental knowledge competition, for the undergraduate dental students of the Middle East region. With the honorary title of AEEDC Champion awarded to the winning school". 



Dr. Amer Al Sharif, Director of Continuous Education Department, Dubai Health Authority, in behalf of H. E. Qadhi Saeed Al Murooshid, Director General - Dubai Health Authority announced at a press conference held today at the Director General office of the Dubai Health care authority that preparations are at full swing for the only dental gathering in the Middle East region and North Africa. The

2009 are bigger than last year. The exhibition space is 20% bigger compared to last year, with an increase of 25% in number of exhibitors. We are also expecting more than 20,000 specialists from 115 country to attend and participate in AEEDC 2009". Moreover, a number of Country representatives, chairmen and presidents of International associations and cooperations will participate in AEEDC 2009" Al.

## Abu Dhabi set to revise health insurance scheme

**Abu Dhabi: The full medical insurance scheme for Emiratis working in the private sector will be withdrawn by the Health Authority Abu Dhabi (HAAD) effective from February.**

A circular issued by the HAAD on February 3 states that Emiratis working in the private sector will henceforth have to bear 50 per cent of the cost of pharmaceutical products and dental care services.


The new rule cuts back on some of the benefits enjoyed by Emiratis under the "Thiqa" Health Insurance scheme. The Thiqa card earlier assured nationals of access to free medical coverage in all health care facilities and qualified them for broader geographical coverage and extra health benefits.

Registered with the National Health Insurance Company's network (Daman), the Thiqa scheme has opened two designated branches in Abu Dhabi and Al Ain and has a call centre to an-

swer enquiries by Emirati citizens.

"The decision to charge Emirati employees working in the private sector 50 per cent of the cost of pharmaceutical products and dental care services was made by HAAD. From our side we are technically prepared to implement the change and are currently in discussions with our providers to make sure the implementation process moves smoothly," said Dr Michael Bitzer, chief executive officer at Daman.

Bitzer acknowledged that people alarmed by the decision had been keeping the call centre busy with their phone calls.


When contacted for clarifications, the official at the HAAD concerned with health insurance policies refused to comment on the decision. However, in earlier meetings, some of the HAAD's top officials had sought to tell the media that all Thiqa card holders would be entitled to full medical treatment free of charge. 


<b>DENTAL TRIBUNE</b> <small>The World's Dental Newspaper - Middle East &amp; Africa Edition</small>	
<b>Published by Venus Advertising</b> <small>in licence of Dental Tribune International GmbH</small> © 2009, Dental Tribune International GmbH. All rights reserved. Dental Tribune makes every effort to report clinical information and manufacturer's product news accurately, but cannot assume responsibility for the validity of product claims, or for typographical errors. The publishers also do not assume responsibility for product names or claims, or statements made by advertisers. Opinions expressed by authors are their own and may not reflect those of Dental Tribune International.	<b>President/CEO</b> <i>Yasir Allawi</i> <i>y.allawi@dental-tribune.ae</i>  <b>Director mCME:</b> <i>Dr. D. Mollova</i> <i>info@cappmea.com</i>  <b>Marketing manager</b> <i>Sawsan Alhalwachi</i> <i>info@dental-tribune.ae</i>  <b>Production manager</b> <i>Hussain Alvi</i> <i>hussain.alvi@dental-tribune.ae</i>  P.O. Box 4475, Dubai, United Arab Emirates, Tel. +9714-2282928, Fax: +9714-2241024 E-mail: info@dental-tribune.ae
<b>Editorial Board</b> Dr. Abdel Salam Al Askary, Implantology, Egypt Dr. Talal Al-Harbi, Orthodontist, Qatar Dr. Mohammed H. Al Jishi, Bahrain Dr. Lara Bakaeen, Prosthodontist, Jordan Dr. Abdullah Al-Shammary, Restorative Dentistry, KSA Dr. Aisha Sultan, Periodontist, UAE Dr. Kamal Balaghi Mobin Aesthetics, Iran Prof. Hussain F. Al Huwaizi, Endodontics, Iraq	

AD


## World Leader

in Fiber Post Technology for Dentistry





translucent quartz fiber



### COLOR ON DEMAND FIBER POST

The smartest post you could envision


## Looking for Distributors Across Middle East

- RADIOPAQUE
- RELIABLE
- AESTHETIC
- EASY TO USE


22°C

37°C

Exclusive Agent in Middle East



**Al Rais Medical & Dental Trading FZE**  
 RAK Free Trade Zone, P.O. Box 10559, Ras Al Khaimah,  
 United Arab Emirates E-mail: armdt@rakfzbc.ae  
 Tel: +971 7 2077407, Fax: +971 7 2041010





– **NEW** –  
Take advantage of the introductory prices now!  
Ask your **VOCO** dental advisor!

**Now  
Available  
in UAE**

**A M A R I S<sup>®</sup>**

**Beauty – compose it!**

**Highly aesthetic restorative**

- Two simple steps
- Layers like in nature
- Brilliant results



**Tigers Medical Equipment LLC**

PO Box 14899, Ajman, UAE Tel. +971 6 7435172 Fax. +971 6 7435173 Mob. +971 50 7863105  
E-mail: [tigeresm@eim.ae](mailto:tigeresm@eim.ae)

**VOCO**

creative in research





**Dubai Medical Equipment**



Choose the **>original<**  
**dubai medical equipment**  
**products**  
of **premium** quality!




TEL: +971 6 5540206      FAX: +971 6 5540207

web: [www.dme\\_equipment.com](http://www.dme_equipment.com)  
e-mail: [dt\\_uae@emirates.net.ae](mailto:dt_uae@emirates.net.ae)

## Cantilevered Premolar The Implant Supported Molar

Although the implant supported mandibular molar is very predictable the restoration of the single posterior implant presents its own unique set of problems. The most obvious problem is that the mesiodistal width of a molar is significantly greater than that of the standard 5.75mm diameter implant. A wider diameter implant would reduce this discrepancy but is reliant on available bone which due to resorption is often insufficient. (Figure 1)

Ideally the implant should be positioned in the centre of the edentulous space but if a standard diameter implant is used as a result of limited buccolingual bone width the crown will be grossly over contoured. (Figure 2) Another option would be to place two standard diameter implants but this requires a minimum mesiodistal space of 14mm. Apart from the difficulty of sufficient space to accommodate two implants there is also an associated cost implication.

An alternative restorative option in this region of the mouth is the cantilever premolar which requires only a single implant for support. (Figure 3) The implant is positioned distally and used to provide support for a mesial can-

tilever premolar pontic. This type of restoration is indicated where the remaining dentition is sound, the occlusion stable and the mesial distal space is between 11-14mm.

### Implant Site Preparation

Following a mid-crestal incision and exposure of the residual alveolar ridge a 2mm pilot bur is used to cut the osteotomy site to the predetermined depth. (Figure 4) As the tapered implant is self drilling as well as self tapping it is not necessary to use any additional burs to enlarge the site prior to implant insertion. (Figure 5) This preserves bone and improves primary stability as well as speeding up the insertion procedure cutting back on surgical stages. As the implant is screwed down into position the bone is expanded improving ridge contour and the emergence profile of the definitive restoration.

### Implant Positioning

It is important for the stability of the bone margin that there is 2mm bone on the buccal aspect of the implant. There should be 1.5mm bone between the circumference of the implant and root of the adjacent tooth. If the implant is placed closer to the root than 1.5mm the biologic

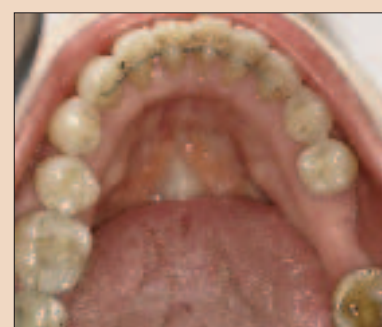

Fig. 1

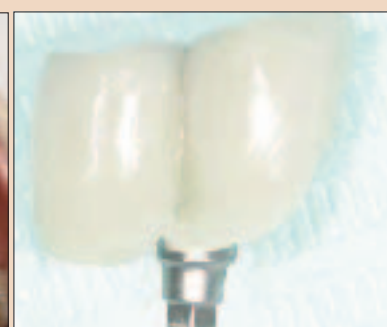

Fig. 2

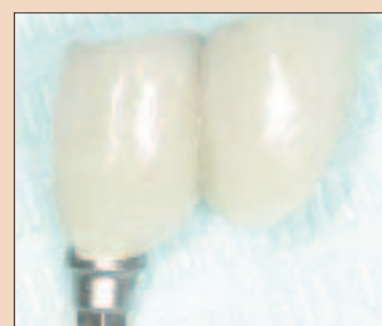

Fig. 3

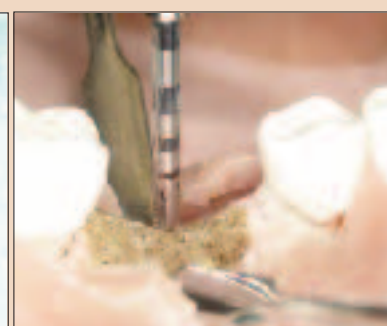


Fig. 4

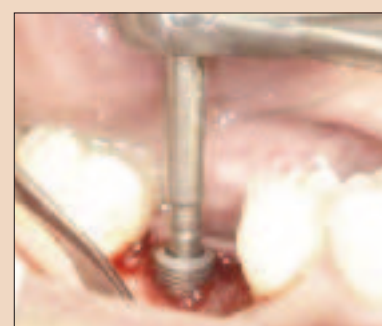


Fig. 5

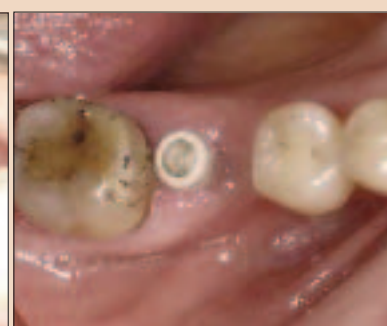

Fig. 6



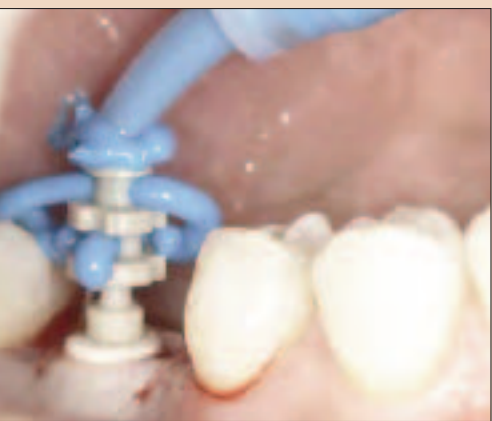

Fig. 7

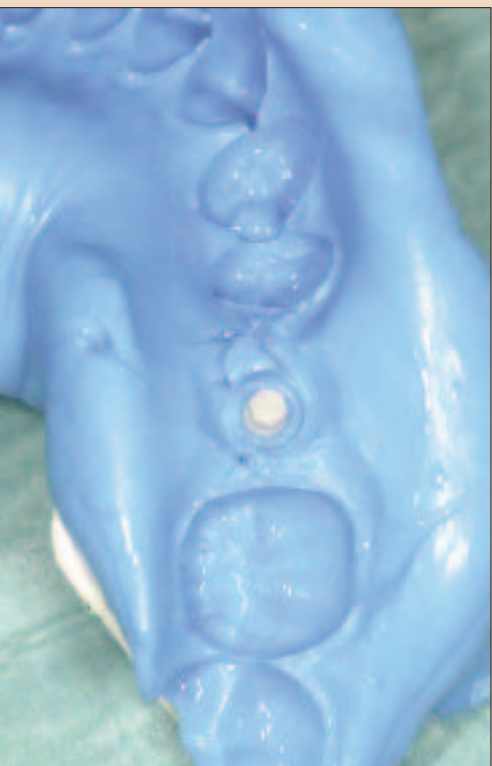

Fig. 8

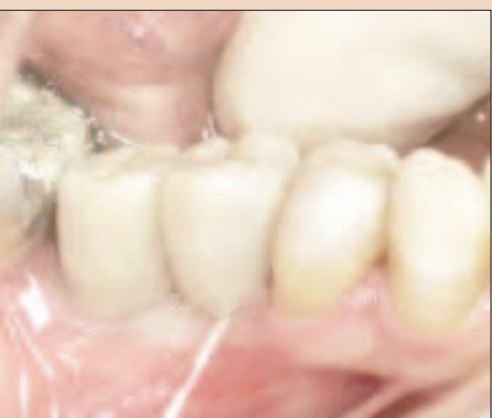

Fig. 9

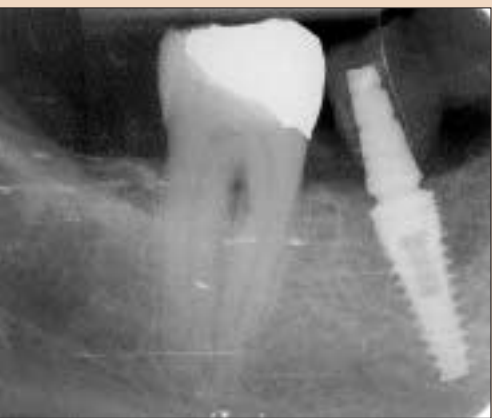

Fig. 10

width is violated and periodontal health of the tooth jeopardised. If the distance is greater than 1.5mm the definitive restoration will be over contoured predisposing to hygiene and maintenance problems. The implant should also be submerged by 1mm beneath the bone crest in order to provide sufficient space to develop the emergence profile.

Transmucosal Healing

Tissue closure is not required as the placement protocol ensures that primary stability is sufficient to permit the placement of

a healing abutment after implant insertion. Instead the flaps are lightly sutured around the healing abutment. Once soft tissue healing is complete after three months impressions can be taken for the definitive restoration. (Figures 6, 7 and 8)

Cantilevered Premolar

Providing the long axis of the implant is parallel to the occlusal plane a friction fit abutment may be used. A friction fit abutment does not require a screw thus

eliminating micro leakage associated with the micro gap. The crown is made from a composite restorative material (gradia) that is bonded directly to the friction abutment. This type of restoration delivers a premolarised posterior occlusion with a narrow occlusal table with low cusp angles reducing lateral load. (Figures 9 and 10) The cantilevered premolar pontic is amenable to routine oral hygiene procedures and is very well tolerated by patients.



Contact Info

Dr Stewart Harding is Honorary Associate Clinical Professor at the University of Warwick and has been placing implants since 1988. He runs regular implant courses from The Dental Center Dubai Health Care City. ([www.gift.org.gg/dubai](http://www.gift.org.gg/dubai)). For more information call Joanne +971 50926 6381 [joanne@gift.org.gg](mailto:joanne@gift.org.gg).

AD

**"Online learning is not the next big thing, it is the now big thing."**  
Donna J. Abernathy  
Learning and Development Editor

### DTSC - COURSES, COMMUNITY, TECHNOLOGY, ON-DEMAND

The DT Study Club makes all of this possible from the comfort of your own computer and without travel expenses. In other words, welcome to the community!

The purpose of this study club is to provide practitioners like yourself an opportunity to learn and network with like-minded colleagues in a friendly, non-threatening environment. We encourage you to take advantage of Dental Tribune's global outreach to access a variety of fresh perspectives and cultures, enhancing your educational mix.

**24/7 LIVE AND INTERACTIVE ONLINE COURSES**

Fulfill your yearly CE requirements with our growing list of archived ADA CERP approved courses.

**DISCUSSION FORUMS**

Focused on helping today's practitioners to stay up to date. Networking possibilities that go beyond borders to create a truly Global Dental Village.

**VIDEO REVIEWS OF PRODUCTS**

Our opinion leaders unveil new products, services, and give you their first impressions of the industry's hottest topics.

**PEER REVIEWED CASE STUDIES**

Upload, comment, participate. We encourage you to share your cases for review with like-minded practitioners.

**REGISTER FOR FREE ON [WWW.DTSTUDYCLUB.COM](http://WWW.DTSTUDYCLUB.COM)**

**CONTESTS WITH CHANCES TO WIN FREE TUITION FOR ADA/CERP C.E. ACCREDITED WEBINARS**

SPONSORSHIP AND SPEAKING INQUIRIES:  
JULIA WEIKAMP, [j.weikamp@dtstudyclub.com](mailto:j.weikamp@dtstudyclub.com), (+16) 907-9836.

**Pm**  
Practice Management

**Gd**  
General Dentistry

**Co**  
Cosmetics

**En**  
Endodontics

**Im**  
Immunology

**Pe**  
Periodontics

**Or**  
Orthodontics

**Dh**  
Dental Hygiene

**WWW.DTSTUDYCLUB.COM**





# CDE Self Assessment in Clinical Dentistry

*Dr WongFoot Meow, BDS(Mal) FDSRCP(S) (Glasg) FICSAM(Mal) FICOI*

The article has been accredited by Health Authority - Abu Dhabi as having educational content and is acceptable for up to 2 (Category 1) credit hours. Credit may be claimed for one year from the date of subscription.

## Prelude

This is a new section of the CDE Self Assessment Series in Clinical Dentistry, Dental Quiz Questions. Note that we have decided to be more clinically orientated with more emphasis on medically related conditions that can affect dental treatment. In this section, we will delve into the intricacies of some soft tissue and dental anomalies. This dental quiz serves to update your CDE prowess.

## QUESTION 1: DIFFERENTIAL DIAGNOSIS OF JAW CYSTS AND TUMOURS

The most common intra-

bony non-inflammatory diseases in the jaws are odontogenic cysts and tumours. However, in the differential diagnosis of jaw lesions, the following must also be considered: i.e., non-plasms, primary and metastatic tumours, developmental lesions, fibrous lesions and dysplastic processes. Think before you cut. An initial differential diagnosis can be established by obtaining a complete history after performing a thorough physical examination. These preliminary data obtained will influence the diagnostic tests ordered and the eventual choice of incisional or excisional biopsy.

### CASE 1A

This 27-year-old Chinese female clerk was blissfully unaware of the huge swelling in the anterior floor of her mouth until her well-informed dentist Dr. C advised her to see me for further management.

- What is wrong with the floor of the mouth? (Fig. 3a)
- What anatomical structures are involved with the swelling?
- Will she have any distinct functional problem in speech and mastication?
- We decided to perform an excisional biopsy (Fig. 3b). What is the difference between an incisional biopsy and an excisional biopsy? Which important possible post-op complication must you warn the patient about before proceeding?
- Why is the incision shaped like this? Describe what you see in Fig 3b.
- The lesion had been enucleated in toto as shown in Fig. 3c. What anatomical structures can you see? What is the yellow blob on the (L) lateral corner near tooth 34?
- Consider the excised lesion in Fig. 3d. It measured 6 cm x 5 cm x 5 cm. What can you see? How can such a huge lesion exist without alarming the patient?
- The surgical closure (Fig. 3e) and one week post-op (Fig.

3f). What post-op measures must you take to avoid complications? What are the types of mid-line swellings that you must consider in the differential diagnosis?

### CASE 1B

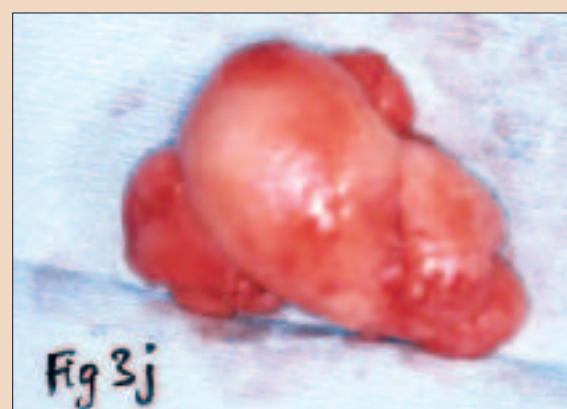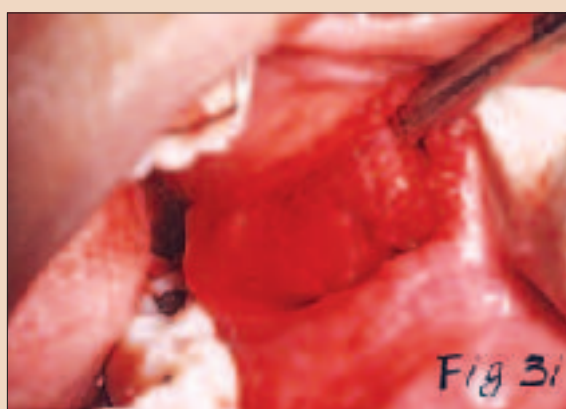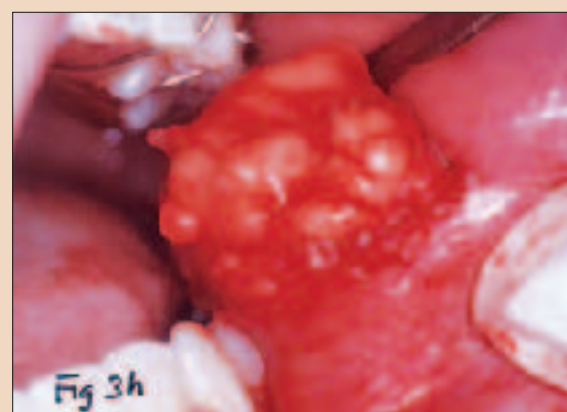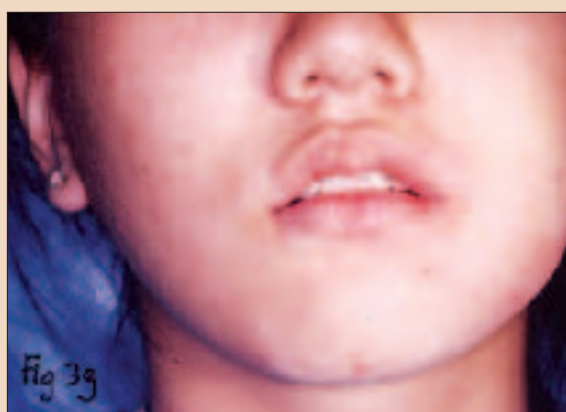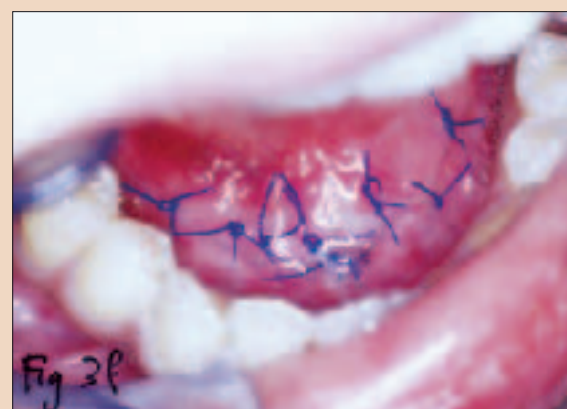
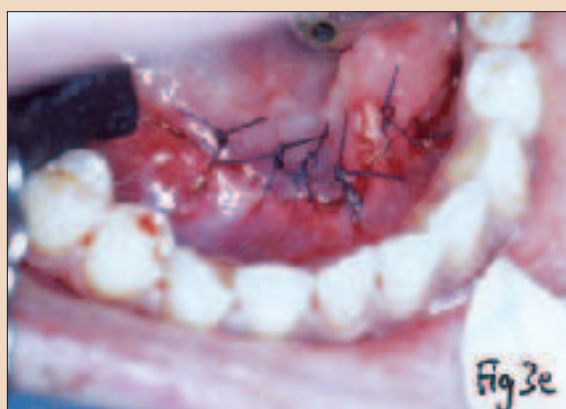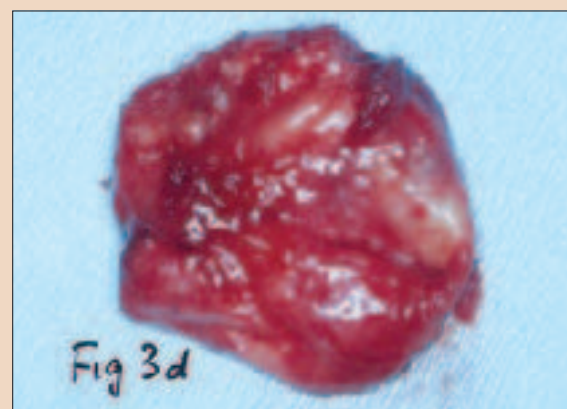
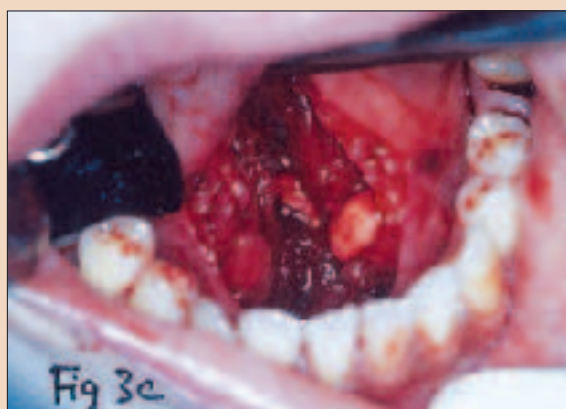
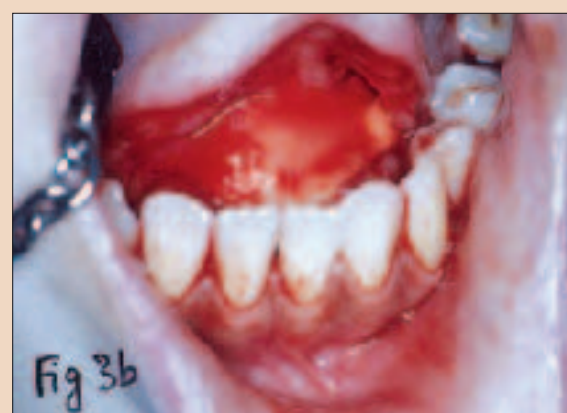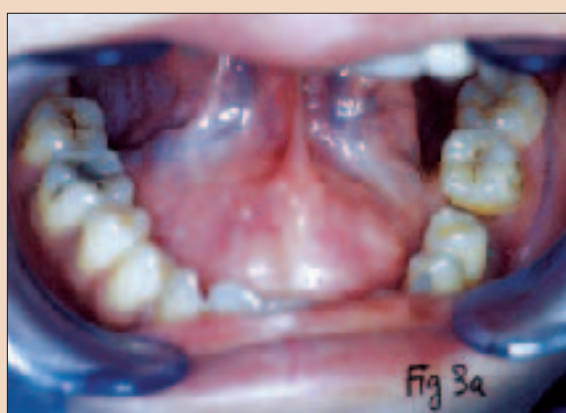This 16-year-old Chinese female student was worried about the increasing asymmetry of her face (Fig. 3g). She complained about this fluctuant mobile lump on her (L) cheek which had gradually increased in size.

- How can you tell that this is so in Fig. 3g?
- Again we decided to do an excisional biopsy. What structures must you avoid when operating on the buccal mucosa of the cheek? (Fig. 3h)
- What structures can you discern in the surgical bed after the enucleation of the tumour? (Fig. 3i)
- The excised lesion Fig. 3j has features highly characteristic of a benign lesion. Judging from the colour and shape, what do you think this is?
- Fig. 3k indicated the immediate post-op scenario and the two weeks post-op appearance (Fig. 3l). What are the basic surgical principles that must be adhered to in order to achieve this result and avoid complications?

### ANSWERS QUESTION 1: CASE 1A

- A huge soft tissue swelling is seen in the mid-line of the floor of the mouth, bulging upwards and outwards towards the oral cavity as the mouth is opened. Normally, the lingual frenum is near the lingual surfaces of

teeth 31 and 41. In this case, even the opening of the sublingual salivary gland (seen as two nodules lateral to the frenum) is displaced posteriorly. In addition, the outlines of the paired sublingual glands have disappeared and a distinct firm hemispherical swelling is apparent.

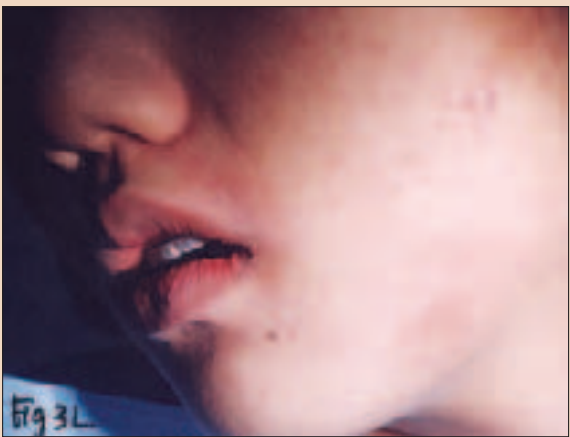
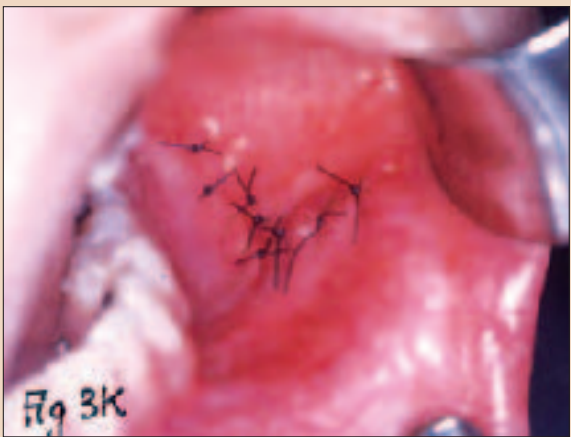


- The floor of the mouth is the mylohyoid muscle. Above this muscle lies the mouth, below it lies the neck. The structures

to watch for when operating around this area are: geniohyoid muscles, the lingual nerve, submandibular gan-

glion, submandibular duct and hypoglossal nerve. In addition, you must be mindful of the sublingual gland, lingual ar-





tery and its dorsales linguae branches.

c. Possible problems arising from a growth encroaching on the floor of the mouth include the following:

- Increase in size of the lower dental arch causing proclination of the lower incisors
- If the cyst is located above the geniohyoid muscle, it can displace the tongue upwards and create difficulty in mastication, speech and swallowing. When the cyst occurs below the geniohyoid muscle, it will protrude submentally causing a “double chin”. In such cases, the differential diagnosis will include thyroglossal duct cysts, periapical and soft tissue abscesses and sublingual sialadenitis. Patient will then have problems pronouncing certain sounds.

d. An incisional biopsy is done by removing a small piece of tissue to establish a definitive diagnosis before initiating final therapy in suspected aggressive benign tumours or malignancies.

- An excisional biopsy is utilised for small benign lesions, suspected small malignant lesions where satisfac-

tory margins can be obtained at the time of biopsy.

- Pre-operative warnings. The patient should be warned of possible lingual paresthesia and loss of taste sensation. VERY IMPORTANT! Haematoma of the floor of the mouth and subcutaneous ecchymosis of the skin of the neck may occur. In addition, there may be temporary salivary backflow involving the sublingual and submandibular salivary gland.

f. The incision is made submucosally in the gutter between the hyoglossus and mylohyoid muscles in an anterior location avoiding the opening of the sublingual duct and the superficial lingual vessels. In this way, you are likely to avoid traumatising the lingual nerve, submandibular duct and lingual vessels.

g. In Fig. 3c, notice the bloodless field achieved by careful dissection. The following structures are discernible in the operating field.

- Genioglossus, which forms the bulk of the tongue (seen superior to the yellow blob).
- The geniohyoid muscle sitting on top of the mylohyoid muscle.

- In the centre is the branch of the lingual artery which, if breached, will cause copious bleeding and possible haematoma formation.
- Parts of the (L) and (R) sublingual salivary glands are seen at the lateral margins.

- If the excision is extended posteriorly, we will come across the hyoglossus muscle, submandibular duct and lingual nerve (“tiger country”). The yellow blob is a daughter cyst of the huge cyst enucleated (Fig. 3d).

- Histopathology reported the specimen in Fig. 3d as a dermoid cyst. The dermoid cyst is a form of cystic teratoma derived principally from embryonic germinal epithelium which in some instances contains structures of other germ layers. Origin: Those cysts are presumed to be derived from enclavement of epithelial debris in the midline during the closure of the mandibular and hyoid branchial arches. Some of these cells are totipotent blastomeres resulting in some of the structures seen through the cyst lining in Fig. 3d including keratin, sebaceous glands, hair follicles, sweat

glands and muscles. (This is according to the HPE report.)

- The soft tissues of the floor of the mouth can accommodate quite a large swelling if it is slow-growing. As they increase in size, they push apart the genioglossus muscles moving deeper into the floor of the mouth and backwards into the tongue thereby allowing adaptation and causing minimal problems in the oral cavity.

h. As mentioned earlier, complete haemostasis must be secured to avoid haematoma formation and subcutaneous ecchymosis of the neck. If required, a drain should be placed. Always test the patency of the submandibular ducts to avoid salivary gland problems. Antibiotics and anti-swelling medication must be given to reduce swelling of the floor of the mouth.

- Differential diagnosis of swellings of the floor of the mouth. There are a number of lesions that bear strong clinical resemblance to the demand cyst and include the following: (a) Ranula (b) Unilateral/bilateral blockage of Wharton’s Ducts (c) Thyroglossal tract cysts (d) Cystic hygroma (e) Branchial cleft cyst (f) Cellulitis of the floor of the mouth (g) Infection of sublingual and submandibular glands (h) Benign and malignant tumours of the floor of the mouth, and (i) Normal adipose tissue in the submental area.

- Loss of the (L) nasal labial fold.
- Asymmetry of the face. The (L) side is enlarged with slight lifting of the (L) earlobe.
- Fullness of the (L) cheek.
- Angle of the (L) corner of the mouth is indistinct.

b. It is usually quite safe to operate on the buccal mucosa. Structures to watch out for include the opening of the parotid salivary gland (Stenson’s Duct), long buccal nerves and branches of the facial artery. The cheek has four layers: cutaneous, muscular, glandular and mucosal together with the buccal pad of fat, molar glands and buccopharyngeal fascia. Where the facial artery crosses from lower to upper jaw, it is applied to the buccinator muscle an inch from the angle of the mouth! Notice that in Fig. 3h, we avoided the angle of the mouth and did not dissect into the muscular layer.

c. Notice that in Fig. 3i, you can see the branches of the long buccal nerve, the buccinator muscle the glandular and mucous layers. The buccal pad of fat can be seen near the suction tip.

d. This soft lobulated tumour (Fig. 3j) measured 3 cm x 4.5 cm x 4 cm. It is a lipoma, which is a benign tumour composed of mature fat cells. The fat cells in the lipoma are histologically similar to normal fat cells but metabolically different as fat is not lost from a lipoma during a starvation diet. The slow growth with rounded, even and smooth contour with the smooth capsule suggests a benign tumour. The oral lipoma is a sessile or pedunculated, painless, slow-

### CASE 1B

a. Notice the following signs of swelling in Fig. 3g. Compare this with Fig. 3i

## MEDIA CME Self-Instruction Program

Dental Tribune Middle East & Africa in collaboration with CAPP introduce to the market the new project mCME - Self Instruction Program.

mCME gives you the opportunity to have a quick and easy way to meet your continuing education needs.

mCME offers you the flexibility to work at your own pace through the material from any location at any time. The content is international, drawn from the upper echelon of dental medicine, but also presents a regional outlook in terms of perspective and subject matter.

How can professionals enroll? They can either sign up for a one-year (10 exercises) by subscription for the magazine for one year (\$65) or pay (\$20) per article. After the payment, participants will receive their membership number and will be able to attend to the program.

**How to earn CME credits?** Once the reader attends the distance-learning program, he/she can earn credits in three easy steps:

1. Read the articles.
2. Take the exercises
3. Fill in the Questionnaire and Submit the answers by Fax (+971 4 3686883) or

Email :[info@cappmea.com](mailto:info@cappmea.com)

After submission of the answers, (name and membership number must be included for processing) they will receive the Certificate with unique ID Number within 48 to 72 hours.

Articles and Questionnaires will be available in the website after the publication.

[www.cappmea.com](http://www.cappmea.com)

# EARN 20 mCME credit hours

Accredited by Health Authority - Abu Dhabi

[www.cappmea.com](http://www.cappmea.com)

E-mail: [info@cappmea.com](mailto:info@cappmea.com) / [info@dental-tribune.ae](mailto:info@dental-tribune.ae)



growing mass arising from the submucous connective tissue of the cheek. They are very soft and may exhibit pseudo-fluctuation. This particular lipoma is yellowish in colour and is fully mobile in the cheek when palpated.

e. Post-operative complications for this type of operation will include swelling, acute pain, haematoma formation, ecchymosis, brisk haemorrhage, infections and wound dehiscence.

f. Basic principles to ensure a successful operation should include the following:

- Treatment planning—pre-

operative anatomical assessment of the operative site is essential to anticipate and pre-empt difficulties and complications. Avoid important nerves and vessels by careful dissection.

- Aseptic technique and use of sterilised instruments.
- Careful enucleation of the lesion via sharp precise dissection. Do not breach the buccinator muscle.
- Meticulous wound closure in layers after achieving complete haemostasis.
- Good post-operative after care and instructions, mouth wash, antibiotics and analgesics.

### CASE 1C

This 32-year-old Chinese housewife presented around Chinese New Year Eve 2004 for a rapidly enlarging swelling which started some months back.

- The facial asymmetry is highly obvious. Describe what you see? (Fig. 3m)
- The intra-oral appearance looks bleak. Why? What features in Fig. 3n suggest that we are dealing with something aggressive, fulminant and probably malignant?
- The X-ray appearance in Fig. 3o confirms our suspicions beyond doubt! What can you see in the (R) maxillary sinus?
- We actually excised the lesion in toto after an initial incisional biopsy confirmed the photos were lost. What do you think we did?

### CASE 1D

This 60-year-old Chinese businessman has had a growth in the (L) maxilla for the last five years!

- What features in Fig. 3p suggest a benign growth in the (L) maxilla?
- Fig. 3q (mirror image appearance—actually the growth is on the (L) side) has a unique feature. What is it? Which tooth is the culprit?
- The X-ray appearance confirms the benign nature in contrast with Fig. 3r. What features indicate its non-aggressive nature?
- The growth was enucleated (Fig. 3s). Are you likely to en-

counter any vital structures in the maxilla?

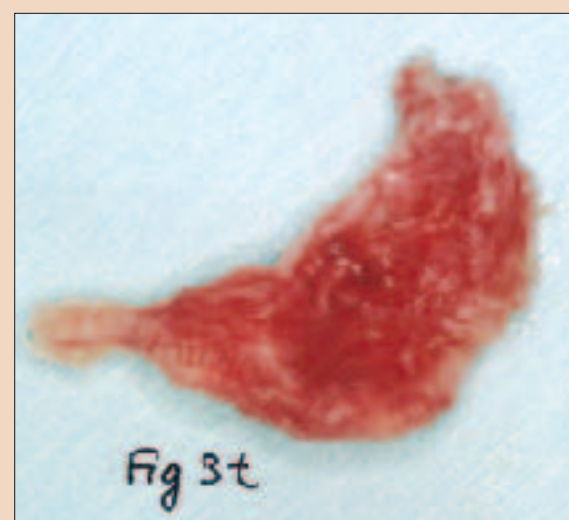
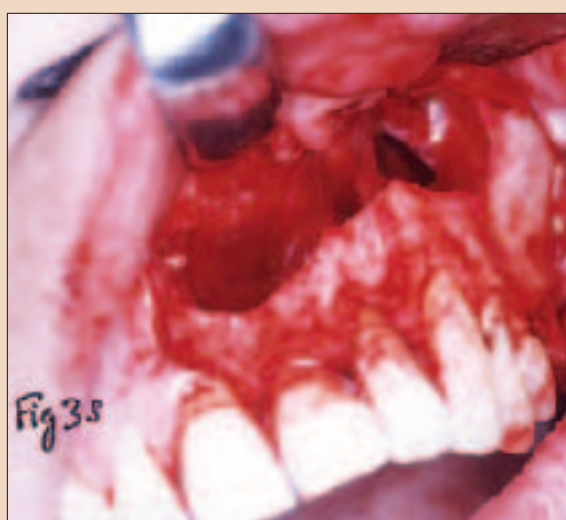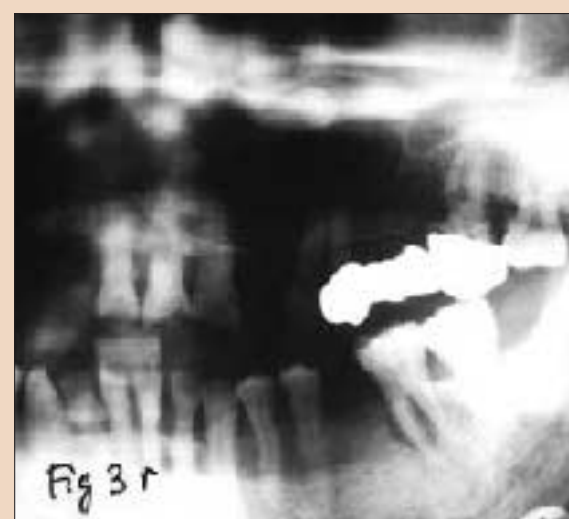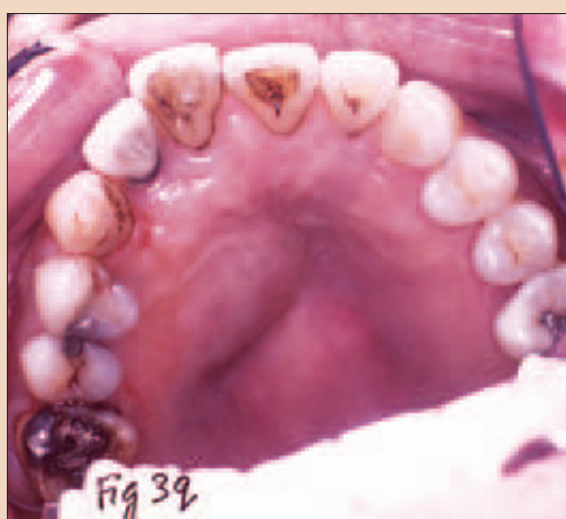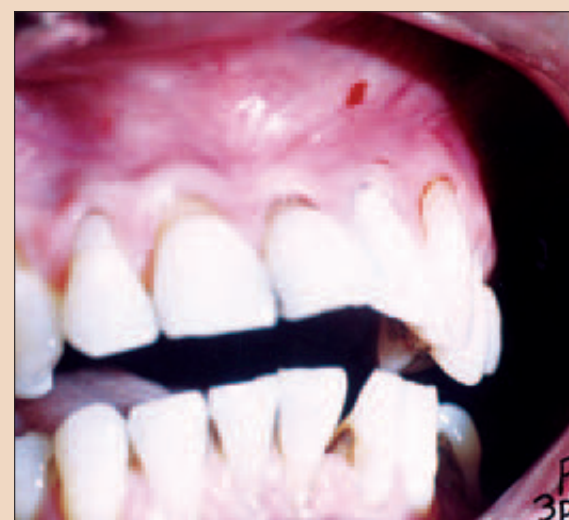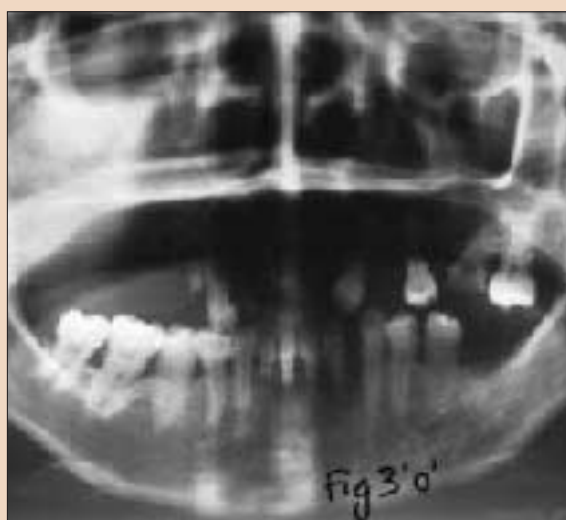
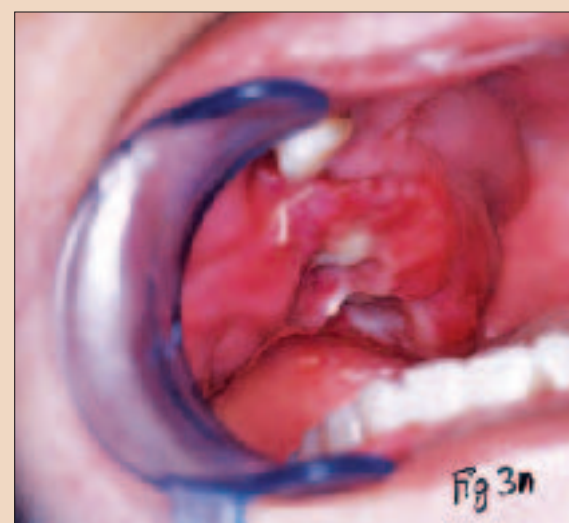
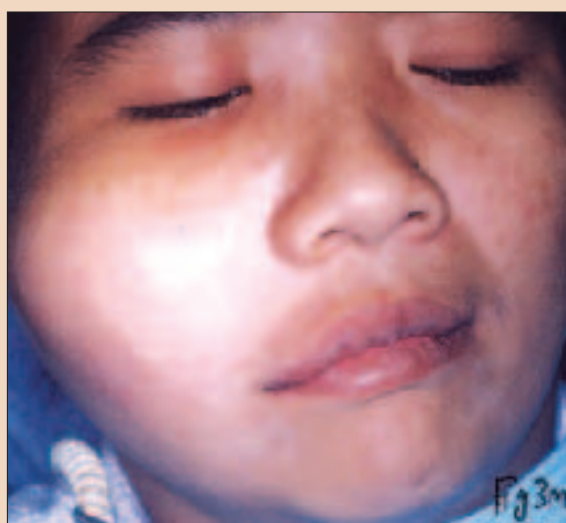- The excised lesion Fig. 3t is quite typical. What can you see?

### CASE 1E

This 74-year-old Malay housewife complained of trismus, pain of (L) jaw and inability to eat plus difficulty in swallowing saliva.

- What can you see in Fig. 3u? What signs indicate that this is probably not an aggressive growth but inflammatory in nature?
- Fig. 3v is the extra-oral presentation. Describe what you see and correlate it with your diagnosis.
- The intra-oral appearance Fig. 3w confirms that this lesion is probably of infective origin. Why?
- The X-ray view (Fig. 3x) is highly informative. What can you see? How does the appearance of the mandibular bone explain your findings in Fig. 3v and Fig 3w? What are those multiple radio opaque lines?
- After one month of conservation treatment, the patient was cured. Fig 3y (intra-oral appearance) confirms this. What do you think the problem was and what did we do to achieve a cure?

The rationale for putting forward cases 1A to 1E is to help readers achieve some skills in narrowing down the identity of a lesion from differential diagnosis. How would you establish a differential diagnosis? (Hint: three main steps.)



### CASE 1C

The patient has squamous cell carcinoma of the maxillary antrum which accounts for more than 90% of antral malignancies.

- Compare Fig. 3m (extra-oral view) with Fig. 3g. Notice the following:
  - Unilateral swelling of the (R) cheek. The overlying skin is glistening and taut owing to massive expansion

of the underlying (R) maxillary sinus.

- The (R) angle of the mouth is pushed inferiorly and outwards with complete loss of the nasolabial fold.
- The (R) eye is pushed upwards (proptosed) with loss of demarcation of the lower eyelids.
- The (R) nostril is pushed inferiorly and outwards.
- There is complete anaesthesia of the infraorbital skin and lack of facial expression.

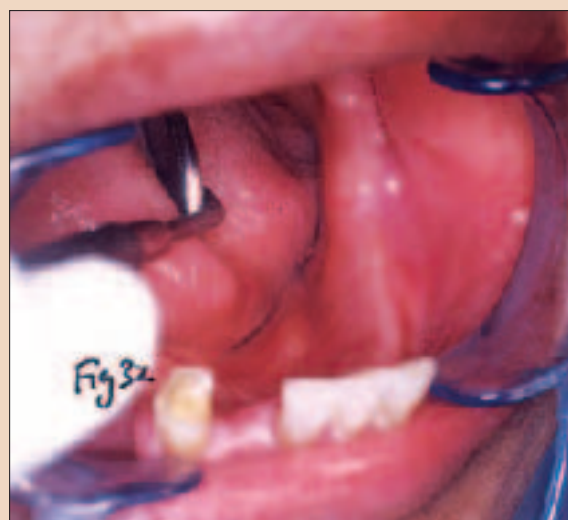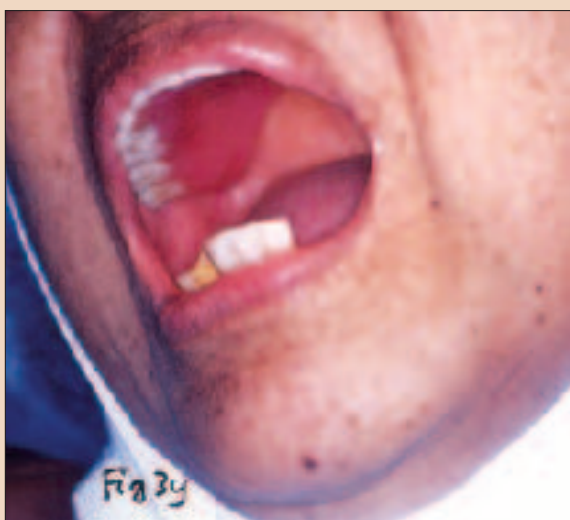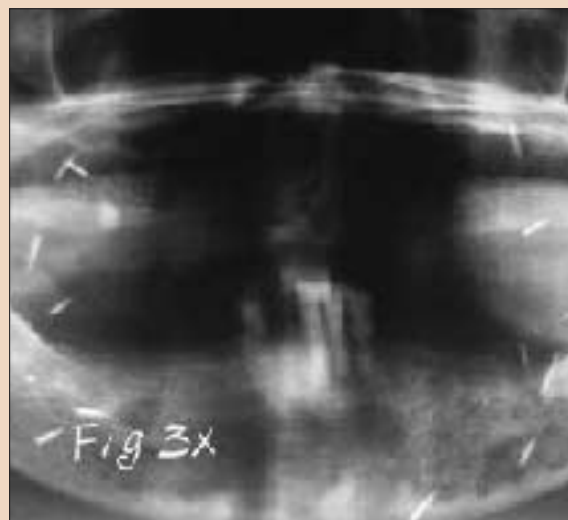
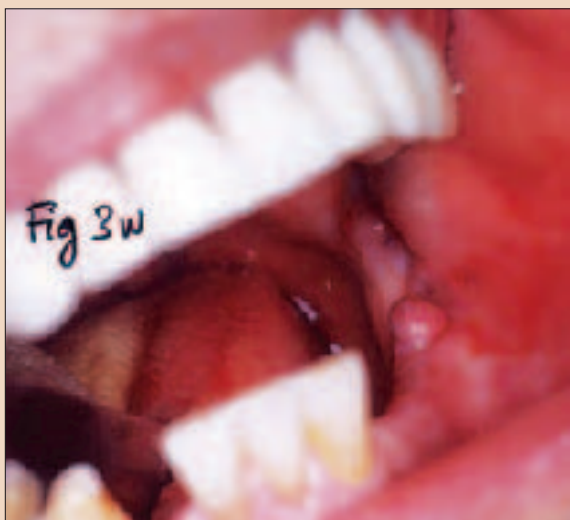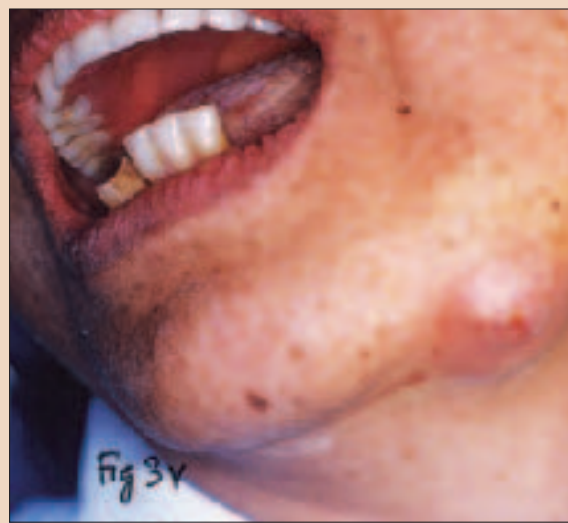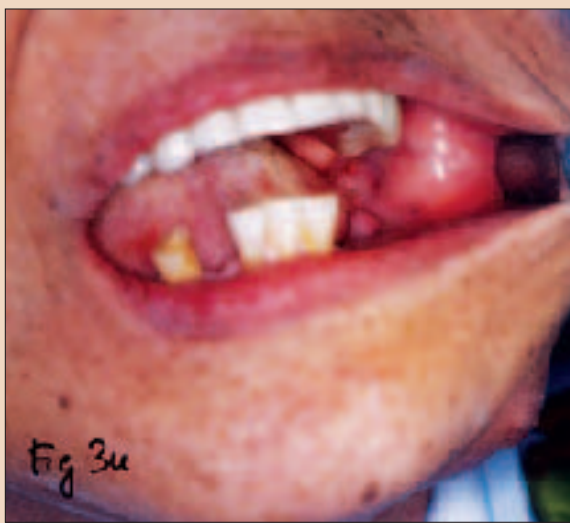- The intra-oral view (Fig. 1n) is highly indicative of an aggressive malignant lesion. Notice the central necrosis of the (R) dentoalveolar process and the fungating red margins. The upper (R) posterior teeth have all been exfoliated with complete obliteration of the (R) buccal sulcus. The palate is deformed with loss of palatal vault contour.
- The characteristic radiographic changes of antral mucosal malignancy include the following (Fig. 3o):

- Destruction of the lateral and inferior bony walls of the (R) maxillary antrum.
- The inferior orbital margin has been infiltrated. Surprisingly, the lateral walls of the (R) nostril remain intact.
- The (R) maxillary tuberosity has been completely destroyed with loss of all upper (R) posterior teeth.
- The (R) zygomatic complex is completely opaque. All the above features can be elucidated by comparing with the normal anatomy of the (L)

nostril, orbit, antrum and zygomatic complex.

- This is an extremely mutilating operation and the patient must be prepared psychologically as there are acute social post-operative problems of appearance, speech, mastication and physical suffering after the operation. A (R) total maxillectomy was done via a Weber-Fergusson skin incision (Fig. 3a and Fig 3b). After securing haemostasis, we applied a skin graft from the opposite thigh. The skin graft is





### CASE 1E

a. Severe infections are uncommon in the mouth but this case took on a combination of the following forms—osteomyelitis, cellulitis and soft tissue abscess. Fig. 3u revealed soft tissue abscesses in the (L) lower molar region and left extra-oral submandibular abscess. (The history indicated that cellulitis had occurred here before the abscess appeared.) The first step in the management of this case is to determine that the patient is not medically compromised with uncontrolled diabetes or on immuno suppressive drugs or other chronic medical conditions.

b. Fig. 3v indicates that the lesion is probably inflammatory in nature. There is no facial asymmetry and no change in jaw outlines. The lips and overlying skin look normal. The skin is not stretched and the usual ageing spots, pigmentation and moles are clearly set in normal looking facial skin. The sudden onset and the initial favourable response to antibiotics indicates that this is an inflammatory condition.

c. Fig. 3w is highly informative. Except for the soft tissue abscess, there is no swelling of the buccal or lingual cortical plate. The lingual and buccal sulcus are within normal limits. The tongue looks coated and furry, indicating an infective origin.

d. The X-ray view is highly unique (Fig. 3x). The patient has multiple “susuk”. These are gold needles inserted by bomohs (medicine men) in Asian women who believe that it will retard ageing and help maintain their attractiveness. Notice the following in Fig. 3x: the sharp trabecular pattern of the bone is lost where bone had been resorbed and areas of radiolucency indicative of bone destruction have appeared. These areas extend from tooth 13 all the way to the (L) retro-molar area giving a classical appearance of bone with ill-defined margins resembling a fluffy or “moth-eaten” appearance.

e. Patient has osteomyelitis of the mandible secondary to the “susuk”. There were no obvious dental causes. The principles of management for this case were as follows:

- Bacteriological diagnosis via a specimen of pus.
- Antibiotics—Clindamycin 300 mg, bd x 30 days.
- Incision and drainage of the infra-oral and extra-oral soft tissue abscesses.
- Removal of sequestra after infection was controlled. The key in this case was the Clindamycin, which in my experience works beautifully in resolving osteomyelitis as seen in the post-treatment views of Fig. 3y and Fig. 3z. Notice the superb healing with no signs of scarring whatsoever. Osteomyelitis is a severe infection and must be treated with the utmost respect as it can cause the

following complications: (a) Inferior dental nerve anaesthesia, (b) pathological fracture, (c) cellulitis especially if streptococci is involved and, (d) septicaemia especially in older patients.

f. Establishment of a differential diagnosis of cysts and tumours can be methodically done with the following steps i.e., history, physical examination, diagnostic imaging and biopsies.

#### • History

**Pain**—Not a feature of cysts and tumours unless there is secondary infection or neural invasion.

**Swelling**—Persistent slow growth suggests an expanding lesion. Rapid growth suggests concurrent infection or an aggressive lesion.

**Loss of Function**—Trismus results from intra-capsular or extra-capsular TMJ disease. Extra-capsular causes of decreased function include inflammation of the muscles of mastication, paramandibular pain of any aetiology and tumour invasion from the jaws into the surrounding soft tissues.

**Sensory or Motor Changes**—Altered or lost sensation along the distribution of V1, V2 or V3 indicates long standing infection, and invasive malignant or aggressive benign tumour.

• **Physical Examination:** Inspection, palpation and thorough physical evaluation. Surface Changes—Is it chemical, traumatic, vesicular bullous, neoplastic, metabolic or inflammatory?

**Swelling**—Note the location, tissue and origin, time of onset, rate of enlargement, changes in size and relation to eating and jaw function.

**Olfactory Findings**—Necrotic lesions of the jaws portend advanced disease. Necrotic tissue has a characteristic order (especially in cancer patients) that is readily identifiable. Anaerobic infections associated with cysts and tumours are also foul smelling. Sebaceous material found from cysts is easily identified by the appearance and strong odour. All of the above is represented by the five cases presented earlier.

• **Diagnostic Imaging**—Most plain radiographs and the various oral views are adequate to help arrive at a provisional diagnosis. If need be, tomography, CT scan and MRI scanning can be helpful.

• **Biopsy**—If all three steps are methodically followed, a definitive diagnosis can be obtained by the biopsy i.e., aspiration, incisional or excisional biopsy. [\[4\]](#)

applied to the raw surface of the cheek flap and the pterygoid fossa. This is important. If the inner surface of the flap is not grafted, the cheek will contract badly. A denture obturator with black gutta percha stent is used to fill the cavity and give support to the cheek and flap. The denture obturator is held in place by (R) and (L) circumzygomatic stainless steel wires.

### CASE 1D

Odontogenic cysts arise from epithelium concerned in tooth formation and comprise three main types—periodontal, dentigerous and primordial. The periodontal cysts form the majority of the odontogenic cysts. This patient had a long-standing periodontal cyst arising from a non-vital upper (L) lateral incisor tooth.

a. Although the growth was allegedly present for at least 5 years, the only visible signs were splaying of the (L) maxillary anterior teeth and a distinct bulge of the (L) buccal

sulcus. The colour and markings of the labial mucosa are normal.

b. Visible and palpable expansion of the (L) palate is seen in Fig. 3q. Normally, this sort of swelling occurs with maxillary cysts related to the posteriorly inclined root of the lateral incisor and palatal roots of the first pre-molar and molar teeth. Notice the bluish tone of the palatal mucosa where the cyst had perforated the palatal bone and the labial proclination of tooth 21 and 22. Although tooth 22 is the culprit, tooth 21 has moved quite a bit labially. The swelling is confined to the left because of the midpalatal raphe and rugae.

c. The following features are highly indicative of a benign cystic growth (Fig. 3r).

- Minimal displacement of teeth with intact roots in a rounded clearly radiolucent area with a sharply defined outline.
- Unilocular lesion with clear condensed peripheral radiopaque margins or cortex.
- Surrounding structures and alveolar bones remain intact

with the usage distinct radiographic markings.

- No loss of teeth and dental tissue in spite of the size of the cyst.

d. In Fig. 3s, a trapezoidal mucoperiosteal flap was raised from tooth 11 to tooth 26. The labial window was naturally created as it has become egg-shell in the thickness. Notice the smooth internal walls.

e. The specimen in Fig. 3t represents the cyst wall and capsule. The cyst capsule contains collagenous fibrous connective tissue. There is minimal inflammatory infiltrate with evidence of areas split up by spaces and clefts (cholesterol clefts). The fluid has been evacuated but was watery with a shimmering appearance because of the cholesterol crystal effect. The only vital anatomical structures of note in this operation would be the apices of the neighbouring teeth, the incisive canal and the (L) maxillary antrum. Avoid traumatising the inferior lateral floor of the (L) nostril and possible perforation of the palatal mucosa.