

	<h2>ENDO TRIBUNE</h2> <p>The World's Endodontic Newspaper · U.S. Edition</p>	<h2>COSMETIC TRIBUNE</h2> <p>The World's Cosmetic Dentistry Newspaper · U.S. Edition</p>
<p>Las Vegas or Santa Barbara? If you're going to AMED or AADOM, we've got the highlights of each for you. ▶ pages 8A-10A</p>	<p>Apical microsurgery The conclusion of this six-part series discusses sutures and suturing technique. ▶ page 1B</p>	<p>Direct splinting Case study using this procedure for maintenance of perio-compromised teeth. ▶ page 1C</p>

Gum disease a significant public health concern

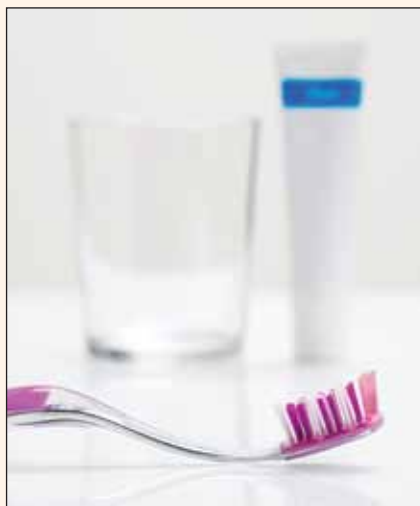The prevalence of periodontal disease in the United States may be significantly higher than originally estimated. Research published in the Journal of Dental Research from the Centers for Disease Control and Prevention (CDC) and the American Academy of Periodontology (AAP) suggests that the prevalence of periodontal disease may have been underestimated by as much as 50 percent. The implication is that more American adults may suffer from moderate to severe gum disease than previously thought.

In a National Health and Nutrition Examination Survey (NHANES) pilot study, funded by the CDC's Division of Oral Health, a full-mouth, comprehensive periodontal examination was conducted on over 450 adults over the age of 35. Periodontal disease was classified according to definitions determined by the CDC in collaboration with the AAP.

The prevalence rates were then compared against the results of previous NHANES studies, which used a partial-mouth periodontal examination. Historically, NHANES has served as the main source for determining prevalence of periodontal disease in U.S. adults. The pilot study finds that the original partial-mouth study methodology may have underestimated true disease prevalence by up to 50 percent.

Several research studies have associated gum disease with other chronic inflammatory diseases, such as diabetes, cardiovascular disease and rheumatoid arthritis.

"This study shows that periodontal



(Photo/Molka, Dreamstime.com)

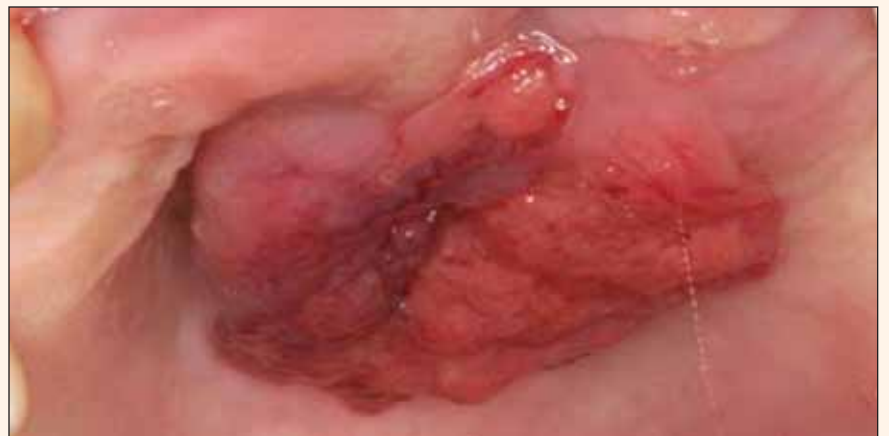disease is a bigger problem than we all thought. It is a call to action for anyone who cares about his or her oral health," said Samuel Low, DDS, MS, associate dean and professor of periodontology at the University of Florida College of Dentistry and president of the AAP.

"Given what we know about the relationship between gum disease and other diseases, taking care of your oral health isn't just about a pretty smile. It has bigger implications for overall health, and is therefore a more significant public health problem," Low added.

Low explained that the increased prevalence of periodontal disease makes it essential to maintain healthy teeth and gums. "Not only should you

→ [DT](#) page 2A, GUM DISEASE

Papillary squamous cell carcinoma



Oral squamous cell carcinoma (OSCC) is the most common malignancy of the oral cavity and has several known variants. The papillary variant of OSCC affecting the palate is rare compared to more common sites of involvement that include the larynx, pharynx and nasopharynx.

→ See page 5A

ADA conference seeks solutions for older adults

The American Dental Association (ADA) is extending invitations to those concerned about the oral health of vulnerable older adults and people with disabilities to attend a national conference and help shape the future of oral health care for this underserved and growing population.

The national coalition conference, titled Oral Health of Vulnerable Older Adults and Persons with Disabilities, is scheduled for Thursday, Nov. 18, at

the JW Marriott in Washington, D.C.

"We look upon this conference as the first step in building a consensus among a multi-disciplinary group of professionals in seeking solutions about oral health care for the vulnerable older adult and the disabled," said Dr. Raymond F. Gist, ADA president.

"We are looking for attendees' ideas, collaboration and support in

→ [DT](#) page 2A, ADA

AD

Is this the first 8th Generation bond?





Futurabond DC

Dual-Cured

- It is dual-cured and works with all light-, self- or dual-cured resins
- It works in a self-cured mode without any light - great for endo
- It takes only 35 sec. from start to finish

More info and **FREE SAMPLE** at www.vocoamerica.com

- and it has everything you expect from a great self-etch bond
- Virtually no sensitivity
- Over 30 MPa bond strength to dentin and enamel

Futurabond DC - one for all applications



Call toll-free 1-888-658-2584

PRRST STD
 U.S. Postage
 PAID
 Permit # 506
 Mechanicsburg, PA


Dental Tribune America
 215 West 35th Street
 Suite #801
 New York, NY 10001

← DT page 1A, GUM DISEASE

take good care of your periodontal health with daily tooth brushing and flossing, you should expect to get a comprehensive periodontal evaluation every year," he advised.

According to Paul Eke, MPH, PhD, epidemiologist at the CDC and lead author of the study, the findings have significant public health implications. "The study suggests we have likely underestimated the prevalence of periodontal disease in the adult U.S. population," he said. "We are currently utilizing a full-mouth periodontal examination in the 2009/10 NHANES to better understand the full extent and characteristics of periodontal disease in our adult population."

Eke added, "Research suggests a connection between periodontal health and systemic health. In light of these findings, understanding the relationships between periodontal disease and other systemic diseases in the adult U.S. population is more crucial than ever."

Patients can assess their risk for periodontal disease and learn more by visiting perio.org. 

(Source: AAP)

About the AAP

The American Academy of Periodontology (AAP) is the professional organization for periodontists. Periodontists are also dentistry's experts in the treatment of oral inflammation. They receive three additional years of specialized training following dental school. The AAP has 8,000 members worldwide.

← DT page 1A, ADA


helping frame the conference's recommendations that could be used by many sectors, including educational institutions, professional organizations and policy makers."

Professionals concerned about oral health for vulnerable older adults and people with disabilities, including dentists and dental hygienists, geriatricians, nurses, oral health advocates, aging and disability advocates, long-term care providers and policy makers and legislative staff, are encouraged to register for the conference.

Dental experts will present topics of critical importance in meeting the oral health needs of special populations, including collaboration between disciplines, oral health delivery systems, policy implications, medical dental considerations and coalition building.

Responding to each presentation will be an expert from outside dentistry, representing geriatric medicine, long-term care, aging advocacy, state health and policymakers.

Active audience participation will follow as attendees have the opportunity to provide input as they discuss the presentations.

"The conference is a unique opportunity to help shape the future of oral health care and improve the quality of life for vulnerable older adults and those with disabilities," said Gist. "We highly encourage those interested professionals to attend." 

(Source: American Dental Association)

Asthmatic kids and tooth decay

In the past, there have been suggestions that asthma and tooth decay were linked, especially for children. But according to a new report from the American Dental Association, that is apparently not the case. A critical review of the literature examined 27 separate studies published in 29 different papers between 1976 and March 2010.

The studies looked into possible connections between asthma and dental caries.

Gerardo Maupomé, professor of preventive and community dentistry at the Indiana University School of Dentistry and author of the new study, said: "We found little evidence to suggest that asthma causes tooth decay. In fact, the two largest studies we reviewed found that children with asthma appear to have fewer cavities than others. This may be because their parents are used to taking them to health-care providers, and routinely bring them to the dentist."

"The notion that there is a link between asthma and tooth decay may have its origin in anecdotal statements by emergency room workers who see children with poorly managed asthma," Maupomé said. "These children could also be more likely to have poorly managed dental conditions, and therefore tooth decay. It's reasonable to believe that poor clinical management may be associated with both conditions, not the asthma that is causing the cavities."

The study does acknowledge that it is difficult to explicitly determine if there is a connection between asthma and dental decay — predominantly because of the large number of variables related to asthma, including the wide range of treatments for the illness and the severity of asthma symptoms. Yet, researchers suggest there is no need for parents with asthmatic children to be concerned.

However, children who use nebulizers to control their asthma may be increasing their exposure to sugars, as nebulizers often contain fructose. Frequent intake of sugar can lead to tooth decay as the sugar reacts with the plaque on teeth and forms an acid that gradually dissolves the protective enamel coating on the teeth.

Dr. Nigel Carter, chief executive of the British Dental Health Foundation, advises the best way to protect children's teeth from decay is to make sure they brush twice a day with a fluoride toothpaste. It is also important to cut down how often sugar occurs in a child's diet.

Carter said: "It is vital that children brush their teeth both morning and night for two minutes with

DENTAL TRIBUNE

The World's Dental Newspaper - US Edition

Publisher & Chairman

Torsten Oemus
t.oemus@dental-tribune.com

Vice President Global Sales

Peter Witteczek
p.witteczek@dental-tribune.com

Chief Operating Officer

Eric Seid
e.seid@dental-tribune.com

Group Editor & Designer

Robin Goodman
r.goodman@dental-tribune.com

Editor in Chief Dental Tribune

Dr. David L. Hoexter
d.hoexter@dental-tribune.com

Managing Editor/Designer

Implant, Endo & Lab Tribunes
Sierra Rendon
s.rendon@dental-tribune.com

Managing Editor/Designer

Ortho Tribune & Show Dailies
Kristine Colker
k.colker@dental-tribune.com

Online Editor

Fred Michmershuizen
f.michmershuizen@dental-tribune.com

Product & Account Manager

Mark Eisen
m.eisen@dental-tribune.com

Marketing Manager

Anna Włodarczyk
a.wlodarczyk@dental-tribune.com

Sales & Marketing Assistant

Lorrie Young
l.young@dental-tribune.com

C.E. Manager

Julia E. Wehkamp
j.wehkamp@dental-tribune.com

Dental Tribune America, LLC
116 West 25rd Street, Suite 500
New York, NY 10011
Tel.: (212) 244-7181
Fax: (212) 244-7185

Published by Dental Tribune America
© 2010 Dental Tribune America, LLC
All rights reserved.

Dental Tribune strives to maintain the utmost accuracy in its news and clinical reports. If you find a factual error or content that requires clarification, please contact Group Editor Robin Goodman at r.goodman@dental-tribune.com.

Dental Tribune cannot assume responsibility for the validity of product claims or for typographical errors. The publisher also does not assume responsibility for product names or statements made by advertisers. Opinions expressed by authors are their own and may not reflect those of Dental Tribune America.

Editorial Board

Dr. Joel Berg
Dr. L. Stephen Buchanan
Dr. Arnaldo Castellucci
Dr. Gorden Christensen
Dr. Rella Christensen
Dr. William Dickerson
Hugh Doherty
Dr. James Doundoulakis
Dr. David Garber
Dr. Fay Goldstep
Dr. Howard Glazer
Dr. Harold Heymann
Dr. Karl Leinfelder
Dr. Roger Levin
Dr. Carl E. Misch
Dr. Dan Nathanson
Dr. Chester Redhead
Dr. Irwin Smigel
Dr. Jon Suzuki
Dr. Dennis Tartakow
Dr. Dan Ward

Tell us what you think!

Do you have general comments or criticism you would like to share? Is there a particular topic you would like to see more articles about? Let us know by e-mailing us at feedback@dental-tribune.com. If you would like to make any change to your subscription (name, address or to opt out) please send us an e-mail at database@dental-tribune.com and be sure to include which publication you are referring to. Also, please note that subscription changes can take up to 6 weeks to process.

AD



Universal and scanable registration material >> recommended by SIRONA for CEREC Bluecam

METAL-BITE™ Blue

- High final hardness - Shore-D 38
- Setting time about 60 s
- Scanable for powderless 3D-data registration of antagonists (CAD/CAM)
- High brightness and contrast
- Perfect physical parameters
- 2 Cartridges + 12 Mixing cannulas

Available at
PATTERSON DENTAL
pattersondental.com

R-dental
Dentalerzeugnisse GmbH
E-mail: info@r-dental.com
r-dental.com 

→ DT page 4A

REGISTER FOR The Future of Dentistry

What's In, What's Out: Materials and Methods to Keep You on the Cutting Edge

EXIT 1A

Complacency
This Lane
Achievers
Merge Right



**MOTIVATION
SOLUTIONS
SUCCESS**

This EXIT
10 Miles
25 Miles

Just because the economy is unstable does not mean that your practice has to be.

LVI will steer you in the right direction!

Now is the time to take the driver's seat and invest in yourself and your future.
Recession-proof your practice with an education from LVI.

Bring a new enthusiasm to yourself, your practice, your team, and your patients!
You can have the practice of your dreams, and we can show you how.

Stockton, CA	October 22-23	Pittsburgh, PA	November 19-20	Santa Barbara, CA	March 4-5
Moncton, NB	October 22-23	Kitchener, ON	November 26-27	Tampa, FL	March 18-19
Littleton, CO	October 22-23	2011 Events		Sarasota, FL	March 25-26
Madison, WI	October 22-23	Houston, TX	February 4-5	Arcadia, CA	March 25-26
Kansas City, MO	October 29-30	Park City, UT	February 11-12	Shreveport, LA	April 1-2
Minneapolis, MN	November 5-6	Lubbock, TX	March 4-5	Yuma, AZ	April 1-2
Carlsbad, CA	November 12-13	Phoenix, AZ	March 4-5	Galveston, TX	April 15-16

LVI is bringing 11 CE credits TO YOU with
The Future of Dentistry in your area!

For complete details visit www.LVIRegionalEvents.com

No Interest Tuition Financing Available Through **ChaseHealthAdvance**™ FINANCING OPTIONS | **CHASE**

If paid in full within the promotion period of 12 months. Interest will be charged to your account from the purchase if the balance is not paid in full within the promotional period 12 months, if you make a late payment, or if you are otherwise in default.

ADA CERP® | Continuing Education Recognition Program

LVI Global is an ADA CERP Recognized Provider. ADA CERP is a service of the American Dental Association to assist dental professionals in identifying quality providers of continuing dental education. ADA CERP does not approve or endorse individual courses or instructors, nor does it imply acceptance of credit hours by boards of dentistry. LVI Global designates this activity for 11 continuing education credits.



Sponsored by



CHANGING DENTISTRY. CHANGING LIVES.

Academy of General Dentistry
Approved PACE Program Provider
FAGD/MAGD Credit
6/1/2007 to 5/31/2011

Check with your provider to see which plans are available. Available for purchases of \$1,000.00 or more. Interest will accrue during the promotional period at an APR of 24.75% to 27.99% (depending on creditworthiness). Your actual APR will be stated at the time of purchase. A Penalty Rate of 29.99% will be applicable if your minimum payment is not received within 60 days of the due date if stated at the time of purchase. Due Date Change Fee \$15. Minimum finance charge \$.50. See your Purchase Acknowledgement and ChaseHealthAdvance Revolving Account Agreement for more information about this Promotion. Please read that material carefully.

Dental practice audits

By Stuart J. Oberman, Esq.

Dental audits were rare at one time. Now, however, with insurance companies and third-party payers auditing more routinely, it is much more likely that a dental practice will face an audit. Most dental practices that are contracted with dental plans are audited at least once during the course of their practice.

Many of these dentists are left wondering why audits are becoming a more routine exercise of third party payers. The answer: alarming statistics. The FBI estimates that 10 percent of the money expended on health care is due to fraudulent activity. Insurance companies estimate that fraudulent health-care billing represents up to \$10 billion each year.

In addition, Medicare fraud is becoming more rampant. The United States General Accounting Office estimated that out of every \$7 spent on Medicare, \$1 is lost to Medicare fraud. Fraud is adding enormous costs to the nation's health-care system. As more fraudulent health-care charges rack up for insurance companies to pay, insur-



(Photo/Elenathewise, Dreamstime.com)

ance companies are becoming serious about auditing health-care practices. With a thorough understanding of the audit process, dentists will be better prepared for what appears to be the inevitable.

Why me?

After receiving notice of an impending audit, dentists often wonder why their practice has been targeted. Generally, the audits conducted by dental plans and third-party payers are a method of showing state regulators that the patients are receiving quality care. A third-party payer is an organization other than the patient (which would be the first party) or health-care provider (also known as the second party)

involved in the financing of health care services.

The audits are typically meant to check the status of a dental plan and are not meant to be a check on the specific dental practice. The selection process third parties undertake to audit a given dental practice varies. Third parties may randomly pick dental practices based on how likely the practice is to have discrepancies once audited. The third party's goal is to recoup lost dollars, and so this strategy is chosen to allow a third party to obtain the largest return.

A dental practice is most likely to be audited after submitting atypical claims online. A third-party payer analyzes each claim submitted. The auditors flag abnormal or atypical charges as these may suggest provider abuse. Additionally, third parties track information on practice charges by analyzing the average cost per claim, average cost per person and how often certain treatments are performed. With this information, the third parties target specific dental practices for an audit.

An auditor's goals

Auditors typically share common goals. By conducting audits, third party payers are attempting to prevent abuse of the payment system. By performing audits on practices, dentists are forced to understand the importance of keeping records and submitting only honest and accurate claims.

Also, dentists are more likely to keep accurate records and submit truthful claims when they know an audit may be lurking than if they assume their dental practice will never face an audit.

A second goal ties in with the first, and that is to help dentists understand and follow the third-party payer's guidelines. Finally, the auditors are trying to find instances of overpayments to dental practitioners for claims the dental practice has submitted.

The audit process: first contact

Many dentists want to know what to expect if their practice is hit with an audit. First, the dentist will most likely be notified of the impending audit by a letter, however, the third-party payer may make initial contact with the dental practice by telephone. When a telephone call takes place, a day and time for the audit will be arranged, and the dentist should ascertain what type of audit will be conducted.

It is also advisable to ask why the audit is being performed. The answer may be that it was simply a random selection, but a dental practitioner should make certain that it was not because of a claim submission that the third-party payer flagged as abnormal.

Auditors and file access

When auditing the dental practice, the insurance plan will most likely send representatives to the dental practice to ensure that billing claims match documentation in patient files. Auditors will analyze whether amounts paid to the practice were for an actual member of their insurance plan, whether the services rendered were actually provided according to treatment plans and whether the services provided by the dentists were in accord with federal law.

Additionally, auditors may analyze patient files. Auditors may be interested in reviewing patient medical histories, dental histories, documentation of oral examinations, treatment notes, diagnosis, procedures completed, the outcome of each procedure and follow-up care. It is also possible that documentation supporting submitted claims will be requested during an audit.

Problems encountered during audits are most likely due to improper documentation of records rather than by fraudulent billings. The dentist is typically without recourse if the records in the patient file do not match up with the claims billed.

Various state laws and the HIPAA (Health Insurance Portability and Accountability Act) privacy rule permit third-party payers to access and review the health records of their own members. However, third-party payers are no longer permitted to access the records of patients who are not enrolled in their plans like they were in the past. Therefore, third-party payers are no longer able to compare

AD

WELCOME
TO THE
6th Annual
Dental Office Managers Conference
LAS VEGAS
NEVADA

OCTOBER 22-23, 2010
LAS VEGAS, NEVADA

Don't miss the premier educational and networking event for dental administrative professionals!
SPACE IS LIMITED! For more details or to register, visit www.dentalmanagers.com or call 732-842-9977.

ICE ADMINISTRATORS • INSURANCE & FINANCE COORDINATORS • PA
COORDINATORS • OFFICE MANAGERS • PATIENT & TREATMENT COO
ERS • PRACTICE ADMINISTRATORS • INSURANCE & FINANCE COORDINA
ORS • OFFICE MANAGERS • PATIENT & TREATMENT COORDINATORS

Proudly presented by:
American Association of
Dental Office Managers
Work Smarter, by Association

www.dentalmanagers.com

← **DT** page 2A

fluoride toothpaste and visit their dentist as often as recommended. Sugary foods and drinks can damage the teeth. Instead, replace these with healthy snacks such as cheese, raw vegetables, seeds, bread, crackers, breadsticks and fruit, and try to encourage children to drink more milk and water. Parents should try

and reduce the number of 'snack attacks' to no more than three meals and two snacks a day."

"These simple changes to a child's diet and oral health routine can really help decrease risks of tooth decay and other oral health problems," Carter said. **DT**

(Source: British Dental Health Foundation)

their enrollees' records and charges with those of patients not enrolled under their plans.

Beyond patient files

Aside from auditing the patient files, the third-party payer may also access the quality of the facility, the maintenance of the equipment, the level of difficulty patients on their plan encounter in obtaining appointment times, and the level of compliance with federal regulations during the course of the audit.

It is prudent that the dentist remains with the auditor at all times. It is worth the time to clear the calendar on the day of the audit and to stay with the auditor as patient and billing records are reviewed. Also, the staff of the dental practice should be prepared for the audit, and the dentist should discuss the procedures to be followed before the day it is conducted.

Because dental audits are becoming a routine part of doing business, dentists must protect their practice by preparing their office for an audit.

To prevent audit problems, dentists should make themselves aware of terms of any third-party contracts, keep the plan manuals in a safe place so the dentist can refer back to them, ensure each procedure performed matches the procedure billed and ensure that all patient records are organized and contain all relevant information on each patient.

Also, when claims are filed online, ensure that the correct price is sent to the third-party insurer.

With a more thorough understanding of third-party audits and the third-party payer's motivation for conducting them, dentists will be more likely to avoid costly mistakes. **DT**

Papillary squamous cell carcinoma of the hard palate

Report of a rare case affecting the oral cavity

By Paul C. Lee, BA; Justin Olsen, BS; Joshua Adcox, BS and Parish P. Sedghizadeh, DDS, MS

Approximately one in three Americans will develop a malignancy in their lifetime.¹ The chances of developing certain malignancies increase with age and several contributing risk factors such as tobacco and alcohol use. Notwithstanding

significant decreases in death rates from heart disease, cerebrovascular disease and infections over the previous 50 years for many forms of cancer, death rates remain essentially unchanged during that same time period.¹

Squamous cell carcinoma (SCC) is the most common malignant neoplasm affecting the head and neck. Mucosal cases account for more

than 90 percent of all malignant neoplasms affecting oropharyngeal structures, with oral squamous cell carcinoma (OSCC) being the most common oral malignancy.²

Several variants of OSCC exist and histopathologic classifications for variants of OSCC include papillary, spindle cell, adenosquamous,

→ **DT** page 6A

AD

About the author



Stuart J. Oberman, Esq., has extensive experience in representing dentists during dental partnership agreements, partnership buy-ins, dental MSOs, commercial leasing, entity formation (professional corporations), limited liability companies, real estate transactions, employment law, dental board defense, estate planning, and other business transactions that a dentist will face during his or her career.

For questions or comments regarding this article, visit www.gadentalattorney.com.

THE SHOFU CHALLENGE

Compare and Save

OneGloss[®] Super-Snap[®]

to other leading brands

GET A FREE SAMPLE
Visit www.shofu.com
Enter code: **DTWOGSS10**
while supplies last

Proven to outperform the leader* at almost half the cost!

- Finish and polish
- Fast and easy
- Disposable and a GREAT VALUE

Quality · Performance · Value

Visit www.shofu.com or call 800.827.4638

Shofu Dental Corporation • San Marcos, CA

*Super-Snap Singles won THE DENTAL ADVISOR 2010 Top Composite Finishing & Polishing System Award.

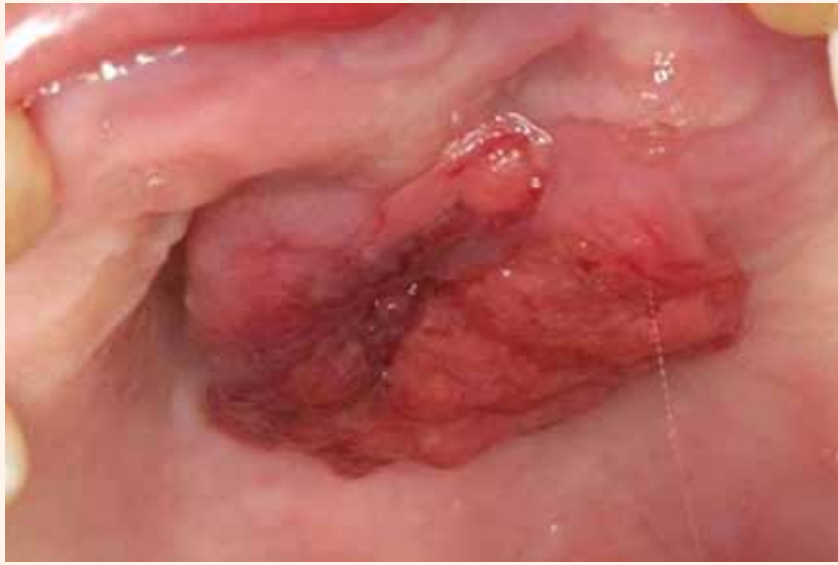

Fig. 1: Clinical image of the palate of a 63-year-old female showing an erythematous exophytic mass with a cauliflower-like or papillary surface architecture. (Photos/Provided by Paul Lee)

← DT page 5A

and basaloid carcinoma; it is also possible to categorize types of OSCC based on clinical descriptors such as ulcerative, flat, polypoid and verrucoid.² OSCC variants can have different growth patterns, ranging from small mucosal thickenings to large masses, and can appear endophytic or exophytic.

These tumors are erythematous to

white to tan, frequently feeling firm on palpation. Conventional OSCC is composed of variable degrees of squamous differentiation, with well-differentiated cells closely recapitulating normal squamous epithelium but demonstrating some degree of basement membrane violation by nests of tumor cells, to poorly differentiated cells with more anaplastic-like appearances.

As a result of its complex exophytic papillary architecture, the

papillary variant of SCC can be a challenge to accurately diagnose and histologic assessment of underlying invasion can be very difficult.⁵ Risk factors and pathogenesis for papillary SCC are unclear although human papilloma virus subtypes are thought to play a role in some cases.⁵

The purpose of this paper is to (a) present a rare case of papillary OSCC affecting the hard palate, and (b) describe the clinical and histologic features of this tumor in supporting the dentist's role in early detection.

Case report

A 63-year-old female presented to the dental clinic at the Herman Ostrow School of Dentistry, University of Southern California with the chief complaint of a growth appearing on the roof of her mouth approximately two months prior to her presentation to our clinic. The patient's past medical history included type II diabetes mellitus controlled with diet and exercise, and denial of any alcohol or tobacco use.

The remainder of her medical and social history was non-contributory; she was not taking any medications and a review of systems was unremarkable. Intraoral examination revealed a 3.5 cm exophytic mass in the anterior midline region

of the hard palate (Fig. 1). The lesion appeared vascularized with ill-defined borders and no evidence of ulceration or erosion.

The patient had mild sensitivity upon palpation of the lesion. No cervical or submandibular lymphadenopathy was observed during the extraoral examination of the head and neck. Panoramic radiography revealed no abnormalities of the palatal area.

The patient was informed that a biopsy must be taken to obtain a definitive diagnosis; informed consent was obtained for incisional biopsy with local anesthesia. During the administration of local anesthesia, the cortical bone under the tumor felt intact with the end of the needle. A representative wedge of tissue was removed and placed in 10 percent formalin for microscopic evaluation.

The biopsy site was cauterized to obtain postoperative hemostasis due to the high degree of vascularity. The biopsy site was closed with four 3.0 chromic gut interrupted sutures. Hemostasis was achieved, postoperative instructions were given and the patient's postoperative condition was good.

The gross examination of the specimen consisted of a soft, tan papillary and friable mass. The his-

AD



ANNUAL DENTAL TRIBUNE STUDY CLUB
SYMPOSIA AT THE GNYDM
NOVEMBER 28 – DECEMBER 1, 2010, 10:00 AM DAILY



For the third year in a row, the DTSC hosts its annual CE Symposia at the GNYDM, offering four days of focused lectures in various areas of dentistry. Find us on the Exhibition Floor in Aisle 6000, Room # 3.



SUNDAY, NOVEMBER 28

10:00 - 11:00 Howard Glazer, DDS, FAGD
BEAUTIFIL: GO WITH THE FLOW - COURSE: 3020

11:20 - 12:20 John Flucke, DDS
LIGHT CURED ADHESIVE DENTISTRY - SCIENCE AND SUBSTANCE - COURSE: 3030

1:20 - 2:20 Martin Goldstein, DMD
A SIMPLIFIED APPROACH TO MULTI-LAYER DIRECT COMPOSITE BONDING - COURSE: 3040

2:40 - 3:40 Jay Reznick, DMD, MD
3D IMAGING AND CT-GUIDED DENTAL IMPLANT SURGERY - 3050

4:00 - 5:00 Louis Malcmacher, DDS, MAGD
TOTAL FACIAL ESTHETICS FOR EVERY DENTAL PRACTICE - COURSE: 3060

MONDAY, NOVEMBER 29

10:00 - 11:00 Mrs. Noel Brandon-Kelsch
ECO-FRIENDLY INFECTION CONTROL-UNDERSTANDING THE BALANCE - COURSE: 4120

11:20 - 12:20 Gregori Kurtzman, DDS
INCORPORATING NEW ADVANCES IN DENTAL MATERIALS AND TECHNIQUES INTO YOUR RESTORATIVE PRACTICE - COURSE: 4130

1:20 - 2:20 Damien Mulvany, DDS
OPTIMIZING YOUR PRACTICE WITH 3D CONE-BEAM TECHNOLOGY - COURSE: 4140

2:40 - 3:40 Edward Katz, DDS
IMPROVING PATIENT CARE WITH 3D CONE BEAM COMPUTERIZED TOMOGRAPHY - COURSE: 4150

4:00 - 5:00 George Freedman, Fay Goldstep and Edward Lynch
SOFT TISSUE LASERS AND CARIES DIAGNOSIS - COURSE: 4160

TUESDAY, NOVEMBER 30

10:00 - 11:00 George Freedman, Fay Goldstep and Edward Lynch
SOFT TISSUE LASERS AND CARIES DIAGNOSIS - COURSE: 5110

11:20 - 12:20 Greg Diamond, DDS
LASERS IN PERIODONTAL THERAPY - COURSE: 5120

1:20 - 2:20 Dov Almog, DMD
INTRODUCTION TO CONE BEAM CT (CBCT), ESPECIALLY AS IT PERTAINS TO PREVENTION OF FAILURES IN ORAL IMPLANTOLOGY - COURSE: 5130

2:30 - 3:30 Maria Ryan, DDS, PhD
DETECTING CORONARY HEART THROUGH PERIODONTITIS AND PERIIMPLANTITIS - COURSE: 5140

4:00 - 5:00 Dwayne Karateew, DDS
CONTEMPORARY CONCEPTS IN TOOTH RELACEMENT: PARADIGM SHIFT - COURSE: 5150

WEDNESDAY, DECEMBER 1

10:00 - 11:00 Mr. Al Dube
BEST MANAGEMENT PRACTICE, WASTE MANAGEMENT FOR THE DENTAL OFFICE, AND OSHA COMPLIANCE - COURSE: 6060

11:20 - 12:20 Glenn van As, DMD
HARD AND SOFT TISSUE LASERS - COURSE: 6070

12:45 - 4:45 Dr. Benedict Bachstein, Dr. David Hoexter, Dr. Jeffery Hoos, Dr. Dwayne Karateew, Dr. Enrique Merino, Dr. Ethan Pansick
THE FIRST ANNUAL OSSEO UNIVERSITY SUMMIT: IMPLANT DRIVEN DENTISTRY - COURSE: 6080

THIS PROGRAM IS SUBJECT TO CHANGE

PLEASE FIND FURTHER PROGRAM AND SPEAKER DETAILS UNDER WWW.DTSTUDYCLUB.COM/GNYDM



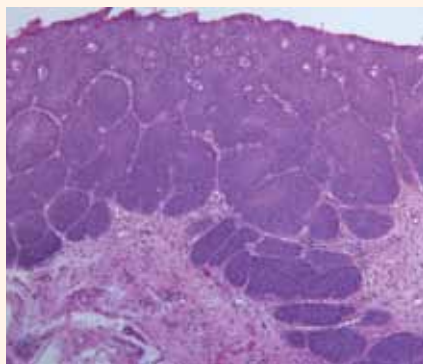


Fig. 2: Histopathologic evaluation demonstrates abnormal mucosa with a micropapillary surface morphology and marked maturational perturbations in association with acute and chronic inflammatory cells (H&E, 20x original magnification).

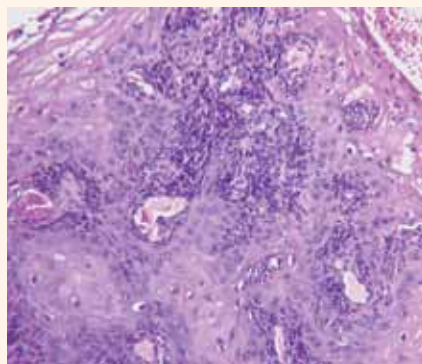


Fig. 3: Histopathologic evaluation reveals invasive islands and cords of malignant epithelium in addition to dyskeratosis and early keratin pearl formation (H&E, 20x original magnification).

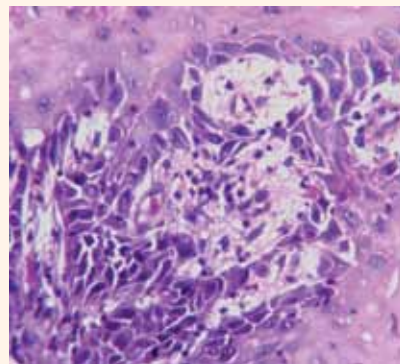


Fig. 4: Histopathologic evaluation of invasive cords of mucosa at high power magnification shows cellular and nuclear pleomorphism, hyperchromatism, acantholysis, dyskeratosis, prominent nucleoli and increased nuclear-to-cytoplasmic ratios (H&E, 40x original magnification).

topathologic evaluation revealed an exophytic, papillary proliferation of surface mucosa showing marked maturational perturbations. It included cellular and nuclear pleomorphism, prominent nucleoli, hyperchromatism, acantholysis, increased mitotic activity and abnormal mitotic figures, dyskeratosis and keratin pearls, and increased nuclear-to-cytoplasmic ratios.

Invasive cords and islands of malignant mucosa were visualized and the associated connective tissue contained an influx of acute and chronic inflammatory cells. To evaluate whether the inflammatory infiltrates observed in the cancerous tissue were in response to superimposed fungal infection (because organisms such as *Candida albicans* are common oral inhabitants), periodic-acid Schiff staining was conducted and determined to be negative with appropriate staining of control tissue.

The patient was referred to the head and neck oncology group at the University of Southern California, Los Angeles County Hospital and Keck School of Medicine. Clinical work-up for staging was performed and computerized tomography scans of the head, neck and chest were determined to be negative for metastatic disease; the lesion was staged at T2N0M0.

The patient underwent tumor resection with 1 cm margins and suprahyoid neck dissection, with no radiation or chemotherapy. Her postoperative course was uneventful, and histopathologic analysis confirmed a diagnosis of papillary OSCC.

The dissected lymph nodes showed no metastatic involvement, confirming that the surgical margins were tumor free. There was no clinical evidence of recurrence at 6-months follow-up.

Discussion

The typical presentation for OSCC can be either a symptomatic or asymptomatic mucosal ulcer. These superficial ulcers often progress into symptomatic or asymptomatic exophytic or endophytic nodules with eroded or ulcerated surfaces, and can progress to direct invasion of the deeper structures resulting in a firm,

non-movable mass.¹

However, OSCC often begin as white or red plaques of surface mucosa, making early clinical detection possible. If a leukoplakic or erythroplakic lesion appears in the oral cavity and does not heal within a few weeks, biopsy is recommended for definitive diagnosis, which may represent levels of histologically normal tissue (e.g., keratosis) to atypia, dysplasia, carcinoma in situ or overt carcinoma.¹

Papillary OSCC, such as the case presented here, is a variant of SCC as classified by the World Health Organization⁴ and can present as either in situ or invasive lesions.⁵ Male predominance exists in OSCC cases, and the sites most commonly affected in order of prevalence are the larynx, nasal cavity and oral cavity.^{2,5}

The clinical appearance of papillary OSCC often mimics other variants such as verrucous carcinoma, which is included in a differential diagnosis until confirmation with microscopic examination and diagnosis.⁵

Microscopically, OSCC can show invasive and disorganized growth with the following: dyskeratosis, keratin pearls and intercellular bridges, increased nuclear-to-cytoplasmic ratios, nuclear chromatin irregularities, prominent eosinophilic nucleoli and increased mitotic figures with atypical formation. Perineural invasion can be seen in some lesions, presenting a positive correlation to metastatic potential.¹ In this case presentation, many of the aforementioned microscopic features of OSCC were evident without evidence of perineural invasion.

Early detection of OSCC, specifically stage I or II diagnosis, is usually associated with a favorable prognosis. Papillary OSCC in general has a 70 percent, five-year survival rate at any stage, and at T1 it carries a 100 percent survival rate⁶ compared to other variants, such as basaloid (40 percent, two-year survival), adenosquamous (55 percent, two-year survival), and spindle cell (80 percent, five-year) carcinomas.² Most reported cases of papillary SCC exhibit a mean diameter of 1 to 1.5 cm². Our patient presented with a relatively large lesion measuring

over 3 cm in diameter.

Dentists have a critical role in early identification of and effective care during OSCC progression from premalignant lesion to malignancy.⁷ A study conducted to evaluate the effectiveness of dentists in the early detection, treatment and post-operative care of OSCC in a central European population revealed the following results: Dentists identified 72.5 percent of the tumors in the 608 patients they saw as malignant, while family physicians did

so in only 40.11 percent of their 406 patients. This difference was statistically significant ($P < .001$).⁸

OSCC is a major public health problem that is not just limited to certain risk groups, such as those who smoke and drink as in this case report. Early detection and identification of OSCC is critical to patient treatment and survival. **□**

A complete list of references is available from the publisher

About the authors

Paul C. Lee, BA; Justin Olsen, BS; and Joshua Adcox, BS, are dental students at the Herman Ostrow School of Dentistry of USC, University of Southern California, Los Angeles. Parish P. Sedghizadeh, DDS, MS, is an assistant professor at the Herman Ostrow School of Dentistry of USC, University of Southern California, Los Angeles.

For correspondence:

Paul C. Lee
925 West 34th Street, DEN 4110
University of Southern California,
School of Dentistry
Los Angeles, Calif. 90089-0641
E-mail: chong.lee@usc.edu

AD

STABILIZE · CUSHION · RETAIN

"Two and a half years ago I tried 5 different mini implant systems for denture stabilization. While all systems produced results, I quickly settled on Atlas Denture Comfort as my favorite due to its flapless surgical protocol, low-profile retentive head and easy maintenance. It's as simple as placing a post and doing a refine."

—Neils Ewoldsen, DDS, MSD, York, PA

ATLAS[®] Denture Comfort NARROW-BODY IMPLANTS

THE EASY-TO-LEARN ATLAS DENTURE COMFORT TECHNIQUE

It's the perfect system to start treating your mandibular denture patients, all without O-rings, housings or adhesives. The low start up costs and economically priced implants make it easy for you to expand into this modality at your own pace.

- Grow Your Practice
- Life Changing for Your Patients
- Easy to Learn & Implement

HANDS-ON WORKSHOP

Nov 5 – Charlotte, NC
Nov 5 – Boston, MA
Nov 19 – Cincinnati, OH
Dec 10 – Salt Lake City, UT

For additional courses and more information on educators visit www.dentatus.com

Call the Henry Schein Implant Team at (877) 537-8862
www.denturecomfort.com

Available in the US exclusively through:

©2010 Dentatus USA, Ltd. - Patented and Patents Pending

Santa Barbara hosts a dentist's look through the microscope

The Academy of Microscope Enhanced Dentistry's 9th Annual Meeting and Scientific Session will be held Nov. 4-6 in Santa Barbara, Calif., at Fess Parker's Double Tree Resort. The theme is "The Intersection of Macro & Micro Dentistry."

The meeting will feature lectures from top clinicians in every discipline as well as master classes, corporate forums and pre- and post session, comprehensive, hands-

on courses at education facilities along the Pacific coast.

If you have not registered for the meeting yet, you may register online and view the complete schedule at www.microscope-dentistry.com. Your pre-registration helps AMED plan and prepare so please make your registration as soon as possible.

During the meeting there will also be special events that accom-

panying guests will be sure to enjoy. Call (800) 564-4333 to make your hotel reservations.

You may also become an AMED fan on Facebook at www.facebook.com/microscope-dentistry. See you in Santa Barbara!

The daily schedule for the event follows.

Thursday, Nov. 4

- 7 a.m., registration and exhib-

its open

- 9:30 a.m.-1:30 p.m., spouse/guest event, Lotus land garden tour (there is a fee for this event)

- 8 a.m.-12:45 p.m., general session

~ John West, DDS, MSD, President's Welcome

~ Cliff Ruddle, DDS, My Endodontic Practice: A 35-year Retrospective Analysis

~ Terrel Pannkuk, DDS, MScD, The Endo/Perio Differential Diagnosis

~ Paul Anstey, DDS, The Power of 3-D Imaging in Endodontics and Beyond

~ Tetsuya Hirata, DDS, PhD, What I Learned During Eight Years of Research Study in Image Enhanced Dentistry

~ Cheryl Sheets, DDS, Quantitative Percussion Diagnostics and Magnification: A Synergistic Combination

- 12:45-1 p.m., members' business meeting

- 12:45-2 p.m., luncheon buffet

• 2-5 p.m., Endo Master Class
~ Carlos Murgel, DDS, Small FOV CBCT for Endodontics: Another Gadget or a Paradigm Shift?

~ Terrel Pannkuk, DDS, MScD, Outcome Study Science and Art: Can the Value of an Endodontic Technique or Technology Be Adequately Assessed?

~ Morlo Okaguchi, DDS, Microscope Assisted Precision Dentistry II
~ Eudes Gondim, DDS, PhD, Beyond the Microscope: What Else Can Make the Difference?

~ John West, DDS, MSD, speakers' panel moderator

• 2-5 p.m., Perio Master Class
~ Markus Hürzeler, DMD, PhD, Minimally Invasive Implant Surgery Supported by Microsurgical Techniques

~ Adriana McGregor, DDS, The Hidden Secrets of Outstanding Results in Soft-tissue Management Around Implants: From Planning to Placement to Restoration

~ Te-Fu Li, DDS, Micro-invasive Treatment of Periodontal Pockets

~ Katsuhiko Akiyama, DDS, Papilla Reconstruction Using the Patch Technique

~ Bryan Pearson, DDS, MS, speakers' panel moderator

- 2-5 p.m., Restorative Master Class

~ Kunio Matsumoto, DDS, Pre-Treatment in Esthetic Restoration

~ Masayuki Okawa, DDS Minimally Invasive Interventions and Interdisciplinary Approach for Esthetic Dentistry

~ José Roberto Moura, DDS, Art and Precision with Direct Composites

~ Claudia Cia Worschech, DDS, PhD, Obtaining Clinical Success

AD

YANKEE
Dental Congress® 36

Boston Convention & Exhibition Center
JANUARY 26-30, 2011
EXHIBITS: JANUARY 27-29, 2011

Your Dental Connection

- ◆ **INNOVATION**
450+ Exhibitors, High-Tech Playground, and Dental Office Design Pavilion
- ◆ **EDUCATION**
Over 300 Courses Featuring Live Patient Demonstrations, Endodontic and Periodontic Fast Tracks, Hands-on Courses, and More
- ◆ **COLLABORATION**
Networking Lounge, Receptions Galore, and Fat Thursday Carnival

NEW REGISTRATION GROUP DISCOUNT
Your Entire Dental Team Can Get Connected
Register 4 dental professionals from the same office and the 5th goes FREE*
*SOME RESTRICTIONS APPLY

Get Connected - Registration is Now Open!
yankeedental.com + 877-515-9071

with Micro Laminate Porcelain Veneers

~ Assad F. Mora, DDS, MSD, FACP, speakers' panel moderator

• 7-11 p.m., Social Event: Welcome reception, entertainment and dance

Friday, Nov. 5

• 8 a.m., registration and exhibits open

• 8 a.m.-5 p.m., Test Drive the Latest Technology

• 9 a.m.-12:45 p.m., general session

~ Larry Rifkin, DDS, Facial Esthetics

~ Glenn vanAs, DDS, Lasers and the Operating Microscope: Seeing the Light!

~ Marc Alexander, DDS, Treatment Planning for Esthetics

~ Paul Piontkowski, The Perfect CAD/CAM Restoration

• 2-5 p.m., short presentations

~ Randy Shoup, DDS, Minimally Invasive Restorative Dentistry: Live Demonstration of Principals, Techniques, Equipment and Materials

~ Junya Okawara, DDS, Periodontal Microsurgery: Achieving Gingival Level Alignment with Connective Tissue Graft

~ Cami Ferris, DDS, Heroic Endodontics in an Age of Implants

~ Masahiro Nakazawa, DDS, Utility of All-on-4 with Socket Preservation

~ Kazuo Kurihara, DDS, Tissue Management Around Implants in Esthetic Zones

~ Stephane Browet, DDS, The Matrix Revisited

• 2-5 p.m., corporate forums

~ BioClear Composites Hands-on Course (there is an additional cost for this course)

~ Global Surgical

~ AMD Lasers

~ Crystal Mark & GC America: Air Abrasion

• 2-3:30 p.m., spouse/guest event: Land shark tour (there is a fee for this event)

• 7-11 p.m., social event: president's dinner and awards

Saturday, Nov. 6

• 8 a.m. registration and exhibits open

• 9 a.m.-1:30 p.m., Test Drive the Latest Technology

• 9 a.m.-1:30 p.m., general session

~ Dennis Shanelec, DDS, A Retrospective of Clinical Periodontal Microsurgery

~ Jeff Hamilton, DDS, Oral Medicine and the Clinical Operating Microscope

~ Eric Herbranson, DDS, The Latest in Photographic Documentation

~ Peter J. Jannetta, MD, Neurogenic Face Pain in the Dental Office

~ Malcolm Snead, DDS, PhD, Thinking the Unthinkable: Regenerating the Whole Tooth

• 1:30 p.m., adjourn

~ Off-site hands-on courses

~ Pre & post session hands-on courses will be held at the Microsurgery Training Institute

Social events and tours

• Santa Barbara Back-Country Wine Tour, Nov. 10, a.m.-4:30 p.m.

Enjoy lush valley views, breathtaking scenery and stops at four of the region's best wineries for tastings and a gourmet picnic lunch at one of the vineyards.

Journey back to Santa Barbara through oak-shaded canyons and dirt trails, past the former Reagan Ranch and along the beautiful Pacific.

• Spouse/guest event: LotusLand garden tour with lunch, Nov. 4, 9:30 a.m.-1:30 p.m.

You are invited to visit Lotusland, a unique 57-acre estate and botanic garden situated in the foothills of Montecito to the east of the city of Santa Barbara. Visit www.lotusland.org for more information.

• Welcome reception, entertainment and dancing, Nov. 4, 7-11 p.m.

This event is an opportunity for members and guests from around the world to meet face to face. Enjoy a Santa Barbara themed dinner, entertainment and dancing. Attire is California casual.

• Spouse/guest event: Santa Barbara's land shark tour, Nov. 5, 2-3:30 p.m.

Climb aboard Santa Barbara's original amphibious tour vehicle for a personally narrated 90-minute land and sea adventure. Enjoy exquisite views of the Santa Barbara coastline, the Riviera and the Santa Ynez mountains as seen only from our boat at sea.

• President's dinner and awards,

Nov. 5, 7-9:30 p.m.

Enjoy an elegant evening during AMED's annual President's Dinner and short awards presentation ceremony. Attire for this event is semi-formal. www.amed.org

AMED Program Co-chairs: Drs. William Lannan and John West

AMED Scientific Session Committee: Drs. Terry Pannkuk, Adriana McGregor and Tetsuya Hirata

Contact information:

Academy of Microscope Enhanced Dentistry

P.O. Box 15834

Fort Wayne, Ind. 46885

Phone: (260) 249-1028

www.microscopdentistry.com

AD

EMS-SWISSQUALITY.COM



EMS
ELECTRO MEDICAL SYSTEMS

SUBGINGIVAL WITHOUT LIMITS

THE DEEPEST
PERIODONTAL POCKETS
NOW WITHIN REACH
WITH THE ORIGINAL
AIR-FLOW METHOD



> Subgingival application of the Original AIR-FLOW® method reduces periodontal pocket depth, removes biofilm, prevents periimplantitis

AIR-FLOW®
KILLS
BIOFILM
ems-swissquality.com

AIR-FLOW MASTER®
is the name of the world's first subgingival prophylaxis unit. With two application systems in one. For sub- and supragingival use with matching handpiece and powder chamber.

Incredibly easy to operate. Uniquely simple to use.

Touch 'n' flow: Highly sensitive 3-touch panel for easy choice of settings.



The inventor of the Original Air-Flow Method is now first to cross the boundaries of conventional prophylaxis.

"I FEEL
GOOD"

For more information > welcomes@ems-ch.com