

JULY 2011

www.implant-tribune.com

VOL. 6, No. 7

## INDUSTRY CLINICAL

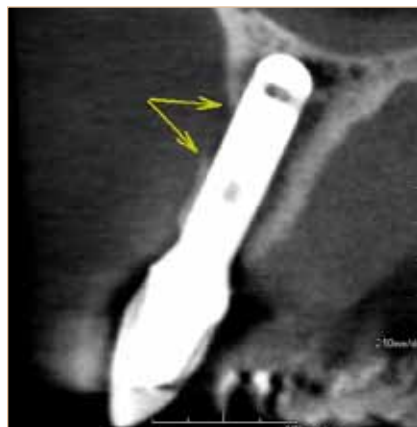

Fig. 1: Sagittal CBCT MPR showing bone defect at point of dehiscence of the implant coating.

## Clinical and diagnostic advantages of PreXion 3-D imaging system

By Dan McEowen, DDS

For nearly 100 years, dentists have relied on 2-D radiographic imaging for diagnosis and treatment planning. With the 1999 introduction of cone-beam computed tomography (CBCT), all dentists now have tools available for more accurate diagnosis and treatment.<sup>1</sup>

The ability to look at a tooth in any direction and orientation, as well as in 3-D, eliminates much of the guesswork commonly experienced with 2-D radiographs.

We have been limited in most cases to only a buccal-lingual view provided by periapicals, bitewings and panoramic radiographs with the occasional axial view of an occlusal film. Medical CT scans and images began in the early 1970s and were sometimes used by dentists, offering our first multi-planer views.<sup>2</sup>

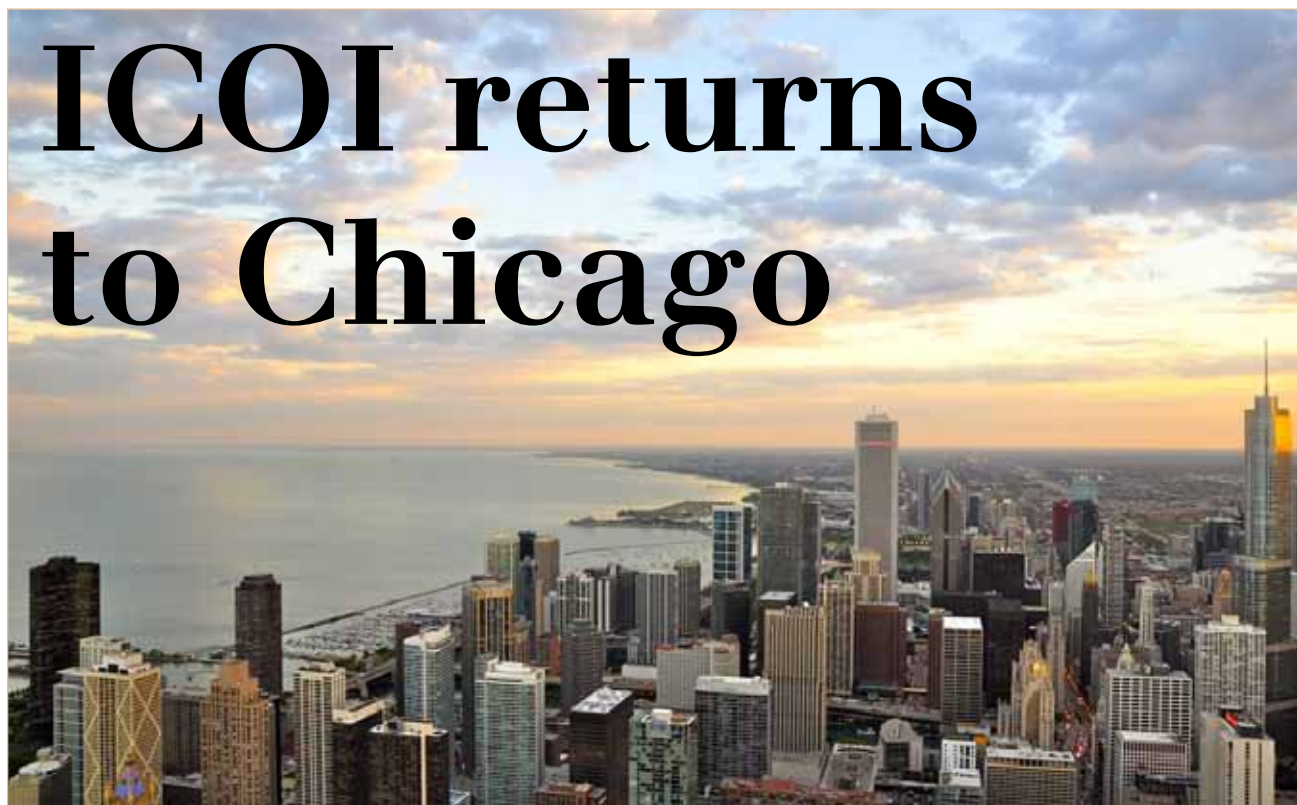The adoption of 3-D cone-beam imaging is appropriate and has important advantages for all modalities of dentistry. From every specialist to the general dentist, the increased amount of radiographic information as well as increased accuracy will aid in the most sound diagnosis possible.

### CBCT description

CBCT is a single or partial rotation of an X-ray source around the head, capturing X-rays on various flat panel arrays and sensors. The information is converted to a series of axial slices by computed tomography and stored as

→ [page 2B](#)

# ICOI returns to Chicago



Chicago is the site for the ICOI's 14th annual Implant Prosthetic Summer Symposium. (Photo/Christiane Ferret, Dental Tribune)

## Windy City welcomes ICOI Implant Prosthetic Symposium in August

By Craig Johnson, ICOI Executive Director

The International Congress of Oral Implantologists (ICOI) will return to one of its favorite locales for its 14th annual Implant Prosthetic Summer Symposium. The dates to add to your calendar are Aug. 18-20,

and the venue will be the Downtown Marriott Hotel on Michigan Avenue in the heart of Chicago. Just steps from the famous Navy Pier and the excitement of summer in the city, this meeting promises both educational enrichment and social opportunities.

The Chicago program's goal is about education for everyone on the implant team. Formulated with the original vision of ICOI's Implant Prosthetic Symposium, the mission is to highlight the restorative

→ [page 2B](#)

## JOI: Gene combination identified as risk factor in success of dental implants

The health of the surrounding tissue affects the success of a dental implant. Identifying and reducing risk factors is therefore a key step in the implant process. Now a combination of genes has been identified as a possible indicator of greater tissue destruction leading to negative outcomes for implants.

The authors of an article in the Journal of Oral Implantology report on a study of individuals with the combination of interleukin (IL)-1 allele 2 at IL-1A-889 and IL-1B+3954. These people are "genotype positive" and susceptible to increased periodontal tissue destruction.

Peri-implantitis, or the process of tissue inflammation and destruction around failing implants, is very similar to periodontal disease. The researchers sought to find any association of these genotypes with the severity of peri-implantitis progression and the effect of this combina-

tion on treatment outcomes.

This study compared two groups of patients, all of whom had implants. The first group consisted of 25 patients with peri-implantitis, while the second group of 25 patients had healthy tissue. Seventeen patients from the first group and five from the second group were genotype positive.

Patients in the first group, those with peri-implantitis, took part in a treatment and maintenance program. The genotype-positive patients in this group experienced greater periodontal tissue destruction and increased discharge from tissues. The genotype-negative patients responded better to treatment. Statistically significant differences were noted between the groups.

The combination of these two alleles in patients with inflamed periodontal tissues denotes a risk factor that can lead to further tissue destruction. Patients with the specific

genotype can have exaggerated local inflammation. Gene polymorphism may affect the outcomes of treatment for peri-implantitis in genotype-positive people and affect the long-term success of implants.

Full text of the article, "The Effect of Interleukin-1 Allele 2 Genotype (IL-1a-889 and IL-1b+3954) on the Individual's Susceptibility to Peri-Implantitis: Case-Control Study," Journal of Oral Implantology, Vol. 37, No. 5, 2011, is available at <http://allenpress.com/publications/journals/orim>.

### About the Journal of Oral Implantology

The Journal of Oral Implantology is the official publication of the American Academy of Implant Dentistry and of the American Academy of Implant Prosthodontics. For more information about the journal or society, visit [www.joionline.org/orimonline/?request=index-html](http://www.joionline.org/orimonline/?request=index-html). [▶](#)

← **IT** page 1B

aspects of implant dentistry, with a focus on expanding technologies that enhance the daily practice for the GP, the specialist, dental auxiliary and dental laboratory technician.

The scientific program will begin on Thursday afternoon, Aug. 18, with a focus on the latest in esthetics and prosthetic reconstruction techniques. Friday will deal with recent innovations in guided surgery applications and treatment of the atrophic patient as presented from the clinician and laboratory technician perspective.

The program will conclude on Saturday with presentations on occlusion, over-denture concepts, complications and advancements in restorative components.

Dr. Scott Ganz has arranged the scientific program, which features speakers including Drs. Natalie Wong, Michael Moskovitch, Philippe

Russe, Lampert Stumpel, Thomas Balshi, Dwayne Kareteew, Michael Pikos, Jack Krauser, Konstantinos Valavanis, Barry Goldenberg, Aldo Leopardi, Carl Misch, Paul Wiegel, Marius Steigmann, Hom-Lay Wang, Ady Palti, Zeev Ormianer, Roberto Marra and dental technicians Stephen Balshi, Renzo Casellini and Ulrich Hauschild and many more.

The ICOI is an ADA CERP and AGD PACE Recognized Provider. This symposium is designated for 19 continuing education credits.

Preceding the general session, there will be six pre-symposium workshops on Thursday morning offered by the two Gold sponsors, Nobel Biocare and Osstell, and the five Silver sponsors, BioHorizons, Dentsply Tulsa Dental Specialties, Implant Direct, Osteogenics and PreXion. For complete information on these courses and on the meeting in general, visit ICOI's web site at

[www.icoi.org](http://www.icoi.org).

In addition, ICOI will continue to hold its Table Clinic/Poster Presentation competition for delegates at all levels of experience. These will take place Thursday evening during the Welcome Reception in the Exhibition Hall.

ICOI's auxiliary section (ADIA) will also hold a two-and-a-half-day program (in tandem with the doctors program), which will include its full-day certification programs for hygienists, dental assistants and practice management staff members.

Delegates should make sure to contact the host hotel, the Downtown Marriott on Michigan Avenue, as rooms are going fast.

To contact the Marriott, call (800) 266-9452, or visit [www.icoi.org](http://www.icoi.org), and make reservations online. But do so today.

We want to see you this August in that Toddlin' Town, Chicago. **IT**

← **IT** page 1B

virtual anatomy in the computer.

With the use of sophisticated software, the dentist is able to view information in several different views, including: axial slices (head-to-toe orientation), coronal slices (front-to-back orientation), sagittal slices (side-to-side orientation) all known as multi-planer reconstructions (MPR). The thickness of each slice can be varied to include more or less information.

Because the voxels (volumetric pixels 3-D) are isotropic, other MPR images can be generated by slices drawn at any angle, curve or thickness through the scan to view areas critical to the final diagnosis.<sup>5,8</sup>

The final view offered by CBCT is a 3-D view that can be rotated and viewed in any direction.

Once again through software manipulation, 3-D images can be viewed as conventional radiographs, maximum intensity projections (MIP), soft-tissue projections and a variety other views.

This nearly endless ability to manipulate the data aids in the diagnosis and identification of disease, nerve canals, sinus morphology, dental caries, bone density, fractures, endodontic pathology, implant placement criteria, periodontal defects, bone pathology, fractured teeth, iatrogenic trauma, TMJ morphology and disease, third-molar position and many more healthy or diseased conditions.

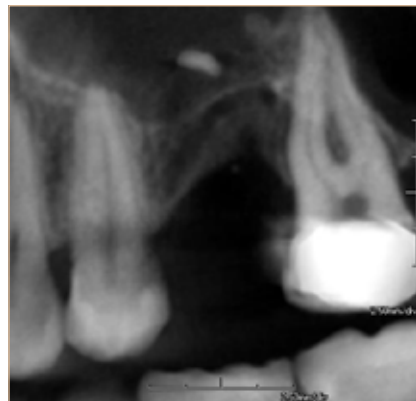

Fig. 2: Periapical does not show the sinus anatomy or the width of the bone.

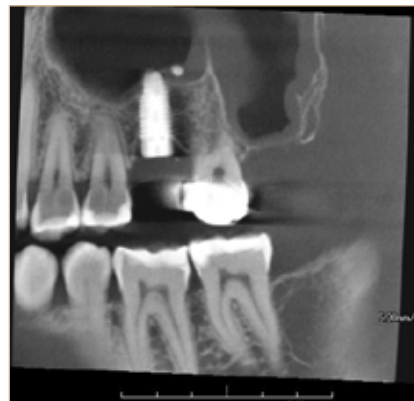

Fig. 3: MPR showing post op of sinus graft and implant placement.

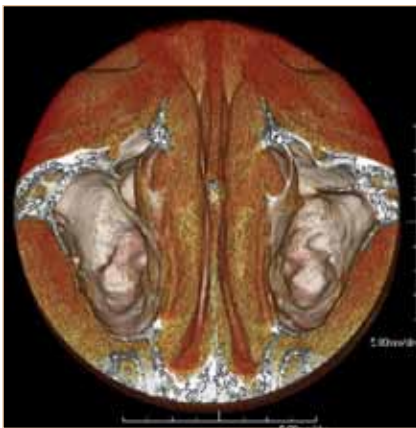

Fig. 4: The 3-D CBCT showing anatomy of the maxillary sinuses.

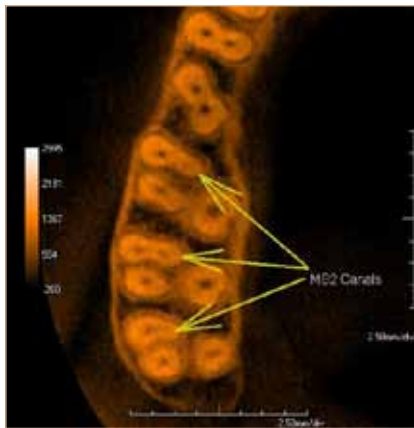


Fig. 5: Axial MPR showing mesial buccal roots in first, second and third molars.

### Early CBCT adoption with implants

The first and primary use of CBCT for early adopters was implant placement. As the scope and the value of the information became better known, dentists of all branches began to see the value

of MPRs and 3-D renderings including periodontics, endodontics, oral surgery, treatment of TMJ, orthodontics, implantology and general dentistry.<sup>1,7,8</sup>

Clinical peri-apical and panoram-

→ **IT** page 4B

## IMPLANT TRIBUNE

The World's Newspaper of Implantology - U.S. Edition

### Publisher & Chairman

Torsten Oemus  
[t.oemus@dental-tribune.com](mailto:t.oemus@dental-tribune.com)

### Chief Operating Officer

Eric Seid  
[e.seid@dental-tribune.com](mailto:e.seid@dental-tribune.com)

### Group Editor & Designer

Robin Goodman  
[r.goodman@dental-tribune.com](mailto:r.goodman@dental-tribune.com)

### Editor in Chief

Sascha A. Jovanovic, DDS, MS  
[sascha@jovanoviconline.com](mailto:sascha@jovanoviconline.com)

### Managing Editor/Designer

Implant, Endo & CAD/CAM Tribunes  
Sierra Rendon  
[s.rendon@dental-tribune.com](mailto:s.rendon@dental-tribune.com)

### Managing Editor/Designer

Ortho Tribune & Show Dailies  
Kristine Colker  
[k.colker@dental-tribune.com](mailto:k.colker@dental-tribune.com)

### Online Editor

Fred Michmershuizen  
[f.michmershuizen@dental-tribune.com](mailto:f.michmershuizen@dental-tribune.com)

### Account Manager

Humberto Estrada  
[h.estrada@dental-tribune.com](mailto:h.estrada@dental-tribune.com)

### Marketing Manager

Anna Wlodarczyk  
[a.wlodarczyk@dental-tribune.com](mailto:a.wlodarczyk@dental-tribune.com)

### Marketing & Sales Assistant

Lorrie Young  
[l.young@dental-tribune.com](mailto:l.young@dental-tribune.com)

### C.E. Manager

Julia Wehkamp  
[j.wehkamp@dental-tribune.com](mailto:j.wehkamp@dental-tribune.com)

### International C.E. Sales Manager

Christiane Ferret  
[c.ferret@dtstudyclub.com](mailto:c.ferret@dtstudyclub.com)

Dental Tribune America, LLC  
116 W. 23rd St., Suite #500  
New York, NY 10011  
Phone: (212) 244-7181, Fax: (212) 244-7185

### Published by Dental Tribune America

© 2011 Dental Tribune America.  
All rights reserved.

Dental Tribune makes every effort to report clinical information and manufacturer's product news accurately, but cannot assume responsibility for the validity of product claims, or for typographical errors. The publishers also do not assume responsibility for product names or claims, or statements made by advertisers. Opinions expressed by authors are their own and may not reflect those of Dental Tribune International.

### Editorial Advisory Board

Dr. Sascha Jovanovic, Editor in Chief

Dr. Bernard Touati

Dr. Jack T. Krauser

Dr. Andre Saadoun

Dr. Gary Henkel

Dr. Doug Deporter

Dr. Michael Norton

Dr. Ken Serota

Dr. Axel Zoellner

Dr. Glen Liddelow

Dr. Marius Steigmann

**Tell us  
what  
you  
think!**

Do you have general comments or criticism you would like to share? Is there a particular topic you would like to see more articles about? Let us know by e-mailing us at [feedback@dental-tribune.com](mailto:feedback@dental-tribune.com). If you would like to make any change to your subscription (name, address or to opt out) please send us an e-mail at [database@dental-tribune.com](mailto:database@dental-tribune.com) and be sure to include which publication you are referring to. Also, please note that subscription changes can take up to six weeks to process.

### IT Corrections

Implant Tribune strives to maintain the utmost accuracy in its news and clinical reports. If you find a factual error or content that requires clarification, please report the details to Managing Editor Sierra Rendon at [s.rendon@dental-tribune.com](mailto:s.rendon@dental-tribune.com).





FREE SHIPPING\*

Purchases from this catalog will receive FREE Shipping!\*

**Download the catalog  
now at [acesurgical.com](http://acesurgical.com)**

\* FREE GROUND SHIPPING ON ALL THE PRODUCTS FOUND INSIDE THIS CATALOG.

Free shipping on the products in this catalog is only valid from July 1st - Sept. 31, 2011.  
Additional items ordered that are not in this catalog will be charged our normal UPS rates.  
Orders must be \$400 or more to be eligible for free shipping.

ACE Surgical Supply Company, Inc. • 1034 Pearl Street, Brackton, MA 02301



800.441.3100

[www.acesurgical.com](http://www.acesurgical.com)



← **IT** page 2B

ic radiographs for the placement of implants can be misleading with elongation, foreshortening, superimposition and geometrically incorrect data.<sup>7,8</sup> A look at the implant in the periapical shows no obvious disease to an existing integrated implant. Clinically, a buccal fistula was present with exudate and slight pain. The CBCT scan (Fig. 1) reveals a more accurate view showing a buccal defect on a sagittal MPR. A surgical flap revealed a dehiscence of the coating of the implant. Removal of the foreign body resulted in an asymptomatic and healthy patient

The evaluation of the available bone for the initial implant placement can be crucial for the long-term success of the case. If there is inadequate bone available, grafting may be a necessity. CBCT studies render the most accurate information available at a low radiation dose. The periapical shows an obvious lack of bone height, but does not show the buccal-lingual dimensions or an accurate view of the sinus morphology (Fig. 2).

The MPR view of the CBCT shows all necessary measurements to perform the sinus lift and grafting with the immediate placement of the implant fixture (Fig. 3). 3-D views show the floor of the sinus and any soft-tissue pathology (Fig. 4). Having accurate measurements in all dimensions is an advantage of CBCT scanning.

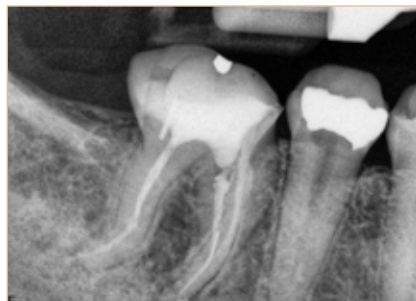

Fig. 6: Periapical showing minimal pathology with no radiolucency.

#### CBCT and endodontics

Endodontics is a field that is rapidly adopting the use of CBCT and for good reason. The inherent geometric deficiencies of 2-D radiographs make the CBCT scan a valuable adjunct to investigate the root morphology in both 3-D and MPR. The typical periapical will show superimposed canals in the anteriors, bicusps and molars as well as unwanted bone densities both buccal and lingual to the affected tooth making the image quality poor.

The ability to view MPR slices in cross-section, long axis and oblique directions gives the ability to follow all canals in any direction and show their relationship and measurements from other known structures. This virtual tour of the root morphology is a great benefit to the final treatment outcome (Fig. 5).<sup>3,4</sup>

Post root-canal infection can be difficult to diagnose with the standard peri-

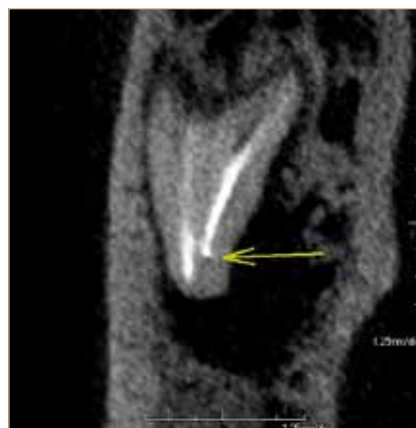

Fig. 7: Coronal MPR showing a short fill on the mesial lingual and radiolucency.

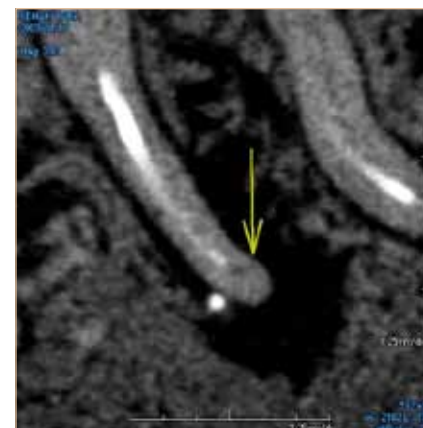


Fig. 8: Sagittal MPR showing unfilled canal and radiolucency.

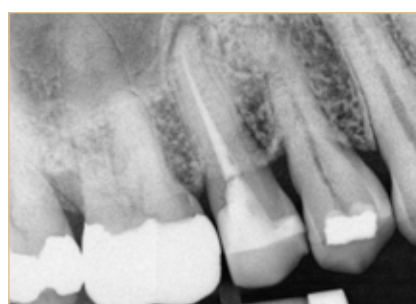

Fig. 9: Periapical showing a normal fill with a radiolucency.

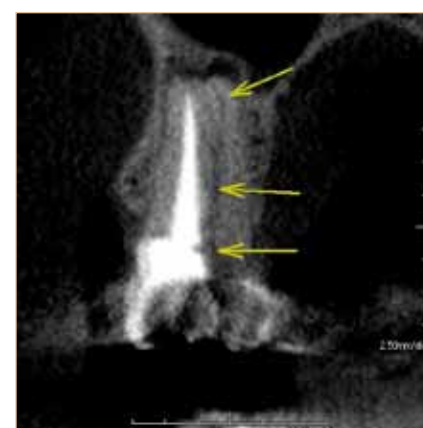

Fig. 10: Coronal MPR showing the superimposed lingual root unfilled.

apical. The endodontic fills may appear to be normal even though other clinical findings and symptoms are abnormal. The patient presents several months post root-canal treatment with pain on palpation and pressure and avoids this side of the mouth. A periapical radiograph shows minimal pathology (Fig. 6). The roots appear to be filled and a small puff of sealer extends through the apex of the mesial roots. The distal root structure and fill appear normal. There is little indication of periapical radiolucency only a widening of the periodontal ligaments of the mesial roots.

A CBCT scan reveals a completely different picture. The coronal MPR reveals a short fill near the apex of the mesial lingual root and a large radiolucency (Figs. 7, 8) not visible on the periapical radiograph (Fig. 6).

Missed canals are difficult to see in a buccal-lingual projection of the periapical radiograph as on canal is superimposed on the other (Fig. 9). Often, as viewed in this radiograph, we see periapical pathology with an apparent normally filled canal. CBCT scans allow dentists to look for pathology in MPR planes to identify the actual problem before invasive procedures are performed on the patient. The axial view shows a lingual canal exists and is untreated. The coronal view confirms the diagnosis and treatment can be completed (Fig. 10).

Today's endodontists, as well as general dentists, are benefiting from the diagnostic capabilities of the high-resolution CBCT scanners available over conventional 2-D periapical.<sup>5,6</sup>

#### Oral surgery

Oral surgery, with its inherent invasive nature, can be better served using CBCT with MPR as well as 3-D images. The ability to perform virtual surgery is a benefit to both the doctor and the patient. Doctors have the advantage of seeing morphology and landmarks in real time and space with accurate measurements, and patients will gain a bet-

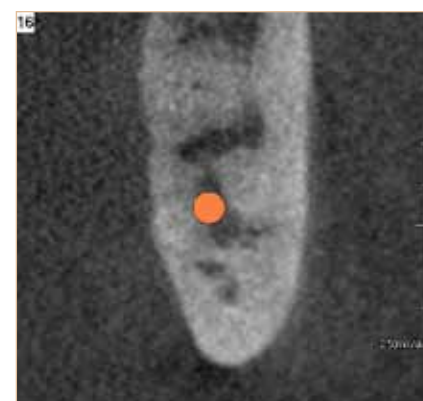


Fig. 11: Coronal MPR showing nerve between roots of the third molar.

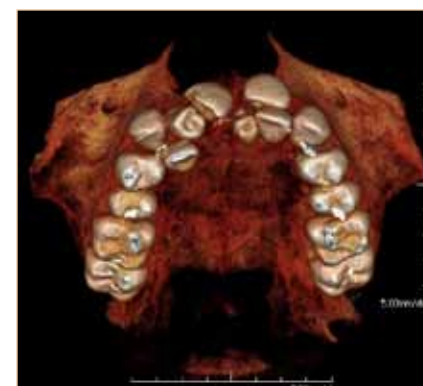


Fig. 12: The 3-D rendering showing supernumary teeth and positions.

ter understanding of the problems and the solutions their doctors are offering them.

Third-molar extractions can be risky based on 2-D and panoramic radiographs. These radiographs can often superimpose nerves and sinuses over root structures. Dentists using 2-D radiographs must often rely on experience to assess the risks of iatrogenic trauma. The use of CBCT with MPRs and 3-D images reduces any guessing as well as the chance for any permanent damage to the patient. With the adoption of CBCT, the judgment is based on solid

AD

AAID 60th ANNUAL MEETING  
**REALITIES OF IMPLANT DENTISTRY**  
 STACKING THE DECK IN YOUR FAVOR

AMERICAN ACADEMY OF IMPLANT DENTISTRY | OCTOBER 19-22, 2011

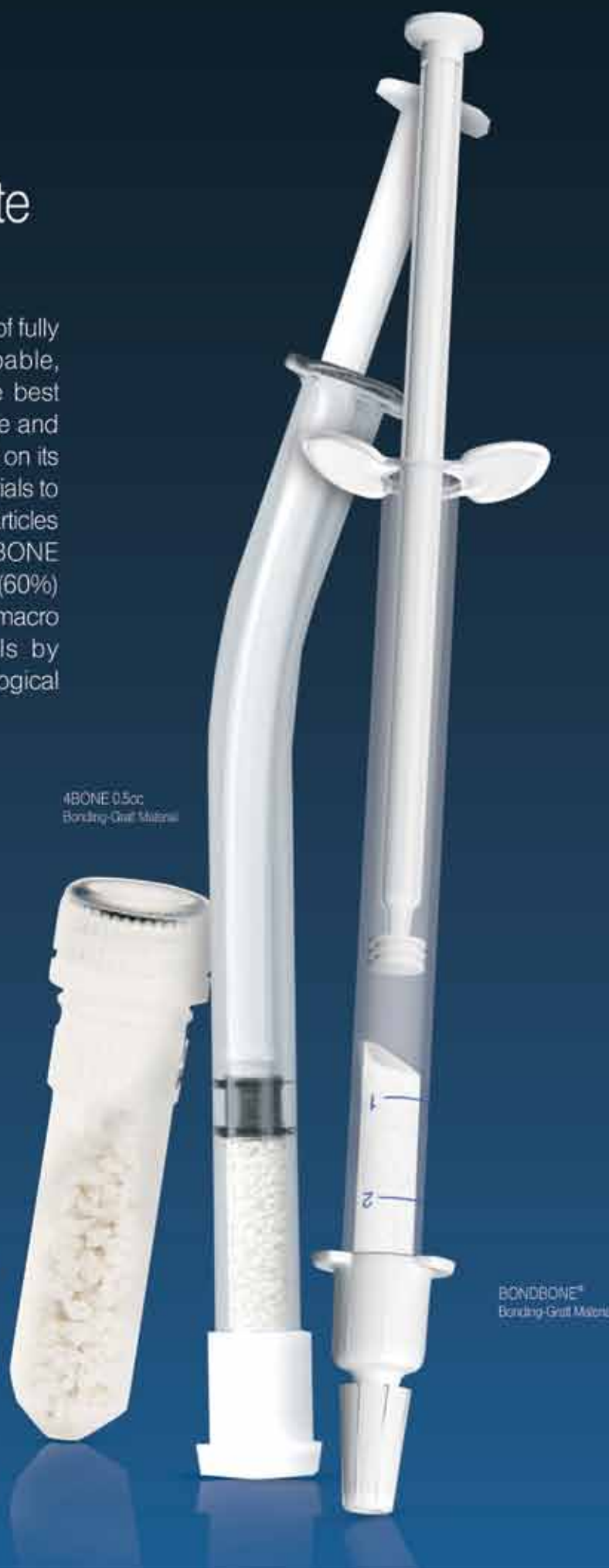LAS VEGAS

www.aaid.com



## Innovative Bonding Graft Material & Fully Synthetic Bone Substitute

The MIS Bone augmentation materials include a line of fully synthetic bone grafts. BONDBONE® is a resorbable, osteoconductive bone grafting material, taking the best qualities of hemihydrate and dihydrate calcium sulfate and combining them into a unique product. It can be used on its own, or mixed with other granular bone grafting materials to form a composite that will help to prevent migration of particles and often eliminate the need for a separate barrier. 4BONE SBS is a fully synthetic bone graft composed of HA (60%) and  $\beta$ TCP (40%). Permeable interconnected micro and macro porosity promotes invasion of osteogenic cells by osteoconduction, which permits the diffusion of biological fluids, leading to fast formation of bone.



4BONE 0.5cc  
Bonding-Graft Material

4BONE 6cc  
Bonding-Graft Material

BONDBONE®  
Bonding-Graft Material

© MIS Corporation. All rights Reserved.



MIS offers a wide range of implant designs and restorative components, along with innovative kits and accessories for the varied challenges encountered in implant dentistry. To learn more about MIS visit our website: [misimplants.com](http://misimplants.com) or call us: **866-797-1333 (toll-free)**

**MIS**<sup>®</sup>  
USA  
Make it Simple

Introducing

# PreXion3D *Elite*

WITH CLEARimage™ SCANNING TECHNOLOGY

**NEW** Up to 53% Reduction in radiation

**NEW** Up to 50% Increase in scanning speed

**NEW** Four new scanning modes, all faster and with reduced radiation

**NEW** Advanced Software Features

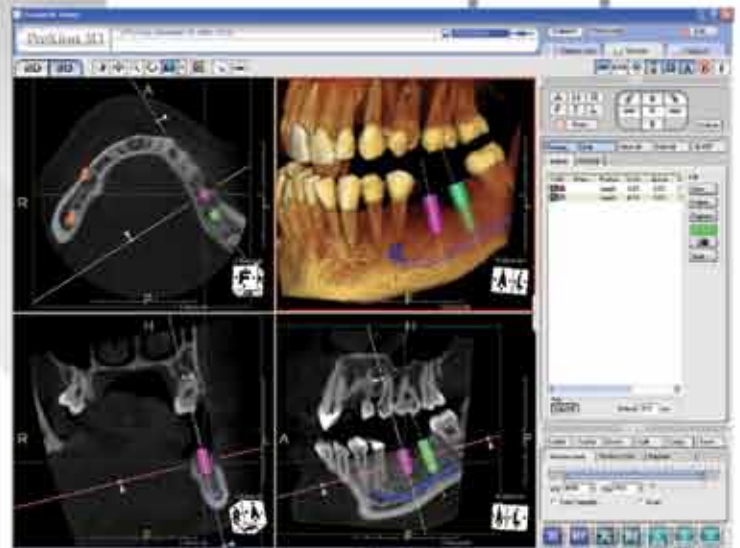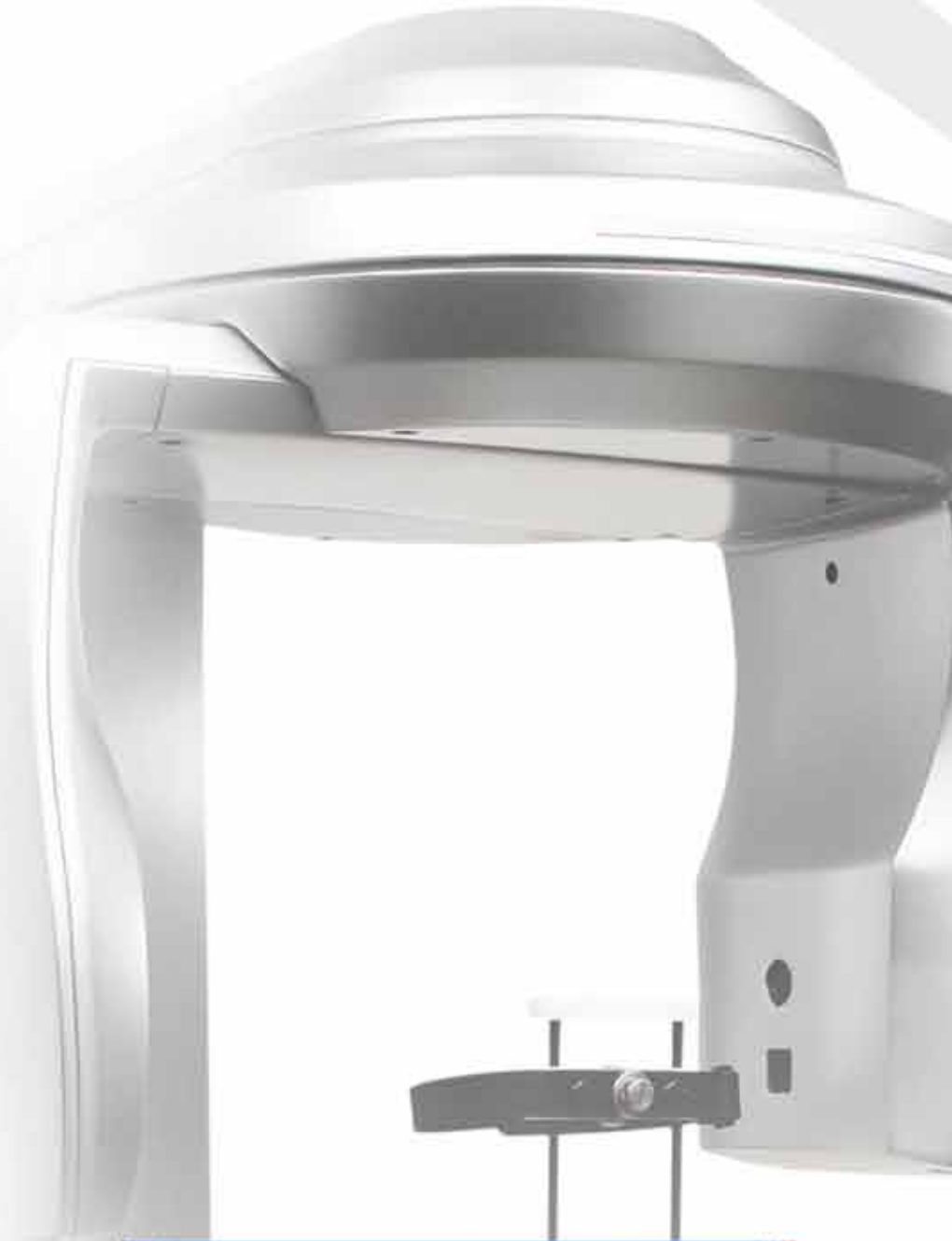- Implant Planning Support Functions
- Fusion/Stitching Mode
- Endodontic Tracing Tool that allows for identifying root structures

Smallest focal spot at 0.15mm

Industry Leading High Quality, High Definition, Highly Diagnostic Images

Compatible with ALL implant software planning systems

Call **1-855-PREXION**  
today to schedule a  
demonstration



**PreXion**

*The World Leader in High Quality,  
Highly Diagnostic 3D CBCT Images.*

Visit PREXION at the ICOI Summer  
Implant Prosthetic Symposium  
Booths 403 & 405

[www.PreXion.com](http://www.PreXion.com)



← IT page 4B

evidence and the risk will decrease.

A panorex of the superimposed third molars gave no solid evidence the canal lies between the roots. It is only with the use of CBCT and the MPRs that the nerve can accurately be seen traversing between the mesial buccal and mesial lingual root (Fig. 11).<sup>4,5</sup>

Other surgical advantages include the identification and the position of supernumerary or impacted teeth. The images show accurate positions and show definitive morphology that will aid in removal of the proper teeth (Fig. 12). Knowing the exact position of many of these teeth is a benefit to both the doctor and patient. It will lead to the most precise surgical path and the least invasive procedure.

**Periodontics**

The explanation of periodontal problems are often misunderstood by the patient. As doctors we talk about pockets, point to X-rays and propose treatment only to have patients refuse treatment because they do not understand what we are clinically describing. Using the 3-D portion of the CBCT scan can improve the understanding and acceptance of treatment plans. The images are a picture of the problem that is owned by that patient and much easier to understand by the layperson. Illustrating periodontal defects and pockets allows the patient to better participate in the process (Fig. 13).

The MPRs and the 3-D projections aid in surgical planning for periodontists, allowing for accurate measurements and bone analysis prior to osseous surgery that doctors can not get using the periapicals or panoramics. Studies have shown that CBCT images are more accurate than panoramic radiographs. For the periodontist placing implants, the ability to measure bone density and avoid important anatomy is important.<sup>4,5</sup>

**Orthodontics**

Orthodontists are beginning to adopt large field-of-view CBCT. Recent studies show that linear measurements of bony structures are more accurate using CBCT and have less distortion than currently used methods of measurement: lateral cephalometric, posteroanterior (PA) and submentovertex (SMVT).<sup>5</sup> Accurate measurements of tooth volume and tooth position can aid in accelerated treatment times and more precise treatment.

Along with tooth position, density of bone and size of arches, the orthodontist also has an accurate evaluation of the temporomandibular joint and position of the condyles. Impacted teeth are easily identified and position either buccal or lingual can be confirmed prior to movement or removal. Both MPRs and 3-D projections give the doctor a complete picture of the problems and the treatment course. With a single CBCT scan, the orthodontist can produce all of the information they need: panoramic, cephalometric, PA, SMVT, tooth size and volume, crowding evaluation in any plane, TMJ evaluation and airway analysis, all with both soft-tissue and skeletal information.<sup>5,7</sup>

**Conclusion**

We treat our patients in 3-D, and now,

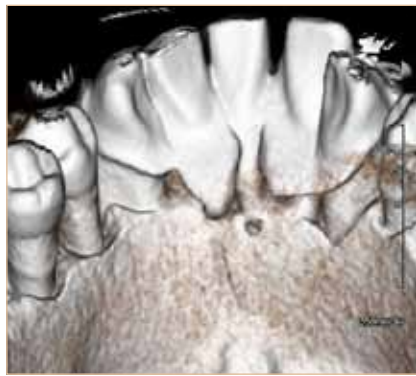

Fig. 13: The 3-D Rendering with periodontal defects and calculus bridge.

with cone-beam computed tomography, we are changing the way we diagnose from 2-D to 3-D. The addition of this technology will increase your diagnostic skills with better and more complete information at your disposal. As with any type of invasive diagnostic

tool, doctors should weigh the risk to benefit in using CBCT scans.

Judicious use of CBCT and knowledge of patient's lifetime doses should always be a consideration as well as the availability of other diagnostic tests appropriate for the problems of the patient. When adopting new technology, training is paramount. Along with training comes the responsibility of the doctor to read and diagnose information from CBCT scans.

Do not avoid CBCT from lack of knowledge; instead, take this opportunity to become a better diagnostician and radiologist. As you review radiology and pathology, your use of CBCT will aid in making the most accurate diagnosis and the most complete treatment plans. IT


References available upon request from the publisher.

**IT About the author**

Dr. Dan McEowen is a 1982 graduate of Loma Linda School of Dentistry and has been in private practice for 26 years. He is a founding member of the World Clinical Laser Institute, achieving a mastership level of proficiency. He has been active in FDA approval of oral surgery techniques using Erbium lasers. McEowen has lectured and trained internationally in techniques using lasers in general and specialty dental fields. He is a member of the ICOI and is active in implantology. McEowen has been involved in cone-beam technology for more than five years and owns 3D Imaging Center in Maryland.




AD




**Atlas Denture Comfort**  
NARROW-BODY IMPLANTS

**Easy to Learn & Implement, Life Changing for Your Patients**



"When I received the Atlas Denture Comfort procedure, I became a different person. I feel wonderful and I am very happy with myself and how others compliment the way I look. My new confidence has changed my life."

—Atlas Denture Comfort Patient



**GROW YOUR PRACTICE**

The easy-to-learn Atlas Denture Comfort technique is the perfect system to start treating your mandibular denture patients, all without cumbersome O-rings, housings or adhesives. The low start up costs and economically priced implants make it easy for you to expand into this modality at your own pace.

**LIFE CHANGING FOR YOUR PATIENTS**


The minimally invasive, 1 hour Atlas Denture Comfort procedure can restore quality of life to your patients who cannot undergo conventional implant therapies due to lack of time, bone or money.

**GET STARTED WITH A HANDS-ON WORKSHOP**

Attend one of our award winning courses and help the millions of underserved Americans who suffer with their dentures. Atlas Hands-On Workshop participants learn the step-by-step technique on an esthetic model, which is yours to keep for staff training and case presentation.

**HANDS-ON WORKSHOP SCHEDULE**


Sep 16 – Seattle, WA	Sep 30 – New York, NY
Sep 23 – Pittsburgh, PA	Oct 14 – Portland, OR



The resiliently soft Tuf-Link® Silicone material provides vertical resilience between the hard denture base and soft gum tissue, providing the highest level of secure retention & comfort to your patients. Tuf-Link creates a perfect fit every time.

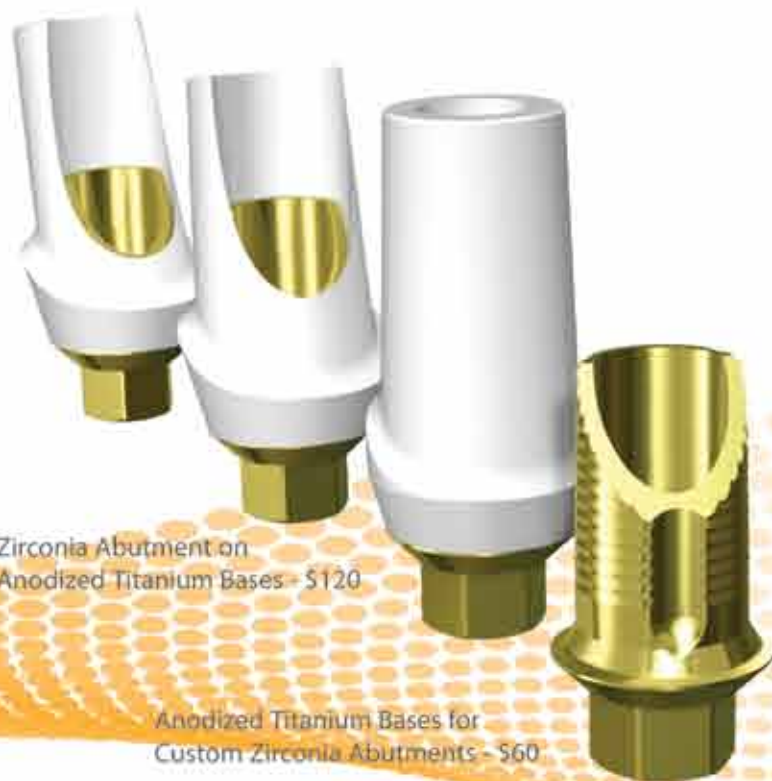
For secure online registration, more course dates and information on educators visit [www.dentatus.com](http://www.dentatus.com)

1-800-323-3136  
[www.dentatus.com](http://www.dentatus.com)



©2011 Dentatus USA, Ltd. • Patented and Patents Pending





Zirconia Abutment on Anodized Titanium Bases - \$120

Anodized Titanium Bases for Custom Zirconia Abutments - \$60

Implants with All-in-1 Packaging - \$150-\$200  
Including implant, abutment, transfer, cover screw & healing collar<sup>1</sup>

### Industry compatible implants with All-in-1 Packaging for Value


Implant Direct Sybron continues to transform the Implant Industry with the broadest selection of implants, offering surgical & prosthetic compatibility with other major brands. Our patented combination of micro-threads for crestal bone preservation & double-lead threads for faster insertion simplify surgery & increase initial stability, essential for immediate load applications.

### Zirconia Abutments on Titanium Bases for Esthetics and Strength

The titanium base is anodized gold to mask the grey color & can be used in the fabrication of cad-milled custom abutments. The stock abutments, provided assembled, are offered in 0°, 8° & 15° angulations with contoured margin collars of 1mm & 2mm heights. The Zirconia can be modified intra-orally with diamond burs, providing the benefits of custom zirconia abutments for a fraction of the cost.

Joining our full line of industry compatible prosthetics  
See the considerable savings for our most popular abutments

	Straight Snap-On	15° Angled Contoured	Gold/Plastic	Angled Zirconia/Ti Abutment	Ball Attachment	GPS™ Attachment	Multiple-Unit w/Cap & Transfer
<b>Our price</b>	\$85	\$85	\$100	\$120	\$107	\$100	\$85
<b>Zimmer Dental®</b>	\$210	\$180	\$190	\$247	\$172	\$160	\$167
<b>Straumann®</b>	\$181	\$203	\$157	\$339 <sup>2</sup>	\$192	\$193	\$169
<b>Nobel Biocare™</b>	\$186	\$225	\$216	\$285	\$217	\$149	\$229



**Intro Offer: Buy 5 GPS™ abutments and receive the tools FREE.<sup>3</sup>**

<sup>1</sup>Price comparisons based upon US list prices as of April 2011.

<sup>2</sup>Items included in All-in-1 Packaging varies by implant.

<sup>3</sup>Comparison based upon Straumann's CARES custom zirconia abutment. Price varies depending upon the laboratory.

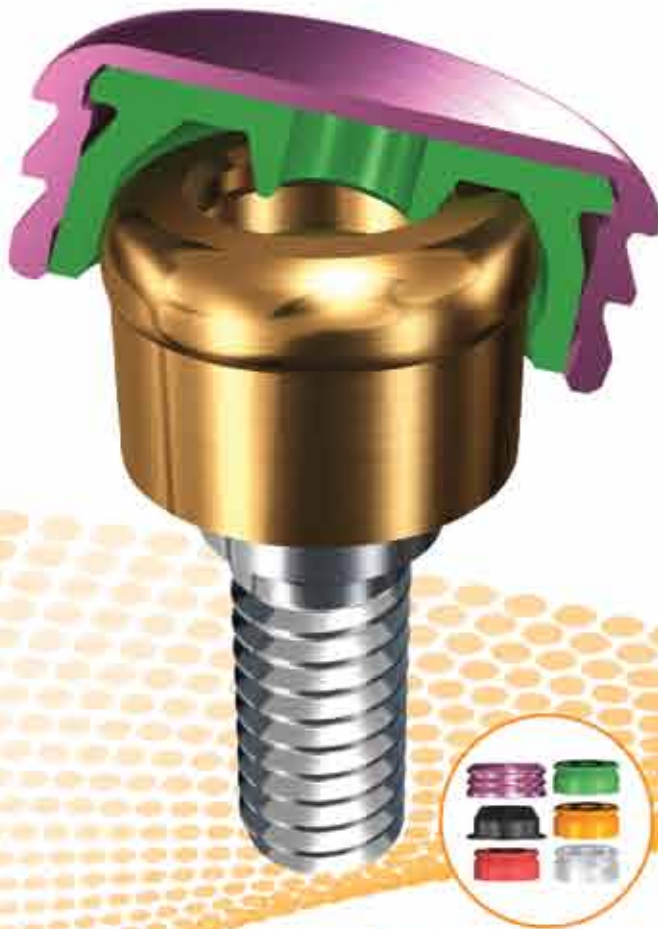<sup>4</sup>Terms and conditions apply.

All trademarks are the property of their respective companies.

LOCATOR® is a registered trademark of Zest Anchors Company. The GoDirect™ and GPS™ Systems are neither authorized, endorsed nor sponsored by Zest Anchors Company.



**WARNING:** Some advertisements may be hazardous to your practice. Implant Direct Sybron's GPS™ Overdenture Abutments have been targeted in Zest Anchor Company's recent journal advertisements, demonstrating that compatible attachments offering significant cost savings are a threat to Zest's dominant position in the overdenture attachment market. Discover the full story on GPS™ below.



**GPS™ Overdenture Attachment System**

# IF YOU LIKE ZEST'S LOCATOR® YOU'LL LOVE THE GPS™ Abutments & GoDirect™ Implants FROM IMPLANT DIRECT SYBRON FOR SAVINGS, SIMPLICITY AND COMPATIBILITY

GPS™ accommodates the greatest degree of relative divergence available on the market.



GPS™

- Titanium Cap design enhances retention in denture base
- One nylon liner design for up to 20 degrees divergence
- Black Processing Cap made from high melting point plastic
- Abutment inserted with standard insertion tools for each system
- Abutments with Cap Attachment & related components for \$100

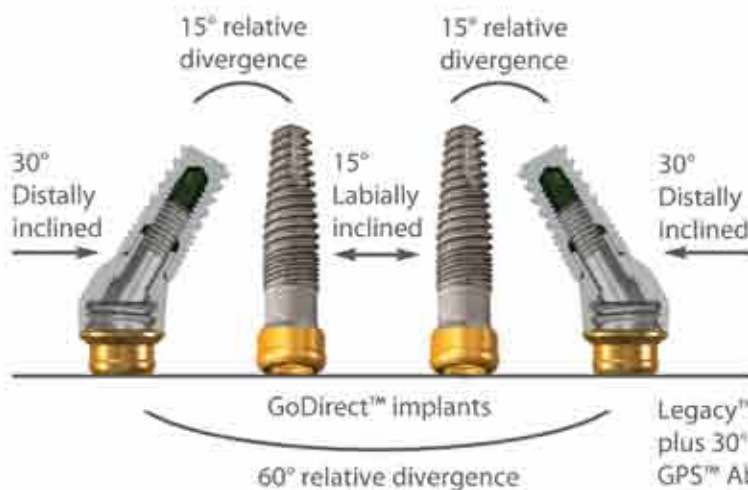VS

- Titanium Cap design with minimal retention in denture base
- Two nylon liner designs, with 10 & 20 degrees divergence
- Black Processing Cap made from lower melting point plastic
- Abutment insertion requires Zest's triangular tool
- Abutments, Cap Attachment & Components sold for \$156



ZEST LOCATOR®

Available now for Straumann Tissue Level, NobelReplace, Zimmer Screw-Vent, BioHorizons® Internal, MIS & Blue Sky Bio Available 4Q11 for NobelActive™, BIOMET 3i Certain® & Astra Tech™



**GoDirect™ Implant**

- GPS™ & LOCATOR® Compatible Platform
- Internal threads for prosthetic versatility
- Available in 3.0mm, 3.7mm & 4.7mm diameters
- 1-piece implant design
- Micro-threads
- Tapered with self-tapping grooves

**1-Piece Implant for \$150  
GPS™ Attachment for \$20**

[www.implantdirect.com](http://www.implantdirect.com) | 888-649-6425

Visit us at booth #402 at the ICOI Implant Symposium

