

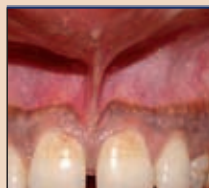# DENTAL TRIBUNE

— The World's Dental Newspaper • Middle East & Africa Edition —

PUBLISHED IN DUBAI

December 2010


No. 10 Vol. 8



## Trends & Applications

Comparison of conventional techniques with diode laser

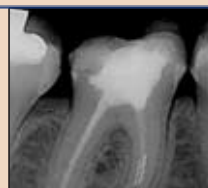Page 4



## Media CME

CBCT applications in dental practice: A literature review

Page 6



## Practice Matters

Removal of a fractured instrument:

Two case reports Page 9

## Flouride rich baby food under fire from scientists

Daniel Zimmermann  
DTI

NEW YORK, USA/LEIPZIG, Germany: Scientists in the US have warned of the risks of exposing young children to large amounts of fluoride. In a study published in the October edition of the Journal of the American Dental Association they claim that an increased intake of the mineral

from drinking water, dentifrice, infant powder products or beverages can lead to a higher risk of developing fluorosis, a condition that discolours and weakens teeth.

The findings confirm earlier evidence indicating a link between dental fluorosis and greater intake of fluoride in early life. The latest study, conducted

by researchers from the University of Iowa in the United States, found that a greater fluoride intake from reconstituted powder, a popular choice for infant food in the US, and other beverages with added water increased fluorosis risk in children between the ages of three and nine months. They suggested avoiding the ingestion of additional fluoride through consumption of these mixtures

in order to reduce the prevalence of the condition nationwide.

According to the US Centers for Disease Control and Prevention, one-third of children between the ages of 12 to 15 years in the US suffer from some form of fluorosis.

The country also has the highest occurrence of flouridated water in the world. DT



## New evidence links mercury to Alzheimer's

Yvonne Bachmann  
DTI

LEIPZIG, Germany: Dental patients with silver fillings are more likely to suffer from senile dementia of the Alzheimer's type. In a review published in the latest Journal of Alzheimer's Disease, researchers associated with universities in Boston (USA), Freiburg/Breisgau and Frankfurt (Oder), both in Germany, claim that symptoms of the condition were reproduced or accelerated when brain tissue was exposed to inorganic mercury, the main ingredient of amalgam.

Earlier studies of low-dose human exposure, such as to den-

tists and their staff, have shown that exposure to mercury is correlated with long-term neurological or psychological harm. The new review is one of the first that has found a systematic link between memory deficits and increased levels of mercury found in Alzheimer's patients.

According to Prof. Harald Walach, Viadrina European University in Frankfurt (Oder), patients with silver fillings are exposed to 1 to 22 µg mercury per day, of which the majority accumulates in the brain. The metal binds with selenium, a substance responsible for preventing oxidative stress, which can lead to cell death and early ageing. Removing mer-



cury from medical and ecological cycles could slow down cell death and prevent the development of

dementia and possibly other forms of neurological disorders, including Parkinson, he added.

"The situation is similar to the early 1970s regarding smoking: substantial experimental evidence existed, but human studies were inconclusive at the time and were under attack by groups with a vested interest," Prof. Walach told Dental Tribune Asia Pacific. "To wait until irrefutable evidence has accumulated is not the best option in view of what we already know about the toxic potential of mercury."

Amalgam is still the most common type of filling used by dentists worldwide. It is banned in Sweden and restricted in Norway and Denmark. DT

(Edited by Daniel Zimmermann, DTI)

AD

# PROMEDICA

Highest quality made in Germany

- ▶ high quality glass ionomer cements
- ▶ first class composites
- ▶ innovative compomers
- ▶ modern bonding systems
- ▶ materials for long-term prophylaxis
- ▶ temporary solutions
- ▶ bleaching products...

All our products convince by

- ▶ excellent physical properties
- ▶ perfect aesthetical results

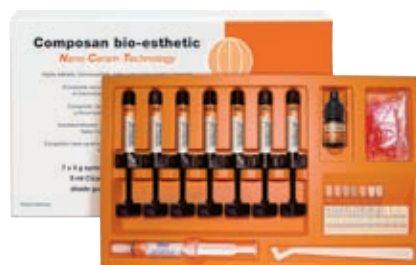Meet us at  
several exhibitions -  
[www.promedica.de](http://www.promedica.de)

New:  
Bleach Shade!



**Temporary crown and bridge material**

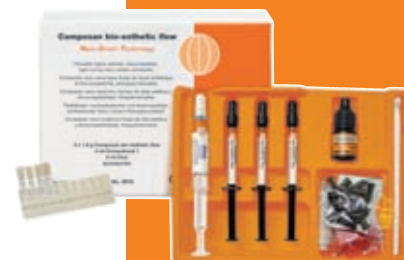- particular fracture and wear resistance
- now available in 6 attractive shades



**Light-curing nano-ceram composite**

- universal for all cavity classes
- comfortable handling, easy modellation
- highly esthetic and biocompatible

Nano-Ceram-Technology



• exact match of translucency and shade to the packable Composan bio-esthetic



**Resin-reinforced glass ionomer luting cement**

- strong adhesion, very low film thickness
- especially suited for zirconia-based pieces

**PROMEDICA Dental Material GmbH**  
Tel. + 49 43 21 / 5 41 73 · Fax + 49 43 21 / 5 19 08  
Internet: <http://www.promedica.de> · eMail: [info@promedica.de](mailto:info@promedica.de)

**PROMEDICA**



# Prison dentist gets prison sentence

A dentist who treated jail inmates has been given a 2.5-year prison sentence for defrauding the NHS.

According to news reports, John Hudson was jailed for claiming more than £300,000 from the health service by billing twice for the same treatment. Hudson, 58, provided dental care

for inmates at HMP Altcourse, a privately run facility at Fazakerley near Liverpool. Dental services at Altcourse were also contracted out and the dentist took advantage of a change in NHS accounting and billing systems in 2006.

The court heard that a good part of the illegally gotten pay-

ments went on fees for the education of his three children and holidays, but he now owes £40,000 and is being sued by the NHS for £500,000.

Hudson admitted to two charges of dishonesty and illegally obtaining credit from the health service. Judge Graham



Morrow QC, who sentenced Hudson yesterday at Liverpool Crown Court, said that Hudson had held a respected position in the community at the nearby town of Whitworth, but had committed acts of blatant dishonesty that deprived patients of money that should have gone towards their care. It was revealed that

Hudson was paid by HMP Altcourse but also claimed £307,000 over two years.

It was also reported that Hudson approached Liverpool Primary Care Trust about a contract at the jail demanding £247,000 a year; he went on to accept half that figure.DT

## EAO votes first Brit for president

Daniel Zimmermann  
DTI

LONDON, UK/LEIPZIG, Germany: Dr David A. Stone has been elected the first British President of the European Association for Osseointegration (EAO). The dentist from Perthshire in the UK, who also serves as Chairman of the Royal College of Surgeons of Edinburgh Advisory Board in Implant Dentistry, took over from Prof. Christoph Hämmerle, Switzerland, during the association's recent congress in Glasgow in October. He will serve as president for 2011/2012.

The meeting also saw Prof. Søren Schou from Denmark instated as President-Elect. French Prof. Pascal Valentini from Paris will be taking over as new Secretary-General.

"Dentistry is still an 'empirical discipline', relying on evidence to provide the most appropriate way of treating patients. A very important part of the EAO's philosophy is to bridge the gap between science and clinical practice." Dr Stone told Dental Tribune Asia Pacific. "As president of this organisation I intend



Dr Paul Stone addressing the audience at the EAO congress in Glasgow. (DTI/Photo courtesy of the European Association for Osseointegration, Belgium)

to ensure that this is further strengthened in a way that is relevant to modern practice."


Founded in Munich in Germany in the late 1980s, the EAO aims to promote and facilitate research, clinical applications, and treatment methods based on the principles of osseointegration. The organisation's recent congress in the UK focused on a wide range of surgical, prosthodontic and planning processes in implant dentistry. DT

## Malpractice in Pakistan spreads

Policy makers in Pakistan have urged the government to condemn the spread of medical malpractice through tougher restrictions on the registration of medical and dental personnel. According to the Pakistan Ministry of Health, over 200,000 doctors including 70,000 dentists currently practice without a licence. DT

## Korean kids have better oral health

Dentists from the Department of Preventative and Public Health Dentistry at the Seoul National University in South Korea have reported a decline of dental decay among children. Most improvement was observed in the age group 9 where, in 2006, over 40 per cent had lower caries levels compared to the year 2000. DT



### ESTHETIC CURRICULUM

**Program Chairs:**  
Dr. Ed McLaren & Dr. Sascha Jovanovic

**Session Chairs:**  
Dr. Didier Dietschi, Dr. Daniel Edelhoff, Dr. Mauro Fradeani

**SESSION I - FEBRUARY 18 - 21, 2011  
IN ATHENS, GREECE**  
DIRECT RESTORATIONS AND ADHESIVES  
with DR. DIDIER DIETSCHI and others

**SESSION II - JUNE 24 - 27, 2011  
IN ATHENS, GREECE**  
INDIRECT RESTORATIONS, FULL CERAMIC  
CROWNS AND VENEERS  
with DR. DANIEL EDELHOFF and others

**SESSION III - OCTOBER 2 - 5, 2011  
IN ATHENS, GREECE**  
ALL CERAMIC RESTORATIONS AND  
FIXED PROSTHODONTICS  
with DR. MAURO FREDEANI & DR. STAVROS PELEKANOS


**SESSION IV - NOVEMBER 28 - DECEMBER 2, 2011  
IN LOS ANGELES, CALIFORNIA**  
GRADUATING WEEK AT UCLA  
with DRS. ED MCLAREN, SASCHA JOVANOVIC, BRIAN LESAGE  
TODD SCHOENBAUM, PASCAL & MICHEL MAGNE

### PROGRAM FEATURES

- CLASSROOM EDUCATION
- LIVE PATIENT TREATMENTS
- CASE PRESENTATIONS
- HANDS-ON
- 90 HOURS SELF-STUDY
- 217 HOURS CE
- 2 CERTIFICATES from gIDE and UCLA


**2011 gIDE/UCLA 1 YEAR MASTER PROGRAM IN ESTHETIC DENTISTRY**




**EXPERT FACULTY**  
DIDIER DIETSCHI, MAURO FREDEANI,  
DANIEL EDELHOFF, STAVROS PELEKANOS,  
PANOS BAZOS, ED MCLAREN,  
SASCHA JOVANOVIC, PASCAL &  
MICHEL MAGNE, BRIAN LESAGE & OTHERS...



**Register & More Information at:**  
**Contact in Athens:**  
 Lito Christofilopoulou  
 Tel: +30 210 213 2084, +30 210 222 2637  
 E-mail: lito@omnipress.gr, omnipress@omnipress.gr  
 Web: www.omnicongresses.gr

**Contact in the US:**  
 Nena Puga  
 Tel.: +1 310 696 9025  
 E-mail: nena@gidedental.com  
 website: www.gidedental.com

Media Partner: 

**SPONSORS**  
  

### Editorial Board

Prof. Abdullah Al-Shammary, Restorative Dentistry, KSA  
 Prof. Hussain F. Al Huwaizi, Endodontics, Iraq  
 Prof. Samar Burgan, Oral Medicine, Jordan  
 Dr. Abdel Salam Al Askary, Implantology, Egypt

Dr. Talal Al-Harbi, Orthodontist, Qatar  
 Dr. Mohammed H. Al Jishi, Bahrain  
 Dr. Lara Bakaeen, Prosthodontist, Jordan  
 Dr. Aisha Sultan, Periodontist, UAE  
 Dr. Kamal Balaghi Mobin Aesthetics, Iran

## DENTAL TRIBUNE

The World's Dental Newspaper - Middle East & Africa Edition

### Published by Education Zone

in licence of Dental Tribune International GmbH

© 2010, Dental Tribune International GmbH. All rights reserved.

Dental Tribune makes every effort to report clinical information and manufacturer's product news accurately, but cannot assume responsibility for the validity of product claims, or for typographical errors. The publishers also do not assume responsibility for product names or claims, or statements made by advertisers. Opinions expressed by authors are their own and may not reflect those of Dental Tribune International.

*President/CEO*      Yasir Allawi  
y.allawi@dental-tribune.ae

*Director mCME:*      Dr. D. Mollova  
info@cappmea.com

*Marketing manager*      Khawla Najib  
khawla@dental-tribune.ae

*Production manager*      Hussain Alvi  
dentalme@dental-tribune.ae

PO Box 214592, Dubai, UAE, Tel + 971 4 391 0257  
 Fax + 971 4 366 4512 [www.dental-tribune.com](http://www.dental-tribune.com)



## A-dec Introduces Its Newest Family Member: A-dec 200™

**New Point-of-entry A-dec 200 Offers No-Compromise Performance and Real A dec Value**

A-dec, a global leader in dental equipment, introduces A dec 200™, the newest in A dec's lineup of patient chairs and delivery systems, with input from dental professionals around the world to accommodate the wide range of practice styles found in global markets.

The space-saving chair-mounted delivery system includes a telescoping assistant's

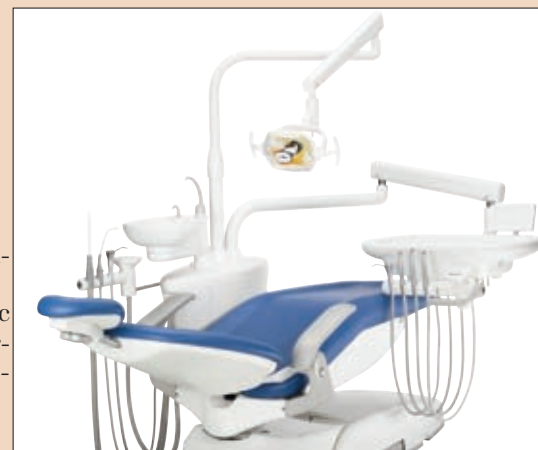arm and an oversized tray to hold everything the dental team needs. The new multi-axis light provides easy and precise positioning of illumination, and the cuspidor rotates conveniently to the patient when needed.

AD

The chair, light and cuspidor functions are easily controlled from A dec's modern touchpad and small and large practices will enjoy the open platform that leaves room to add or change an-

cillary devices for peak performance now, and in the future.

To learn more about A-dec 200, contact your local authorized A-dec dealer. [www.a-dec.com](http://www.a-dec.com).



## Colgate ranks top among Asian customers

Daniel Zimmermann  
DTI

HONG KONG/LEIPZIG, Germany: Consumers in Singapore, Malaysia and Hong Kong consider Colgate one of their favourite brands. A recent survey conducted by the Nielsen Company Singapore & Malaysia has found that Colgate, a toothpaste manufactured and distributed by US-based consumer products giant Colgate-Palmolive, is a brand preferred by the majority of consumers in all three markets. A similar survey in India also put it amongst consumers' most trusted brands.

Colgate has ranked top amongst consumers in recent years but has had to relinquish the top spot recently to other companies, including Nokia and Internet giant Google. However, the brand was the only one to achieve top ten rankings in all four countries, Nielsen reports.

Colgate, which is based in New York, is one of the largest distributors of consumer dental products worldwide. In 2009, the company reported a record profit of US\$631 million, which they said was mainly driven by increasing toothpaste sales globally. Colgate also sells manual and electric toothbrushes, mouthwash, and tooth-whitening products.

"In this time of economic uncertainties, it is even more crucial to have strong brands to retain customer loyalty and sustain business growth. Brands with the greatest equity are more likely to tide over the tough times, as customers are willing to pay higher prices for products which they have established a closer relationship with," said Paul Richmond, Managing Director, Consumer Group, the Nielsen Company Singapore and Malaysia.

The Nielsen reports identified over 500 brands across 93 categories of consumer products and services in Singapore, Malaysia, Hong Kong and India. [DTI](#)

## كلية نيقولا وآسب الجامعية NICOLAS & ASP UNIVERSITY COLLEGE

The 1st Accredited Dental Postgraduate Training Programs in the UAE

**Register NOW...**

### Masters Degree in Pediatric Dentistry

- Next Intake - (5 February 2011)
- 3 years study in UAE
- Accredited by
  - UAE Ministry of Higher Education & Scientific Research

**NEW**

### Diploma in Advanced Education in General Dentistry (AEGD)

- New Intake
- 2 years Higher Diploma in UAE
- Accredited by
  - UAE Ministry of Higher Education & Scientific Research

### Masters Degree in Orthodontics

- 5th Intake (5 February 2011)
- 3 years study in UAE
- Recognized by Swedish National Board of Health and Welfare
- In collaboration with Malmö University, Sweden
- Accredited by
  - UAE Ministry of Higher Education & Scientific Research
  - Saudi Commission for Health Specialities

### High Diploma in Oral Implantology

- 5th Intake (12 January 2011)
- 1 year (modules) for practicing dentists and specialists
- Program is offered in cooperation with Gothenberg University, Sweden
- Accredited By
  - UAE Ministry of Higher Education & Scientific Research

**Unique group of European & American faculty**

**For more information: Tel.: 00971 43624788**



### Abu Dhabi Headquarters

Admission Office:  
Al Odaid Office Tower, Airport Road, Abu Dhabi, UAE  
10th Floor, Office 1201  
Telephone: +971 2 404 7141

### Dubai Branch

Dubai Healthcare City  
Ibn Sina Building (No. 27)  
Block D, 3rd floor, Office 302  
Telephone: +971 4 3624787

Fax: +971 4 362 4793

P.O. Box: 53382, Dubai, UAE

Website: [www.dubaipostgraduate.com](http://www.dubaipostgraduate.com)

Email: [info@dubaipostgraduate.com](mailto:info@dubaipostgraduate.com)



# Frenectomy review: Comparison of conventional techniques with diode laser

Authors\_Dr M.L.V. Prabhuji, Prof Dr S.S. Madhu Preetha, Dr Ameya G. Moghe, India

## Introduction

The word frenum is derived from the Latin word “fraenum”. Frena, are triangle-shaped folds found in the maxillary and mandibular alveolar mucosa, and are located between the central incisors and canine premolar area. Frenum may be classified depending upon its morphology as:

- Long and thin
- Short and broad. Depending upon the attachment level, frenum has been classified as: (Placek et al. 1974)
- Mucosal
- Gingival
- Papillary
- Papillary penetrating.

When the insertion point of the frena is at the gingival margin it may pose a problem (Corn 1964). This kind of abnormal insertion of the frenum may cause marginal recession of the gingiva. Abnormal frenal insertion can distend and retract the marginal gingiva or papilla away from the tooth when the lip is stretched. A frenum that encroaches on the margin of the gingiva may interfere with plaque removal, and tension on this frenum may tend to open the sulcus. This condition may be more conducive to plaque accumulation and inhibit proper oral hygiene. Aberrant frenum can be treated by frenectomy or frenotomy procedures. The terms frenectomy and frenotomy signify operations that differ in degree of surgical approach. Frenectomy is a complete removal of the frenum, including its attachment to the underlying bone, and may be required for correction of abnormal diastema between maxillary central incisors (Friedman 1957). Frenotomy is the incision and relocation of the frenal attachment.

## Indications

- The indications for frenectomy procedure include
- Tension on the gingival margin (frenal-pull concomitant with or without gingival recession)
- Facilitate orthodontic treatment
- Facilitate home care. Techniques for frenectomy
- Conventional technique
- Using soft tissue lasers.

## Conventional technique

Conventional technique utilises traditional instruments like the scalpels and periodontal knives. Different procedures have been mentioned under the conventional frenectomy technique. These include Dieffenbach, Schuchardt, & Mathis. The most common being Dieffenbach V-plasty & Schuchardt Zplasty.

## Armamentarium

- Bard-Parker handles no. 3, No. 15 blade, mosquito haemostat, suture material.
- Procedure

## Dieffenbach V-plasty

Surgical steps: The area is anesthetized by giving local anes-

thetic injection (2 % lignocaine with 1:200,000 adrenaline). After anesthesia is achieved, the frenum is held with the mosquito haemostat to its full depth. With the No. 15 blade mounted on a Bard-Parker handle, an incision is made along the upper surface of the haemostat till the entire depth of the frenum extending into the vestibule. A similar incision is repeated on the under-surface of the haemostat so that the haemostat is detached along with the frenal tissue within its beaks. Once this is achieved, a rhomboid area exposing the deeper connective tissue fibers becomes visible. With the help of fine scissors, the deeper fibers are detached from the underlying periosteum. Periosteal scoring is done with the help of surgical blade so as to prevent the reattachment of fibers. The labial mucosa is undermined so as to permit the approximation of the edges. The bleeding is controlled by applying pressure packs.

Suturing: The diamond shaped wound is sutured using either a 4-0 or 5-0 silk sutures in simple interrupted fashion. Proper approximation of the margins is ensured. A periodontal dressing is placed to cover the surgical area.

Frenectomy by V-plasty may result in scar formation that could prevent the mesial movement of the central incisors (West 1968). However, it is typically a safe surgical procedure with no notable complications.

## Schuchardt Z-plasty

The main advantage of this method over the Vplasty method was minimal scar tissue formation. The method requires a skilled operator as it is tedious to perform.

Frenectomy using soft tissue lasers

LASER (Light Amplification by Stimulated Emission of Radiation) is based on Albert Einstein's theory of spontaneous and stimulated emission of radiation. It was Maiman in 1960 who gave the first laser prototype using ruby crystal. Shortly there after, in 1961, Snitzer published the prototype for the Nd:YAG laser.

The first application of a laser to dental tissue was reported by Goldman et al. and Stern and Sognnaes, each article describing the effects of the ruby laser on enamel and dentin. Lasers designed for surgery deliver concentrated and controllable energy to the tissue. For the laser to have effect the energy must be absorbed. The degree of absorption in the tissue varies as a function of wavelength and characteristics of target tissue. As the temperature increases at surgical site, the soft tissues are subjected to:

- Warming (37 °C to 60 °C)
- Welding (60 °C to 65 °C)
- Coagulation (65 °C to 90 °C)
- Protein denaturation (90 °C to 100 °C)
- Drying (100 °C)
- Carbonization (above 100 °C)

## Carbon dioxide laser

The carbon dioxide lasers have a wavelength of 10,600 nm. The beam of this laser falls in the infrared range and is thus invisible. This made the use of CO2 lasers awkward. Thus later on a quartz fiber incorporating a 630 nm coaxial He-Ne laser was used as an aiming beam in the handpiece. The CO2 laser received safety clearance from FDA in 1976 for use in soft tissue surgery. With the CO2 laser there is rapid intracellular rise of temperature and pressure leading to cellular rupture and release of 'laser plume' (vapour and cellular debris).

The CO2 laser is readily absorbed by water. Soft tissue consists of 75 % to 90 % water, 98 % of the incident energy is converted into heat and absorbed at the tissue surface with very little scatter or penetration. Thus moist surface is essential for maximal effect. With CO2 laser no contact is made with the tissue, and no tactile feedback occurs.

## Neodymium:YAG laser

The Nd:YAG laser has a wavelength of 1,064 nm and lies in the infrared zone like the CO2 laser. The Nd:YAG laser penetrates water upto 60 mm after which it is attenuated 10 % of its original strength. Thus energy is scattered in soft tissue rather than being absorbed onto the surface. The wavelength of Nd:YAG laser is at-

tracted to colours and as a result its scattering in heavily pigmented soft tissues like skin is almost double its absorption.

This heating effect of the Nd:YAG laser is ideal for the ablation of potentially haemorrhagic abnormal tissue and for haemostasis of small capillaries and venules. In 1990, the FDA approved soft tissue removal by means of a pulsed Nd:YAG laser. In 1997, the FDA approved sulcular debridement by means of a pulsed Nd:YAG laser.

## Erbium:YAG laser

The Er:YAG laser was introduced in 1974 by Zharikov et al. as

a solid-state laser that generates a light with a wavelength of 2,940 nm. Of all lasers emitting in the near- and mid-infrared spectral range, the absorption of the Er:YAG laser in water is the greatest because its 2,940 nm wavelength coincides with the large absorption band for water.

The absorption coefficient of water of the Er:YAG laser is theoretically 10,000 and 15,000–20,000 times higher than that of the CO2 and the Nd:YAG lasers, respectively. Since the Er:YAG laser is well absorbed by all biological tissues that contain water molecules, this laser is indicated not only for the treatment of soft tissues but also for ablation of hard tissues. The FDA approved the pulsed Er:YAG laser for hard tissue treatment such as caries removal and cavity preparation in 1997, unchanged for soft tissue surgery and sulcular debridement in 1999 and for osseous surgery in 2004.

| Laser Type    |  | Wavelength | Colour       |
|---------------|--|------------|--------------|
| Excimer laser | Argon fluoride (ArF)<br>Xenon chloride (XeCl)  | 193 nm     | Ultraviolet  |
|               |  | 308 nm     | Ultraviolet  |
| Gas laser     | Argon<br>Helium-Neon (HeNe)<br>Carbon dioxide (CO <sub>2</sub> )   | 488 nm     | Blue         |
|               |  | 514 nm     | Blue green   |
|               |  | 637 nm     | Red          |
|               |  | 10,600 nm  | Infrared     |
| Diode laser   | Indium Gallium Arsenide Phosphorus (InGaAsP)<br>Gallium Aluminium Arsenide (GaAlAs)<br>Gallium Arsenide (GaAs)<br>Indium Gallium Arsenide (InGaAs) | 655 nm     | Red          |
|               |  | 677–830 nm | Red-Infrared |
|               |  | 840 nm     | Infrared     |
|               |  | 980 nm     | Infrared     |
| Solid state   | Frequency doubled Alexandrite<br>Potassium Titanyl Phosphate (KTP)   | 337 nm     | Ultraviolet  |
|               |  | 532 nm     | Green        |
| Lasers        | Neodymium:YAG (Nd:YAG)<br>Holmium:YAG (Ho:YAG)<br>Erbium:Chromium (Er,Cr:YSGG)<br>Erbium:YSGG (Er:YSGG)<br>Erbium:YAG (Er:YAG)                     | 1,064 nm   | Infrared     |
|               |  | 2,100 nm   | Infrared     |
|               |  | 2,780 nm   | Infrared     |
|               |  | 2,790 nm   | Infrared     |
|               |  | 2,940 nm   | Infrared     |
|               |  |            | Infrared     |

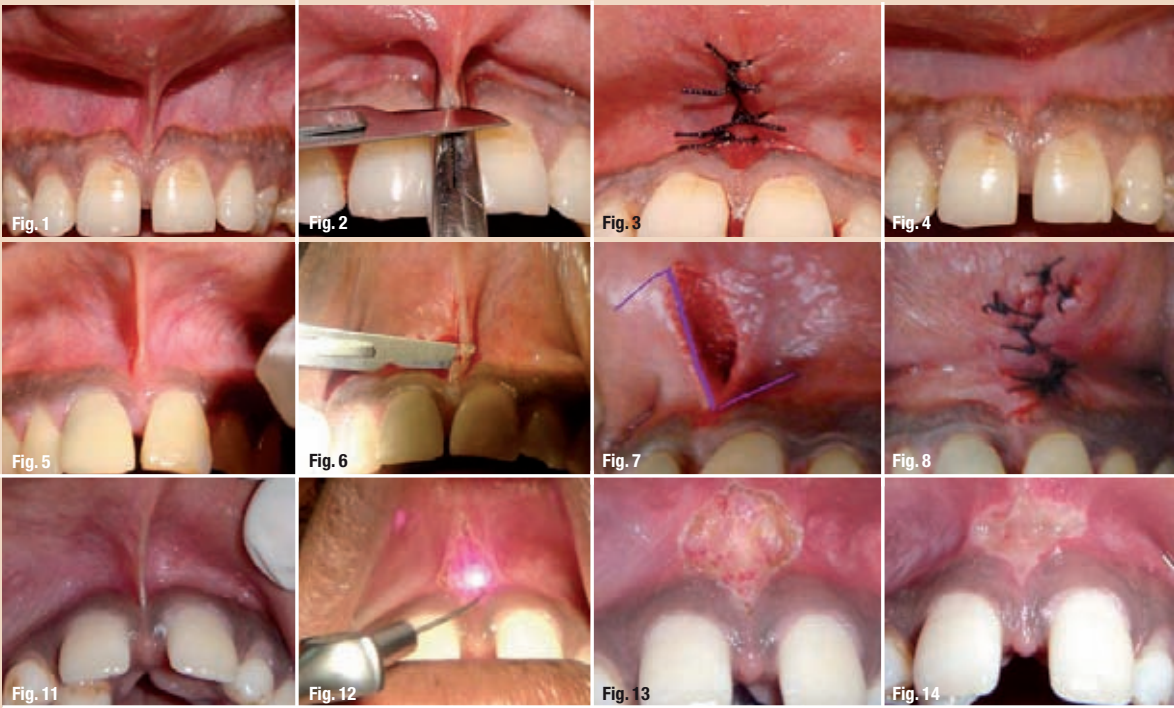
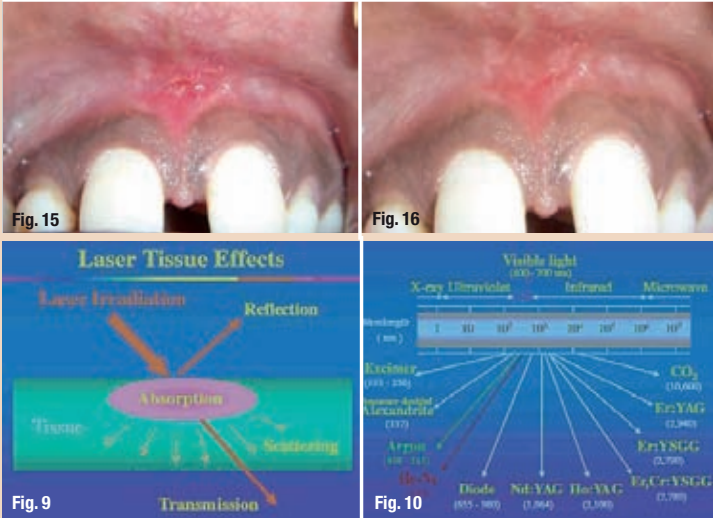


Fig. 1\_Abnormal frenal attachment.  
Fig. 2\_Haemostat in place & incision made.  
Fig. 3\_Sutures placed.  
Fig. 4\_Post-op two months.  
Fig. 5\_Papillary frenal attachment.  
Fig. 6\_Horizontal incision made.  
Fig. 7\_Outline for Z-plasty.  
Fig. 8\_Sutures placed.  
Fig. 11\_Papillary penetrating frenum.  
Fig. 12\_Diode laser applied.  
Fig. 13\_Immediate Post-operative view.  
Fig. 14\_Post-op 2 days.  
Fig. 15\_Post-op 1 week.  
Fig. 16\_Post-op 2 months.





### Diode lasers

The diode laser is a solid-state semiconductor laser that typically uses a combination of Gallium (Ga), Arsenide (Ar), and other elements such as Aluminum (Al) and Indium (In) to change electrical energy into light energy. The wavelength range is about 800–980 nm. The laser is emitted in continuous wave and gated-pulsed modes, and is usually operated in a contact method using a flexible fiber optic delivery system. Laser light at 800–980 nm is poorly absorbed in water, but highly absorbed in hemoglobin and other pigments (ALD 2000). Since the diode basically does not interact with dental hard tissues, the laser is an excellent soft tissue surgical laser (Romanos G, 1999), indicated for cutting and coagulating gingiva and oral mucosa, and for soft tissue curettage or sulcular debridement.

The FDA approved oral soft tissue surgery in 1995 and sulcular debridement in 1998 by means of a diode laser (GaAlAs 810 nm). The diode laser exhibits thermal effects using the 'hot-tip' effect caused by heat accumulation at the end of the fiber, and produces a relatively thick coagulation layer on the treated surface (ALD 2000). The usage is quite similar to electrocauterization. Tissue penetration of a diode laser is less than that of the Nd:YAG laser, while the rate of heat generation is higher (Rastegar S 1992), resulting in deeper coagulation and more charring on the surface compared to the Nd:YAG laser. The width of the coagulation layer was reported to be in excess of 1.0 mm in an incision of bovine oral soft tissue in vitro (White JM 2002). The advantages of diode lasers are the smaller size of the units as well as the lower financial costs.

### Argon laser

The argon laser uses argon ion gas as an active medium and is fiber optically delivered in continuous wave and gated pulsed modes. This laser has two wavelengths, 488 nm (blue) and 514 nm (bluegreen), in the spectrum of visible light. The argon laser is poorly absorbed in water and therefore does not interact with dental hard tissues. However, it is well absorbed in pigmented tissues, including haemoglobin and melanin, and in pigmented bacteria.

The argon laser was approved by the FDA for oral soft tissue surgery and curing of composite materials in 1991 and for tooth whitening in 1995. Considering the advantages of eradication of pigmented bacteria, this laser may be useful for the treatment of periodontal pockets.

### Alexandrite laser

The Alexandrite laser is a solid-state laser employing a gemstone called Alexandrite, which is chromium-doped: Beryllium-Aluminum-Oxide chrysoberyl (Cr+3; BeAl<sub>2</sub>O<sub>4</sub>) and is one of the few trichroic minerals. Rechmann & Henning first reported that the frequency-doubled Alexandrite laser (wavelength 337 nm, pulse duration 100 ns, double spikes, q-switched) could remove dental calculus in a completely selective

mode without ablating the underlying enamel or cementum. The development of this laser for clinical use is widely expected due to its excellent ability for selective calculus removal from the tooth or root surface without ablating the tooth structure.

### Excimer laser

Excimer lasers are lasers that use a noble-gas halide, which is unstable, to generate radiation, usually in the ultraviolet region of the spectrum. Frentzen et al.

demonstrated that the ArF excimer laser, wavelength 193 nm, could effectively remove dental calculus without causing any damage to the underlying surface. The cementum surface was clean, and only a slight roughness could be observed after irradiation, supporting the use of excimer lasers for laser scaling. Folwaczny et al. have reported that the 308 nm wavelength XeCl excimer laser could effectively ablate dental calculus without thermal damages or smear layer production.

Frenectomy procedure using diode lasers Diode laser (A.R.C. Fox™) with wavelength of 810 nm was selected for the procedure. No local anaesthesia was given to the patient. The frenum was stretched to visualize its extent. The diode laser was applied in a contact mode with focused beam for excision of the tissue. The ablated tissue was continuously mopped using wet gauze piece. This takes care of the charred tissue and prevents excessive thermal damage to underlying soft tissue. The tis-

sue was lased until all the underlying muscle fibers were dissected. No sutures were placed at the end of this procedure. Patients were asked to take analgesics only if needed. Advantages of Laser over Conventional technique:

No need of local anaesthesia. Hence it's a painless procedure. As a result there is less patient apprehension.

Bloodless operative field, thus better visibility.

No need of periodontal dressing, therefore no patient discomfort

AD

EMS-SWISSQUALITY.COM

**EMS**<sup>+</sup>  
ELECTRO MEDICAL SYSTEMS

# SUBGINGIVAL WITHOUT LIMITS

THE DEEPEST  
PERIODONTAL POCKETS  
NOW WITHIN REACH  
WITH THE ORIGINAL  
AIR-FLOW METHOD

**AIR-FLOW®  
KILLS  
BIOFILM**  
ems-swissquality.com

> Subgingival application of the Original AIR-FLOW® method reduces periodontal pocket depth, removes biofilm, prevents periimplantitis

## AIR-FLOW MASTER®

is the name of the world's first subgingival prophylaxis unit. With two application systems in one. For sub- and supragingival use with matching handpiece and powder chamber.

Incredibly easy to operate. Uniquely simple to use.

Touch 'n' flow: Highly sensitive 3-touch panel for easy choice of settings.



The inventor of the Original Air-Flow Method is now first to cross the boundaries of conventional prophylaxis.

**"I FEEL  
GOOD"**

For more information > welcome@ems-ch.com



# CBCT applications in dental practice: A literature review

Authors\_ Dr Mohammed A. Alshehri, Dr Hadi M. Alamri & Dr Mazen A. Alshalhoob, Saudi Arabia

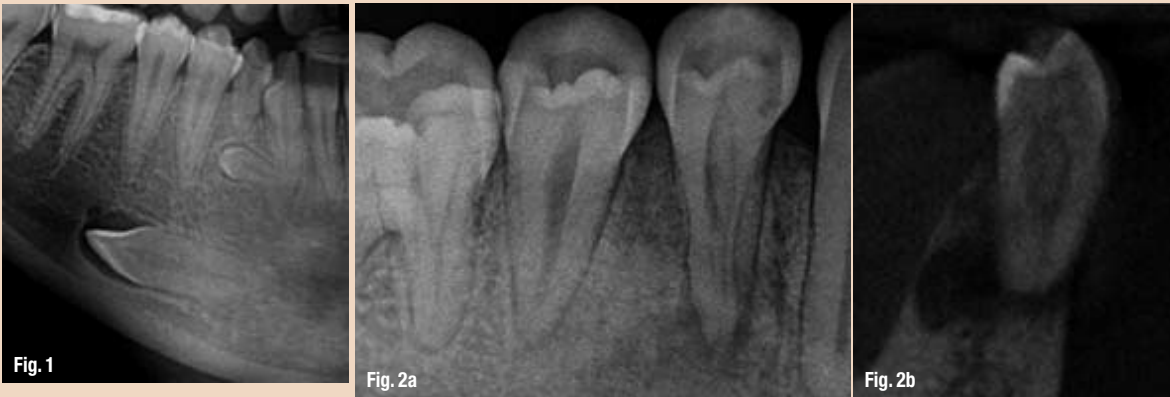
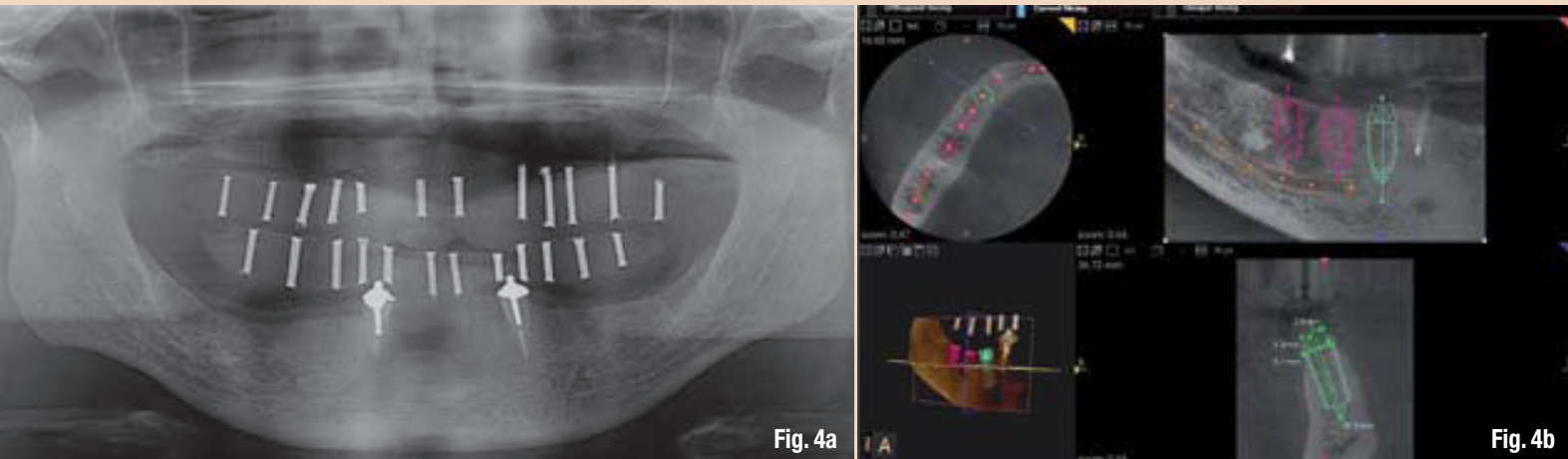
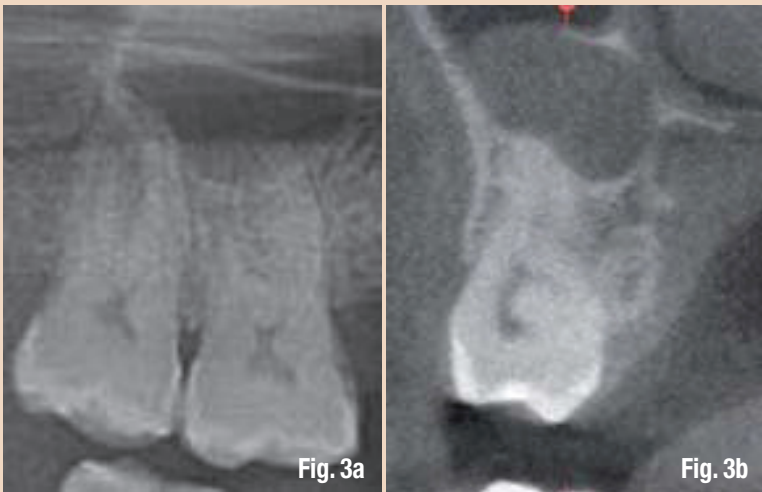
(mCME articles in Dental Tribune (always page 6) has been approved by HAAD as having educational content acceptable for (Category 1) CME credit hours. Term of approval covers issues published within one year from the distribution date (September, 2010). This (Volume/Issue) has been approved by HAAD for 2 CME credit hours.

Two-dimensional imaging modalities have been used in dentistry since the first intra-oral radiograph was taken in 1896. Significant progress in dental imaging techniques has since been made, including panoramic imaging and tomography, which enable reduced radiation and faster processing times. However, the imaging geometry has not changed with these commonly used intraoral and panoramic technologies. Cone-beam computed tomography (CBCT) is a new medical imaging technique that generates 3-D images at a lower cost and absorbed dose compared with conventional computed tomography (CT). This imaging technique is based on a cone-shaped X-ray beam centred on a 2-D detector that performs one rotation around the object, producing a series of 2-D images. These images are re-constructed

in 3-D using a modification of the original cone-beam algorithm developed by Feldkamp et al. in 1984.<sup>1</sup> Images of the cranio-facial region are often collected with a higher resolution than those collected with a conventional CT. In addition, the new systems are more practical, as they come in smaller sizes.<sup>2</sup> Today, much attention is focused on the clinical applications—diagnosis, treatment and follow-up—of CBCT in the various dental disciplines. The goal of the following systemic review is to review the available clinical and scientific literature pertaining to different clinical application of CBCT in the dental practice. **Materials and methods** Clinical and scientific literature discussing CBCT imaging in dental clinical applications was reviewed. A MEDLINE

| Specialty                        | Number of articles | in %  |
|----------------------------------|--------------------|-------|
| Oral and maxillofacial surgery   | 36                 | 26.86 |
| Endodontics                      | 32                 | 23.88 |
| Implantology                     | 22                 | 16.42 |
| Orthodontics                     | 16                 | 11.94 |
| General dentistry                | 14                 | 10.45 |
| Temporomandibular joint disorder | 8                  | 5.97  |
| Periodontics                     | 5                  | 3.73  |
| Forensic dentistry               | 1                  | 0.75  |

Table I



(PubMed) search from 1 January 1998 to 15 July 2010 was conducted. Cone-beam computed tomography in dentistry was used as key phrase to extend the search to all the various dental disciplines. The search revealed 540 papers that were screened in detail. Owing to a lack of relevance to the subject, 406 papers were excluded. Thus, the systemic review consisted of 134 clinically relevant papers, which were analysed and categorised (Table I).

### Analysis

#### Oral and maxillofacial surgery

CBCT enables the analysis of jaw pathology,<sup>3–11</sup> the assessment of impacted teeth (Fig. 1), supernumerary teeth and their relation to vital structures,<sup>6,12–21</sup> changes in the cortical and trabecular bone related to bisphosphonate-associated osteonecrosis of the jaw<sup>5,22–25</sup> and the assessment of bone grafts.<sup>24</sup> It is also helpful in analysing and assessing paranasal sinuses<sup>6,25</sup> and obstructive sleep apnea.<sup>27–28</sup> As the images are collected from many different 2-D slices, the system has proven its superiority in overcoming superimpositions and calculating surface distances.<sup>28–29</sup> This advantage made it the technique of choice in mid-face fracture cases,<sup>30–31</sup> orbital fracture assessment and management<sup>32</sup> and for inter-operative visualisation of the facial bones after fracture.<sup>33–34</sup> Since it is not a magnetic resonance technique, it is the best option for intra-operative navigation dur-

ing procedures, including gunshot wounds.<sup>35–36</sup> CBCT is largely used in orthognathic surgery planning when facial orthomorphologic surgery is indicated that requires detailed visualisation of the interocclusal relationship in order to augment the 3-D virtual skull model with a detailed dental surface. With the aid of advanced software, CBCT facilitates the visualisation of soft tissue to allow for control of post-treatment aesthetics, for example in cleft palate cases to evaluate lip and palate bony depressions.<sup>37–42</sup> Research is underway to assess its ability to detect salivary gland defects.<sup>43</sup> Honda et al.<sup>44</sup> describe a clinical case in which the time needed to complete a tooth auto-transplant case was significantly shortened owing to the application of CBCT.

#### Endodontics

CBCT is a very useful tool in diagnosing apical lesions (Figs. 2a & b).<sup>21,45–56</sup> A number of studies have demonstrated its ability to enable a differential diagnosis of apical lesions by measuring the density from the contrasted images of these lesions, in whether the lesion is an apical granuloma or an apical cyst (Figs. 3a & b).<sup>49,55–57</sup> Cotton et al.<sup>46</sup> used CBCT as a tool to assess whether the lesion was of endodontic or non-endodontic origin. CBCT also demonstrated superiority to 2-D radiographs in detecting fractured roots. Vertical and horizontal root fracture detection is described in several

clinical cases.<sup>21,46,55–59</sup> It is also agreed that CBCT is superior to peri-apical radiographs in detecting these fractures, whether they are bucco-lingual or mesiodistal.<sup>60–61</sup> In cases with inflammatory root resorption, lesions are detected much easier in early stages with CBCT compared to conventional 2-D X-ray.<sup>21,62</sup> In other cases, such as external root resorption, external cervical and internal resorption, not only the presence of resorption was detected, but also the extent of it.<sup>21,46,54,56,63–64</sup> CBCT can also be used to determine root morphology, the number of roots, canals and accessory canals, as well as to establishing the working length and angulations of roots and canals.<sup>21,25,46,55–56,58,65–67</sup> It also is accurate in assessing root-canal fillings.<sup>47,51,56,58</sup> Owing to its accuracy, it is very helpful in detecting the pulpal extensions in talon cusps<sup>68</sup> and the position of fractured instruments.<sup>69</sup> It is also a reliable tool for pre-surgical assessment of the proximity of the tooth to adjacent vital structures, size and extent of lesions, as well as the anatomy and morphology of roots with very accurate measurements.<sup>21,46,48,50,54–58,69–72</sup>

**Figs. 3a & b** Apical cyst shown as orthopantomogram (a) and CBCT (b).

**Fig. 4a** Orthopantomogram for a full-mouth rehabilitation case. Only limited data can be obtained from this image.

**Fig. 4b** CBCT images for the same patient. Data obtained from these images regarding bone quality, implant length and diameter, implant location and proximity to vital structures is magnificent.



Additionally, in cases in which teeth are assessed after trauma and in emergency cases, its appli - cation can be a useful aid in reaching a proper diagnosis and treatment approach.<sup>46,55,75-74</sup>

Recently, owing to its reliability and accuracy, CBCT has also been used to evaluate the canal preparation in different instrumentation techniques.<sup>75-76</sup>

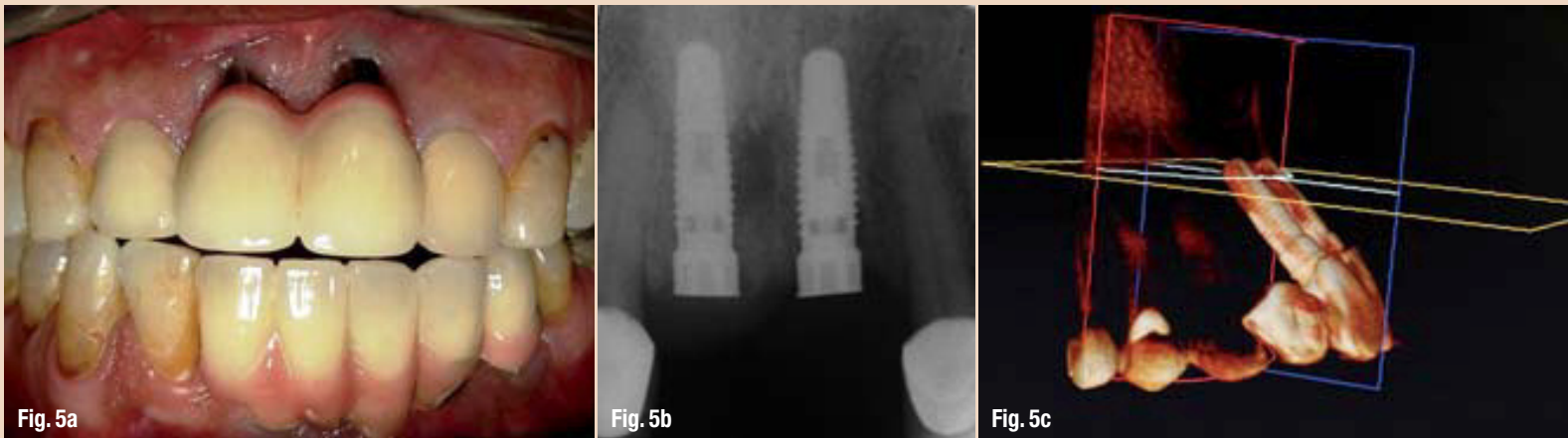
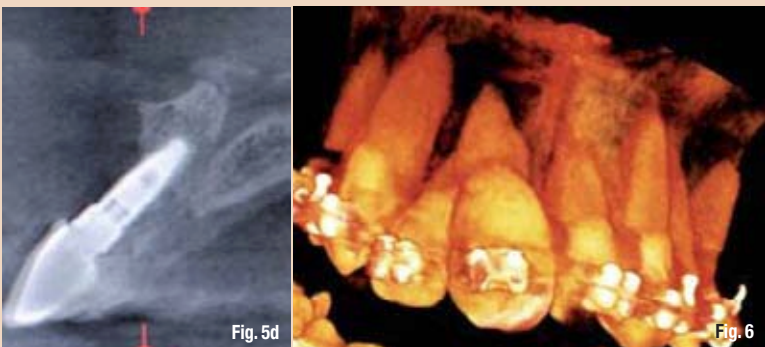Implantology

With increased demand for replacing missing teeth with dental implants, accurate measurements are needed to avoid damage to vital structures. This was achievable with conventional CT. However, with CBCT giving more accurate measurements at lower dosages, it is the preferred option in implant den-

Table II \_Typical doses of various dental radiological procedures.

Fig. 5d \_Total buccal plate destruction is evident in this CBCT image.

Fig. 6 \_CBCT image to assess the bone density during treatment.



tistry today (Figs. 4a & b).<sup>2,6,11,18,70,77-89</sup>

With new software that constructs surgical guides, damage is also reduced further.<sup>77,84,90-93</sup> Heiland et al.<sup>94</sup> describe a technique in which CBCT was used inter-operatively in two cases to navigate the implant insertion following microsurgical bone transfer.

CBCT enables the assessment of bone quality and bone quantity.<sup>18,26,70,80-81,85,88,95-97</sup> This leads to reduced implant failure, as case selection can be based on much more reliable information.

This advantage is also used for post-treatment evaluation and to assess the success of bone grafts (Figs. 5a-d).<sup>18,88</sup>

Orthodontics

Orthodontists can use CBCT images in orthodontic assessment and cephalometric analysis.<sup>6,70,84,98-99</sup> Today, CBCT is already the tool of choice in the assessment of facial growth, age, airway function and disturbances in tooth eruption.<sup>100-103</sup>

CBCT is a reliable tool in the assessment of the proximity to vi-

tal structures that may interfere with orthodontic treatment.<sup>104-105</sup> In cases in which mini-screw implants are placed to serve as a temporary anchorage, CBCT is useful for ensuring a safe insertion<sup>106-108</sup> and to assess the bone density before, during and after treatment (Fig. 6).<sup>109-110</sup>

Having different views in one scan, such as frontal, right and left lateral, 45-degree views and sub-mental, also adds to the advantages of CBCT.<sup>111,124</sup> As the images are self-corrected from the magnification to produce or-

Fig. 5a \_Clinical picture of multiple implants placed in 2005.

Fig. 5b \_Peri-apical radiograph for the implants replacing teeth #8 and #9. Little data can be collected from such an image.

Fig. 5c \_The CBCT image clearly demonstrates the amount of bone loss.

thogonal images with 1:1 ratio, higher accuracy is ensured. CBCT is thus considered a better option for the clinician<sup>115</sup>

Temporomandibular joint disorder

One of the major advantages of CBCT is its ability to define the true position of the condyle in the fossa, which often reveals possible dis - location of the disk in the joint, and the extent of translation of the condyle in the fossa.<sup>18,56,114</sup> With its accuracy, measurements of the roof of the glenoid fossa can be done easily.<sup>115-116</sup> Another advantage of some of the available devices is their ability to visualise soft tissue around the TMJ, which may reduce the need for magnetic resonance imaging in these cases.<sup>117</sup>

Owing to these advantages, CBCT is the imaging device of choice in cases of trauma, pain, dysfunction, fibro-osseous ankylosis and in detecting condylar cortical erosion and cysts.<sup>70,87,118-120</sup> With the use of the 3-D features, the imageguided puncture technique, which is a treatment modality for TMJ disk adhesion, can safely be performed.<sup>121</sup>

Periodontics

CBCT can be used in assessing a detailed morphologic description of the bone because it has proved to be accurate with only minimal error margins.<sup>56,122</sup> The measurements proved to be as accurate as direct measurements with a periodontal probe.<sup>56,123</sup> Furthermore, it also aids in assessing furcation involvements.<sup>20,56,116</sup>

CBCT can be used to detect buccal and lingual defects, which was previously not possible with conventional 2-D radiographs.<sup>56,124</sup> Additionally, owing to the high accuracy of CBCT measurements, intra-bony defects can accurately be measured and dehiscence, fenestration defects and periodontal cysts assessed.<sup>56,125-127</sup> CBCT has also proved its superiority in evaluating the outcome of regenerative periodontal therapy.<sup>124</sup>

General dentistry

Based on the available literature, CBCT is not justified for use

MEDIA CME Self-Instruction Program

Dental Tribune Middle East & Africa in collaboration with CAPP introduce to the market the new project mCME - Self Instruction Program.

mCME gives you the opportunity to have a quick and easy way to meet your continuing education needs. mCME offers you the flexibility to work at your own pace through the material from any location at any time. The content is international, drawn from the upper echelon of dental medicine, but also presents a regional outlook in terms of perspective and subject matter.

**How can professionals enroll?**

They can either sign up for a one-year (10 exercises) by subscription for the magazine for one year (\$65) or pay (\$20) per article. After the payment, participants will receive their membership number and will be able to attend to the program.

**How to earn CME credits?**

Once the reader attends the distance-learning program, he/she can earn credits in three easy steps:

1. Read the articles.
2. Take the exercises
3. Fill in the Questionnaire and Submit the answers by Fax (+971 4 36868883) or Email :info@cappmea.com

After submission of the answers, (name and membership number must be included for processing) they will receive the Certificate with unique ID Number within 48 to 72hours.

Articles and Questionnaires will be available in the website after the publication.

www.cappmea.com



Continuing Dental Education

mCME

EARN

upto 20mCME

credit hours

Accredited by Health Authority - Abu Dhabi

For more information: e-mail: info@dental-tribune.ae,  
Tel: + 971 4 391 0257, Fax: + 971 4 366 4512 Mob: + 971 50 6625011



in detecting occlusal caries, since the dose is much higher than conventional radiographs with no additional information gained. However, it proved to be useful in assessing proximal caries and its depth.<sup>20</sup> Table II shows examples of typical doses of various dental radiological procedures in dental practice.

### Forensic dentistry

Many dental age estimation methods, which are a key element in forensic science, are described in the literature. CBCT was established as a non-invasive method to estimate the age of a person based on the pulp-tooth ratio.<sup>128</sup>

### Discussion

CBCT scanners represent a great advance in dento-maxillofacial (DMF) imaging. This technology, introduced into dental use in the late 1990s,<sup>129</sup> has advanced dentistry significantly. The number of CBCT-related papers published each year has increased tremendously in the last years. The above systematic review of the literature related to CBCT-imaging applications in dental practice was undertaken in order to summarise concisely the indications of this new image technique in different dental specialties.

Cone-beam computed tomography in dentistry was used as key phrase in this systematic review. Other terminology encountered in the literature, such as cone-beam volumetric scanning, volumetric computed tomography, dental CT, dental 3-D CT and cone-beam volumetric imaging, did not result in additional relevant papers.<sup>130</sup>

The clinical applications for CBCT imaging in dentistry are increasing. The results of this review demonstrate that 134 papers were clinically relevant and that the most common clinical applications are in the field of oral and maxillofacial surgery, implant dentistry, and endodontics. CBCT has limited use in operative dentistry owing to the high radiation dose required in relation to its diagnostic value.

The literature on CBCT is promising and needs further research, especially with regard to its use in forensic dentistry, in order to explore more potentially beneficial indications in that area. No literature concerning direct CBCT indications in prosthodontics was found. However, several overlapping indications were found in other dental specialties attributing to the final standard of care in prosthodontic treatment. These indications include but are not limited to bone

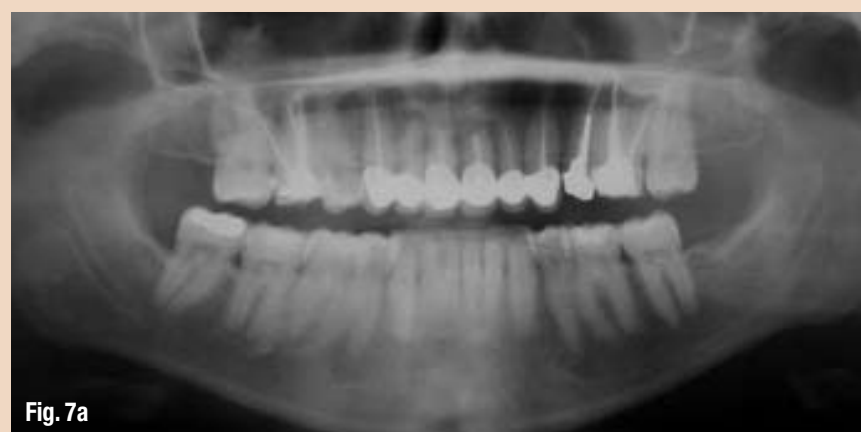

Fig. 7a

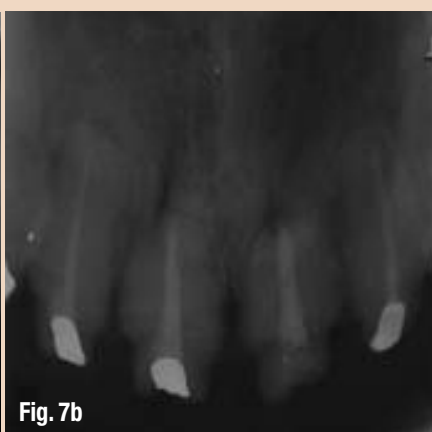


Fig. 7b

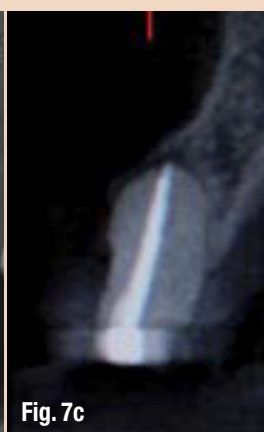

Fig. 7c

grafting, soft-tissue grafting, prosthetically driven implant placement, maxillofacial prosthodontics and temporomandibular joint disorder. CBCT images can also be of great value in special cases in which multiple teeth have to be assessed for restorability (Figs. 7a-e).

The latest CBCT units have a higher resolution, lower exposure, are less expensive and designed for use in dentistry. Additionally, the flat-panel detectors appear to be less prone to beam-hardening artefacts. There are, however, several important disadvantages as well, such as susceptibility to movement artefacts, low contrast resolution, limited capability to visualise internal soft tissues and, owing to distortion of Hounsfield Units, CBCT cannot be used for the estimation of bone density.

It is crucial that the ALARA principle (As Low As Reasonably Achievable) is respected during treatment, as far as the radiation dose of CBCT imaging is concerned. CBCT imaging will improve patient care, but users have to be trained to be able to interpret the scanned data thoroughly. Dentists should ask themselves whether these imaging modalities actually add to their diagnostic knowledge and raise the standard of dental care or whether they only place the patient at a higher risk. Continuous training, education and thorough research are thus absolutely essential.

One of the most clinically useful aspects of CBCT imaging is the highly sophisticated software that allows the huge volume of data collected to be broken down, processed or reconstructed.<sup>131</sup> This makes data interpretation much more user friendly, if the appropriate technical and educational knowledge is available.

The increasing popularity of CBCT resulted in numerous CBCT-unit manufacturers, frequent presentations at conferences and an increase in published papers. This resulted in an uncontrolled and non-evidence based exchange of radiation dose

values and attributed to the limited technical knowledge about medical imaging devices for new-user groups. As a result, the European Academy of DentoMaxilloFacial Radiology has developed the following basic principles on the use of CBCT in dentistry:<sup>132</sup>

1. CBCT examinations must not be carried out unless a history and clinical examination have been performed.
2. CBCT examinations must be justified for each patient to demonstrate that the benefits outweigh the risks.
3. CBCT examinations should potentially add new information to aid the patient's management.
4. CBCT should not be repeated on a patient 'routinely' without a new risk/benefit assessment having been performed.
5. When accepting referrals from other dentists for CBCT examinations, the referring dentist must supply sufficient clinical information (results of a history and examination) to allow the CBCT practitioner to perform the justification process.
6. CBCT should only be used when the question for which imaging is required cannot be answered adequately by lower dose conventional (traditional) radiography.
7. CBCT images must undergo a thorough clinical evaluation (radiological report) of the entire image dataset.
8. Where it is likely that evaluation of soft tissues will be required as part of the patient's radiological assessment, the appropriate imaging should be conventional medical CT or MR, rather than CBCT.
9. CBCT equipment should offer a choice of volume sizes, and examinations must use the smallest that is compatible with the clinical situation, if this provides a lower radiation dose to the patient.
10. Where CBCT equipment offers a choice of resolution, the resolution compatible with an adequate diagnosis and

the lowest achievable dose should be used.

11. A quality assurance programme must be established and implemented for each CBCT facility, including equipment, techniques and quality-control procedures.
12. Aids to accurate positioning (light-beam markers) must always be used.
13. All new installations of CBCT equipment should undergo a critical examination and detailed acceptance tests before use to ensure that radiation protection for staff, members of the public and patient are optimal.
14. CBCT equipment should undergo regular routine tests to ensure that radiation protection, for both practice/facility users and patients, has not significantly deteriorated.
15. For staff protection from CBCT equipment, the guidelines detailed in Section 6 of the European Commission document Radiation protection 136: European guidelines on radiation protection in dental radiology should be followed.
16. All those involved with CBCT must have received adequate theoretical and practical training for the purpose of radiological practices and relevant competence in radiation protection.
17. Continuing education and training after qualification are required, particularly when new CBCT equipment or techniques are adopted.
18. Dentists responsible for CBCT facilities, who have not previously received 'adequate theoretical and practical training', should undergo a period of additional theoretical and practical training that has been validated by an academic institution (university or equivalent). Where national specialist qualifications in dento-maxillofacial radiology exist, the design and delivery of CBCT training programmes should involve a DMF radiologist.
19. For dento-alveolar CBCT images of the teeth, their supporting structures, the mandible and the maxilla up to the floor of the nose (for example, 8 cm x 8 cm or smaller fields of view), clinical evaluation (radiological report) should be done by a specially trained DMF radiologist or, where this is impracticable, an adequately trained general dental practitioner.
20. For non-dento-alveolar small fields of view (for example, temporal bone) and all craniofacial CBCT images (fields of view extending beyond the teeth, their supporting structures, the mandible, including the TMJ, and the maxilla up to the floor of the nose), clinical evaluation (radiological report) should be done by a specially trained DMF radiologist or by a clinical radiologist (medical radiologist).

### Conclusion

CBCT is most frequently applied in oral and maxillofacial surgery, endodontics, implant dentistry and orthodontics. CBCT examination must not be carried out unless its medical necessity is proven and the benefits outweigh the risks.

Furthermore, CBCT images must undergo a thorough clinical evaluation (radiological report) of the entire image dataset in order to maximise the benefits. Future research should focus on accurate data with regard to the radiation dose of these units. CBCT units have small detector sizes and the field of view and scanned volumes are limited, which is the reason that CBCT units specific to orthodontic and orthognathic surgery are not yet available. Additional publications on CBCT indications in forensic dentistry and prosthodontics are also desirable.

### About the authors

**Dr Mohammed A. Alshehri** is a Consultant for Restorative and Implant Dentistry at the Riyadh Military Hospital, Department of Dentistry and Assistant Clinical Professor at the King Saud University, College of Dentistry, Department of Restorative Dental Sciences. He can be contacted at dr\_mzs@hotmail.com.

**Dr Hadi M. Alamri** and **Dr Mazen A. Alshalhoob** are interns at Riyadh Colleges of Dentistry and Pharmacy.

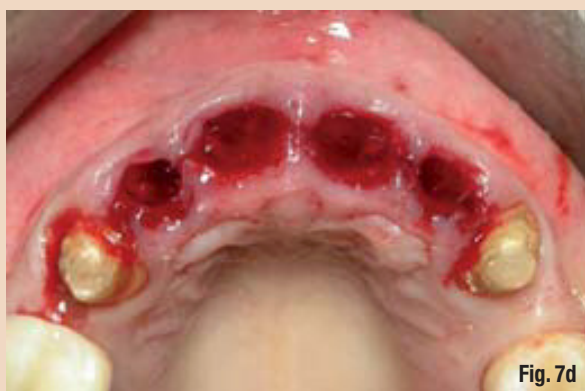

Fig. 7d

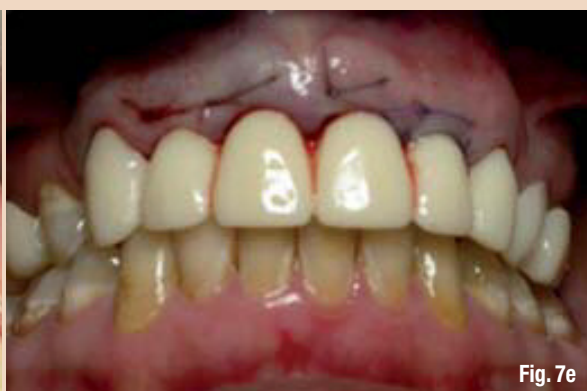

Fig. 7e

Fig. 7d Extractions done for teeth

#7, 8, 9 and 10 were atraumatic and bone grafting was performed.

Fig. 7e Temporisation done and healing of the grafted sites for future implant placement is awaited.



# Removal of a fractured instrument: Two case reports

Author: Dr Rafaël Michiels, Belgium

Fractured instruments pose a challenge to every endodontist. The difficulty in the retrieval of these instruments ranges from surprisingly easy to downright impossible. The clinical outcome of cases with fractured instruments depends on several factors, such as the position of the instrument in the canal, the type of material, the instrument size and canal anatomy.<sup>1</sup> Failure in retrieval of the fractured instrument does not automatically result in failure of the case.<sup>2</sup> One can still try to bypass the instrument, choose a surgical approach, or even wait and see. However, if we bear 'nothing ventured, nothing gained' in mind, then we should always at least try to retrieve the fractured instrument.

## Case I

A 27-year-old female patient was referred to our practice. She was in good health and had an American Society of Anesthesiologists (ASA) score of 1. The patient had some mild clinical symptoms on tooth #30 due to apical periodontitis. She had been told, by the referring dentist, that there was a fractured instrument in her tooth and that the instrument had to be removed first in order to allow for decent retreatment.

Before starting with the treatment, a new diagnostic radiograph was taken. In this case, the diagnostic radiograph (Fig. 1) showed not one but two broken instruments in the mesial root, one in each mesial canal. Thereafter, the tooth was isolated with the rubber dam and the coronal filling was removed. Straight-line access was established, as this is imperative in order to be able to reach and see the fractured instruments. Gates-Glidden burs (DENTSPLY Maillefer) were used to enlarge the mesial orifices coronally.

Diagnostic radiograph (Fig. 1) showed not one but two broken instruments in the mesial root, one in each mesial canal. Thereafter, the tooth was isolated with the rubber dam and the coronal filling was removed. Straight-line access was established, as this is imperative in order to be able to reach and see the fractured instruments. Gates-Glidden burs (DENTSPLY Maillefer) were used to enlarge the mesial orifices coronally.

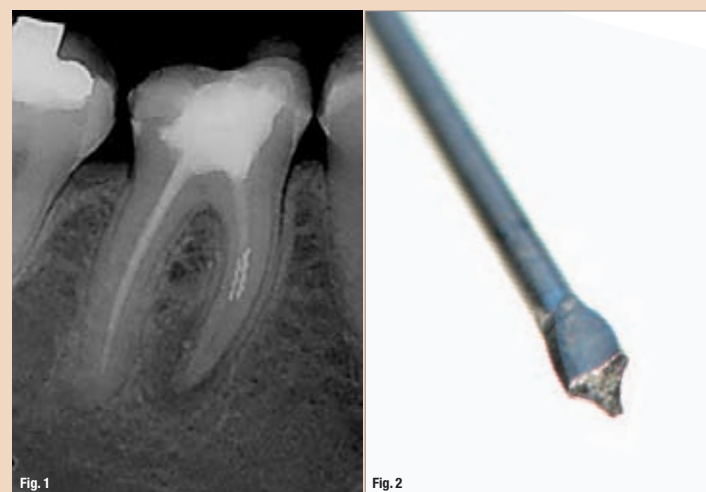One-and-a-half hours after starting the treatment, the fragment had been loosened but was still stuck in the canal. We decided to leave it in place for the time being and made a new appointment. Calcium hydroxide paste (UltraCal XS, Ultradent) was put into the coronal part of the mesial canals and the tooth was sealed with glass-ionomer

ce-ment (Fuji IX GP Fast, GC) and a cotton pellet.

During the next visit, the tooth was again isolated and opened. The calcium hydroxide paste was removed, using 10 % AD

Fig. 1 Diagnostic radiograph, showing two separated instruments in the mesial root.

Fig. 2 A modified Gates-Glidden bur used for creating a plateau above the instrument.



**DUBAI  
2011**

**1-3  
February**

Dubai International  
Convention &  
Exhibition Centre

Supported by



[www.aeddc.com](http://www.aeddc.com)

Organised by



Strategic Partner



Supported by



**INDEX® Conferences & Exhibitions Organisation Est.**

P.O. Box: 13636 | Ibn Sina Bldg. #27 Block B, Office 203, Dubai Healthcare City | Dubai - United Arab Emirates  
Tel: +971 4 3624717 | Fax: +971 4 3624718 | E-mail: [aeedc@index.ae](mailto:aeedc@index.ae) | Website: [www.index.ae](http://www.index.ae)

**“Delivering Science & Technology”**

*15<sup>th</sup> Anniversary*

**UAE INTERNATIONAL  
DENTAL CONFERENCE &  
ARAB DENTAL EXHIBITION**

**“Where Oral Health Professionals Meet”**

- Keep up to date with the newest developments and techniques in dentistry through a series of lectures and specialized courses
- Enhance your dental practice with various management and clinical workshops
- Learn the optimal prevention and treatment services in the field of dental traumatology
- Visit 20,000 sqm. of exhibition space and explore the latest innovations and business practices
- Enjoy a panoramic view from Burj Khalifa, the world's tallest tower
- Ride the Metro and see Dubai !