

IMPLANT TRIBUNE

The World's Dental Implant Newspaper · U.S. Edition

MARCH 2010

www.implant-tribune.com

VOL. 5, No. 3



Dental industry's future
Implants and bone graft
market to top \$4.5B by 2012

▶Page 2



ICOI event: learning & jazz
New Orleans is the site
of the next spring symposium

▶Page 13



New products
Astra Tech launches
OsseoSpeed TX line at AO

▶Page 14

Scenes from the AO's annual meeting



Zimmer Dental is celebrating the 10th anniversary of its Tapered Screw-Vent Implant System. Featured at AO, more than 2 million units have been sold. (Photo/Humberto Estrada, DTA)

The Academy of Osseointegration's annual meeting took place from March 4-6 in Orlando. To catch a glimpse of the many exhibitors who showcased innovative implant technology at the event, turn to Page 12B.

AD

Dental Collab BETA
FINALLY A SOLUTION FOR GETTING
THAT SECOND OPINION.
WWW.DENTALCOLLAB.COM

FIRST MONTH
FREE
CODE: ITDC09



Esthetic management of a single dental implant in the esthetic zone

By Michael Sonick, DMD

A medically and periodontally stable 37-year-old man presented with coronally fractured tooth #9, which had a history of endodontic treatment (Figs. 1a, 1b). The tooth was deemed restoratively hopeless.

Treatment plan

1. Extraction of tooth #9 and socket preservation
2. Three-month healing period
3. Placement of implant #9 and connective tissue graft
4. Three-month healing period
5. Implant #9 exposure, placement of healing abutment and connective tissue graft
6. Three-month healing period
6. Final implant #9 crown restoration

Extraction and socket preservation of tooth #9

After oral sedation with 0.25 mg triazolam one hour prior to surgery and local anesthetic induction using 2 percent lidocaine with 1:100,000 epinephrine and 0.5 percent bupivacaine with 1:200,000 epinephrine, a sulcular incision was made circumferentially around tooth #9. The remaining root was extracted atraumatically using a piezoelectric periotome device (Fig. 2).

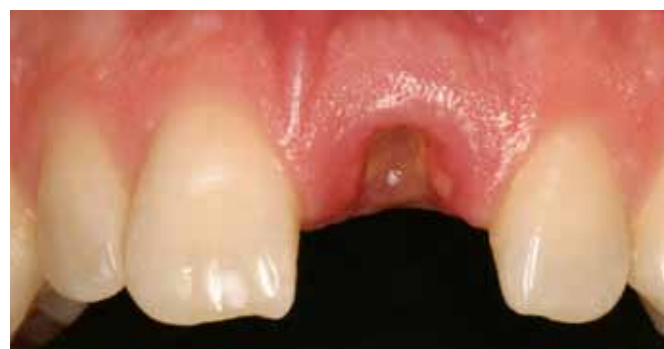
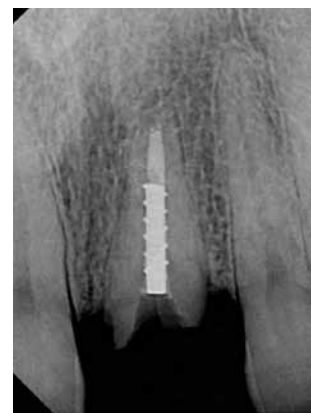
Fig. 1a, left: Hopelessly fractured tooth #9.

Fig. 1b, below: Periapical radiograph of endodontically treated tooth #9

Thorough degranulation of the extraction site with a pear-shaped carbide finishing bur and Prichard curette proceeded. No dehiscence or fenestration was detected. Freeze-dried bone allograft (FDBA) was used to obliterate the extraction socket.

A bioabsorbable collagen plug (CollaPlug®, Zimmer Dental, Carlsbad, Calif.) was used to cover the graft. The area was secured using 4-0 expanded polytetrafluoroethylene (ePTFE) suture (Fig. 3). The restorative dentist temporized space #9 with an interim removable partial



(Clinical photos/Provided by Dr. Michael Sonick)

→ IT page 4B

AD

AUXILIARIES: Are you implant certified?

Patient Questions... Insurance Coverage... Tracking...
Operatory Set Up... Radiographic Protocol...
Assessment Parameters... Hygiene Instrumentation...
Communications with the Lab...

Implant Training Makes all the Difference!



Dental Hygiene Implant Certification Program® (DHICP) • Practice Management Implant Certification Program® (PMICP)

Dental Assisting Implant Certification Program® (DAICP) • Implant Coordinator Training Program®

The ADIA presents these comprehensive courses at many venues throughout the year.



To find out more about these exciting programs and about membership in the ADIA visit our website:

www.adiaonline.org

World dental implant and bone graft market to top \$4.5B by 2012

Global sales of dental implant systems, fast becoming the preferred restoration for replacement of missing or extracted teeth or as supports for dentures, crowns and bridges, are expected to maintain double-digit growth during the next five years, soaring to more than \$4.5 billion, according to "Implant-Based Dental Reconstruction: The Worldwide Dental Implant and Bone Graft Market," second edition, a new study released from Kalorama Information.

Sales of dental implants and abutments rose more than 15 percent in 2006 alone reaching nearly \$2 billion, led by Europe, where the popularity of implants saw sales peaking at \$760 million or 42 percent of the global market.

Advanced bone grafting and regeneration techniques have radically expanded the possibilities for implant-based restorative dentistry. World sales of dental bone grafts reached \$150 million in 2006, up 12 percent from 2005.

The report projects the use of bone grafts will more than double by 2012 with revenues reaching \$266 million.

Grafting techniques are making

'... the future of BMP and increased use of grafts and implants looks very promising.'

it possible to expand the candidate pool for implants to include a sizable population of edentulous patients who were poor candidates for dental implantation due to severe bone resorption.

"The most closely watched research and development projects in dental bone grafting today involve bone morphogenetic protein (BMP) products," noted Anne Ansbomb, the report's author.

"BMPs have the potential to transform the bone grafting market and surpass all other products on the market including synthetic substitutes, allografts, and demineralized bone matrices. With the announcement in March that the FDA approved Medtronic's InFuse Bone Graft for certain oral maxillofacial and dental regenerative bone grafting procedures, the future of

BMP and increased use of grafts and implants looks very promising."

Implant-based dental reconstruction includes revenue forecasts for each segment through 2016, global market share for four geographic regions, more than 35 tables and figures with detailed market data, reviews of new products, and computer-aided dentistry and reimbursement trends.

It can be purchased directly from Kalorama Information by visiting www.kaloramainformation.com/Implant-Based-Dental-1399457. It is also available at MarketResearch.com. ■

CK Dental Industries
Phone: (800) 675-2537
Fax: (800) 634-1788
www.ckdental.net

Cadent iTero added to curriculum at LVI

Cadent, a leading provider of 3-D digital and CAD/CAM solutions, recently announced it has signed an agreement with the Las Vegas Institute for Advanced Dental Studies (LVI), one of the world's premier post-graduate dental training facilities, whereby the iTero digital impression system will become the exclusive digital impression technology integrated into LVI's curriculum.

LVI students who attend Core II (orthotic maintenance, adjustment and essential esthetic reconstructive techniques) and Core III (mastering dynamic adhesion in complex reconstructive cases) will be exposed to the iTero system.

Core V (comprehensive esthetic occlusal reconstruction) and Core VII (full-mouth reconstruction — essential tools for finalization of neuromuscular rehabilitation) programs will have the opportunity to utilize iTero in the restorative process. iTero clinical trainers will be onsite during

the programs to provide training and hands-on support for LVI students to obtain live case experience working with the iTero system.

Along with Cadent, the LVI partner laboratories (The Aurum Group, DTI MicroDental, Las Vegas Esthetics and Williams Dental Lab) will provide the comprehensive prosthetic case development from the iTero digital impressions.

"The integration of iTero into the LVI curriculum supports our expanding network of educational opportunities for new and existing iTero dentists," said Timothy Mack, president and chief executive officer of Cadent. "Cadent recently completed its 2 millionth 3-D digital case for restorative dentists and orthodontists, a record of proven success which is required even to earn recognition by the faculty at the LVI.

"We are especially pleased that iTero has been deemed worthy of a partnership with LVI, a world-class

organization that provides dentists with the continuing education needed to further develop their restorative dentistry practice."

"The inclusion of the iTero digital impression system supports LVI's ongoing efforts to integrate the best of dentistry's technological advances into the LVI curriculum," said William G. Dickerson, DDS, founder and chief executive officer of LVI. "The era of digital dentistry has arrived and the addition of iTero to our programs will enable LVI students to become proficient in the industry's most successful digital impression system."

iTero serves more than 1,700 dentists in 12 countries, and is the only digital impression technology that does not require powdering or coating of the teeth, enabling the processing of more complex cases than any other system. ■

(Source: Cadent)

IMPLANT TRIBUNE

The World's Newspaper of Implantology · U.S. Edition

Publisher & Chairman

Torsten Oemus
t.oemus@dental-tribune.com

Vice President Global Sales

Peter Witteczek
p.witteczek@dental-tribune.com

Chief Operating Officer

Eric Seid
e.seid@dental-tribune.com

Group Editor & Designer

Robin Goodman
r.goodman@dental-tribune.com

Editor in Chief

Sascha A. Jovanovic, DDS, MS
sascha@jovanoviconline.com

Managing Editor/Designer

Sierra Rendon
s.rendon@dental-tribune.com

Managing Editor/Designer

Ortho Tribune & Show Dailies
Kristine Colker
k.colker@dental-tribune.com

Online Editor

Fred Michmershuizen
f.michmershuizen@dental-tribune.com

Account Manager

Humberto Estrada
h.estrada@dental-tribune.com

Marketing Manager

Anna Wlodarczyk
a.wlodarczyk@dental-tribune.com

Marketing & Sales Assistant

Lorrie Young
l.young@dental-tribune.com

C.E. Manager

Julia Wehkamp
j.wehkamp@dental-tribune.com

Dental Tribune America, LLC
213 West 35th Street, Suite 801
New York, NY 10001
Phone: (212) 244-7181, Fax: (212) 244-7185



Published by
Dental Tribune America

© 2010, Dental Tribune America, LLC.
All rights reserved.

Dental Tribune makes every effort to report clinical information and manufacturer's product news accurately, but cannot assume responsibility for the validity of product claims, or for typographical errors. The publishers also do not assume responsibility for product names or claims, or statements made by advertisers. Opinions expressed by authors are their own and may not reflect those of Dental Tribune International.

Editorial Advisory Board

Dr. Sascha Jovanovic, Editor in Chief

Dr. Bernard Touati

Dr. Jack T. Krauser

Dr. Andre Saadoun

Dr. Gary Henkel

Dr. Doug Deporter

Dr. Michael Norton

Dr. Ken Serota

Dr. Axel Zoellner

Dr. Glen Liddelow

Dr. Marius Steigmann

**Tell us
what
you
think!**

Do you have general comments or criticism you would like to share? Is there a particular topic you would like to see more articles about? Let us know by e-mailing us at feedback@dental-tribune.com. If you would like to make any change to your subscription (name, address or to opt out) please send us an e-mail at database@dental-tribune.com and be sure to include which publication you are referring to. Also, please note that subscription changes can take up to 6 weeks to process.

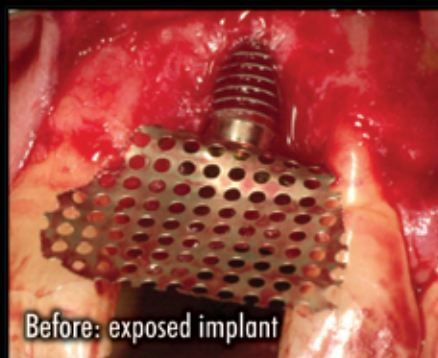
II Corrections

Implant Tribune strives to maintain the utmost accuracy in its news and clinical reports. If you find a factual error or content that requires clarification, please report the details to Managing Editor Sierra Rendon at s.rendon@dental-tribune.com.

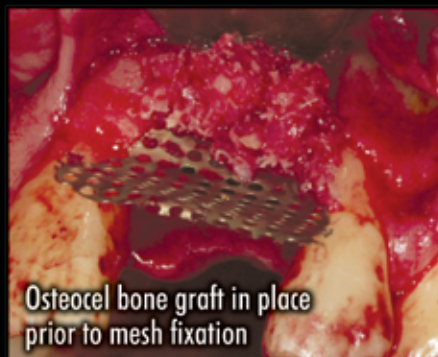Osteocel[®]

The Cellular Advantage.

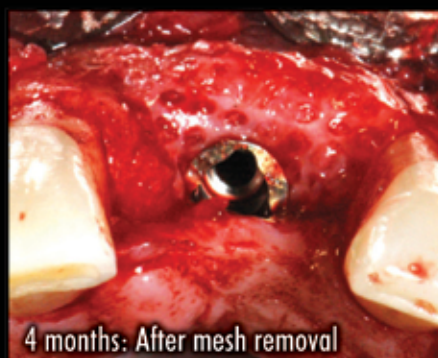For more information or to place an order call **800.441.3100**



Before: exposed implant



Osteocel bone graft in place prior to mesh fixation



4 months: After mesh removal

Ridge Augmentation clinical case.

A Bone Matrix Product Containing Stem Cells.

The Properties of Autograft without Associated Risks

The proprietary processing technology that produces Osteocel[®] results in a viable bone matrix product that preserves the native stem cells found in marrow rich bone. It is the only product available today that has the desired beneficial properties of autograft - osteoconduction, osteoinduction and osteogenesis — and that allows surgeons to provide their patients with optimal bone growth conditions without the added risk and cost of a secondary procedure.

Low Immunogenicity

Mesenchymal stem cells are IMMUNE-PRIVILEGED cells that do not stimulate a cellular immune response. Osteocel does not activate T cell proliferation, as shown *in vitro* from Mixed Lymphocyte Reaction (MLR) testing.

Histologic Evidence

Positive clinical use of Osteocel since 2005 demonstrates bone-forming ability. Histology from a human sinus augmentation study using Osteocel shows substantial vital bone content at 16 weeks, with very low residual graft material.¹

Bone Formation

Stem cells contained in Osteocel are capable of differentiating into bone cells. Every lot of Osteocel is tested for bone forming potential.

Viable Cell Content

The osteogenic potential arises from the stem cells in Osteocel. Following processing of marrow-rich bone, release testing demonstrates osteogenic potential according to the following criteria:

- Rich supply of stem cells: Greater than 50,000 cells/cc
- Viability: Greater than 70% cell viability
- Positive osteogenesis: In vitro cell culture assay

¹ Histologic Evaluation of a Stem Cell Based Sinus Augmentation Procedure: A Case Series. — McAllister, Haghghat, Gonshor. — Journal of Perio., April 2009

← **IT** page 1B

denture.

After three months of uneventful healing (Fig. 4), Stage 1 implant placement was initiated.

#9 fixture placement and connective tissue graft

After oral sedation with 0.25 mg triazolam and local anesthetic induction using 2 percent lidocaine with 1:100,000 epinephrine and 0.5 percent bupivacaine with 1:200,000 epinephrine, a flap was created using a trapezoidal papilla-sparing incision design that involved a palatally oriented crestal incision over the #9 site with two vertical releasing incisions made on the buccal, both avoiding the mesial and distal papillae.

A full-thickness flap was raised past the mucogingival junction. Degranulation of the site with a pear-shaped carbide finishing bur and Neumeier bur revealed adequate apico-coronal, bucco-lingual and mesio-distal dimensions for implant placement.

After osteotomy preparation, a rough-surfaced, internal hex 4 mm (diameter) by 13 mm (length) implant was placed into the filled site (NanoTite® Parallel Walled Certain® Implant, BIOMET 3i, Palm Beach Gardens, Fla.) (Fig. 5).

Primary stability was achieved, and a cover screw was placed.

In order to form an esthetic soft-tissue profile by expanding mucosal dimensions, a connective tissue graft was harvested from the palate and placed on the buccal aspect of

the ridge overlying the implant. The graft was stabilized using 5-0 chromic gut sutures (Fig. 6).

After periosteal release via lateral scalpel incisions, the flap was primarily closed with 4-0 ePTFE sutures in an interrupted and horizontal mattress fashion (Fig. 7). The area was re-temporized with a resin-bonded fixed partial denture.

Implant exposure with connective tissue graft

The #9 site healed well and without incident after three months (Fig. 8). After using a tissue punch technique to remove the mucosa immediately coronal to the fixture (Fig. 9), a one-piece 4.1 mm (platform) by 5 mm (emergence profile) by 4 mm

→ **IT** page 7B

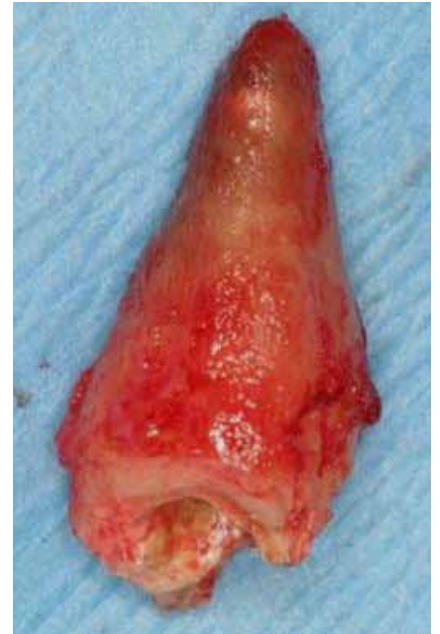

Fig. 2: Atraumatically extracted #9 tooth.

AD



KAT Implants™

Implant strength you can rely on

Price you can afford

- ✔ Single platform for mini, small, standard and wide diameter implants – any abutment will fit all implants
- ✔ Restore mini implants without a "lollipop" effect and cement contamination
- ✔ Mini implants are FDA approved for transitional and long-term applications
- ✔ Strength of the one-piece implant with versatility of two-piece implants
- ✔ Torque-activated screwless locking taper connection for accurate force calibration
- ✔ Precise tri-lobe abutment positioning without any rotational play
- ✔ Ultimate accuracy of the Pick-Up Abutment™ implant indexing method
- ✔ Implant length as short as 6.0mm
- ✔ 3.5mm implants may be used in the molar area due to high implant strength (425N)
- ✔ Healing Abutment Level Temporization™ (HALT™) for healthy soft tissue



www.katimplants.com




1-877-KAT-SYSTEM (877-528-7978)

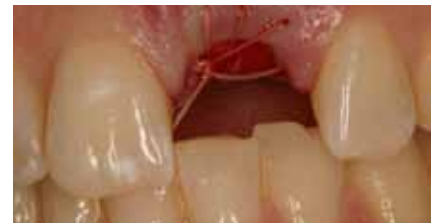

Fig. 3a: Buccal view of socket preservation site.

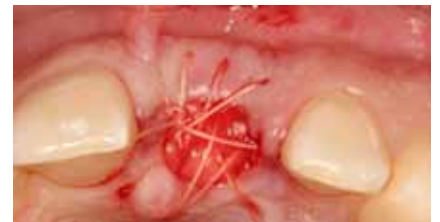

Fig. 3b: Occlusal view of socket preservation site.

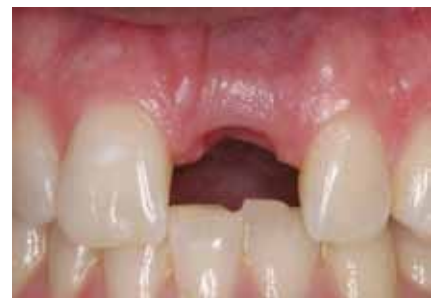

Fig. 4: Healing three months post-extraction and socket preservation.

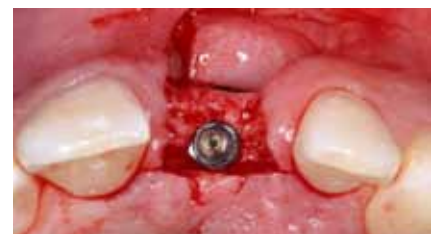

Fig. 5a: Occlusal view of implant placement. Note palatal placement of fixture.

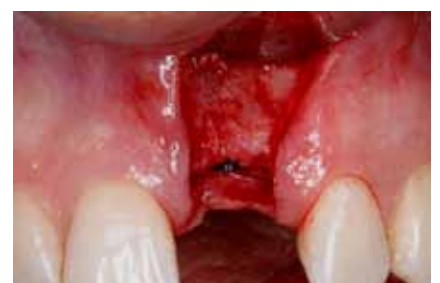

Fig. 5b: Buccal view of implant placement. Note papilla-sparing flap design.



AMD LASERS™

The Fine Art of Laser Dentistry

The Experts Agree

Picasso is #1

"I tried many different lasers during my implant seminars. Picasso is by far the **best value** and **best quality** diode laser on the market today"



Dr. Arun K. Garg
International Lecturer
Implant Dentistry



Picasso

7.0 Watts
8 Custom Presets
3-Year Warranty
\$4995



Picasso Lite

2.5 Watts
3 Custom Presets
2-Year Warranty
\$2495

Thousands of Dental Practitioners Agree



"After evaluating several popular diodes, the decision to purchase a Picasso was a no-brainer. The Picasso offers the **best performance, price,** and **warranty** while enhancing my ability to place implants."

Benjamin Jump D.D.S.
Neighborhood Dentist
Newark, Ohio

Special Offer

- FREE 6 CE Credits
- FREE *Everything is Marketing* by Fred Joyals, CEO 1-800-DENTIST
- FREE Cetacaine® Topical Anesthetic
- \$1500 Gift Certificate from Fortune Management
- \$250 Off Orascoptic® Laser Loupes



AMD LASERS™
Effective. Practical. Affordable. World Class Lasers.

7405 Westfield Blvd.
Indianapolis, IN 46240

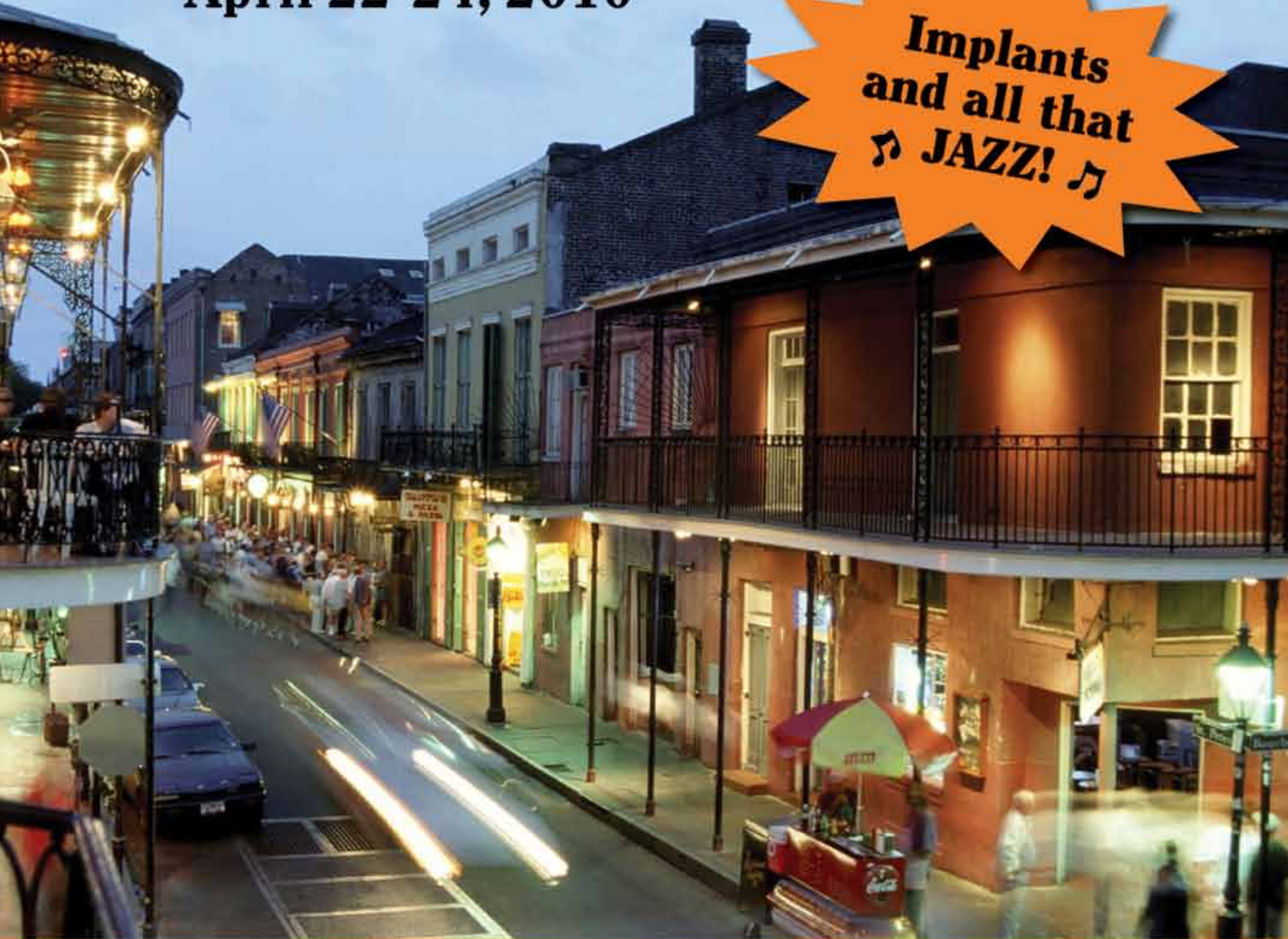

1-866-999-2635
www.amdlasers.com
Product Videos

NEW ORLEANS

April 22-24, 2010

Implants
and all that
♪ JAZZ! ♪



ICOI Spring Symposium and 13th IPS Symposium *New Orleans Marriott on Canal Street*

For more information please contact the ICOI Central Office
at (973) 783-6300 or visit our website at www.icoi.org

Sponsored by:

ADA CERP® | Continuing Education
Recognition Program

AGD - Accepted Program Provider
FAGD/MAGD Credit, 5/1/09 - 6/30/12

Photo Credit: Richard Nowitz

ICOI is an ADA CERP Recognized Provider. ADA CERP is a service of the American Dental Association to assist dental professionals in identifying quality providers of continuing dental education. ADA CERP does not approve or endorse individual courses or instructors, nor does it imply acceptance of credit hours by boards of dentistry. ICOI designates this activity for **23 continuing education credits**.



ADIA

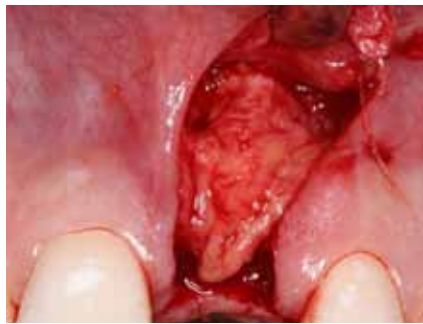

Fig. 6: Connective tissue graft secured in place over the buccal ridge.

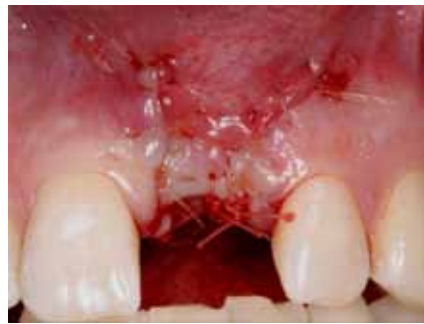

Fig. 7: Primary closure of grafted implant site.

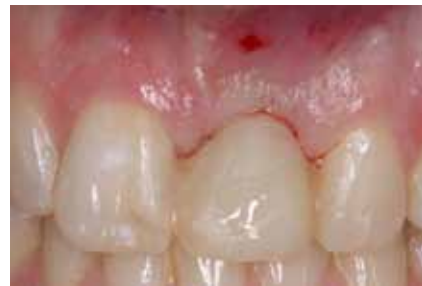

Fig. 8: Healing three months post-implant placement. Note the favorable position of the mucosal margin.

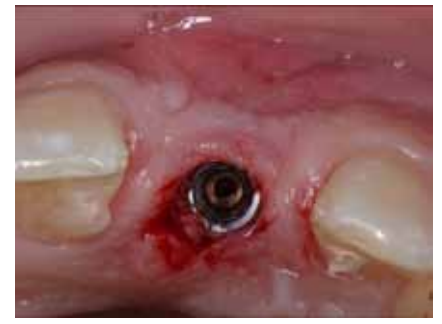

Fig. 9: Exposure of the #9 implant using a tissue-punch technique.

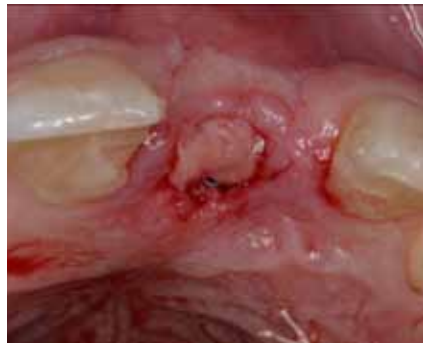

Fig. 10a: Soft-tissue graft inserted into the buccal pouch.

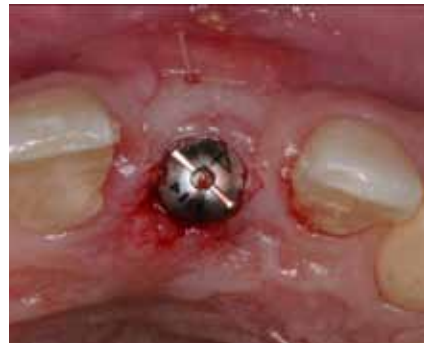

Fig. 10b: Placement of the healing abutment on the #9 implant.

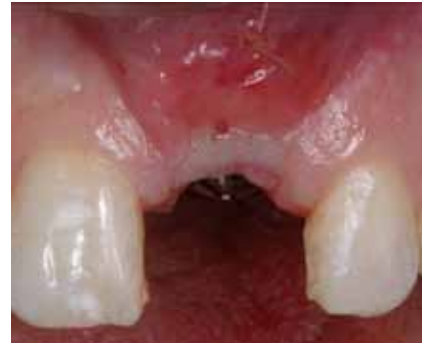

Fig. 10c: Buccal view of site with graft in place.

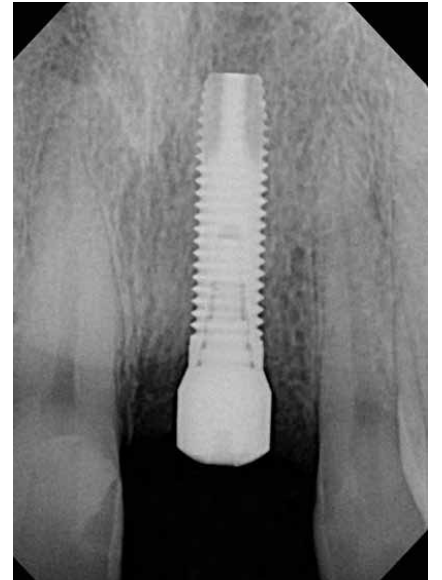


Fig. 11: Periapical radiograph of fracture at time of exposure. Note the favorable bone height.

← **ii** page 6B

(height) healing abutment (Certain® EP® Healing Abutment, BIOMET 3i, Palm Beach Gardens, Fla.) was placed on the #9 implant.

To further augment the buccal ridge dimension, another connective tissue graft was harvested from the palate.

A pouch-like envelope flap was raised over the labial ridge aspect into which the connective tissue was transplanted and fixed using 5-0 chromic gut suture (Fig. 10). The healing abutment remained exposed.

A periapical radiograph revealed sufficient bone height around the

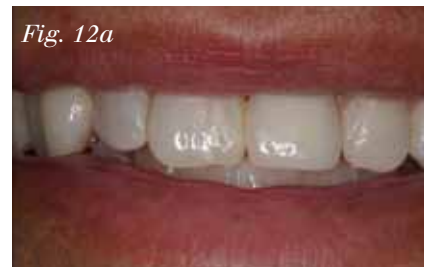

Fig. 12a

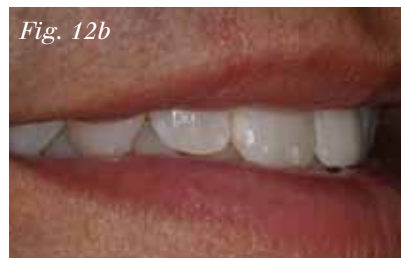

Fig. 12b

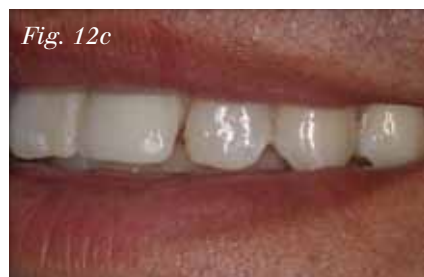

Fig. 12c

Figs. 12a–12c: View of final restoration

→ **ii** page 10B

AD

AD

Dental Collab BETA
 FINALLY A SOLUTION FOR MENTORING WITH EXPERTS & PEERS.
WWW.DENTALCOLLAB.COM

FIRST MONTH FREE
 CODE: ITDC09

IT'S NEW

Send us your case study!

Have an interesting implant case you would like to share with 15,000 of your peers? To have your case study considered for publication in Implant Tribune, send your 800- to 1,200-word case study and up to 12 high-resolution photos to Managing Editor Sierra Rendon at s.rendon@dental-tribune.com. Authors will be notified of publication and have an opportunity to review the designed case study prior to final publication. Cases will be published pending editor approval and space availability.

ATLAS®
 Denture Comfort

It fits where others cannot.
NOW it's available where others are not.

We are pleased to announce that our Atlas® Narrow-Body Implants will be distributed exclusively through Henry Schein Dental. The new benefits of far reaching distribution and support will undoubtedly be of great value to our customers.

Millions of edentulous patients have been neglected as implant candidates because they lack adequate bone structure, are unable to undergo lengthy procedures or have financial constraints.

Atlas has solved these problems.

- Available in 1.8, 2.2 & 2.4mm diameters
- 1 Hour, minimally invasive chairside procedure
- No O-rings, housings or adhesives
- Fewer components
- Fewer post-op visits
- More affordable

For additional course dates, locations and fees, contact us at 877-537-8862 Or see our brochure on line www.dentatus.com

Available exclusively through:
HENRY SCHEIN®
 DENTAL

WORKSHOP SCHEDULE

Apr 9	Chicago, IL
Apr 16	New York, NY
May 14	Pittsburgh, PA
May 14	Albany, NY
May 21	Orlando, FL
Jun 4	Louisville, KY
Jun 18	Los Angeles, CA
Jun 25	Bay Area, CA
July 23	Portland, OR
July 30	Kansas City, KS

Dentatus
www.dentatus.com

TO LEARN MORE ABOUT ATLAS, VISIT US AT ICOI BOOTH #316

©2010 DENTATUS USA, LTD. PATENTS PENDING



Implant Direct™

simply smarter.

Taking Mini-Implants to a New Dimension

Application Specific Implants with All-in-One Packaging

Narrow One- and Two-Piece Implants



3.2mmD

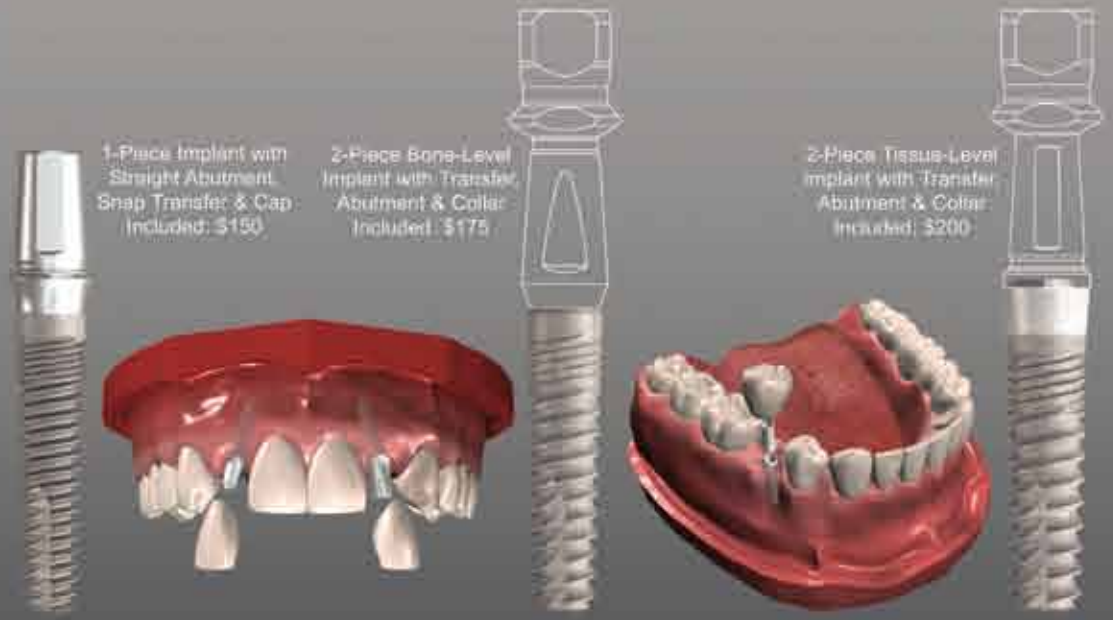
1.8mmD

Legacy™ 3

3.0mmD
ScrewDirect

3.2mmD
Legacy3

3.3mmD
SwissPlant



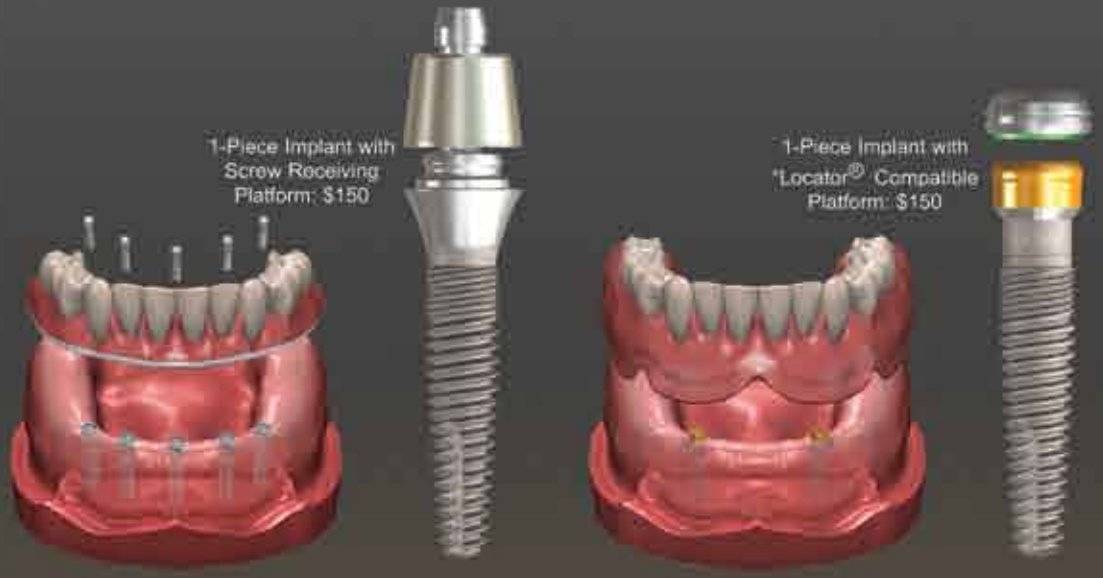
1-Piece Implant with Straight Abutment, Snap Transfer & Cap Included: \$150

2-Piece Bone-Level Implant with Transfer Abutment & Collar Included: \$175

2-Piece Tissue-Level Implant with Transfer Abutment & Collar Included: \$200

3.0mmD
ScrewIndirect

3.0mmD
GoDirect



1-Piece Implant with Screw Receiving Platform: \$150

1-Piece Implant with Locator® Compatible Platform: \$150

Mini-Implant and Teeth-in-1Day™ Hands-On Surgical and Prosthetic Training

Friday March 12th, Los Angeles, CA

Friday April 9th, Los Angeles, CA

Saturday April 17th, San Francisco, CA

Friday May 21st, Los Angeles, CA

Sunday May 23rd, Newport Beach, CA

Saturday June 5th, Las Vegas, NV

8 CE Credits for all attending: \$ 295.00

Approved PACE Program Provider FAGD/MAGD Credit Approval does not imply acceptance by a state or provincial board of dentistry or AGD endorsement. 08/01/2009 to 07/31/2012



Register on-line www.implantdirect.com

Locator® is a registered trademark of Zest Anchor Company

Nobel Biocare Customers

Why use ****NobelActive with an Internal Hex (Niznick 1990 Pat. #4,960,381)** when you can use **ReActive™ Tri-lobe Implants Save 65-70%**

Implant Direct Int'l
 8840 W. Russell Road #210,
 Las Vegas, NV 89148
 Manufacturing/Sales: 1-818-444-3333
www.implantdirect.com

Surgically and/or Prosthetically Compatible Implants

Select Type of Threads and Abutment

- RePlant with Temporary Titanium Abutment
- RePlus with Straight "Snappy" Abutment
- ReActive with Straight Preparable Abutment

RePlant® Body Dimensions: Matches Replace[®]
RePlus® Body Taper: For Bone Expansion
ReActive™ Body Threads: For Increased Surface



RePlant implant surgically compatible with Nobel Replace[®] Drills
 Nobel Replace[®] is a registered Trademark of Nobel Biocare
 **Nobel Active[®] is a registered Trademark of Nobel Biocare

ReActive™ Tri-Lobe Implant

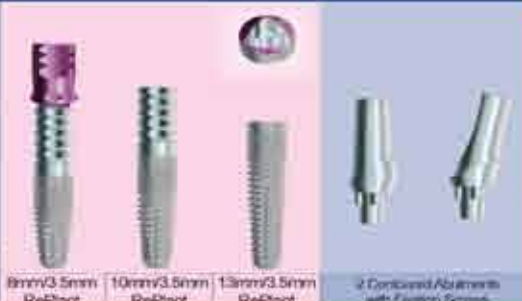- Platform Shifting, Micro-threads, Deeper Threads, Round Apex
- All-in-one Packaging: Cover Screw, Transfer & Straight Abutment
- ReActive USA price = \$200
- NobelActive USA price = \$656



Free Implants for Nobel Biocare Customers

3 Surgically Compatible, RePlant[®] Implants with Titanium Transfer/Temporary Abutments plus 2 Contoured Abutments

US List Price for 3 Implants, Abutments and Prosthetic Components:
RePlant = \$620
NobelBioCare = \$1907



Compare US List Price	Straight Contoured	15° Angled Contoured	Straight Snap-On	Gold w/o Tri-Lobe	Gold with Tri-Lobe	Temporary Abutment	Ball Attachment	Locator Abutment	Screw Receiving	30° Screw Receiving
Implant Direct	\$85	\$85	\$85	\$100	\$100	\$35	\$107	\$110	\$85	\$100
Nobel Biocare	\$170	\$225	\$201	\$216	\$216	\$72	\$217	\$110	\$229	\$269
Cost Savings	50%	62%	58%	54%	54%	51%	51%	0%	63%	63%

List prices as of 2/23/09

FREE Introductory Offers at
www.implantdirect.com
 Terms and Conditions Apply