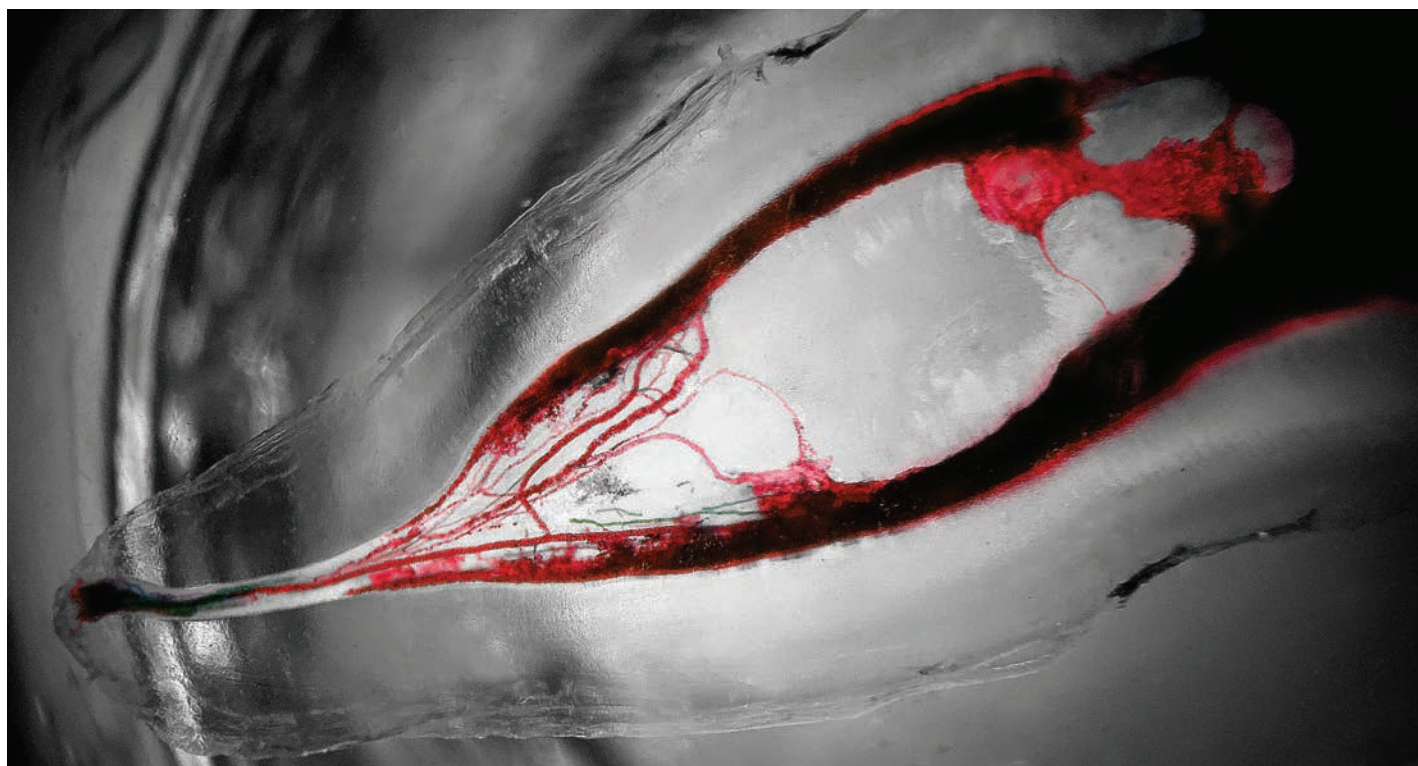


roots

the international C.E. magazine of endodontics

1 2018



C.E. article

The dental operating microscope

tribute

Remembering Fred Weinstein

research

Bioceramic materials in apical resorption



THE SAME EFFICIENCY, SUPERIOR HANDLING

Endodontics

MTA Repair HP

Bioceramic high-plasticity reparative cement

No staining

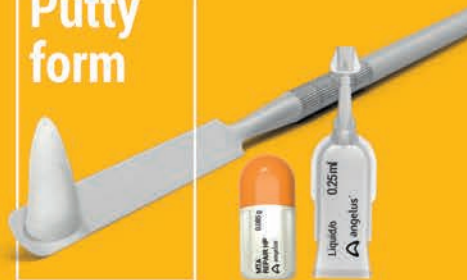

With the new Bioceramic formula, MTA Repair HP keeps all the beneficial properties of the original MTA Angelus, with more than 15 years of proven results, enhancing its handling ability in a friendly putty-form version.

- Putty-form: for easy insertion
- No-staining: totally aesthetic results
- 15 minutes set time: single-visit treatment
- Hydrophilic: adaptable to humid conditions
- 3 years shelf-life: guaranteed
- Exclusive capsules and vials



Putty form



Standard Package (Ref. 8469)
Contains: 10 of each: 0.085 Gm. capsules of powder and 0.25 mL capsules of liquid.



Special offer Buy MTA Repair HP

Ref. 8469

Get 1 MTA-Fillapex

Ref. 827 syringe at no cost.
Shipped with order.



Remembering Dr. Fred Weinstein



Fred Michmershuizen,
Managing Editor

He was wearing a Royal Canadian Mounted Police uniform the first time I met him. It was 2007, and I had just started a new job as an editor with Dental Tribune, covering the specialty of endodontics. With his red blazer, hat and tall boots he looked genuine — and approachable. I just had to talk with him. After all, how often does one get a chance to meet a Mountie?

He turned out to be none other than Dr. Fred Weinstein, and he was dressed up to promote the IFEA meeting, which was being held that year in his hometown of Vancouver, British Columbia. Over the next decade I got to know him quite well. He was always generous with his time, and he was always helpful to me, a non-dentist, with information on the specialty and also about key personalities, tools and equipment, and the industry in general.

Weinstein had already retired after a long and successful career in private practice and as an educator and product innovator, but in 2012 he agreed to serve as editor in chief of *roots* magazine. Over the years we not only worked together on the publication, but we also became friends. We would often meet up at various dental meetings, where I was busy on the exhibit hall floor taking pictures for our show daily. He would be there to partake in the various educational sessions and to visit with his many friends. It seemed he knew almost everybody.

The last time we were together was at last year's AAE in New Orleans. Weinstein and his wife, Heather, and I met up before the meeting got underway for dinner and a stroll in the French Quarter. At this year's AAE gathering in Denver, Weinstein, who passed away last October, will be missed. I sure will miss him. Turn to page 11 of this issue of *roots* for a tribute to Weinstein in which a number of prominent endodontists share their fond memories.

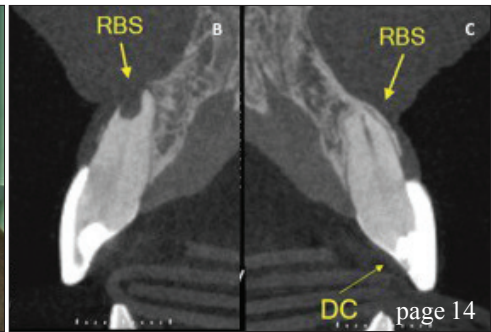
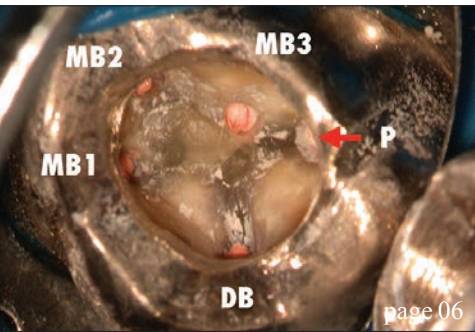
The centerpiece of this publication, however, is an article by Dr. Frank C. Setzer, "The dental operating microscope in endodontics," which originally appeared in AAE's ENDODONTICS: Colleagues for Excellence newsletter. The article is being made available in this issue of *roots* with the permission of the AAE. By reading this article, and then taking a short online quiz at www.DTStudyClub.com, you will gain one ADA CERP-certified C.E. credit.

You can also access the vast library of C.E. articles published in the AAE's clinical newsletter by visiting www.aae.org/colleagues.

I can imagine that taking time away from your practice to pursue C.E. credits is costly in terms of lost revenue and time, and that is another reason *roots* is such a valuable publication. I hope you will enjoy this issue and that you will take advantage of the C.E. opportunity.

Sincerely,

Fred Michmershuizen, Managing Editor
f.michmershuizen@dental-tribune.com



| C.E. article

- 06 The dental operating microscope in endodontics
_Frank C. Setzer, DMD, PhD, MS

| tribute

- 11 'He brought a world of enthusiasm and knowledge to the global endodontic community'
_Fred Michmershuizen, Managing Editor

| research

- 14 Ready-to-use bioceramic materials in apical resorption: A clinical case
_Ricardo Affonso Bernardes

| industry

- 15 Minimally invasive root canal treatment uses fluids, acoustics
- 16 The importance of irrigation and PUI in modern endodontics

| industry education

- 17 There is a better way (and LVI can show you how to get there)
_Mark Duncan, DDS, FAGD, LVIF, DICOI, FICCMO

| about the publisher

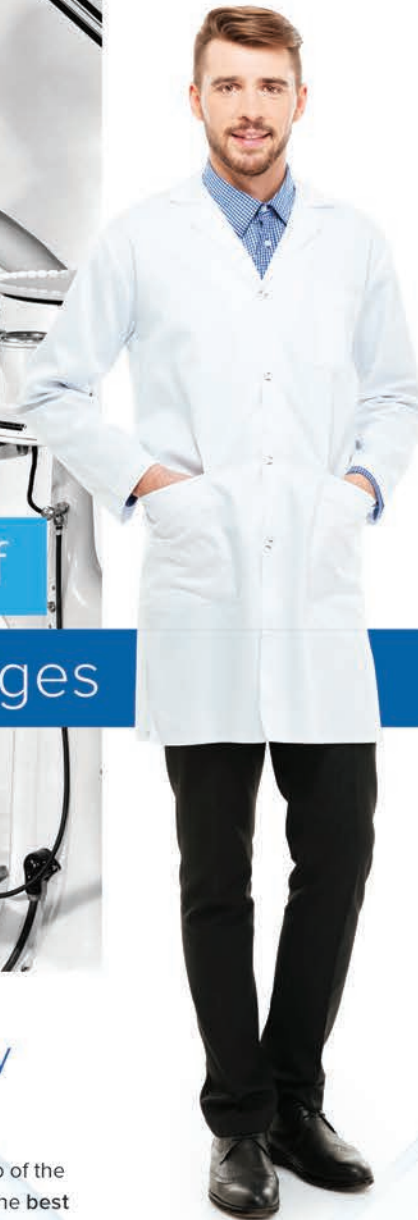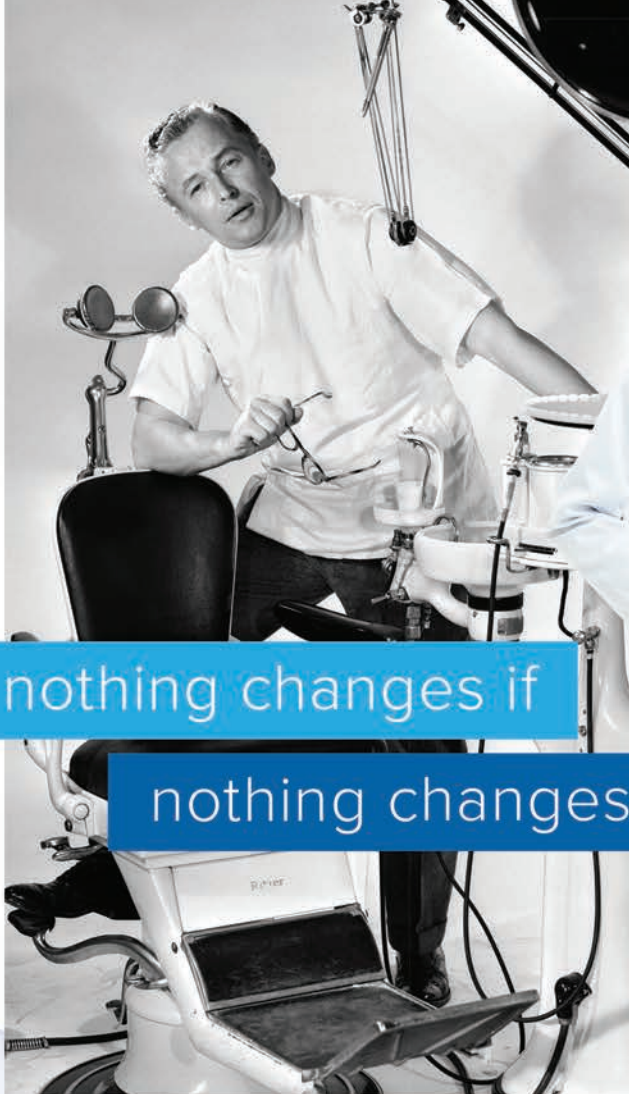- 18 _imprint



| on the cover

A diaphonized mesial root of a lower left second molar, showing the vascularity stained within the demonstration of the pulp canal system, as prepared and photographed by Craig Barrington, DDS. Barrington may be contacted at cbdds002@yahoo.com. You may also follow him on Facebook, Craig Barringtondds.



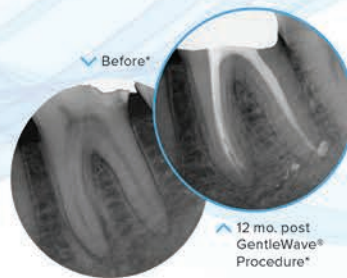

nothing changes if
nothing changes

Improve patient outcomes by improving your technology.

Being an expert in saving teeth requires staying on top of the latest advances to ensure you're giving your patients the best care—and better outcomes. The GentleWave® System delivers the unprecedented cleaning and disinfection you need to do just that.

- The entire procedure from access opening to obturation can typically be completed in just one visit¹
- Cleans the deepest, most complex anatomies of the root canal system^{2,3} to remove bacteria, debris, tissue³ and biofilm⁴
- Helps save the structure and integrity of teeth by preserving more dentin¹



Discover the GentleWave® difference today.
Learn more at sonendo.com/change.

GENTLE WAVE
PROCEDURE

VISIT US AT AAE! APRIL 25-28 | DENVER | BOOTH #1127



© 2018. All rights reserved. SONENDO, the SONENDO logo, GENTLEWAVE, the GENTLEWAVE logo and SAVING TEETH THROUGH SOUND SCIENCE are trademarks of Sonendo, Inc. Patented: www.sonendo.com/intellectualproperty. MM-0528 Rev 01

* Images courtesy Khang T. Le, DDS
1 Sigurdsson A et al. (2016) J Endod. 42:1040-48
2 Molina B et al. (2015) J Endod. 41:1701-5
3 Vandrangl P et al. (2015) Oral Health 72-86
4 Nair NPR et al. (2014) Int Endod J. 47:1003-1011

The dental operating microscope in endodontics

Author_Frank C. Setzer, DMD, PhD, MS

c.e. credit

This article qualifies for C.E. credit. To take the C.E. quiz, log on to www.dtstudyclub.com. Click on 'C.E. articles' and search for this edition (Roots C.E. Magazine — 1/2018). If you are not registered with the site, you will be asked to do so before taking the quiz. You may also access the quiz by using the QR code below.



The practice of endodontics requires precision and great attention to detail. These depend on the training, skills and experience of the clinician. Most endodontic procedures are carried out in dark and confined places, and fractions of millimeters may decide the outcome of treatment. Over the past decades, endodontics has gained not only basic and clinical scientific knowledge, but also has taken technological quantum leaps. Due to the intricate nature of endodontic treatment, practitioners have always sought to improve their vision of the operational field.

Advantages of dental microscopes

Better vision requires enhanced magnification and illumination, and both microscopes and loupes have been widely adopted. Operating microscopes have a number of advantages compared with loupes. Loupes are worn on the head and may be used with or without external light sources. This necessitates weight limitations and restricts the oculars to the bare minimum of lenses needed for magnification. By contrast, the microscope is a self-supported unit; therefore, additional lenses or prisms are not a concern. This has meaningful implications with regard to ergonomics and visualization.

The attachment of loupes to glasses dictates a design that angles the binoculars inward in order for the viewer to focus on the object. As a result, the practitioner's eyes also rotate medially. This is similar to near object accommodation by the naked eye,

which can lead to eye muscle strain and fatigue. By contrast, microscope binoculars are arranged in a parallel orientation. This arrangement is facilitated by prisms that let the incoming light

beams reach the eyes also in a parallel direction. This simulates the observation of a distant object: a straight, forward-looking gaze that causes less muscle stress and fatigue. In addition, from an ergonomic perspective, working correctly with a dental microscope improves overall body posture and may reduce neck and back pain.

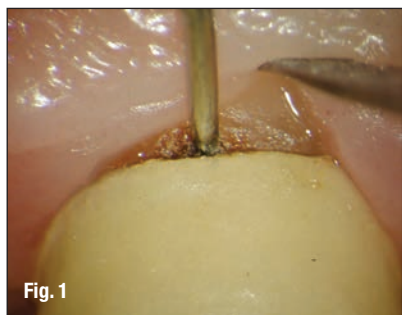
Commercially available microscopes provide adjustable magnification ranging from approximately 4x-25x magnification, while most loupes provide fixed magnification between 2.5x-6x. Magnification can be divided in low magnification (~2x-8x), mid magnification (~8x-16x), and high magnification (~16x-25x). Low, mid and high magnification are applicable for different procedural steps throughout nonsurgical and surgical endodontic treatment. Low magnification is mainly applicable for an overview of the operating field.

Mid magnification is used for the main procedural steps throughout root canal therapy and endodontic surgery. High magnification is used for the identification of minute structures and documentation of the finest details. Using a microscope significantly increases a practitioner's accuracy.¹ However, it must be mentioned that there is a learning curve and working at both mid and high magnification will require the practitioner to slow down movements to avoid unintended actions on the smallest of anatomical structures. As a result of working in a small-scale environment, new types of micro-instruments also were introduced to the dental profession.

History of microscopes in endodontics

The idea of using microscopes in dentistry is not new. Bowles suggested and used a dental microscope as early as 1907!² In endodontics, dental operating microscopes were first introduced by individual clinicians^{3,4} and then adopted by endodontic specialty programs throughout the United States. The American Association of Endodontists was an early proponent of training in microscopes for endodontic residents and successfully advocated for the Com-

Fig. 1 High-magnification inspection of caries below crown margin. Courtesy of Dr. Francesco Maggiore, Aschaffenburg, Germany. (Photos/Provided by American Association of Endodontists)



mission on Dental Accreditation to add a microscope proficiency standard to the CODA educational standards for postgraduate endodontic programs in 1998. The latest standard requires the teaching of magnification devices "beyond that of magnifying eyewear" at an in-depth level, which is the highest of the levels of knowledge prescribed by CODA.⁵ Based on two surveys, in 1999 and 2008, the accessibility and use of the microscope by endodontists increased from 52 percent to 90 percent.^{6,7} It is now also increasingly being used by other specialties⁸ and in dental education.⁹

Microscope use for nonsurgical procedures

For the endodontic practitioner, the dental microscope is useful for diagnosis and clinical procedures. The microscope may aid diagnostically in identifying caries, insufficient crown or restorative filling margins (Fig. 1), or assessing craze or fracture lines. During root canal therapy, magnification and illumination provided by the operating microscope aids with caries removal, access preparation, removal of pulp chamber calcifications, identification of root canal orifices, identification of cracks and fracture lines (Fig. 2), and the treatment of internal resorptions. Under the microscope, subtle changes in dentin color and texture become apparent, such as developmental lines on the pulp floor guiding the practitioner toward root canal orifices, or the darker color of the pulp floor itself, allowing the practitioner safer dentin removal.

High magnification can help in the localization and instrumentation of obstructed and calcified canals, the identification of canal bifurcations (Fig. 3), the removal of canal obstructions such as denticles and calcifications, and obturation (Figs. 4a,b). Additional primary endodontic procedures benefiting from microscope use include vital pulp therapy and regenerative endodontics by allowing careful and gentle manipulation of the pulpal tissues or a blood clot, respectively. Enhanced vision also aids in the treatment of dental anomalies, such as *dens invaginatus*, or fused teeth.

In endodontic retreatments, the microscope is helpful in identifying and removing leftover filling materials, such as sealer remnants, pastes or gutta-percha,¹⁰ silver points and carrier-based materials, posts or fractured instruments¹¹ (Figs. 5a-d). It also aids in nonsurgical perforation repair, allowing the practitioner to clean the perforation site and place the perforation repair material more precisely.^{12,13}

Microscope use for surgical procedures

Surgical endodontics has been completely transformed by microscopic procedures. For many years

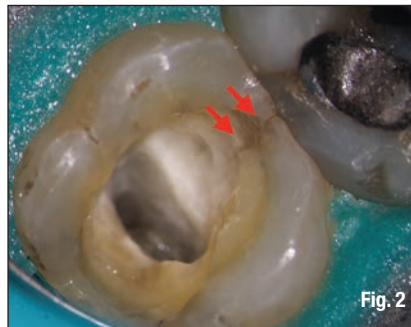

Fig. 2

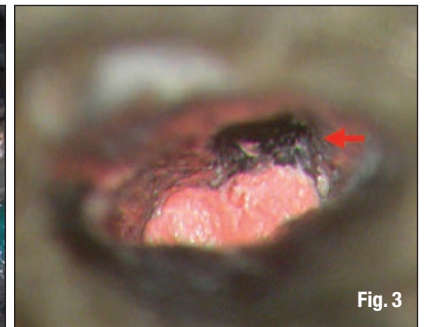


Fig. 3

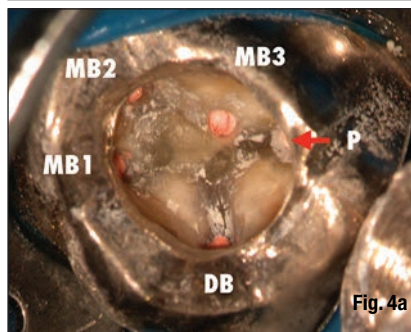


Fig. 4a

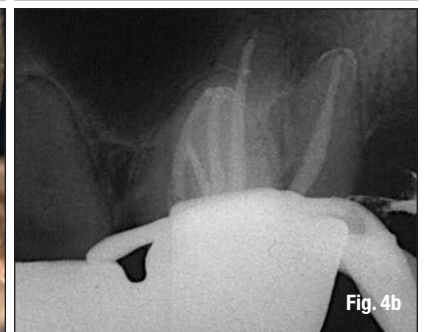


Fig. 4b

surgical burs and amalgam for root-end fillings were the standard of care. The incorporation of the microscope, and also to a certain degree the endoscope, together with the use of ultrasonic tips and biocompatible filling materials, has evolved the classical apicoectomy into modern endodontic microsurgery.¹⁴ All steps of endodontic microsurgery are carried out under varying degrees of magnification, including flap preparation, osteotomy, identification of root apices, root-end resection, inflammatory tissue removal, observation of the resected root surface (Fig. 6), root-end preparation, root-end filling, and suturing.¹⁵ The microscope is also helpful for cervical or external resorption or perforation repairs.

Treatment effects

There has been great debate over whether the use of magnification would actually increase the success rate of endodontic procedures. It is an accepted fact in endodontics that microbes and their endotoxins are responsible for the majority of inflammatory periapical lesions. Healing of these lesions in cases of a diagnosis of pulp necrosis has been associated with disinfection of the root canal system, reduction of the microbial content, filling of the root canal system and the permanent restoration of the tooth.

It is thus assumed that the identification and treatment of all parts of the root canal system increase the chances of a successful treatment and good long-term prognosis. Ample literature has been published with regard to the identification of additional canals with the help of higher magnification

Fig. 2 Evaluation of extent of mesial fracture line (arrows) in left second maxillary molar. Microscopic inspection confirmed restorability.

Fig. 3 Deep canal bifurcation. Microscope-controlled filling of first canal just below split (arrow).

Fig. 4a Situation after irreversible pulpitis of left maxillary first molar two weeks after delivery of fixed partial denture. High magnification allowed for identification and treatment of three mesio-buccal canals through existing restoration.

Fig. 4b Post-operative radiograph.

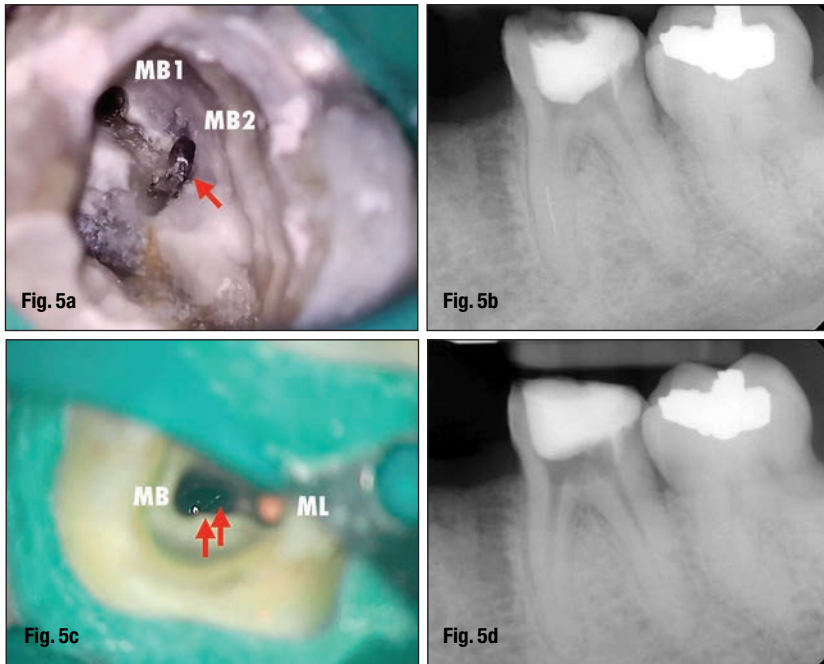


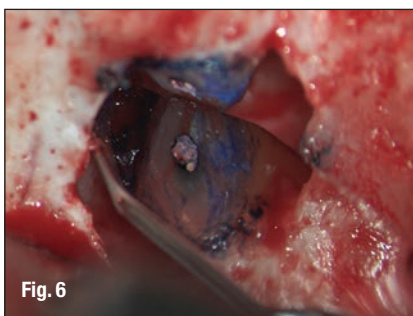Fig. 5a Separated instrument in second mesio-buccal canal of left maxillary first molar (arrow). Situation after uncovering of fragment with ultrasonic tips and debris removal.

Fig. 5b Pre-operative radiograph. Fractured instrument in mesial root of lower left first molar. Patient was referred for fragment removal and continuation of treatment.

Fig. 5c Access to instrument fragment (arrows) in mesiobuccal canal using ultrasonic tips. Note loosely placed gutta-percha in mesiolingual canal to prevent any fragments or debris from accidentally blocking the canal.

Fig. 5d Radiograph verifying complete instrument removal. Temporary after first appointment. Canals are filled with non-radiopaque calcium hydroxide.

Fig. 6 High-magnification inspection of resected root surface of left maxillary lateral incisor using a micro-mirror. Note leakage of previous root filling stained with methylene blue.



and illumination.^{16,17} The effectiveness of vision enhancement for the detection of second mesio-buccal canals (MB2) in maxillary molars was assessed both in vitro and in vivo. The detection rate of MB2 canals in vitro was shown to be 90 percent with the operating microscope and 52 percent without aided vision. Gorduysus et al.¹⁸ demonstrated that the percentage of MB2 canal negotiation increased with the aid of higher magnification.

Burley et al.¹⁹ described the successful identification of MB2s in 312 maxillary first and second molars in 57.4 percent of the cases when using the operating microscope, 55.3 percent with dental loupes and 18.2 percent with unaided vision. In first maxillary molars, the incidences of MB2 identification were 71.1 percent, 62.5 percent and 17.2 percent for the microscope, dental loupes and no magnification groups, respectively. Stropko²⁰ treated a total 1,732 maxillary molars working at times with unaided vision and at times with a dental microscope. With more experience and a dental microscope, the incidence of locating MB2 canals increased from 73.2 percent to 93.0 percent in first molars and from 50.7 percent to 60.4 percent in second molars. Microscope use also increased the number of root canal orifices located in mandibular molars,²¹ and significantly increased the quality of access cavity preparation and the accuracy of canal identification when treat-

ment was performed by dental students recently instructed in microscope use.²²

_Nonsurgical treatment outcomes

It was long uncertain if microscope usage resulted in improvements in nonsurgical treatment outcomes. Del Fabbro et al. conducted two Cochrane Reviews, in 2009²³ and 2015,²⁴ to identify randomized controlled trials and quasi-randomized controlled trials comparing endodontic therapy performed with or without one or more magnification devices. Neither in 2009, nor in 2015, were the authors able to identify a single study reporting the outcome of either nonsurgical or surgical endodontic therapy matching the strict criteria put forward in their study. Hence, the authors concluded that it was unknown if and how any magnification device affected the treatment outcome, in particular, since a great number of factors besides the microscope can have a significant impact on the success of endodontic procedures. The authors suggested future long-term, well-designed randomized clinical trials.

Recently, however, a study published by Monea et al.²⁵ assessed the impact of the operating microscope on the outcome of nonsurgical treatments of a consecutive series of 184 comparable teeth diagnosed with pulp necrosis and chronic apical periodontitis performed by postgraduate students. Success was defined as a decrease or disappearance of the radiolucency following the recommendations of the European Society of Endodontology. After follow-up periods of six months and 18 months, there were significant differences between microscope and control groups, with 94.8 percent versus 87.5 percent (healed and improved) at six months, and 95.9 percent and 91.9 percent at 18 months. At 18 months, 89 percent of cases available for follow-up in the microscope group were classified as completely healed.

_Surgical treatment outcomes

Another systematic review by del Fabbro et al.²⁶ to investigate the use of magnification devices in endodontics identified three prospective clinical trials evaluating the outcomes of endodontic surgery. The authors were unable to identify significant differences in outcomes depending on treatment with loupes, microscope or an endoscope and suggested that different magnification devices could only minimally affect the outcome. In two meta-analyses, Setzer et al. described the differences in outcome of three techniques for endodontic surgery.^{27,28} Investigated were clinical studies that applied traditional endodontic surgical techniques (TRS), including 12 studies with a total sample size of 925 teeth using no magnification, straight surgical handpieces and

amalgam root-end filling and a cumulative success rate of 59.0 percent; seven studies using contemporary surgical procedures (CRS) with a collective sample size of 610 teeth, employing magnifying loupes, ultrasonic root-end preparation and biocompatible filling materials and a cumulative success rate of 88.1 percent; and nine studies on endodontic microsurgery (EMS) with a total of 699 teeth using the identical techniques as CRS with the only differences being the use of high-power magnification devices such as microscopes or endoscopes instead of loupes and a cumulative success rate of 93.5 percent.

The cumulative success rate of the EMS group was significantly higher than the CRS group, which only employed loupes, and the TRS group, which used no magnification. The EMS group combined studies that employed both the dental microscope and the endoscope. It needs to be mentioned that these studies are comparable as both microscopes and endoscopes provide high-power magnification and illumination and also because the microscope is used for the majority of the steps of the surgical procedure in the studies where an endoscope was used during root-end preparation.

The endodontic microsurgery procedures demonstrated significantly better cumulative success rates than the studies that only employed loupes when all 16 studies with a total of 1,309 teeth were compared. Seven of 16 studies provided information on the individual tooth type (four for CRS and three for EMS), demonstrating a significant difference in probability of success between the groups for molars. Tsesis et al.²⁹ provided an updated systematic review on endodontic surgery in 2013 and also confirmed a statistically significant difference in successful outcomes of both microscope and endoscope-assisted procedures compared with loupes.

Microscope features and upgrades

Modern dental microscopes have evolved considerably with regard to features and options available to the dental clinician. Depending on personal preferences and possible locations in the operatory, floor-standing, wall- or ceiling-mounted units are available. While standard microscopes come with basic optics and light options, certain accessory features are recommended for endodontic purposes. Surgical procedures will require greater angulations to view resected root surfaces and other surgical details. At a minimum, a microscope should be equipped with 180-degree-tiltable binoculars to address the angulation requirements and an eyepiece with a reticle.

A reticle is a set of fine lines, most commonly in the shape of crosshairs or concentric rings, that provides proper centering on the object in focus and allows for easier individual calibration (parfocaling) of the

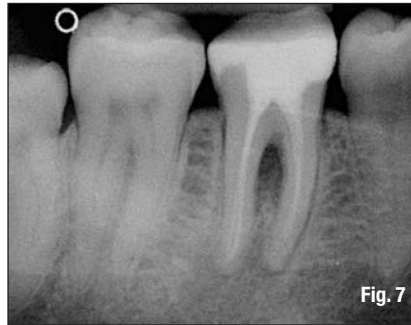

Fig. 7

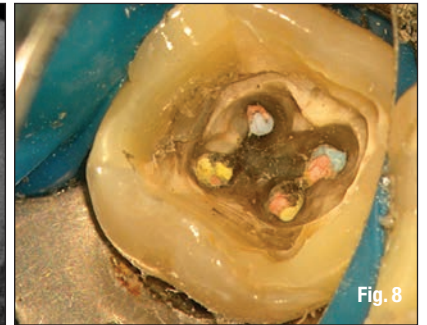


Fig. 8

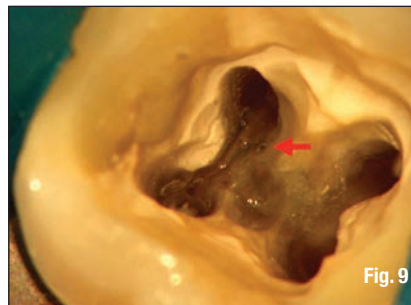


Fig. 9

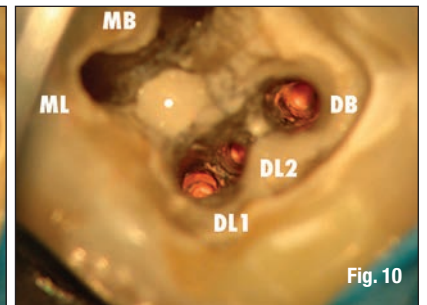


Fig. 10

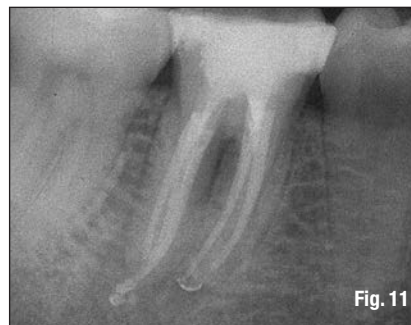


Fig. 11

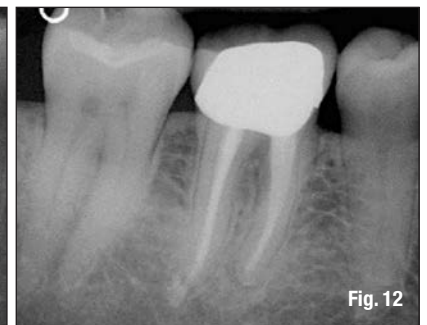

Fig. 12

microscope. It also is an indispensable tool for documentation. Since light and the object image reach the binoculars virtually free of shadows, microscope photography and recording allow for excellent image quality for documentation and clinical operations. However, this requires perfect calibration with an external monitor and a reticle to center the image. Full high-definition and three-chip cameras are the gold standard for video recording and available as external or internal solutions. Screenshots from video recordings can be obtained at higher quality by using post-processing software applications that allow for image stacking.³⁰ For still photography, new generation digital mirrorless cameras have demonstrated advantages compared with DSLRs.

There is a variety of additional upgrades for core microscope functions. Instead of fixed focal distances that limit the microscope to an object distance of 200 mm, 250 mm or 300 mm, variable focal distance adapters have become available, allowing for easier switching between practitioners and easier adjustment to patients of different statures. These are offered in top-of-the-line microscopes, often in conjunction with electrical zoom and fine focus options that allow smooth and stepless adjustments of both magnification and focus. Extendable (foldable)

Fig. 7 Pre-op image of a mandibular right first molar in which nonsurgical root canal treatment had been completed five years ago. (Photos/ Provided by Dr. Frank C. Setzer)

Fig. 8 Clinical image shows previously treated canals with infected gutta-percha filling.

Fig. 9 A furcation canal is visible under high magnification (arrow).

Fig. 10 A third distal canal is also located under magnification.

Fig. 11 Post-operative radiograph shows the retreated tooth with five main canals.

Fig. 12 The one-year follow-up radiograph demonstrates the complete resolution of the periradicular radiolucencies and permanent restoration of the tooth.