

# implants

international magazine of oral implantology



## case report

Minimally invasive implant dentistry

## industry

Implant retreatment

## interview

Measuring implant stability

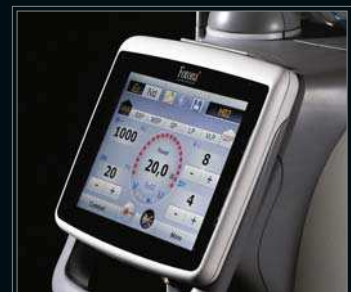

The universe at your fingertips.

## TwinLight<sup>®</sup> Peri-implantitis Treatment

A simple and effective laser procedure that offers the power to treat peri-implantitis – an increasing threat to oral health.

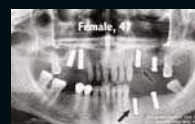
- Minimally-invasive technique
- Fast regeneration/healing
- Reduced inflammatory response
- Highly effective treatment
- No antibiotics needed



 LightWalker<sup>®</sup>

[www.lightwalkerlaser.com](http://www.lightwalkerlaser.com)

Peri-implantitis treatment video



**Dr Rolf Vollmer**

First Vice President and Treasurer of DGZI



## We are **inviting** you to **the future**

Dear colleagues,

This year, the 48<sup>th</sup> DGZI International Annual Congress, being held on 28 and 29 September in Düsseldorf, Germany, will also be the 1<sup>st</sup> Future Congress in Dental Implantology. In cooperation with the congress organiser and publisher OEMUS MEDIA AG, we have developed a diverse and future-oriented further training programme.

On Friday morning, the Future Podium “Visions in Implantology” will kick off the event followed by two live-streamed and moderated surgeries (CAMLOG, Straumann). Table clinics will take place in the afternoon. Participants can attend up to three subsequent table demonstrations, having a choice between 24 table clinics covering diverse, practice-oriented topics. As the number of participants is limited to eight per table, we would like to ask you to inform us about your preferences as soon as possible.

Hard work deserves time off too—after the table sessions, you are thus invited to a casual and relaxed get-together on Friday evening in the exhibition area, where the industry sponsors have put special effort into

their stand designs. Chat with colleagues, expand your network and enjoy the evening, after the day’s events.

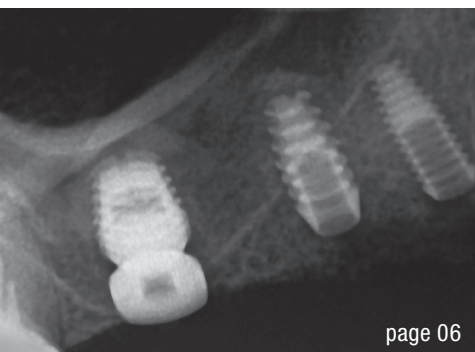
Saturday will be dedicated to scientific presentations of renowned national and international experts. All presentations will be simultaneously interpreted into English or German.

As you can see, we have organised a diversified and informative educational event on modern and future-oriented dental implantology. In addition, a two-day programme (hygiene in dental practices, QMC) will run in parallel for your practice team and is being offered at a special team rate. Detailed programme information can be found in the congress programme on pp. 41–43 and at [www.dgzi-jahreskongress.de](http://www.dgzi-jahreskongress.de).

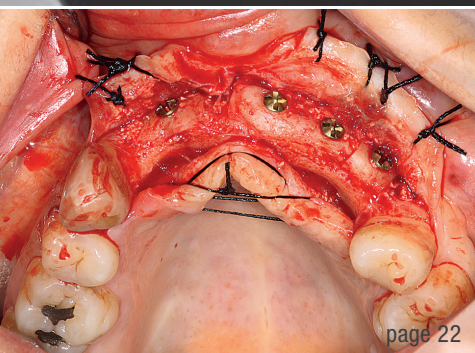
Be part of it! We are looking forward to seeing you in Düsseldorf!

Yours,

Dr Rolf Vollmer



page 06



page 22



page 45

Cover image courtesy of  
Integration Diagnostics Sweden AB  
www.penguinfa.com  
Original Background:  
© Jan Martin Will/Shutterstock.com



## editorial

We are **inviting** you to **the future** 03  
Dr Rolf Vollmer

## case report

**Minimally invasive** implant dentistry with **short or narrow implants** 06  
Prof. Mauro Marincola, Dr Daniel Hernández-González,  
Dr Jaime Guzmán-De Ávila & Dr Miguel Simancas-Pallares

**Periapical implant lesion** and **retrograde peri-implantitis** 14  
Dr Nikolaos Papagiannoulis

## industry

**Implant retreatment** 22  
Dr Philippe Leclercq, Jean-François Martinez,  
France & Michael Brûsh

## interview

Measuring **implant stability** 30

Bringing a turnkey **restoration solution** to dentists 34

## events

Best of **EuroPerio9** 44

Nobel Biocare announces **new products and partnerships** 45

**Implantology & Modern Dentistry** 46

## news

manufacturer **news** 36

**news** 48

## about the publisher

imprint 50




# Penguin<sup>RFA</sup>

MONITOR OSSEOINTEGRATION



- ▶ Autoclavable  
20 times
- ▶ ISQ Standard  
Calibrated™
- ▶ Optimal platform fit
- ▶ Laser marked with  
type number



The ISQ-scale is from 1–99 and tells you how stable your implants are.

# Minimally invasive implant dentistry with short or narrow implants

## Ridge splitting and crestal and internal sinus lift

Prof. Mauro Maricola<sup>1</sup>, Dr Daniel Hernández-González<sup>1</sup>, Dr Jaime Guzmán-De Ávila<sup>1</sup> & Dr Miguel Simancas-Pallares<sup>1</sup>, Colombia

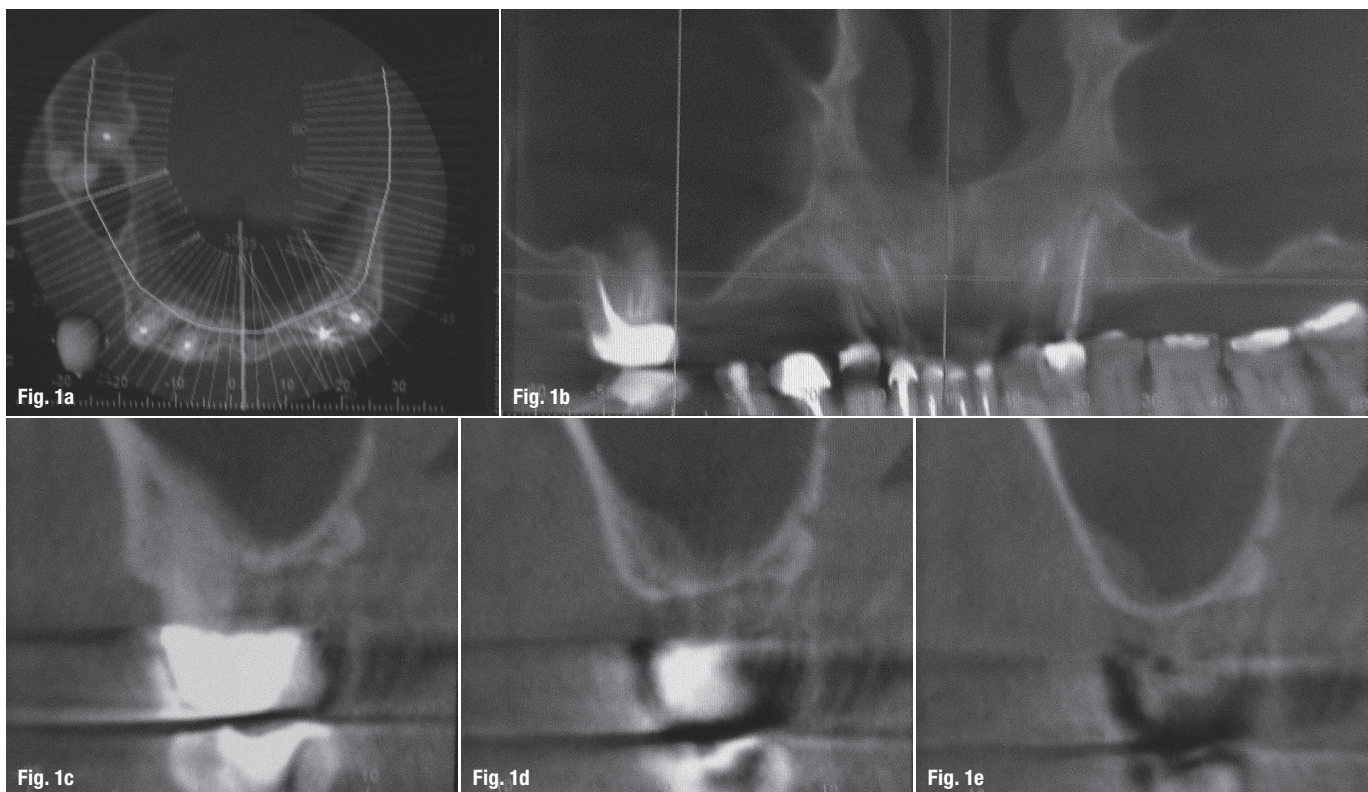
<sup>1</sup>Dental Implant Unit, Faculty of Dentistry, University of Cartagena, Colombia

### Introduction

Dental implants have been advocated as the treatment of choice for missing teeth and tooth replacements. Scientific evidence demonstrates their high success rates and therefore their clinical applicability. However, in some circumstances due to premature posterior tooth loss leading to severe sinus pneumatisation or a congenitally missed tooth causing alveolar bone collapse, implant placement can still remain challenging for clinicians. These circumstances could be present in one surgical

target area at the same time, thus increasing treatment complexity. In such cases, available options such as short implants, ridge splitting, and internal and crestal sinus lifts have been proposed to minimise treatment cost and time, as well as co-morbidities but preserve treatment success rates.

In order to address clinical-related sinus pneumatisation issues, two main surgical approaches have been suggested: internal and lateral sinus lift techniques. The internal sinus lift approach is indicated whenever the re-



**Figs. 1a–e:** CT scan analysis of the targeted surgical area: **a)** Coronal view of the maxilla showing the limited width and **b)** panoramic view of the maxilla depicting the reduced vertical bone height in the right quadrant. **c–e)** Sagittal views of the molar area with the diminished residual bone height as little as 1 mm.

a perfect fit™

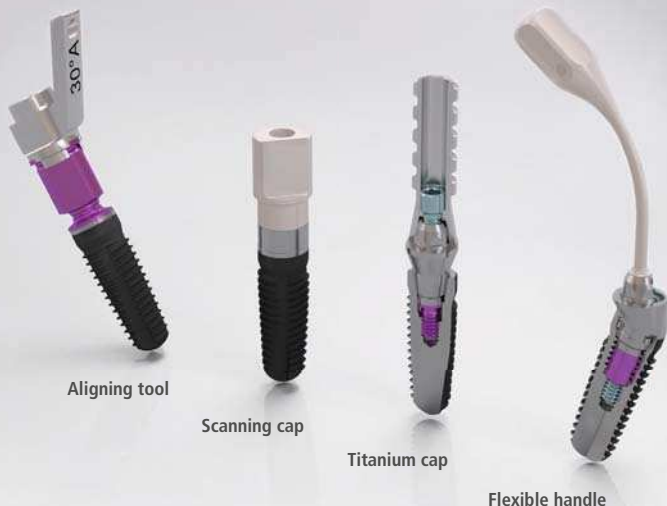
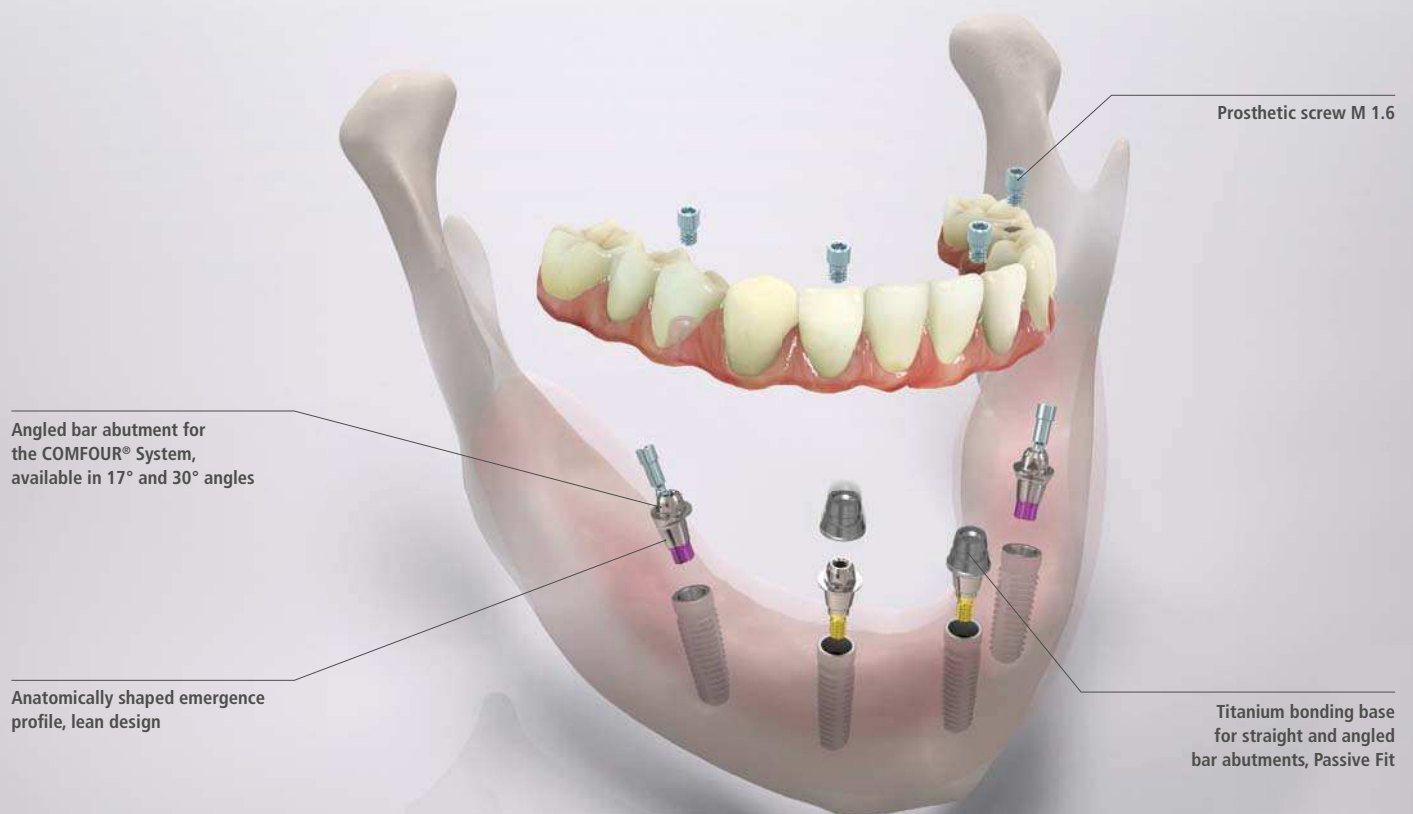camlog

## THE NEW COMFORT CLASS.

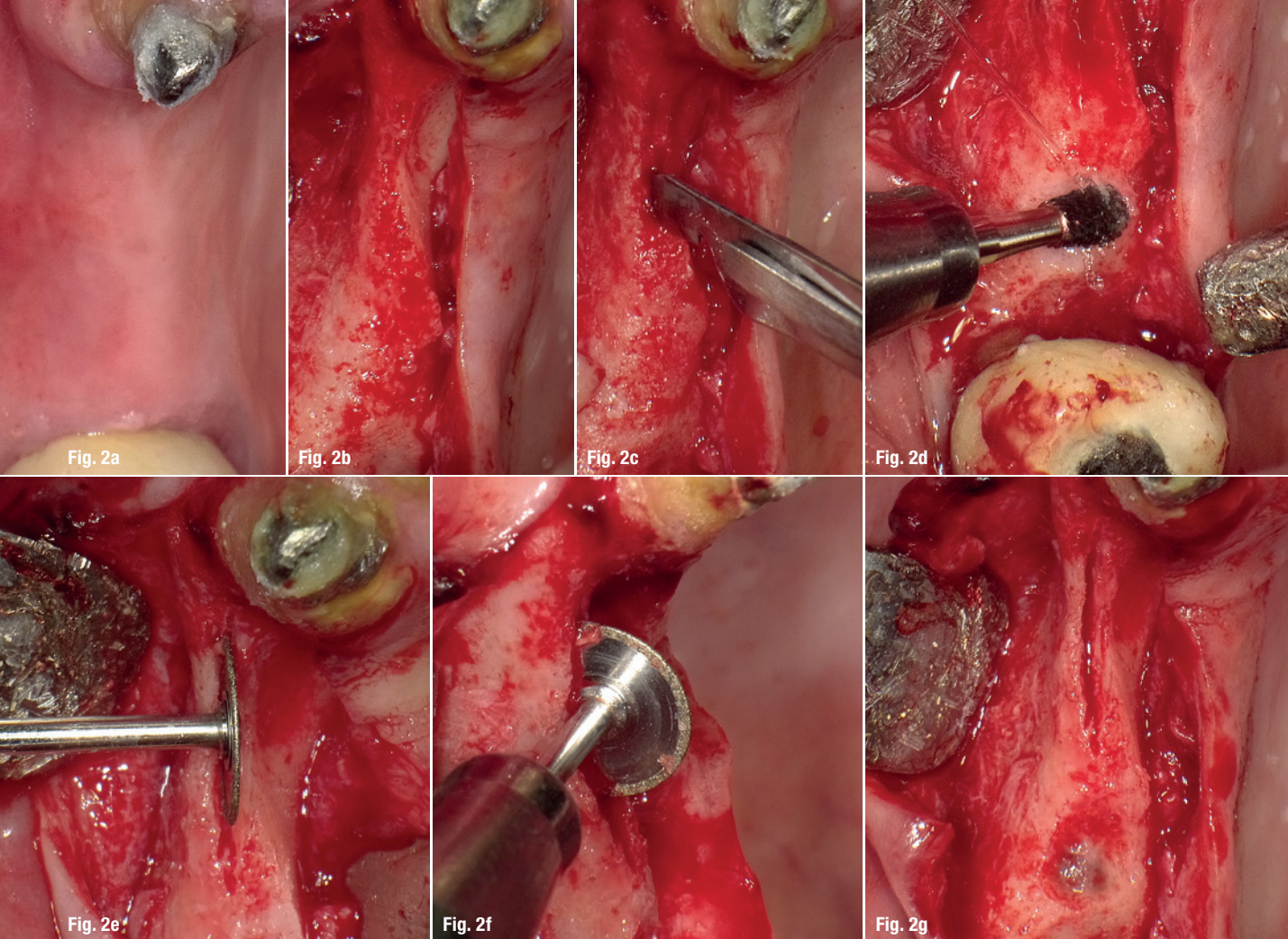
The COMFOUR® Abutment System for occlusal screw-retained restorations is an ideal addition to the CAMLOG® and the CONELOG® Implant System. With the COMFOUR® System, you can offer your edentulous patients the option of an immediate, comfortable and permanent denture on four or six implants – and thus a considerable gain in quality of life. [www.camlog.com](http://www.camlog.com)

**CAMLOG®**  
SYSTEM

**CONELOG®**  
SYSTEM



COMFOUR® offers you a range of options to overcome the challenges you face in your implant practice, making them easier while saving time.



**Fig. 2a:** Pre-op view of the targeted surgical area. **Fig. 2b:** Targeted surgical area once the full-thickness flap was obtained. **Fig. 2c:** Cortical perforations to generate initial split. **Fig. 2d:** Crestal perforation in order to expose the sinus cortical bone and perform a sinus lift. **Figs. 2e & f:** Cortical deepening by use of a diamond-covered disc under continuous irrigation. **Fig. 2g:** Surgical view of the split area in the premolar zone and the crestal perforation in the molar area.

residual bone height (RBH) is 4 to 7 mm. First proposed by Summers, it entails performing a cortical greenstick fracture using osteotomes, allowing the Schneiderian membrane to be easily lifted.<sup>1</sup> This technique has the advantage of allowing immediate implant insertion. The lateral sinus lift approach is suggested when the RBH is less than 4 mm. With this skill-dependent technique, a bony lateral window has to be created, exposing the cortical bone. Once this has been achieved, membrane detachment with the use of curettes is performed, and an alloplastic material is injected as a bone graft. After a graft healing period of five to six months, the implants can be inserted. In order to address alveolar collapse issues, ridge splitting was proposed as a surgical approach, wherein the cortical plates are separated to allow the insertion of implants into the artificially created space.

All these options are of high clinical value when facing such scenarios. However, implant length is considered one of the most important predictors in treatment efficacy when performing these techniques. Likewise, short implants have been proposed, since they have marked clinical advantages, such as minimising the amount of sinus membrane to be lifted and grafting material to be injected, thus introducing the concept of minimally invasive implant dentistry. Short implants are widely dis-

cussed because of their increased use in recent years. Historically, long implants (> 13 mm) in combination with sinus lift procedures were recommended to restore function and aesthetics. Nowadays, improvement on implant design and scientific evidence have shown high success/survival rates of short implants, thus indicating them to be among the most valuable approaches in modern dentistry.

Having all these concepts in mind, the objective of this case report was to demonstrate the use of short implants in combination with ridge splitting and internal and crestal sinus lift in the same surgical area, thus applying a minimally invasive dentistry approach.

## Case presentation

A 52-year-old male patient consulted our practice owing to his desire for functional and aesthetic restoration. The patient did not report any medical background of dental interest. He also signed informed consent prior to the start of treatment and was classified as ASA I physical status. After radiographic (Figs. 1a–e) and clinical (Fig. 2a) examination, it was found that the patient required dental implantation in the right posterior maxilla owing to the missing first and second premolars and first molar.





GC Implants:  
Quality derived  
from tradition



**GC**

[www.gctech.eu](http://www.gctech.eu)