

implants

international magazine of oral implantology



case report

Single tooth restoration with
the one-tooth one-time technique

industry

Initial stability after placement of
a new buttress-threaded implant

interview

Combining strengths towards further evolution

Monitor osseointegration

- Reduce treatment time
- Manage risk patients



- Autoclavable 20 times
- ISQ Standard Calibrated™
- Optimal platform fit
- Laser marked with type number

Dr Rolf Vollmer

First Vice President and Treasurer of DGZI



Second **Future Congress** of DGZI— An event for practitioners

Dear colleagues,

On 4 and 5 October 2019, the second Future Congress for Dental Implantology of the German Association of Dental Implantology (DGZI) will take place in Munich (Germany) under the theme “Perio-Implantology: Implants, Bone & Tissue—Where are we today and where are we headed?” The interactive congress concept that was successfully implemented last year for the first time will serve as the foundation of this year’s conference too and there will be, once again, a strong focus on the future of implant dentistry. You are most warmly invited to attend!

Embracing this novel concept means in concrete terms that there will no longer be a division into various lecture sessions, workshops and parallel programmes, sharpening the profile of the congress as an event for practitioners as a result. The conference will be split into an industry day on Friday, comprising strategy lectures, live streaming of surgeries and table clinics; and a Saturday solely dedicated to science. This format is aimed at fulfilling the information needs of implantologists in particular. Also, the industry will be given even greater significance through the table clinics and an exhibition concept that is a spatially integral part of the programme. By employing modern tools such as the future podium, innovative presentation techniques, digital poster presentations and interactive solutions, the overall experience will be something of a congress trade fair. A special catering concept of “flying service”, bringing participants food where they are, will serve this purpose as well. By

increasingly dissolving the breaks between the lectures, live surgeries and table clinics, participants, speakers and industry representatives will be given significantly more time for communication.


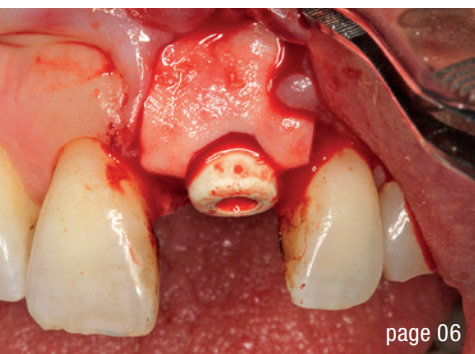
On Friday, 4 October, an implant surgery carried out by Dr Conrad Kühnöl and a tutorial led by Prof. Florian Stelzle will be live streamed to the Munich conference hall and on ZWP online, Facebook and YouTube. The focus of the implant surgery, starting at 12:15 p.m., will be on adapting a digital workflow with a specifically tailored implant concept and compatible software. It will be demonstrated how treatment safety, legal protection through proof of patient education prior to surgery, less patient stress and cost-effectiveness can be achieved through optimised time management. In his tutorial titled “Fast.four.fixed.final—Fixed third teeth in one day”, starting at 1:15 p.m., Stelzle will then guide participants step by step through planning, implant insertion and placement of the prosthetic framework, commenting in real time on the surgical sequences shown and answering questions from online viewers and from participants in the conference room alike.

I look forward to seeing you in Munich!

Yours,

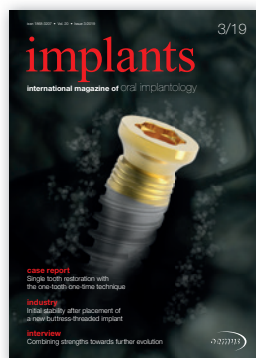A handwritten signature in black ink, appearing to read 'R. Vollmer'.

Dr Rolf Vollmer



Cover image courtesy of Nobel Biocare
www.nobelbiocare.com

Xeal and TiUltra are currently not available in the USA



editorial

- Second **Future Congress** of DGZI—An event for practitioners 03
Dr Rolf Vollmer

research

- Single-tooth** replacement using CBCT matching and **virtual wax-up** 06
Dr Jakob Zwaan & DT Vito Minutolo

case report

- Single tooth restoration with the **one-tooth one-time technique** 14
Drs Louwrens Swart & Paul van Zyl
- Implant treatment of **heavy smokers** with **critical** bone situations 20
Drs Branislav Fatori & Inge Schmitz

industry

- Initial stability** after placement of a new **buttress-threaded** implant 24
Dr Enrico Conserva

interview

- Good **practice guidelines** for implant dentistry 30
- Combining **strengths** towards further **evolution** 32

events

- Game changer? Nobel Biocare launches **new implant system** 42
- Harmony** in a signature smile 44
- The inaugural **Dynamic Navigation** Symposium 2019 in Rome 45

news

- manufacturer news 34
- news 48

about the publisher

- imprint 50

MAKE NO BONES ABOUT IT.

CONFIDENCE IN ALL BONE QUALITIES:
PROGRESSIVE-LINE



SPECIALIST IN SOFT BONE:

- Apical conical area for high primary stability in soft bone
- Thread up to the apex, ideal for immediate implantation
- Thread design with deeply engaging thread flanks
- Flexible drill protocol for preferred stability

WWW.CAMLOG.COM

a perfect fit™

camlog

Single-tooth replacement using CBCT matching and virtual wax-up

Dr Jakob Zwaan, Netherlands & DT Vito Minutolo, Italy

In our practice we often encounter major challenges when just a single tooth needs to be substituted. In order to estimate the risk of an unacceptable aesthetic treatment result and to determine the most effective treatment plan, it is necessary to perform an analysis of the desired tooth shape, the soft tissue architecture and the bone volume necessary to stabilise an implant in the optimal position and support the soft tissue.

In the following, an approach to cases will be described in which a single tooth needs to be replaced by an implant-supported crown. After an anamnestic interview with the patient, we proceed with the intra-oral examination. Hygiene and periodontal health are checked. Normally, an intra-oral radiograph for a single tooth is taken first (Fig. 1) or a dental panoramic tomogram if the need for a more extensive treatment is suspected. In the same session, both dental arches are scanned with an intra-oral scanner and the bite is registered. The photographic sequence is as follows:

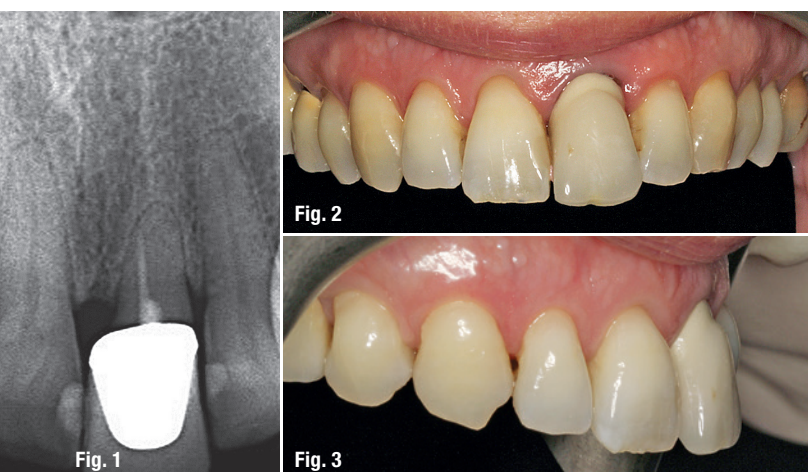1. Full frontal view intra-oral photograph.
2. Detailed photograph of the single arch, possibly with a black mirror to contrast the teeth (Fig. 2).
3. Photograph of laterolateral detail of the tooth and gingival profile (Fig. 3).
4. Full-face photograph with maximum gingival exposure.
5. Full-face photograph of a spontaneous smile.
6. Photograph of the full face at rest.



This sequence allows one to view immediately the presence of orthognathic and periodontal issues (Fig. 1), to evaluate the biotype (Fig. 2) and to estimate aesthetic challenges, like tooth colour, tooth texture, soft tissue/lip exposure and position of the incisal edge/lip (Fig. 3). The 3D intra-oral scan is helpful for determining orthodontic alignment of the teeth and in our protocol replaces an occlusal and/or 12 o'clock photograph in most cases. "There can be different ways of treating a disease, but there can be only one correct diagnosis." Dr Morton Amsterdam, 1974. When anamnesis, intra-oral examination and preliminary radiographs conclude that the tooth in question cannot be preserved, it needs to be decided what the optimal timing for extraction and a CBCT scan is and how to provide for a temporary tooth replacement. Also, the operator must choose between immediate, early or delayed placement in the fresh extraction socket.

Our policy is the following: in case of acute inflammation that cannot be effectively treated, we will proceed with extraction. A temporary fixed etch and bond or removable prosthesis can be used to guarantee acceptable aesthetic comfort to the patient. In these cases, a CBCT scan will be taken after extraction so that the most detailed image of the socket anatomy can be obtained. Since a provisional solution has been provided for, there is no need for very early implant placement. Timing is now based on the expected period needed for the infection to be eliminated and the risk of loss of volume by the collapse of tissue. Normally, the implant is placed four to six weeks after the extraction. Another reason for delayed implant placement can be the need for healed soft tissue in order to facilitate proper wound closure to protect, for example, bone substitutes and membranes when bone augmentation is necessary.

If the patient is suffering, extraction should be done quickly. If the anatomy and biological conditions are favourable, implant surgery can be carried out as early as one week after extraction. Only if there is no inflammation or infection, and sufficient bone and soft tissue quantity and quality are present, the implant should be placed in the fresh extraction socket. In such a case, the CBCT scan would be performed before proceeding.



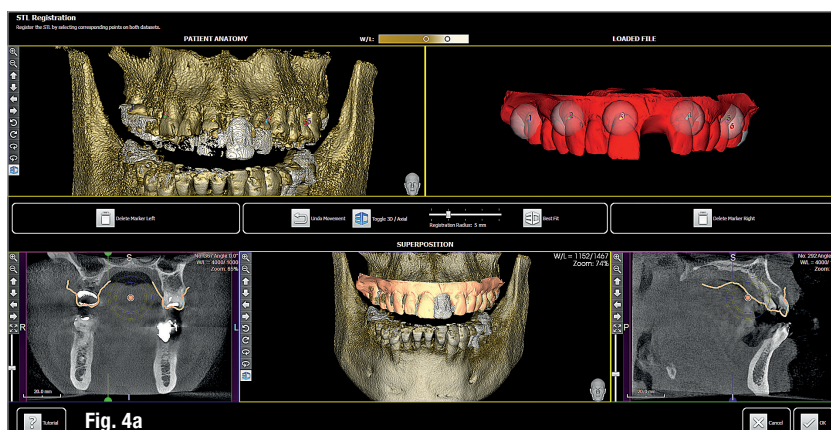


Fig. 4a

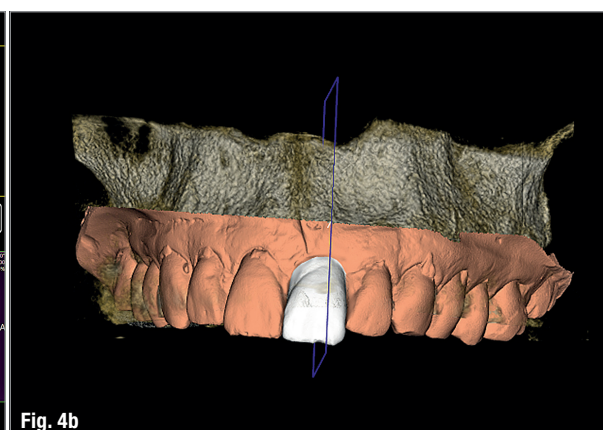
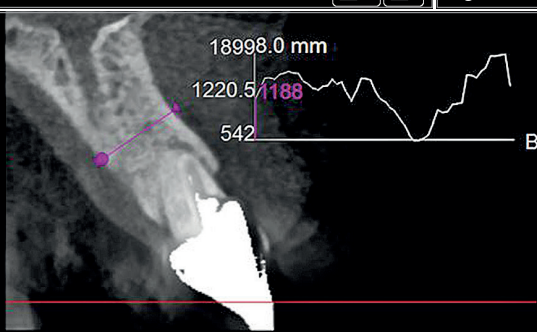


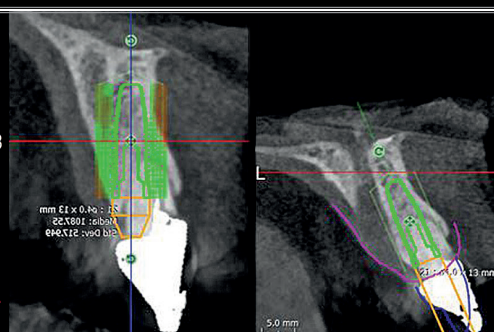
Fig. 4b

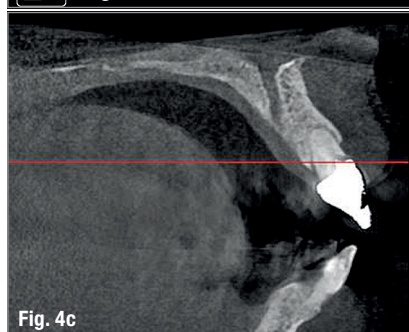

Fig. 4c



B



Minor bone augmentation and/or connective tissue grafting can be performed contemporaneously. The decision to place an immediate provisional crown on the implant is strongly related to the expected primary stability of the implant, as well as the opportunity to manage the position of biomaterials in such way that undisturbed and uncontaminated healing is guaranteed. After healing, good aesthetics and sufficient protection of the underlying implant and implant–prosthesis connection are requisite if we wish to treat our patients in the best possible way.

Risk evaluation

First aesthetic risk evaluation

One can start with a render of a 2D photograph. We use the macro intra-oral shot with the black background behind the teeth (Fig. 2). With Adobe Photoshop, GIMP, Microsoft PowerPoint or Keynote, for example, it is easily possible to cut out the shape of the contralateral tooth that will not be extracted, copy it, flip it horizontally and paste it in the position of the tooth that needs replacement. It will be clear immediately whether this shape supports the papillae sufficiently or whether there is a lack of volume that needs to be compensated for. Also, this image with the flipped contralateral tooth can be aligned with the original photograph and then draw a horizontal line across both images that coincides with the same gingival reference points. This will demonstrate whether there is a vertical component that indicates a lack or abundance of soft tissue. This can be easily quantified in a metric system if an intra-oral reference is measured with

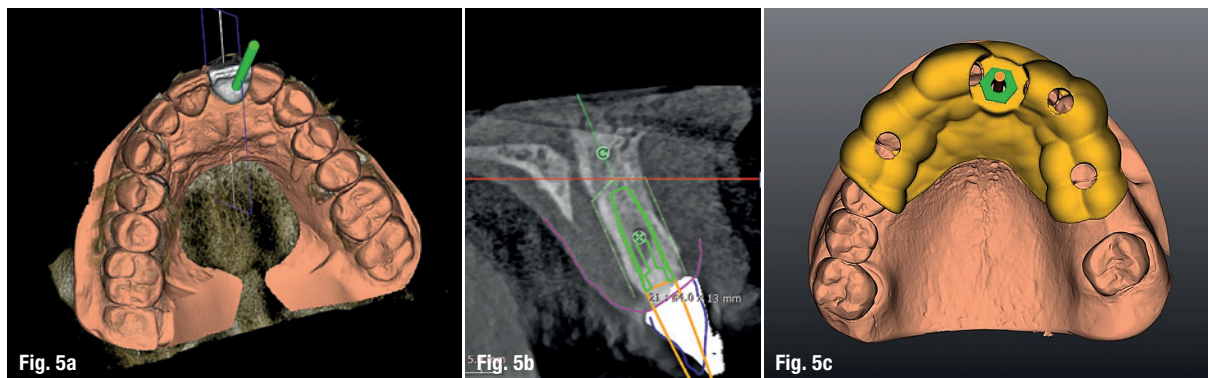
a calliper. The patient can now be informed whether additional procedures like guided bone regeneration (GBR) or a connective tissue graft will be needed.

Second risk evaluation

The intra-oral scan is imported into CAD software and transformed into a virtual master model without the tooth to be extracted and a separate STL shape of the ideal CAD-designed tooth. Now there is the opportunity for 3D evaluation of the dimensional relation between the new tooth and the soft tissue before extraction. In the current case, the tooth involved had not been extracted and a CBCT scan was performed (X-Mind trium, ACTEON; 110 × 80 mm field of view; 0.15 mm voxel size) for further investigation and treatment planning. In the AIS 3D App software that comes with the CBCT X-Mind trium device, STL files can be matched and aligned with the 3D bone volume, thus giving the opportunity to plan the future implant position taking into account the shape and position of the future crown (Figs. 4a & b). In accordance with the prosthetic procedure preferred, cemented versus screw-retained, CAD/CAM-fabricated versus manual layering and the type of material to be used, all the information for the final treatment plan is available, on which decisions can be made regarding GBR, connective tissue graft and timing of implant loading.

Case report

The female patient, aged 47 and a non-smoker, was in good general health. She experienced increasing mo-

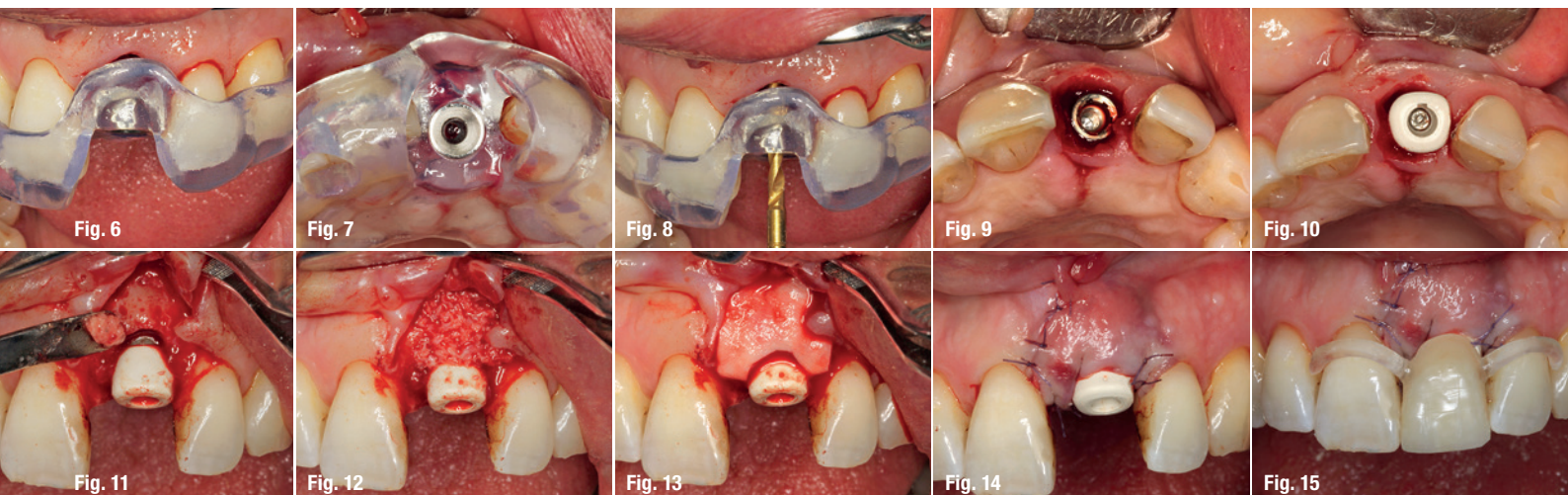


bility of the maxillary left central incisor and complained about compromised aesthetics due to the extrusion and progressive migration of the tooth in a buccal direction. The incisor had been treated with a crown at a preadolescent age after a violent trauma. The intra-oral radiograph showed incomplete root development and evidence of a root canal therapy suggesting a strip perforation though no signs of periapical lesions were present. The shape of the crown was not symmetrical in relation to the triangular shape of the maxillary right central incisor, but had a wider and rectangular profile. Minor general gingival recession had led to the presence of a tiny interdental space. The marginal gingiva was reddened, and the central papilla was not symmetrical. Probing depths were within 2mm for both the right and left central incisors and the radiographic mesial and distal bone peaks were of a regular height. The photographic aesthetic evaluation showed that it would be very difficult to obtain symmetry in tooth shape and have good-looking and healthy soft tissue support at the same time. The patient's maximum smile exposed the gingival contours. In such cases, it may be wise to consider also the possibility of altering the anatomy of the contralateral tooth with, for example, a ceramic veneer and discuss outcomes with the patient before finalising the treatment plan. This can be evalu-

ated by performing the cut/copy/flip/paste sequence in reverse. It was decided to start performing the best possible replacement of the maxillary left central incisor and evaluate at an advanced stage with a temporary crown on the implant and mature, conditioned tissue whether to add a veneer to the maxillary right central incisor.

Analysing the CBCT scan

The short-rooted tooth could be extracted without compromising the buccal bone, and there was sufficient bone volume and quality to obtain good primary implant stability. Thanks to the AIS 3D App software, this information can be visualised using the bone density tool and linear measures tool (Fig. 4c). The presence of the nasopalatine duct prohibited ideal palatal positioning of the implant, and if the implant were to be placed flush with the palatal alveolar bone, this would have resulted in a 1.5–2.0mm high exposure of the implant collar on the buccal aspect (Fig. 5a). It was thus decided to place the implant in that position and to augment the buccal bone volume with a contemporaneous GBR procedure, thus also providing for major soft tissue support. Literature suggests that that in some measure the implant will deviate buccally from the orig-



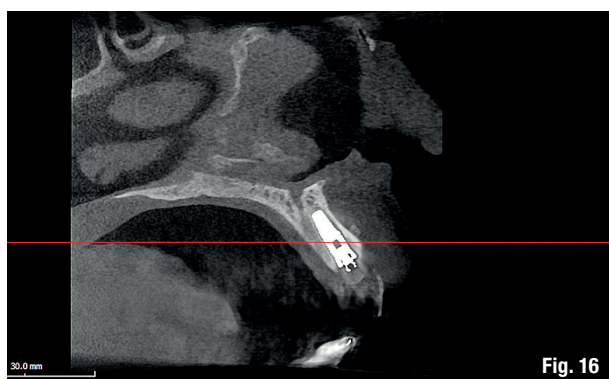


Fig. 16

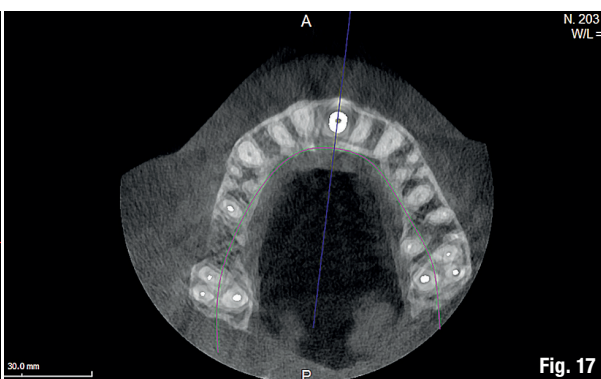


Fig. 17

inal planning because of the major mechanical resistance of the palatal plate.²⁻⁴

The author's team prefers screw-retained solutions. Several production centres are capable of milling angulated screw access holes in cobalt-chromium abutments of up to 25°. It can be easily checked in the implant planning software whether the future access hole will exit on the palatal aspect of the tooth, either by angulating the implant extension tool or by choosing a virtual abutment from the library. Confirming being in the safety range from this point of view allowed for an approach that foresaw the implant in native bone without the necessity for major GBR on the apical aspect of the implant. It was decided to use a surgical guide (Figs. 5a & b) for only the first drill to determine with precision the position and angulation of the osteotomy that would be performed freehand thereafter. A removable temporary prosthetic tooth was produced in advance.

Surgery

Local anaesthesia was performed with 2% mepivacaine with 1:100,000 adrenaline. Preventative antibiotic therapy with amoxicillin (1 g, b.d. for five days) was prescribed,

aided by use of a 0.2% chlorhexidine mouth-rinse three times a day. The tooth was extracted and the sulcular epithelium removed with diamond burs. The milled surgical template (Figs. 6 & 7) served as a guide for the first 2 mm diameter pilot drill (Fig. 8). Thus, the planned depth, position and angulation of the osteotomy were obtained. The drill sequence was completed freehand, using tapered 3.0 and 3.4 mm drills. A Neoss Pro-Active Tapered Implant of 4 mm in diameter and 13 mm in length was inserted flush with the mesial/palatal/distal bone, motor driven up to a torque of 50 Ncm and then with a manual wrench (Fig. 9). The correct position of the internal hex was verified by checking the references on the implant driver, which ideally points in the buccal direction. Resonance frequency analysis with Penguin-RFA (Integration Diagnostics Sweden) determined an ISQ value of 73/76. A Neoss Esthetic Healing Abutment with a ScanPeg was connected to the implant (Fig. 10). A flap was then raised after a vertical incision of the frenulum and the expected buccal exposure of the implant neck was evident. Autogenous bone was positioned directly on the implant surface (Fig. 11), followed by a bone substitute on top of it and on the buccal cortical bone (Fig. 12). This material was covered with a resorbable membrane (Fig. 13). The mobilised flap was then repositioned by rotating it coronally and fixed with single su-

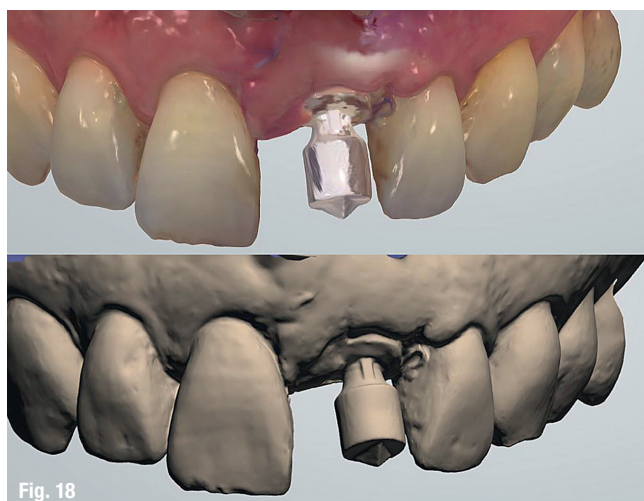


Fig. 18



Fig. 19