

# laser

international magazine of laser dentistry

I | S | L | D



## research

The periodontal pocket

## case report

Laser-assisted gingival modification of an edentulous site

## industry

Analysis of the laser dentistry market



dental





# M.Sc. Lasers in Dentistry

Specialist in dental laser therapies

Next Start: **17<sup>th</sup> September 2020** | Aachen, Germany | 4 semesters

Aachen Dental Laser Center - AALZ  
Pauwelsstraße 17 | 52074 Aachen | Germany  
phone +49 241 47 57 13 10 | fax +49 241 47 57 13 29  
info@aalz.de  
www.aalz.de

RWTH International Academy  
Kackertstraße 10 | 52072 Aachen | Germany  
phone +49 241 80 23543 | fax +49 241 80 92525  
info@academy.rwth-aachen.de  
www.academy.rwth-aachen.de



Aachen Dental Laser Center

**INTERNATIONAL  
ACADEMY**

**RWTH AACHEN  
UNIVERSITY**

**PROFESSIONAL EDUCATION PROGRAMMES**

Your contact for more information: Leon Vanweersch • [vanweersch@aalz.de](mailto:vanweersch@aalz.de) - [www.aalz.de](http://www.aalz.de)

**Prof. Dr Norbert Gutknecht**

ISLD President and Scientific Chairman



## A brief history of dental lasers

Dear friends of dental laser technology,

Exactly thirty years ago the first German users of dental lasers met for a “Laser Study Club” in order to find out what the first Nd:YAG laser of the company “American Dental Laser”, which was especially developed for dental applications, was capable of. It was a free-running pulsed Nd:YAG laser with a power of 0.5–3.0 W and 10–30 Hz. The extraordinary thing was that, for the first time ever, the power could be transmitted to the tissue via a quartz fibre.

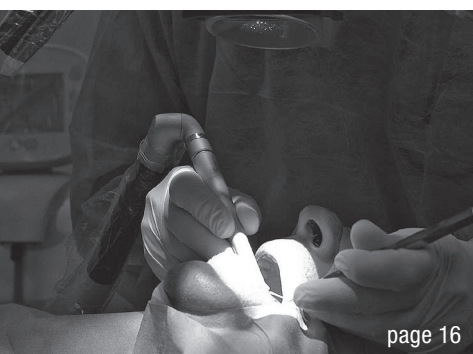Even more “extraordinary” was the fact that the official brochure promoted the laser as being suitable for more than 30 indications, including hard-tissue applications. Unfortunately, this originated from the marketing concept that had been pursued by the company, rather than from actual research findings. Naturally, people had different feelings about this: on the one hand, universities and conservative opinion leaders were not just sceptical, but for the most part they downright rejected the approach, even though they were not able to present any reasonable arguments to the contrary at that point. On the opposite, it triggered a wave of euphoria among dentists, who were willing to spend as much as 115,000 Deutsche Mark on the new laser, which translates to roughly the same amount in Euro or US-Dollar today. In Germany alone, more than 3,000 of these laser systems were sold over the course of about five years, most of which were not used properly, however, since no further training on how to use the devices on patients existed back then. In the US, the number of laser units sold even exceeded 5,000.

Fortunately, the advertised applications of this laser type have since been thoroughly investigated and today, they are not only an integral part of laser-supported endodontics, periodontics and minor oral surgery, but they were also the basis for the establishment of the various diode and erbium lasers used in dentistry. These days, we have access to a large number of different wavelengths from the most diverse laser manufacturers from all over the world and we are able to treat a wide variety of dental indications with them. The once small study clubs in North America, Europe, South America and Asia have evolved into recognised scientific societies, which today are all united in one global organisation—the ISLD (International Society for Laser Dentistry). Our upcoming ISLD World Congress, held in October 2020 in Cairo, Egypt, will certainly be a highlight that we—laser researchers, users and manufacturers alike—can already look forward to with great anticipation.

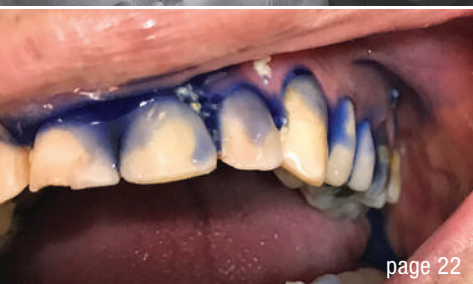With this in mind, I would like to wish you dear readers of our *laser—international magazine of laser dentistry* all the very best for the approaching holidays together with your loved ones and a happy and healthy start into the new year 2020.

Yours

Prof. Dr Norbert Gutknecht



page 16




page 22



page 34

Cover image courtesy of Fotona d.o.o.  
www.fotona.com  
Original Background:  
© Kamjana – stock.adobe.com



## editorial

- A **brief history** of dental lasers 03  
Prof. Dr Norbert Gutknecht

## research

- The diode laser in a fully **digital workflow** for **prosthetic** treatment 06  
Dr Carmine Prisco
- Innovative endodontics using **SWEEPS** technology 10  
Drs Giovanni Olivi & Matteo Olivi
- The **periodontal** pocket 16  
Dr Fabrice Baudot

## case report

- Laser-assisted** gingival **modification** of an edentulous site 20  
Dr Foteini Papanastasopoulou
- Treatment of a patient with **multiple myeloma** 22  
Drs Maziar Mir, Mina Mazandarani & Masoud Shabani

## industry

- Laser **protection** in the medial range 26
- Analysis** of the laser dentistry market 30  
Dr Dimitris Strakas

## practice management

- Successful **communication** in your **daily practice** 32  
Dr Anna Maria Yiannikos

## interview

- On challenges, **excellence** and **embracing** what once was 34

## events

- My **practice**, my **future**—current trends on trial 38  
Dr Stefan Grümer
- Master of Science course “**Lasers in Dentistry**” offered in 2020 39

## news

- manufacturer news 36
- news 40

## about the publisher

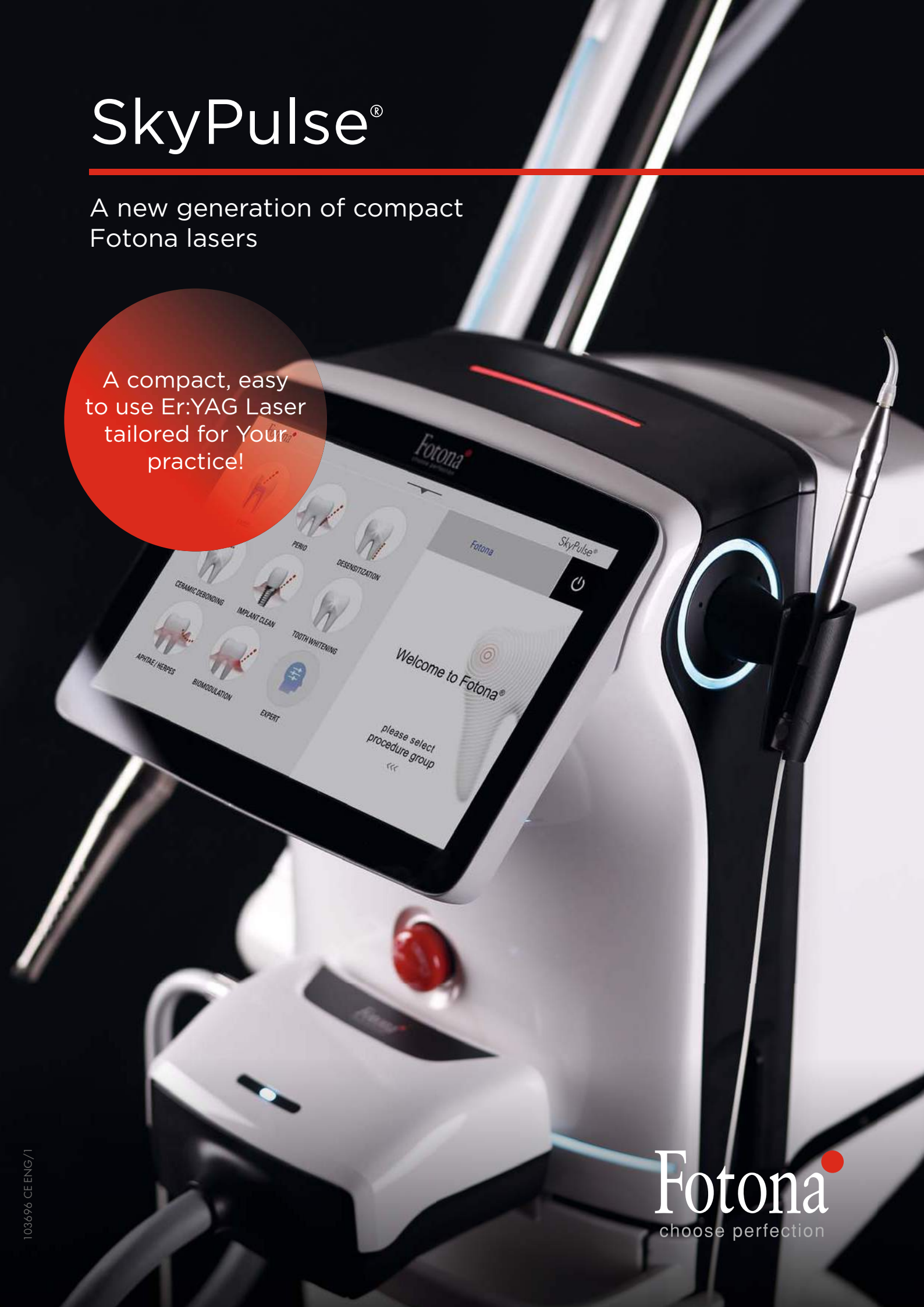- imprint 42



# SkyPulse®

A new generation of compact  
Fotona lasers

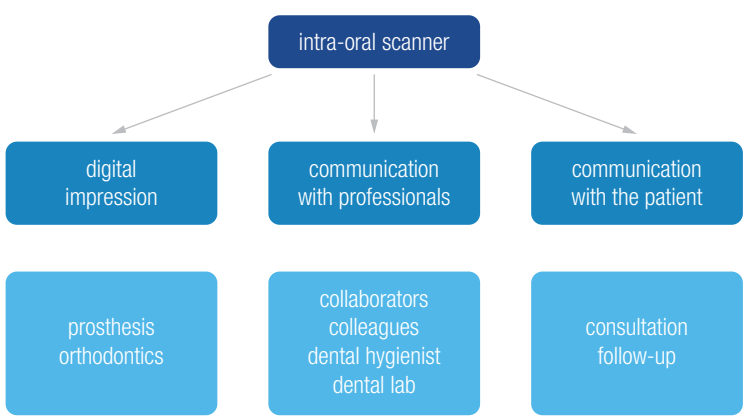
A compact, easy  
to use Er:YAG Laser  
tailored for Your  
practice!



Fotona®  
choose perfection

# The diode laser in a fully digital workflow for prosthetic treatment

Dr Carmine Prisco, Italy



the most widely used technology in the modern dental practice

Fig. 1: The intra-oral scanner is the most widely used technology in today's dental practice.

**Modern dentistry has undergone** an incredible evolution owing to the many new available technologies. The digital transformation and the technological evolution in dental surgery represent a very interesting opportunity for the modern dentist to develop his or her practice. Technologically supported dentistry is completely oriented towards patients' needs, well-being and comfort. Reduced treatment times, minimal invasiveness and better care with predictable results are the guiding principles.<sup>1</sup> A fully digital workflow in prosthetic dentistry

respects these principles. The purpose of this article is to show how the use of a diode laser can be integrated into the procedures of a fully digital workflow to make it more effective, simpler and faster.

The intra-oral scanner is the most widely used technology in the modern dental practice (Fig. 1) and its use is the first step to a fully digital workflow in prosthetic dentistry. The optical impression is used both for a virtual 3D diagnostic analysis of a dentition to plan a minimally invasive treatment<sup>2</sup> virtually and for taking impressions during the various phases of the digital workflow.<sup>3</sup> Transferring a correct impression to the laboratory is fundamental for the success of a prosthetic treatment, and the use of a diode laser is effective in obtaining a clearly readable impression. Versatility and simplicity of use make the diode laser particularly useful in digital prosthetic dentistry for the following: periodontal health, pre-impression troughing and haemostasis, minor pre-impression surgery and second-stage implant surgery.

## Periodontal health

Good periodontal health is an essential condition for any prosthetic treatment: the prosthetic patient always needs adequate periodontal pretreatment for a correct digital impression and for the full success of the therapy. While many laser-assisted therapeutic protocols have been reported in the literature, the laser-assisted full-mouth

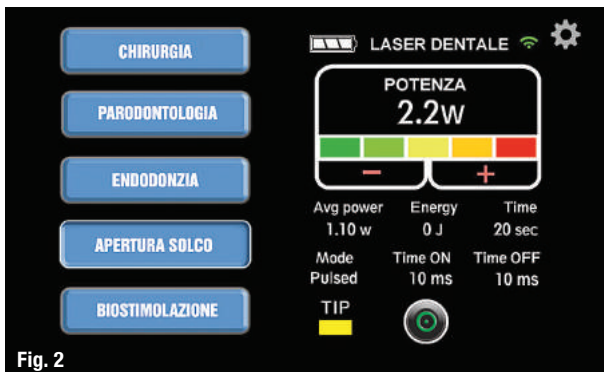

Fig. 2

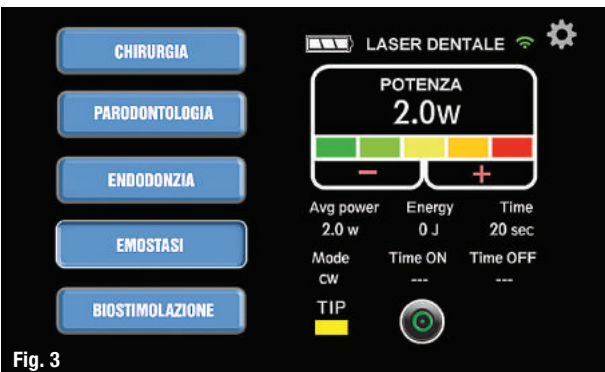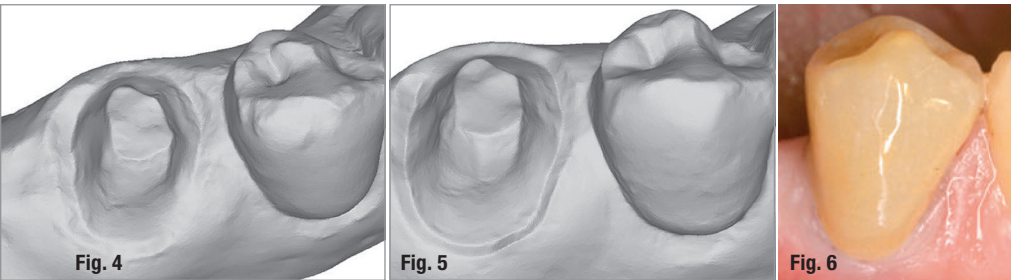


Fig. 3

Fig. 2: The settings of the 980nm diode laser used with single-use fibres. Fig. 3: The laser settings for completely drying the sulcus with a programme in continuous-wave mode.

shop online!

## Dental Laser Protection



**Figs. 4 & 5:** Comparison of the impression without and with treatment of the sulcus shows that the use of the diode laser yields a clearer and more defined impression. **Fig. 6:** There is no significant gingival retraction one year after crown positioning.

disinfection protocol<sup>1</sup> is the one used in our daily clinical practice and is naturally adapted to the patient's periodontal health status. In accordance with the guiding principles of technologically supported dentistry, our goal is to perform the tooth preparation and the optical impression in a single session. The absence of gingival inflammation is an essential condition. Therefore, a session of photodynamic and photothermic therapy a few days ahead is always recommended for a bactericidal effect. A 10% povidone-iodine solution is placed in the gingival sulcus before inserting the fibre of the laser (PRIMO, MEDENCY), employing a pulsed mode of 50 microseconds on and 50 microseconds off for 30 seconds at a power of 2W.

### Pre-impression troughing

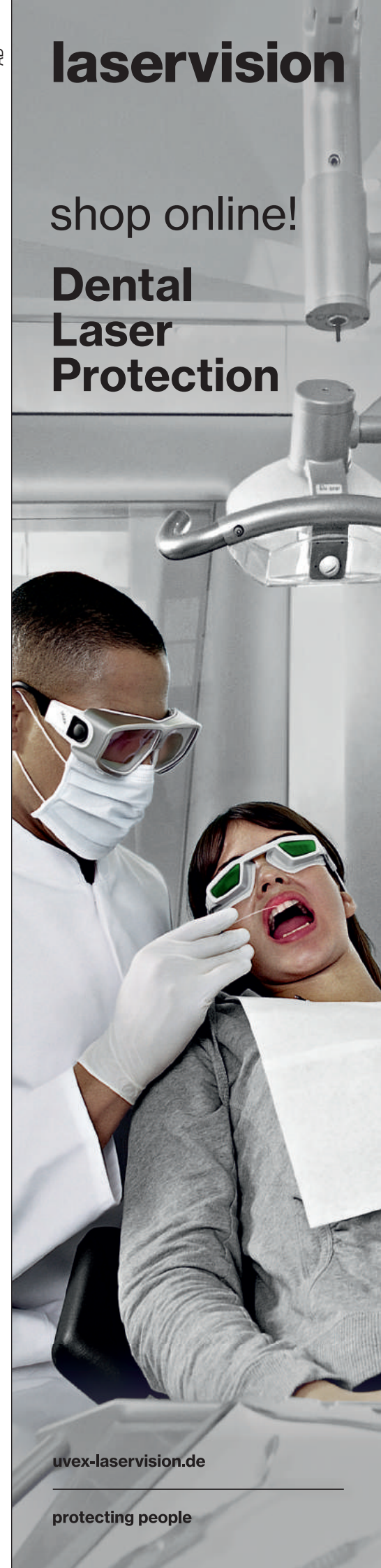Many tooth preparation systems for one-piece complete-coverage crowns, bridges<sup>4</sup> and veneers,<sup>5</sup> like vertical preparation without a finishing line, are discussed in the literature. In our clinical experience, in order to obtain a good optical impression, a simple principle of tooth preparation must be respected when using an intra-oral scanner: juxtapingival preparation in non-aesthetic areas whenever possible and minimal intra-sulcular preparation in aesthetically relevant areas. However, a minimal gingival displacement can help the dentist while taking the impression. Many studies on the evaluation of non-invasive gingival displacement systems are reported in the literature.<sup>6</sup> The diode laser can be used for gingival displacement. While techniques involving gingival retraction cords or a diode laser lead

to similar amounts of gingival retraction, use of the diode laser requires less time, is simpler for the operator and is more comfortable for the patient than are retraction cords.<sup>7</sup> Pre-impression taking with a diode laser does not create gingival retraction problems compared with use of a cord impregnated with aluminium chloride. The amount of recession has been reported as clinically insignificant for both techniques.<sup>8</sup>

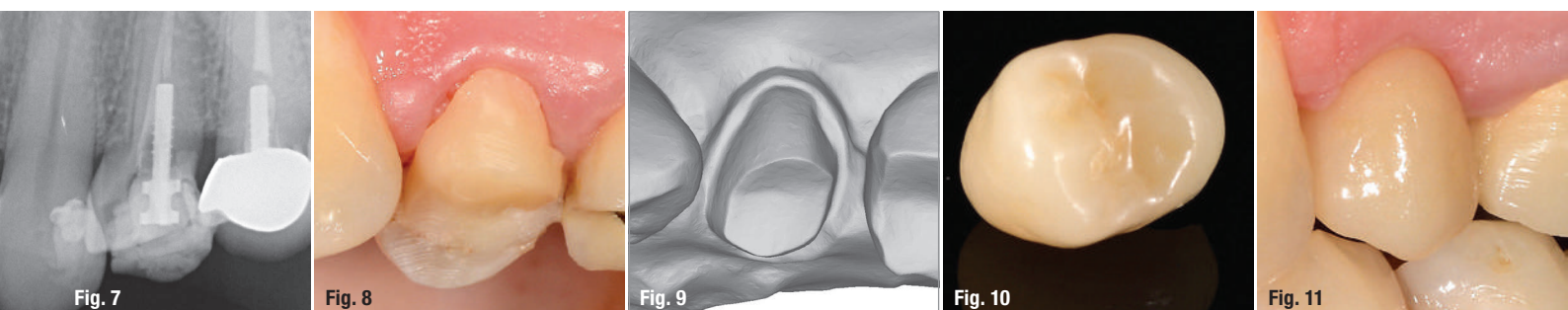
A 980nm diode laser is used with single-use fibres of 10mm and 400µ. The laser is set on a pulsed mode of 10 microseconds on and 10 microseconds off for 20 seconds at 2.2W (Fig. 2). A single rapid and gentle movement of the activated fibre in the gingival sulcus is sufficient to achieve the desired result. The optical impression is taken with the WOW intra-oral scanner (Biotech Dental). Sometimes, a haemostasis treatment may be recommended to achieve the complete drying of the sulcus with a programme in continuous-wave mode for 20 seconds at 2W (Fig. 3). Comparison of the quality of the impression without (Fig. 4) and with (Fig. 5) treatment of the sulcus showed that the use of the diode laser yielded a clearer and more defined impression. In accordance with the results reported in the literature,<sup>8</sup> there was no significant gingival retraction one year after crown positioning (Fig. 6).

### Minor pre-impression surgery

In some cases, minor gingival surgery is necessary for a good result of a prosthetic treatment. Modern dentistry, thanks to the use of advanced technol-







**Fig. 7:** The radiograph shows a subgingival partial fracture of a tooth which had undergone endodontic treatment at one time. **Fig. 8:** A diode laser can be used to remove excess gingival tissue and thereby bring the fracture margin outside the gingival sulcus. **Fig. 9:** Correct impression files need to be sent to the dental laboratory. **Fig. 10:** An all-zirconia crown was fabricated by Laboratoire LDA. **Fig. 11:** At the two-month follow-up visit, the results appeared stable in terms of the crown fit and gingival healing.

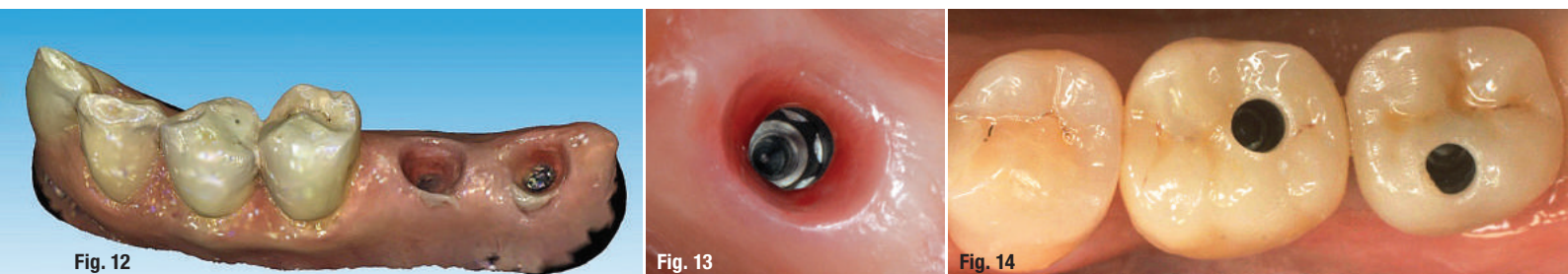ologies, makes it possible by reducing the number of sessions and the inconvenience to the patient. A classic case is a subgingival partial fracture of a tooth that had undergone endodontic treatment at one time (Fig. 7). After tooth reconstruction with a root fibre-reinforced post and composite, the use of a diode laser for minor surgical gingival correction is strongly recommended. The aim was to remove the excess gingival tissue and bring the fracture margin outside the gingival sulcus (Fig. 8). The laser is used with single-use fibres of 10mm and 400µ, and the programme is set to a pulsed mode of 25 microseconds on and 50 microseconds off, 6.5W and an average power of 2.17 W. Its cutting performance without oedema and with immediate coagulation allowed for preparation of the abutment and impression taking in the same session.

It is recommended to allow the gingival tissue to rest for 10–15 minutes between abutment preparation and impression taking. We use this time for the adaptation of a temporary crown. A correct temporary crown is necessary to gain good healing of the gingiva without retraction. Immediately before the impression taking, a haemostatic treatment with the laser allows the practitioner to obtain a clear and defined digital model, sometimes supported by the gentle use of an intra-oral scan powder spray. The WOW scan software immediately shows the STL and the PLY colour files. To send a correct im-

pression to the dental laboratory, analysis of the STL file is essential (Fig. 9). A week later, an all-zirconia crown (Laboratoire LDA; Fig. 10) was positioned on the dental abutment. The quality of the crown fit and of the gingival healing yielded a stable result at the two-month follow-up visit (Fig. 11). The dentist who uses a diode laser and an intra-oral scanner, and who is supported by a dental laboratory using a fully digital workflow, can solve similar cases in just two sessions.

## Second-stage implant surgery

The use of lasers for second-stage implant surgery is a widely discussed topic in the international literature. Implant surgery consists of two distinct techniques: the transmucosal one-stage technique and the two-stage technique. Diode lasers represent a good aid for the two-stage technique in implant dentistry, resulting in decreased trauma to bone and soft tissue, a reduction of pain, an immediate haemostatic effect and a reduction of the risk of postoperative infections. The effects of diode and Er,Cr:YSGG lasers in second-stage implant surgery applications were compared in a cross-sectional study, and the use of these two different lasers showed no statistically significant differences in clinical results.<sup>9</sup> Diode lasers are cheaper and smaller, and meet clinicians' needs, being their preferred choice for second-stage implant surgery. Another study showed that laser utilisation



**Fig. 12:** The laser allows immediate screwing of the scanbodies on to the exposed implants to obtain a correct digital model to be sent to the dental laboratory. **Figs. 13 & 14:** After successful healing of the gingiva, the healing screws can be removed and the crowns can be positioned.



with the recommended parameters yielded no risks of dangerous thermal elevation to the tissue and implants.<sup>10</sup> The laser is used with single-use fibres of 10mm and 400µ, and the programme is set to a pulsed mode of 1 microsecond on and 1 microsecond off, 1.6W and an average power of 0.8W. The protocol facilitates implant exposure and immediate optical impression taking in a single session.<sup>11</sup> The use of the laser, thanks to its immediate haemostatic effect, allows immediate screwing of the scanbodies on to the exposed implants to obtain a correct digital model to be sent to the dental laboratory (Fig. 12).

The choice of healing screw after the impression taking is essential to obtain an excellent final result. The Kontakt series of implants (Biotech Dental) has a wide range of healing screws, and the choice depends on the type of tooth to be replaced, on the condition of the gingiva and on the patient's occlusion. A week later, when the gingival healing was complete (Fig. 13), it was possible to remove the healing screws and to position the crowns. Two screw-retained single zirconia crowns on Ti-base abutments were produced by the laboratory, checked by the practitioner and then positioned in the patient's mouth. The occlusion, gingival health and points of contact were respected and the result was achieved in just two chair sessions (Fig. 14). The diode laser can be used effectively for second-stage implant surgery, providing both the dentist and the patient with additional advantages over the conventional methods used for implant exposure.<sup>12</sup>

## Conclusion

Modern dentistry is patient-centred in order to ensure maximal comfort to the patient throughout the whole treatment. Correct use of modern technologies to adequately address the patient's needs and expectations

through effective and high-quality therapies is the principle on which modern dentistry is founded. The goal is to achieve a minimally invasive treatment, which reduces the number and duration of chair sessions, overall duration of the treatment and inconvenience to the patient. Technology that is correctly chosen and employed represents a fundamental aid to achieving this desired result. The combined use of the diode laser in the ideal surgery and of the intra-oral scanner, supported by a specialist dental laboratory in a fully digital workflow, represents a way of achieving the aforementioned result in prosthetic dentistry.

## about the author



**Dr Carmine Prisco** is an oral surgeon from Italy. He specialises in conservative dentistry, implantology, prosthetics and laser dentistry. Dr Prisco practises in his private dental clinic in Salerno.

## contact

**Dr Carmine Prisco**  
Dental surgery clinic  
Salerno, Italy  
carmineprisco@hotmail.it

Author details




AD

# SUBSCRIBE NOW!

implants—international magazine of oral implantology

Interdisciplinary, transparent & market orientated



ONLINE  
SUBSCRIPTION HERE



www.oemus-shop.de

## Fax: +49 341 48474-290

I would like to subscribe for the following journals:

- ☐ implants—international magazine of oral implantology 4 issues p.a. € 44\*  
☐ ceramic implants—international magazine of ceramic implant technology 2 issues p.a. € 30\*

Last Name, First Name

Signature

Company

Terms & Conditions: The subscription may be cancelled in written form without due justification within 14 days of order by contacting OEMUS MEDIA AG, Holbeinstraße 29, 04229 Leipzig, Germany. Dispatching notification in good time will suffice. The subscription is automatically extended by another twelve months if it is not cancelled in written form 6 weeks prior to the end of the reference period.

Street

Stempel

ZIP, City, Country

E-mail

Credit Card Number

Expiration Date

Security Code

Holbeinstraße 29 · 04229 Leipzig · Germany · Phone: +49 341 48474-315 · grasse@oemus-media.de

OEMUS MEDIA AG

\* All prices include VAT, shipping and handling.

laser 4/19