

# CAD/CAM

international magazine of digital dentistry



## special

Occlusion principles for the practising dentist in the digital age

## case report

Guided implant placement in the anterior zone

## cone beam supplement

Dynamic navigation—The future of minimally invasive endodontics

# IT'S TIME FOR TRUE LOW DOSE CBCT

X MIND  
trium

50%

dose reduction\*  
without compromising  
3D image quality

3D

mapping of bone  
density for improved  
success rate

75µm

ultra high resolution  
image for reliable diagnosis



\*Ratio based on DAP measurements from standard X-Mind Trium settings 90kV-8mA-300prjs

X-Mind® trium, 3-in-1 extraoral imaging system (CBCT 3D, Panoramic and Cephalometric). This medical device is a class IIb device according to the applicable European Directive in force. It includes CE marking. Notified body: DNV GL NEMKO PRESAFE AS - CE 2460. This medical device for dental care is reserved for healthcare personnel; it is not covered by health insurance providers. This equipment was designed and manufactured in accordance with an EN ISO 13485-certified quality assurance system. Please read the user guide carefully. Manufacturer: de Götzen - a Company of ACTEON Group  
For dental professional use only.

DE GOTZEN® | A Company of ACTEON® Group  
Via Roma 45 | 21057 Olgiate Olona VA |  
Tel + 33 39 0331 376760 | Fax + 39 0331 376763  
E-mail: [info@acteongroup.com](mailto:info@acteongroup.com) | [www.acteongroup.com](http://www.acteongroup.com)



Magda Wojtkiewicz

Managing Editor



# Artificial intelligence in your daily practice—Are we already there?

**The Oxford English Dictionary** defines artificial intelligence (AI) as “the theory and development of computer systems able to perform tasks normally requiring human intelligence, such as visual perception, speech recognition, decision-making, and translation between languages”. But what does AI mean, really? And how can this tech trend affect the dental practice?

Only a few years ago, AI was considered to be pure science fiction, and nobody was really considering the possibility of using it in the dental office. Today, AI is found everywhere in consumer technology—many of us can find it in our own smartphones—and is also present in the dental office, as was shown at the International Dental Show in Cologne in Germany in March this year.

Let's consider a few examples of the use of AI in dentistry. Algorithms support computed tomography (CT) diagnostic tools such as the one from Diagnocat (which we covered in **CAD/CAM** 1/2019). Diagnocat uses multiple algorithms, which turn raw outputs from the neural nets into reports and imagery that are easy for dentists to understand. In this software, AI analyses 3D dental studies in DICOM format. The innovative solutions of Diagnocat save a dentist effort and time when analysing CT images and allow him or her to concentrate on treatment, offer-

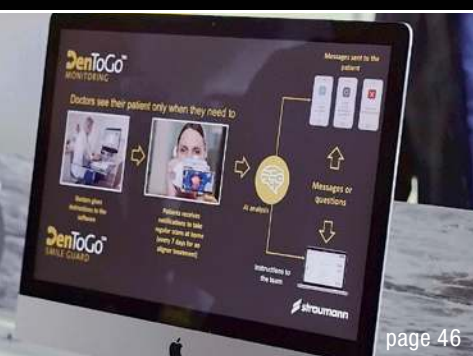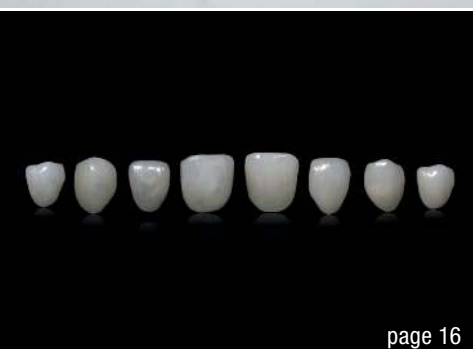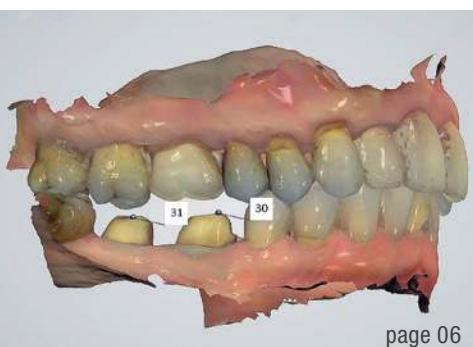ing the patient the best solution and retaining control of the outcome.

Straumann uses AI to simulate treatment outcomes, and this can be highly effective in motivating patients to comply with treatment. In the new DenToGo, a comprehensive suite of AI-based software solutions for tablets and smartphones, not only is patient choice facilitated by prior simulation, but progress is monitored and documented throughout the treatment period.

Artificial intelligence is also used in digital smile design and there are already applications available to help practitioners choose the best smiles for their patients.

I am quite sure that this is only the beginning of a new era in dentistry. However, at the end of the day, AI is only a branch of computer engineering, designed to create machines that behave like humans. Although it has come far in recent years, AI still lacks an essential aspect of human behaviour, namely human emotion. And dentistry is so much more than just analysing the data (although that is very helpful); it is about bringing healthy smiles to patients.

Magda Wojtkiewicz  
Managing Editor



Cover image courtesy of DGSHAPE Corp.  
www.dgshape.com



## editorial

- Artificial intelligence** in your daily practice—**Are we already there?** 03  
Magda Wojtkiewicz

## special

- Occlusion principles** for the practising dentist **in the digital age** 06  
Drs Michael Radu, Daniel Radu & Florin Lazarescu

## clinical report

- Digital face-bow transfer technique** using the dentofacial analyser for dental aesthetics and 2D, 3D smile design: A clinical report 16  
Drs Christian Brenes, Larry Jurgutisb & Courtney S. Babba

## case report

- Computer-aided**, template-guided **immediate implant placement** and loading in the mandible 22  
Drs Thomas Spielau, Uli Hauschild & Joannis Katsoulis

- Guided implant placement** in the **anterior zone** 30  
Drs Burzin Khan & Purvi Bhargava

- Immediate loading** of a socket shield (partial extraction therapy) post-extraction **implant with the final CAD/CAM crown** 36  
Drs Filipe Lopes, Bernardo Mira Corrêa & Maurice A. Salama

## cone beam supplement

- Dynamic navigation**—The future of minimally invasive **endodontics** 42  
Dr Kenneth S. Serota

## trends & applications

- Digital ecosystem:** The future is not in five years, **the future is now** 46  
Simone Matt

## manufacturer news

## interview

- “DTX Studio suite** really can be used **on a daily basis”** 54  
Interview with Dr Pascal Kunz, Vice President of Digital Solutions at Nobel Biocare

## meetings

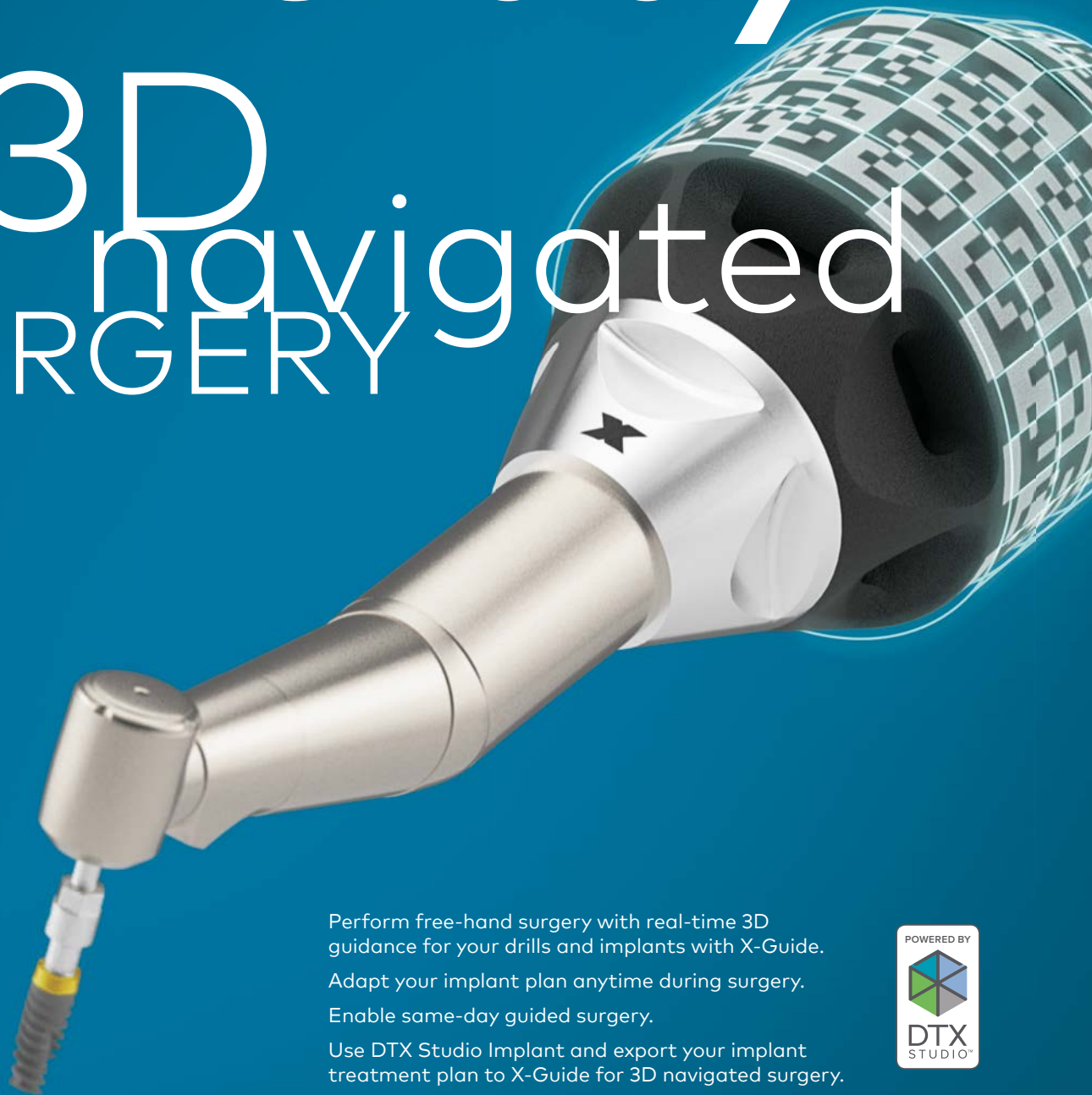
- Dentsply Sirona World 2019** **fast approaching** 56  
International events 58

## about the publisher

- submission guidelines 60  
international imprint 62



# Same-day 3D navigated SURGERY



Perform free-hand surgery with real-time 3D guidance for your drills and implants with X-Guide.

Adapt your implant plan anytime during surgery.

Enable same-day guided surgery.

Use DTX Studio Implant and export your implant treatment plan to X-Guide for 3D navigated surgery.

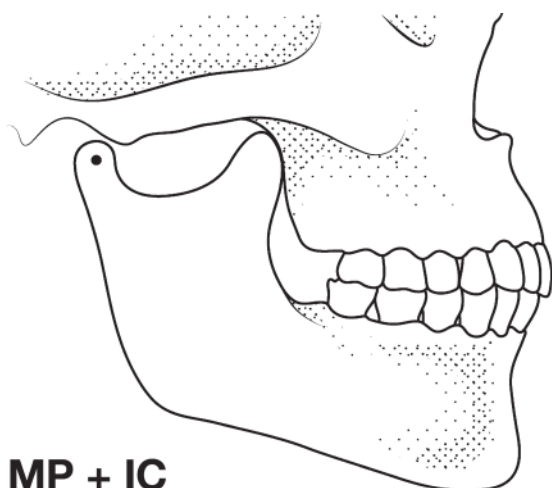


[nobelbiocare.com/x-guide](https://nobelbiocare.com/x-guide)

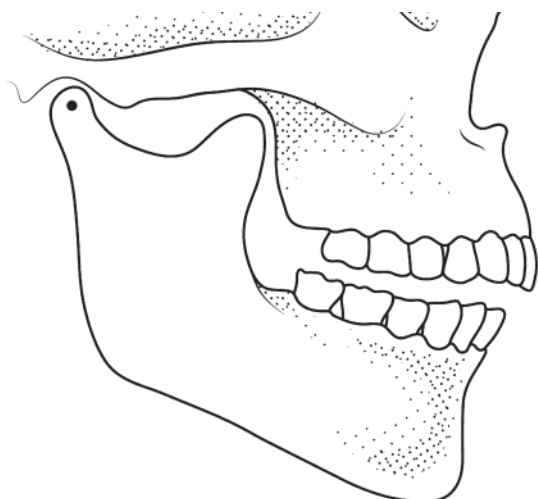
GMT 63673 GB 1907 © Nobel Biocare Services AG, 2019. All rights reserved. Distributed by: Nobel Biocare. X-Guide is either registered trademark or trademark of X-Nav Technologies, LLC in the United States and/or other countries. Nobel Biocare, the Nobel Biocare logotype and all other trademarks are, if nothing else is stated or is evident from the context in a certain case, trademarks of Nobel Biocare. Please refer to [nobelbiocare.com/trademarks](https://nobelbiocare.com/trademarks) for more information. Product images are not necessarily to scale. All product images are for illustration purposes only and may not be an exact representation of the product. Disclaimer: Some products may not be regulatory cleared/released for sale in all markets. Please contact the local Nobel Biocare sales office for current product assortment and availability. For prescription use only. Caution: Federal (United States) law restricts this device to sale by or on the order of a licensed clinician, medical professional or physician. See Instructions For Use for full prescribing information, including indications, contraindications, warnings and precautions.

# Occlusion principles for the practising dentist in the digital age

Drs Michael Radu, Daniel Radu, USA & Florin Lazarescu, Romania



**Fig. 1:** Mandibular position with condyles seated in the fossae and no intercuspation.



**Fig. 2:** Mandibular position with condyles down the eminence and maximal intercuspation.

## Introduction: What do dentists want to know about occlusion?

Occlusion may appear complicated because of the multiple factors involved, such as teeth, muscles and the temporomandibular joints (TMJs). It can also be confusing, owing to imprecise terminology and philosophies of occlusion.<sup>1</sup>

Philosophical disagreements have led to most of the confusion and resulted in several controversies. There is no consensus in the areas of diagnostic and treatment goals for occlusion.<sup>2-4</sup> This relates to a lack of agreement about the most physiological or functional mandibular position.<sup>5,6</sup> Subsequently, the methods used to find such a mandibular position vary greatly. The techniques for interocclusal recordings are not standardised<sup>7</sup> and they include the use of wax, polyvinylsiloxane and computerised recordings.<sup>8,9</sup>

Practising dentists are focused on how to plan a treatment and treat a patient, and occlusion is regarded as only a means to an end. Most dentists want to use simple, well-established and commonly accepted best clinical practices. Most dentists want to know how to record the bite for the laboratory.

Therefore, the purpose of this article is to clarify dental occlusion for practical clinical applications. First, the authors will propose a practical approach to occlusion based on three concepts: intercuspation, mandibular position and occlusal stability. Second, the authors will present a clinical decision guideline for occlusal recordings to use in daily practice. Third, the authors will present and compare the analogue and digital methods of occlusal recordings, placing emphasis on how to find and record centric relation.

## A practical approach to occlusion

**The concepts of intercuspation and mandibular position**  
All occlusal recordings are done at the tooth level. It appears that the recorded relationship is between the maxillary and mandibular teeth. Because the maxillary arch is fixed, the only variable is the position of the mandibular teeth. In a further analysis, the only variable is the position of the mandible. Therefore, occlusal recordings are inter-arch relationships at the tooth level.

“Occlusion” is defined in the ninth edition of the *Glossary of Prosthodontic Terms* (GPT-9) as: “the act or process of closure” and “the static relationship between the incis-ing or masticating surfaces of the maxillary or mandibular teeth or tooth analogues”.<sup>10</sup> Since the process of closure

is of the mandibular teeth on to the maxillary ones, applying deductive reasoning, one can surmise that occlusion has two components mandibular position (MP) and intercuspatation (IC). Any IC is always associated with an MP (Figs. 1 & 2). Occlusion is an MP when the teeth intercusate. We can express it with a mathematical formula: **occlusion = MP + IC**.

#### The concept of stability of occlusion

Like any natural system, occlusion seeks stability, which is accomplished through stability of the mandible. This may be obtained through a stable IC, sometimes named intercuspal position or maximal intercuspal position, and/or musculoskeletal stable joints (condylar position on the eminence).<sup>11,12</sup> The GPT-9 describes "occlusal stability" as "the equalisation of contacts that prevents tooth movement".<sup>10</sup> The authors refer here to the broader concept of the stability of occlusion as a total system.

McNeill describes three stable reference positions that may be used: intercuspal position, myocentric relation and centric relation.<sup>13</sup> In many clinical situations, the existing IC is widely accepted as a stable MP. Another stable reference position is centric relation (CR), which is a condylar-determined MP. CR is a stable musculoskeletal position of the condyles on the articular eminence or a condylar position. To be maintained, it has to be in harmony with a stable IC.<sup>29</sup>

Let us analyse the MP concept further. Three non-colinear points, that is, that are not on the same straight line, can define the position in space of any solid object (Fig. 3). For increased precision, it is advantageous to select points as far apart as possible. The two condyles (first and second points) and the incisal point (third point) can define the position in space of the mandible relative to the anatomical structure of the maxilla/articular eminences (Fig. 4). The position of the condyles on the articular eminences can be defined as condylar position (CP). One stable CP, which is widely accepted, is CR. The position of the mandibular incisal point relative to the maxilla can be defined as the vertical dimension of occlusion (VDO). Using a mathematical formula: **MP = CP + VDO**. Therefore, the occlusion formula becomes (Fig. 5): **occlusion = CP + VDO + IC**.

These are the three variables we need to operate with, and these simplify occlusion by making it practical. Here are the clinical situations to which we can apply these simple occlusal rules.

When we decide to work with what is there, we accept the existing occlusion as functional; we accept the existing IC, but also the VDO and the CP as functional and acceptable for clinical use. When the MP is acceptable, it is irrelevant for that case; it can be considered to be zero, so the formula becomes: if **MP = 0**, then **occlusion = IC**.

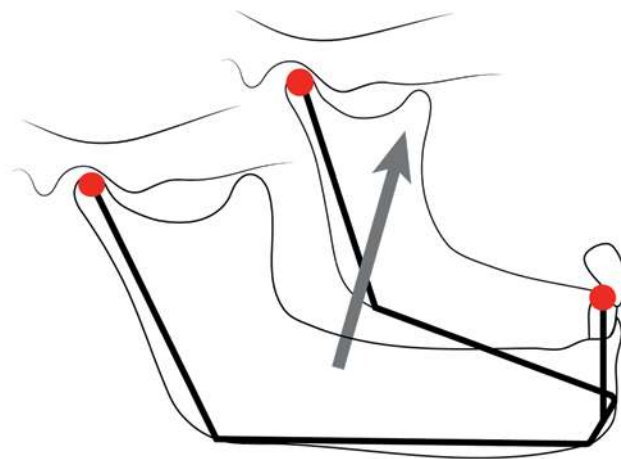


Fig. 3: A drawing of the mandible, anterior teeth and fossae, showing a reversed tripod.

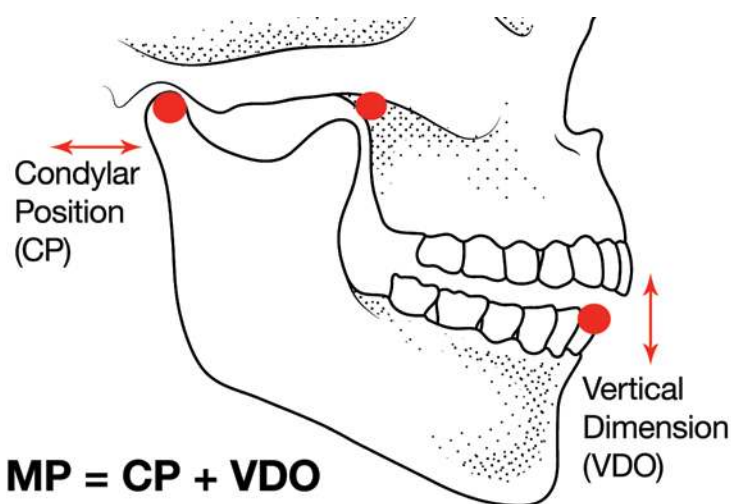


Fig. 4: Mandibular position defined as condylar position and vertical dimension of occlusion.

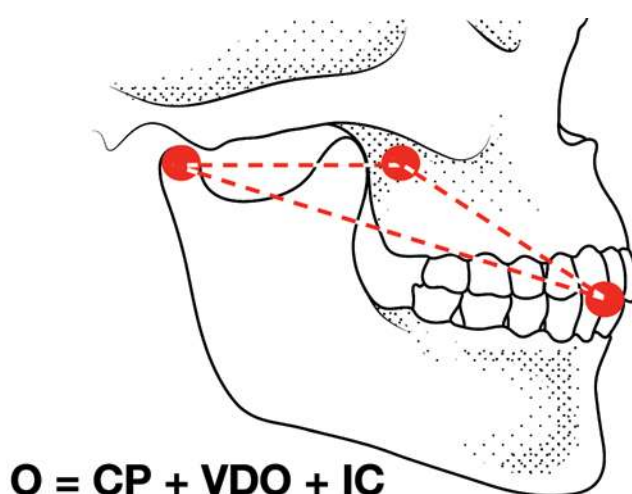
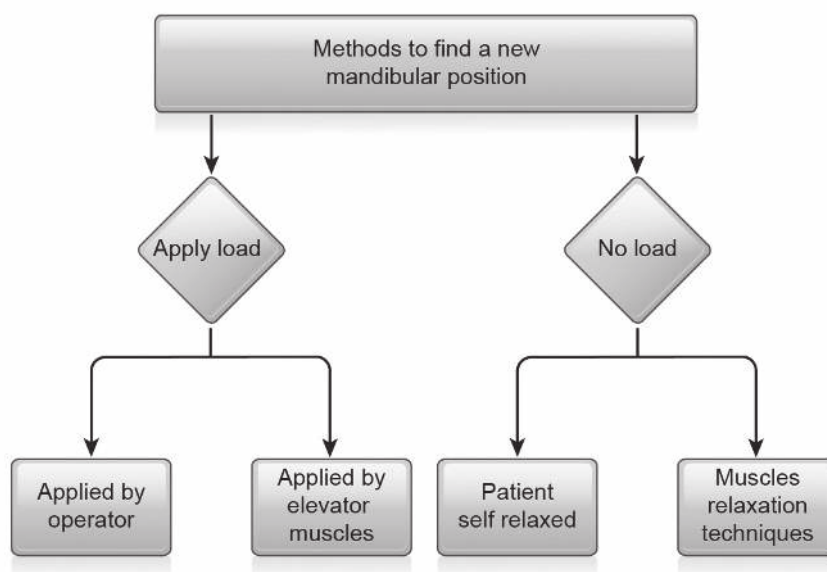


Fig. 5: Occlusion represented as mandibular position and intercuspatation.



**Fig. 6:** Methods to find a new mandibular position.

When we decide to change the existing occlusion, or we do not have one at all (as in edentulous situations), we have to take all three variables into account. In general, all occlusal philosophies agree that VDO can be increased within the rotational movement of the condyles for aesthetic, functional and restorative purposes. The main differences in occlusal philosophies are related to the CP. The question becomes: what is an acceptable, physiological and long-term functional CP on the eminence? In other words: in what CP and VDO shall we create the new IC?

### The case for a stable condylar position (centric relation)

In a stable occlusion, the IC guides the mandible in the same position repeatedly through muscle memory. When the IC is absent, the muscles may position the mandible in an endless number of positions, making

reproducibility and stability a concern. Asking the patient to close in a “comfortable” position is an unpredictable means of finding a new MP.<sup>14</sup>

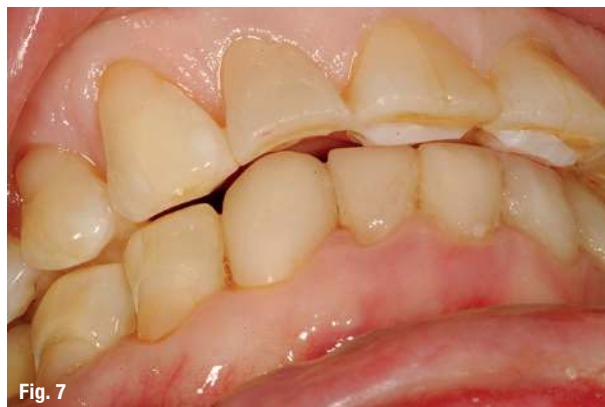When the IC is absent, or the dentist decides to change it, the stability of the mandible has to be established with the help of the condyles and the VDO. The authors will make the case that the desired CP should be CR.

To determine a stable CP, we have two main options: to load or not to load the joints. It may appear that non-loaded, relaxed muscles is preferable. We want the patient to feel good and be relaxed, rather than forced into a particular position. However,

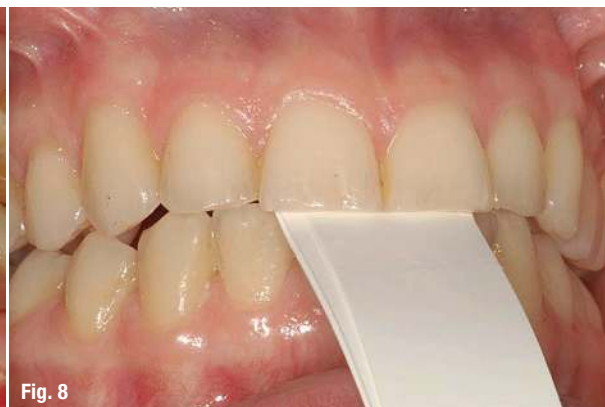there are inherent problems with relaxed, non-loaded positions:

- Relaxed positions can be in a large variety of CPs.
- Relaxed positions are very tricky to record—when we interpose a recording medium, the position may change.
- Most importantly, function and parafunction happen with contracted muscles and not in a relaxed position.

In healthy joints, loading creates a physiological, orthopaedically correct, predictable and reproducible CP.<sup>11</sup> Loading is actually a test of the health of the joints. There are two main ways to apply loading to the condyles: the bimanual manipulation technique<sup>5</sup> and the anterior obstacle technique.<sup>14–16</sup> The obstacle can be a leaf gauge, an anterior deprogramming device or a composite resin device. The anterior obstacle technique relaxes the lateral pterygoid muscles and positions the condyles in CR by contracting the elevator muscles (Fig. 6). These techniques are well documented and relatively easy to use.<sup>18,19</sup>



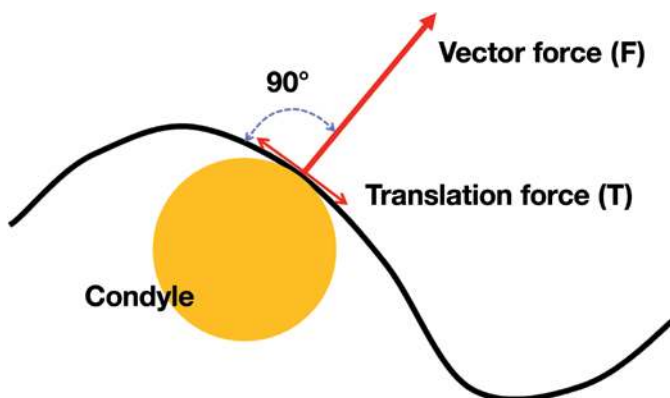
**Fig. 7**



**Fig. 8**

**Fig. 7:** Composite resin device creating a disclusion of posterior teeth. **Fig. 8:** Leaf gauge creating a disclusion of posterior teeth.





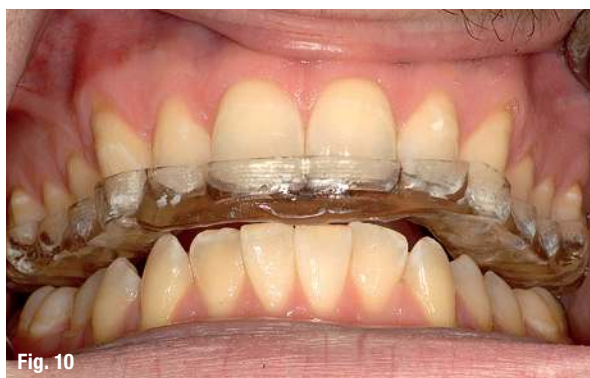**Fig. 9:** The condyle position is based on the vector of force of the elevator muscles—perpendicular to the contour of the eminence.

When we accept CR as the stable CP, the MP formula becomes:  $MP = CR + VDO$ . Therefore, the occlusion formula becomes:  $occlusion = CR + VDO + IC$ .

When coupled with an anterior permissive obstacle of an adjustable size, such as a leaf gauge or a composite resin device, the mandible can simultaneously be placed at the desired VDO too (Figs. 7 & 8).

The bimanual manipulation technique is difficult to master and the mandible is difficult to stabilise, needing an interposed medium. The anterior obstacle technique is easier and allows the patient to find the individual CP on the eminences, based on the direction of the vector of force of the elevator muscles (Fig. 9).<sup>20</sup>

When patients exhibit tension, tenderness or pain upon loading the joints, a complete TMJ examination, both clinical and paraclinical (radiographs and MRI), needs to be done and a diagnosis needs to be established. The consensus of the literature is that a change in occlusion shall be done only after the joint and muscle issues have been resolved. In most cases, periodically adjusted



**Fig. 10**

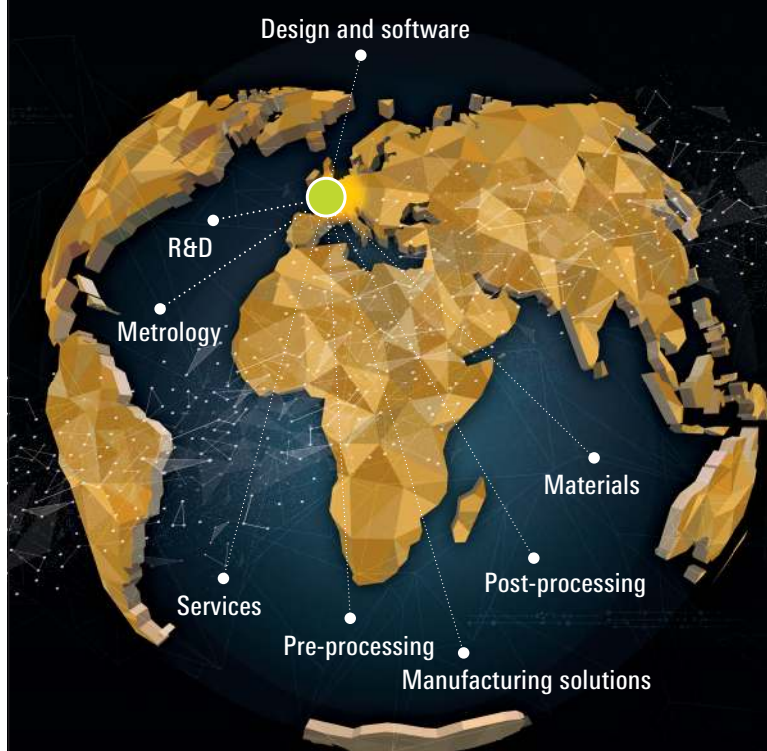**Fig. 10:** A complete-coverage occlusal device to relax the muscles and heal the joints.

# formnext

International exhibition and conference  
on the next generation of manufacturing technologies

Frankfurt, Germany, November 19 – 22, 2019  
formnext.com

## The entire world of additive manufacturing



Additive manufacturing surrounds a whole world of processes.  
Instead of a world tour you only need one ticket – for Formnext!

**Where ideas take shape.**



Official event hashtag #formnext

**mesago**

Messe Frankfurt Group