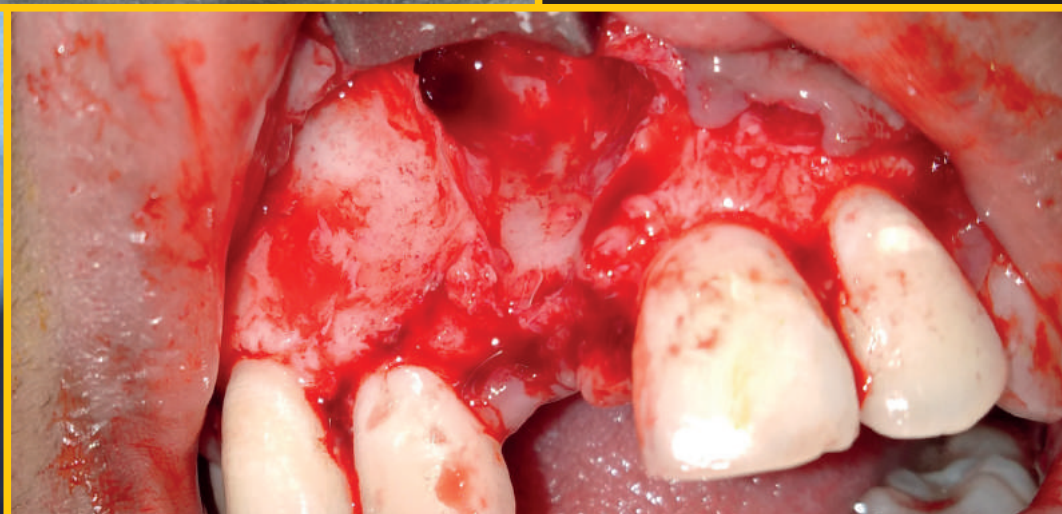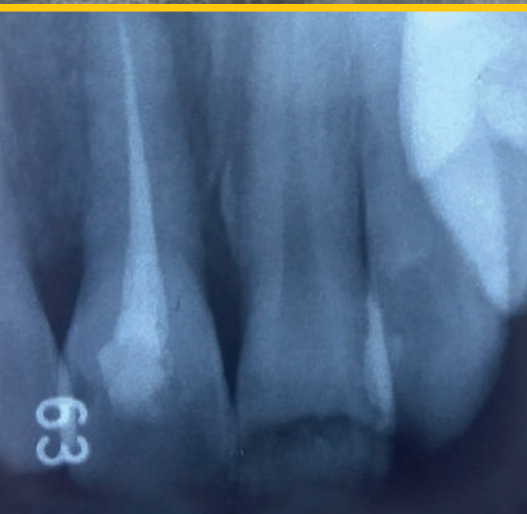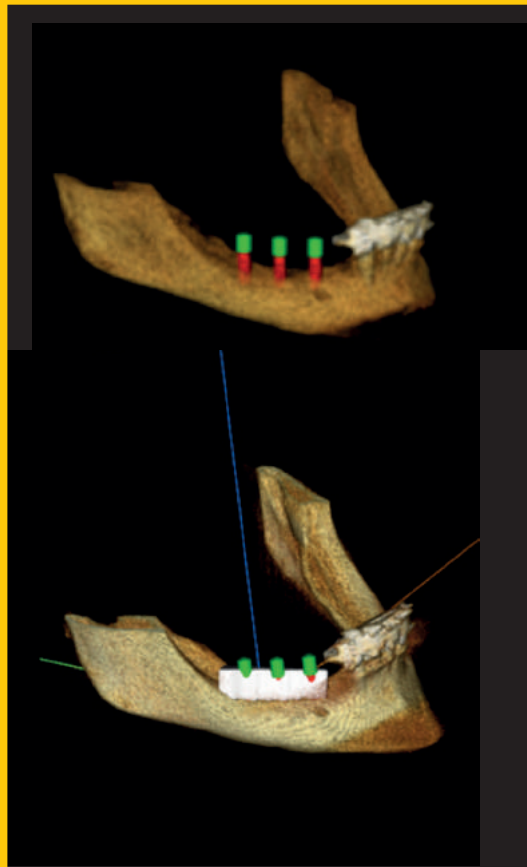


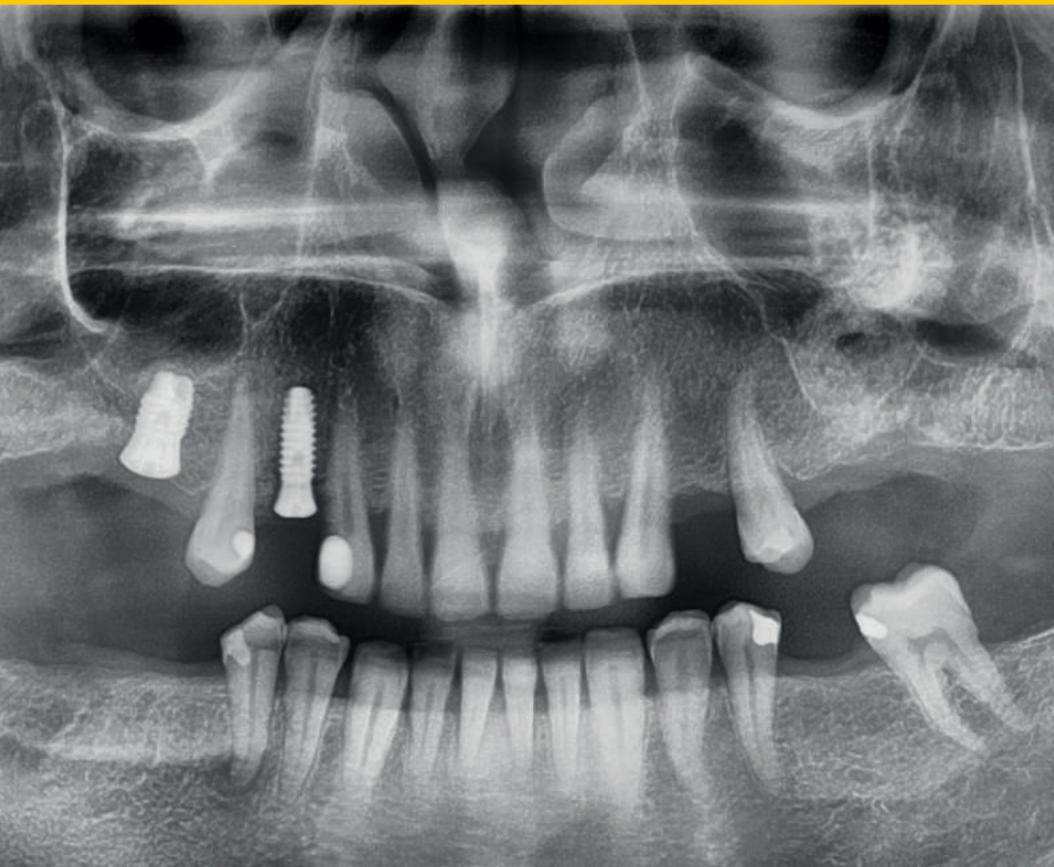Journal of Oral Science & Rehabilitation

Journal for periodontology, implant dentistry,
dental prosthodontics and maxillofacial surgery



IT'S SIMPLE TO BE A WINNER



PROVEN SUCCESS MEETS ENHANCED STABILITY

The biological stability and predictable esthetics of the SEVEN, combined with the extensive research and development process have given the SEVEN a potential advantage in soft tissue preservation and growth as well as an array of restorative benefits. Learn more about the SEVEN implant system and MIS at: www.mis-implants.com

mis[®]
SEVEN[®]



Dentistry, *quo vadis*?

As a professional who has devoted my life to dentistry, treating patients, teaching at a university and contributing to my branch of science, I am growing older, gaining experience and analyzing things from different perspectives. After reflecting on and evaluating my more than 25 years of clinical practice, my role as a teacher and mentor to many students, and my current knowledge, I wonder where to from here.

The knowledge in dentistry is changing rapidly based on different premises. The academic institution has made it clear that randomized clinical trials and meta-analyses are at the top of the pyramid of scientific knowledge. There are some journals that rarely accept a manuscript that does not have in its title the magic words “randomized clinical trial”; yet, there are thousands of systematic reviews and meta-analyses on any meaningless aspect of the literature, meta-analysis based only on those randomized clinical trials. Sometimes, journals publish some meta-analyses based only on one or two manuscripts, which is simply a repetition of the same conclusion of the manuscript. Interestingly, there is even a coincidence in the authorship of both manuscripts, a kind of misconduct in science.


When analyzing the bibliometric aspects of our science, in the context of science, dentistry is almost nothing in comparison with other disciplines; it is like a small star in the Milky Way. However, we are trying to resemble the disciplines of older brothers, forgetting the strength of our own science. As dentists, we are required to contribute the best for patients, reinforcing clinical aspects, based on knowledge and evidence. We are health care providers. Our editors, journals and reviewers, and we ourselves must become aware of this, support deeper clinical research that undoubtedly contributes to better feedback in all fields for our patients and avoid many of those manuscripts that are only aimed at greater impact factors, *h*-indexes or citations, increasing the ego and visibility of some authors and institutions, with no benefit for the real readers of our journals and the final destination of our research: our patients.

As a professor, as a researcher, assuming my share of *mea culpa*, I begin to be fed up with diving into the literature looking for important manuscripts that bring light and knowledge to our community, but remaining unsatisfied. I begin to wonder, dentistry, *quo vadis*?

Dr. Pablo Galindo Moreno
Associate editor and scientific adviser

Contents

- 3 Editorial**
Dr. Pablo Galindo Moreno
- 6 About the Journal of Oral Science & Rehabilitation**
- 8 María Sevilla Heras et al.**
Subcutaneous emphysema after a direct sinus lift: A case report
- 14 Farah Asa'ad et al.**
Digital bone augmentation in posterior mandibles: A retrospective CBCT study and proposal of a 2-step bone augmentation protocol
- 26 Min Jim Lim et al.**
Autotransplantation: Salvaging an odontoma-associated unerupted anterior tooth
- 34 Nabi Nabiev et al.**
Evaluation of the muscular activity and myodynamic balance in children with physiological dental occlusion
- 44 Guidelines for authors**
- 46 Imprint — About the publisher**



Dental Tribune International

The World's Dental Marketplace

www.dental-tribune.com

dti] Dental
Tribune
International

About the Journal of Oral Science & Rehabilitation

The aim of the *Journal of Oral Science & Rehabilitation* is to promote rapid communication of scientific information between academia, industry and dental practitioners, thereby influencing the decision-making in clinical practice on an international level.

The Journal of Oral Science & Rehabilitation publishes original and high quality research and clinical papers in the fields of periodontology, implant dentistry, prosthodontics and maxillofacial surgery. Priority is given to papers focusing on clinical techniques and with a direct impact on clinical decision-making and outcomes in the above-mentioned fields. Furthermore,

book reviews, summaries and abstracts of scientific meetings are published in the journal.


Papers submitted to the *Journal of Oral Science & Rehabilitation* are subject to rigorous double-blind peer review. Papers are initially screened for relevance to the scope of the journal, as well as for scientific content and quality. Once accepted, the manuscript is sent to the relevant associate editors and reviewers of the journal for peer review. It is then returned to the author for revision and thereafter submitted for copy editing. The decision of the Editor-in-Chief is made after the review process and is considered final.

About Dental Tribune Science

Dental Tribune Science (DT Science) is an online open-access publishing platform (www.dtscience.com) on which the *Journal of Oral Science & Rehabilitation* is hosted and published.

DT Science is a project of the Dental Tribune International Publishing Group (DTI). DTI is composed of the leading dental trade publishers around the world.

For more, visit → www.dental-tribune.com



Benefits of publishing in the journal for authors

There are numerous advantages of publishing in the *Journal of Oral Science & Rehabilitation*:

- Accepted papers are published in print and as e-papers on **www.dtscience.com**; abstracts are published on **www.dental-tribune.com**.
- Authors' work is granted exposure to a wide readership, ensuring increased impact of their research through open-access publishing on **www.dtscience.com**.
- Authors have the opportunity to present and promote their research by way of interviews and articles published on both **www.dtscience.com** and **www.dental-tribune.com**.
- Authors can also post videos relating to their research, present a webinar and blog on **www.dtscience.com**.

Subscription price

€50.00 per issue, including VAT and shipping costs.

Information for subscribers

The journal is published quarterly. Each issue is published as both a print version and an e-paper on **www.dtscience.com**.

Terms of delivery

The subscription price includes delivery of print journals to the recipient's address. The terms of delivery are delivered at place (DAP); the recipient is responsible for any import duty or taxes.

Copyright © Dental Tribune International GmbH. Published by Dental Tribune International GmbH. All rights reserved. No part of this publication may be reproduced, stored or transmitted in any form or by any means without prior permission in writing from the copyright holder.

Subcutaneous emphysema after a direct sinus lift: A case report

María Sevilla Heras,^a

Luis Martorell Calatayud,^a

Regino Zaragoza Alonso^a &

Miguel Peñarrocha Diago^a

^a Department of Stomatology, Faculty of Medicine and Dentistry,
University of Valencia, Valencia, Spain
Department of Oral Surgery and Implantology

Corresponding author:

Dr. Luis Martorell Calatayud

Universidad de Valencia

Facultad de Medicina y Odontología

Clínica Odontológica. Cirugía bucal

C/ Gascó Oliag, 1

46021 Valencia

Spain

luismartorell@hotmail.com

How to cite this article: Sevilla Heras M, Martorell Calatayud L, Zaragoza Alonso R, Peñarrocha Diago M. Subcutaneous emphysema after a direct sinus lift: A case report. J Oral Science Rehabilitation. 2019 Jun;5(2):8–13.

Materials and methods

A 52-year-old patient underwent a maxillary direct sinus lift for the future placement of implants in the posterior area. A few hours after the surgery, the patient repeatedly sneezed with his mouth closed 3 times, immediately causing a large swelling in the left periorbital area that prevented him from opening the eye. After clinical and radiographic examination, it was determined that it was a subcutaneous emphysema. The prescribed treatment was antibiotics.

Conclusion

Subcutaneous emphysema is a benign and usually self-limited entity, which usually resolves spontaneously. Most authors agree on the use of turbines as the most frequent etiology. Other reasons, however, have also been reported in the literature, such as endodontic treatment and the use of dental lasers. The main clinical manifestations that aided us in establishing a correct differential diagnosis were swelling without redness, edema and crepitating palpation of the soft tissue. In general, patients do not report pain, but at worst a slight discomfort due to swelling.

Keywords

Subcutaneous emphysema; periorbital edema; orbital emphysema; complications; sinus floor elevation.

Abstract

Objective

Subcutaneous oral emphysema is defined as penetration of pressurized air into the tissue spaces. One possible means of air entry is through the bone window made during a direct sinus lift. There are only 3 cases published in the literature of subcutaneous emphysema with this etiology. It is important that the dentist carefully instruct the patient about the post-surgical protocol that must be carried out to reduce the risk of this complication.

Introduction

Subcutaneous emphysema is defined as the penetration of air pressure into tissue spaces.^{1–8} It is a complication that has been described in the literature for many years. In 1995, Heyman and Babayof reviewed the literature from 1960 to 1993 on emphysematous complications in dental treatment.¹

Subcutaneous emphysema does not occur regularly, but it is important to control to avoid complications such as infections that can be harmful to the patient.⁹

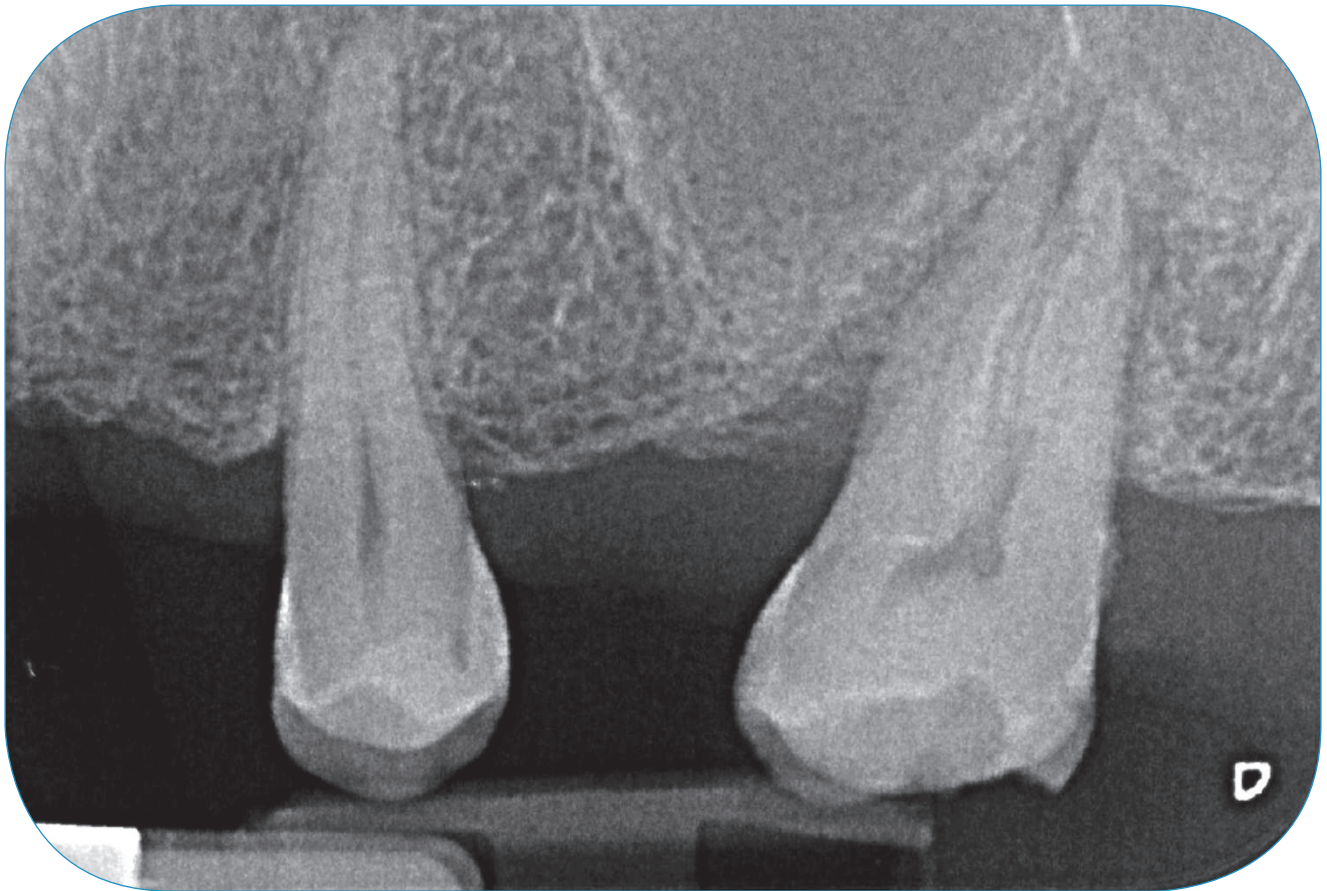


Fig. 1

The condition is usually the result of treatment with high-speed surgical drills and compressed air syringes during restorative and endodontic procedures.⁵ However, in the present case, periorbital edema was observed after several hours of a sinus floor elevation, which makes this case report interesting. There are not many cases reported in the literature about this etiology, which is mostly related to post-surgical maneuvers of the patient (sneezing while keeping the mouth closed, blowing the nose, playing wind instruments).¹⁰ The objective of this clinical case is to demonstrate to oral and maxillofacial surgeons the possibility of orbital and periorbital emphysema after an intervention in the maxillary sinus, as well as the procedure to follow in the case of this complication.

Study design and ethical aspects

The present study is a case report. The patient was willing and fully capable of complying with the clinical procedures, and a written informed consent was obtained 7 days before the initiation of treatment.

Case report

The patient was 52 years old and a nonsmoker. He attended the periodontics department (University of Valencia, Valencia, Spain) for checks and controls periodically. The Department of Oral Surgery and Implantology, University of Valencia, Valencia, Spain, requested restoration of his missing teeth with implants.

The third and second molars had been extracted about 20 months before the observation. The patient was willing to have the right maxillary posterior area rehabilitated with a fixed prosthesis (**Figs. 1 & 2**).

The oral rehabilitation plan called for the placement of an implant 10 mm long and 4 mm wide distal to the maxillary second left premolar. In the right maxilla, an atraumatic sinus lift was sufficient.

The residual height of the bone in the left maxilla was less than 5 mm, which was evaluated by cone