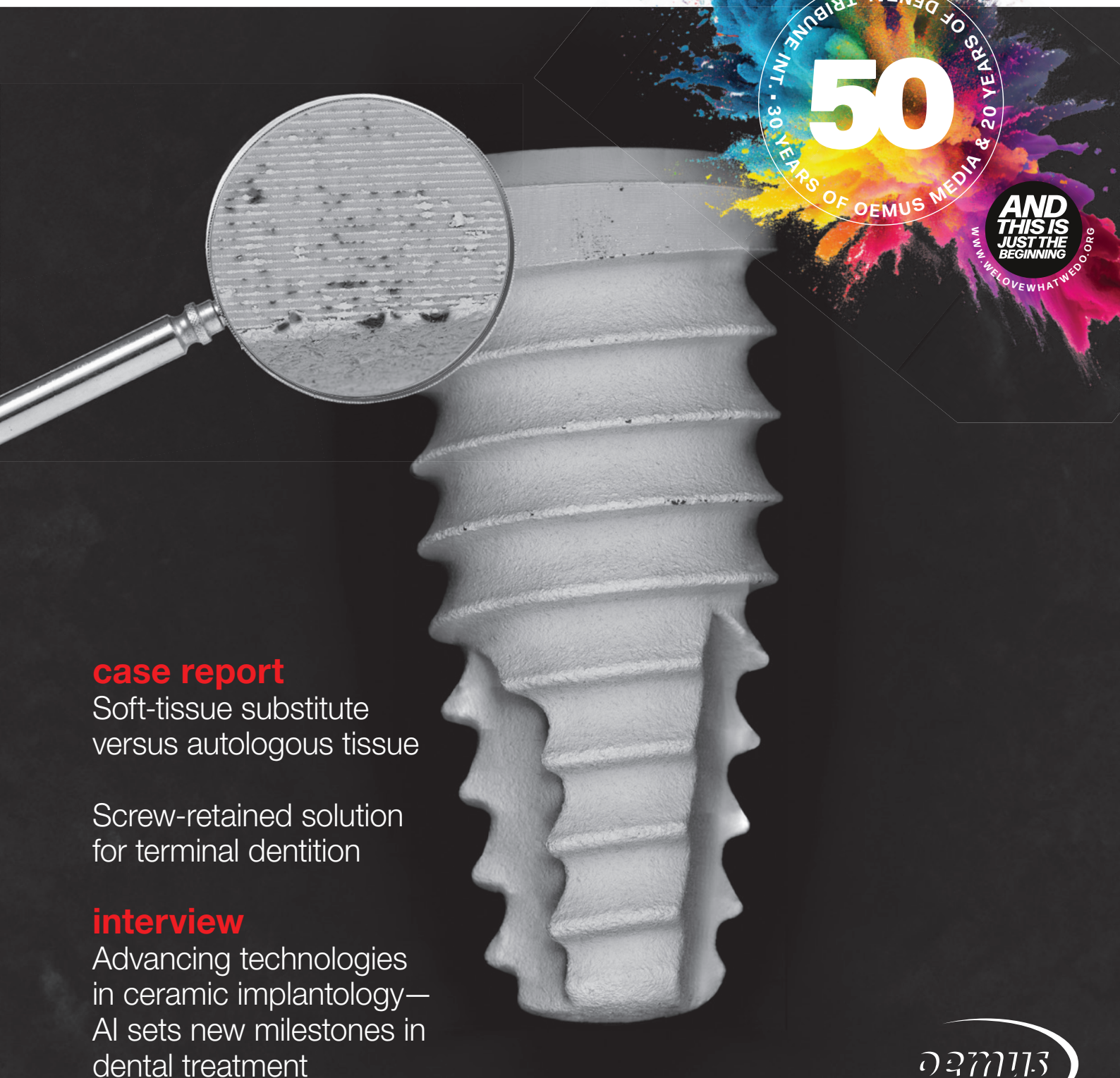

implants

international magazine of oral implantology



50
30 YEARS OF DENTAL TRIBUNE INT. • 20 YEARS OF OEMUS MEDIA

AND THIS IS JUST THE BEGINNING
WWW.WELOVEWHATWEDO.ORG

case report

Soft-tissue substitute versus autologous tissue

Screw-retained solution for terminal dentition

interview

Advancing technologies in ceramic implantology—AI sets new milestones in dental treatment

53RD INTERNATIONAL ANNUAL CONGRESS OF DGZI

IMPLANTOLOGY 4.0 – ON THE WAY TO
PATIENT-SPECIFIC CONCEPTS

SAVE THE
DATE

www.dgzi-jahreskongress.de



8./9. NOVEMBER 2024
DÜSSELDORF



DGZI
Deutsche Gesellschaft für
Zahnärztliche Implantologie e.V.

Dr Georg Bach

President of the DGZI

Here's to new endeavours for the year!



Dear colleagues and friends,

The board of the German Association of Dental Implantology (DGZI) has set ambitious goals for this year. Following our agenda for the board's term of office, we intend to focus primarily on the area of knowledge transfer and knowledge creation. Our experience with the relaunch of our curriculum, especially since the introduction of the online modules, has been extremely positive—and not only in terms of a significant increase in the number of graduates. We are very pleased about this, of course, but even more so about the positive feedback, especially from younger colleagues who have completed our curriculum—we have clearly recognised the needs of a new generation and understood how to satisfy these with a suitable training programme. There is no doubt that this will be the starting point for further activities.

Based on the sustained momentum from our incredibly important and very successful annual congress in Hamburg last autumn, we are already focusing on the DGZI highlight of this year. It may still seem a long way off, but our next International Annual Congress is already on the horizon. It will take place in Düsseldorf this year. You can look forward to a high-calibre, exciting and attractive programme that will cover many relevant issues in implantology.

We have also succeeded in engaging distinguished speakers, and moreover, the North Rhine-Westphalian

metropolis is always worth a visit and is sure to please everyone, including our international guests. The international relationships and even more so the global friendships and networks that the DGZI has forged over more than five decades have supported our growth as the oldest European specialist society and must be maintained. This is an important part of our annual programme.

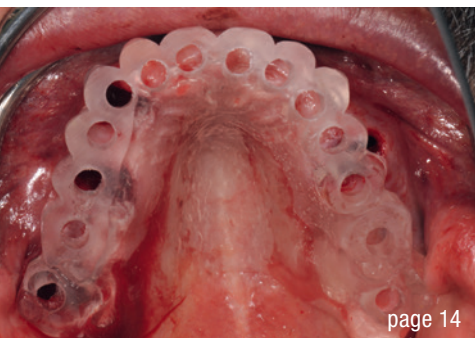
As you can see, dear colleagues, there will be a great deal going on this year too, but be assured that, even with all the focus on the activities described, our commitment as a practitioner society remains unwavering: to uphold our credo of promoting excellent implantology for dentists in private practice.

In this spirit, I would like to send you my warmest regards and wish you much pleasure in reading this first issue of *implants* in 2024!

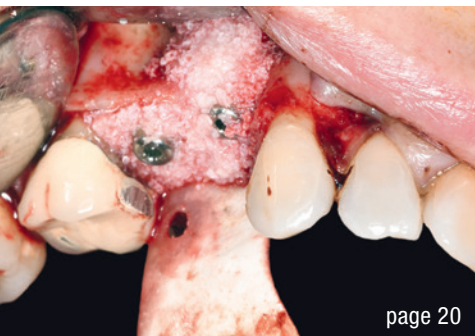Yours,

Dr Georg Bach

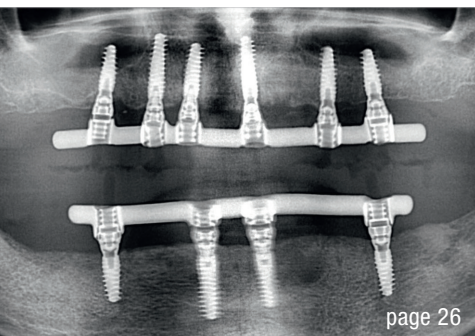
President of the German Association of Dental Implantology



page 14



page 20



page 26

editorial

Here's to new endeavours for the year! 03
Dr Georg Bach

case report

Soft-tissue **substitute** versus **autologous** tissue 06
Dr Yazad Gandhi

Full-arch: **Full rehabilitation** of the upper jaw—Part 1 14
Dr Dr Michael Rak, Norbert Wichnalek, Arbnor Saraci, Lukas Wichnalek

Implant-prosthetic rehabilitation 20
Dr Stefano Scavia

Screw-retained solution for terminal dentition 26
Dr Gian Battista Greco

interview

Advancing technologies in ceramic implantology—
AI sets new milestones in dental treatment 34
An interview with Dr Shepard DeLong

events

MIS unveils plans for its **global** conference in Palma de Mallorca 37

A **fascinating** experience 38
Dr Elisabeth Jacobi-Gresser

Connecting top dental professionals 40

news

Once you **see** it, you cannot **unsee** it! 41

about the publisher

imprint 42

Cover image courtesy of CleanImplant Foundation, www.cleanimplant.com



© A. S. Floro/Shutterstock.com

CONOLOG®
PROGRESSIVE-LINE
conical performance [1,2]
at bone level

Precise conical connection

- Long conus for reduced micromovements
- Superior positional stability in comparison to other conical systems [1, 2]
- Integrated platform switching supporting the preservation of crestal bone



www.biohorizonscamlog.com/conelog



[1] Semper-Hogg, W, Kraft, S, Stiller, S et al. Analytical and experimental position stability of the abutment in different dental implant systems with a conical implant-abutment connection Clin Oral Invest (2013) 17: 1017.

[2] Semper Hogg W, Zulauf K, Mehrhof J, Nelson K. The influence of torque tightening on the position stability of the abutment in conical implant-abutment connections. Int J Prosthodont 2015;28:538-41.

Soft-tissue substitute versus autologous tissue

Enhancing vestibular depth and tissue thickness with porcine-derived acellular dermal matrix to ensure peri-implant health—a case report

Dr Yazad Gandhi, India

The existence or development of a sufficient peri-implant soft-tissue cuff seems to play a significant role in influencing both the dimensions of the surrounding bone and soft tissue as well as the seamless integration of the superstructure into the peri-implant environment.¹ This also contributes to establishing a condition free of inflammation over the long term.¹ Although numerous studies over the years have proved that keratinised tissue around an implant is essential to enhance the protective environment for the crestal bone,² Wennström and Derks suggest that further research is required to explore the importance of keratinised tissue around implants and determine the precise amount of soft tissue necessary to effectively prevent peri-implant disease.³ Nonetheless, there is indirect evidence suggesting that enhancing soft tissue over the long run has a positive impact on peri-implant health.¹ This case report advocates the use of porcine dermis as a soft-tissue substitute, instead of au-

tologous tissue, to augment the tissue thickness (facially as well as vertically) in second-stage implant surgery to gain vestibular depth, facial tissue thickness and vertical tissue thickness at the crest and maintain peri-implant health.

Case presentation

A female patient in her fifties approached our facility with the desire to have her edentulous posterior maxillary quadrants rehabilitated with a fixed restoration. She was in good health and had fair oral hygiene. CBCT scans were obtained (CS 9600, Carestream Dental; magnification: 1.4x; voxel size: 75 µm; exposure time: 5.5–40.0 seconds; continuous scan mode). Her scans revealed poor posterior maxillary dentition that would need to be extracted and hard-tissue deficient for implant placement (Figs. 1 & 2).

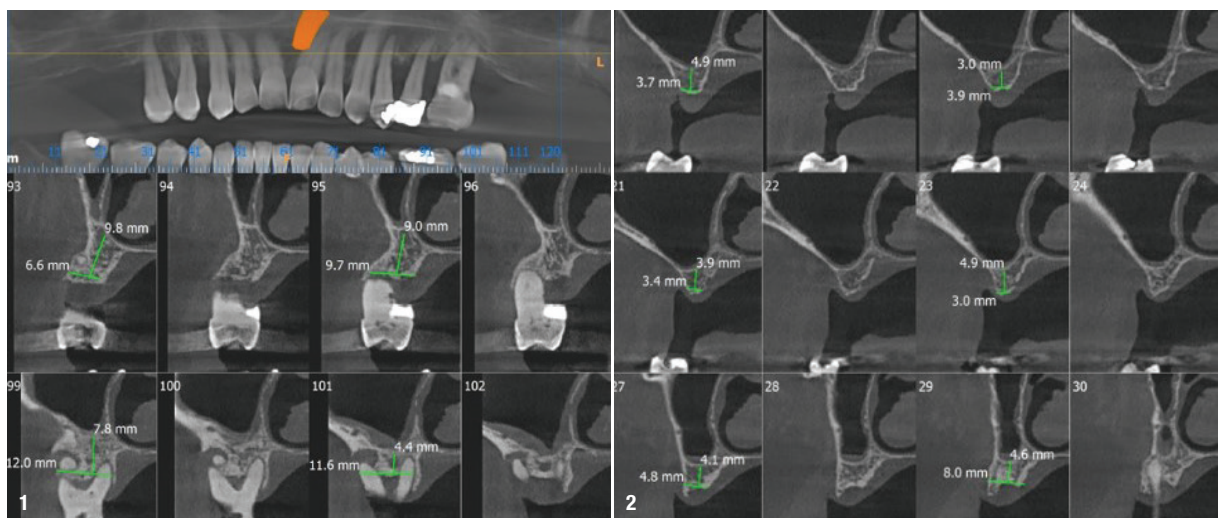


Fig. 1: Preoperative scans revealed mutilated posterior dentition along with poor bone quantity in the vertical and horizontal vector. **Fig. 2:** Good sinus health was confirmed prior to treatment planning by radiological as well as clinical methods.

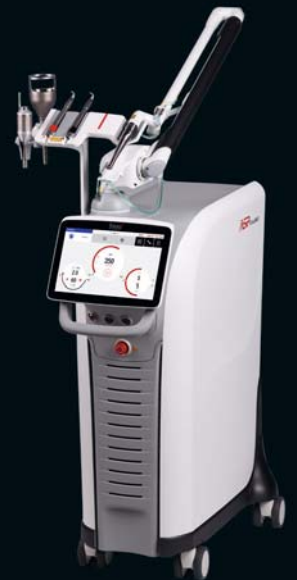Fotona
choose perfection

60
1964
2024
years of innovation

TwinLight® Peri-implantitis Treatment

A simple and effective procedure that offers the power to treat peri-implantitis – an increasing threat to oral health.

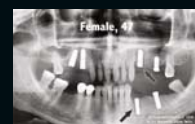
- Minimally-invasive technique
- Fast regeneration/healing
- Reduced inflammatory response
- Highly effective treatment
- No antibiotics needed



LightWalker®

The ultimate all-in-one hard and soft tissue laser

Peri-implantitis treatment video



www.fotona.com

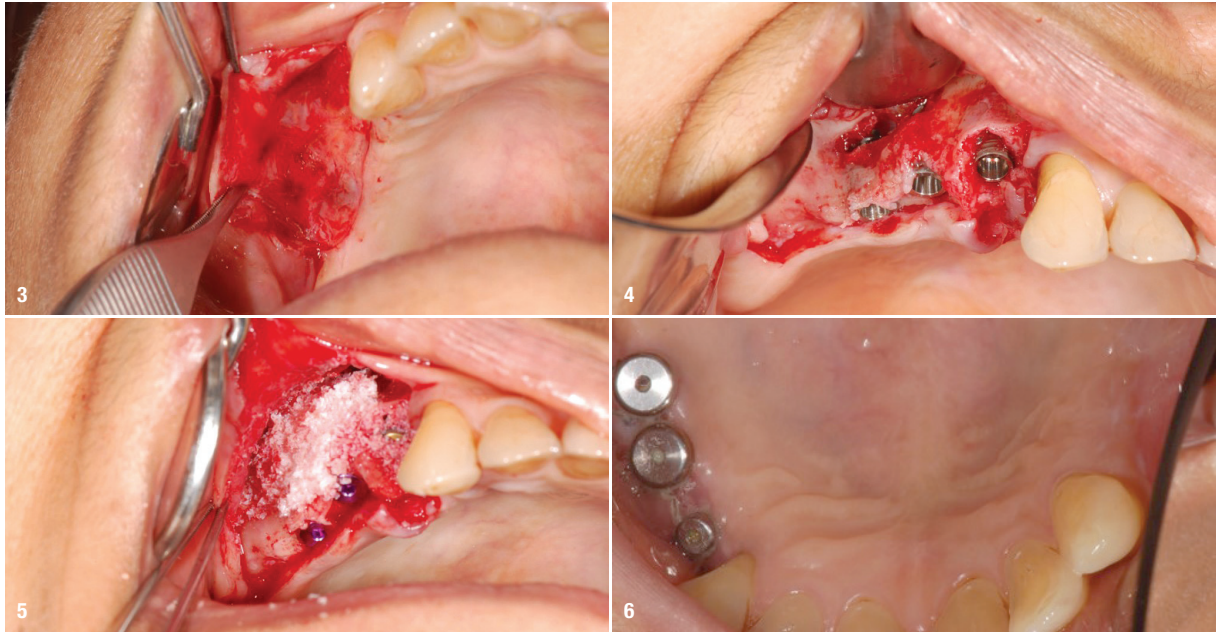


Fig. 3: An apically repositioned flap was made (split tissue thickness) to relocate the non-bound tissue away from the crest and gain vestibular depth. **Fig. 4:** Lateral window sinus augmentation was carried out and three CONELOG PROGRESSIVE-LINE implants (BioHorizons Camlog) were placed in regions 16 (4.3×9.0 mm), 15 (4.3×9.0 mm) and 14 (3.8×11.0 mm). **Fig. 5:** The biomaterial used for augmentation was autogenous bone obtained with a Micros scraper (Osteogenics) mixed with MinerOss XP (BioHorizons Camlog). A cross linked collagen Membrane Mem-Lok (BioHorizons Camlog) was used to cover the site. Augmentation was done to restore the vertical and horizontal deficit. **Fig. 6:** After a waiting period of six months bone maturation was optimal to proceed, but there was lack of adequate crestal keratinised tissue along with deficient vestibular depth.

Lateral window sinus augmentation was planned on the posterior of the right as well as the left maxillary quadrants. The patient was advised to undergo a thorough periodontal protocol including prophylaxis, root planning and subgingival curettage, which was deemed necessary prior to the surgical appointment. Informed consent was obtained after thorough discussion of a detailed treatment plan that involved immediate implant placement and hard-tissue augmentation. The patient was also informed of the possibility of a second-stage soft-tissue surgery.

Surgical procedure

Local anaesthesia was administered by way of nerve blocks as well as infiltration using 2% lignocaine with 1:200,000 epinephrine along with 0.5% bupivacaine. After lateral window sinus elevation, three CONELOG PROGRESSIVE-LINE implants (BioHorizons Camlog) were placed in regions 16 (4.3×9.0 mm), 15 (4.3×9.0 mm) and 14 (3.8×11.0 mm; Figs. 3 & 4). This region was grafted to correct the vertical and horizontal deficits using autogenous bone scrapings collected with a Micros bone scraper (Osteogenics) and MinerOss XP (2 cm³; BioHorizons Camlog) and covered with a cross-linked 20×30 mm collagen barrier (Mem-Lok, BioHorizons Camlog; Fig. 5). Closure was obtained using 4/0 Vicryl sutures. The same procedure using similar biomaterials was carried out in the maxillary left quadrant after two

weeks using three CONELOG PROGRESSIVE-LINE implants in regions 24 (4.3×11.0 mm), 25 (4.3×9.0 mm) and 26 (4.3×9.0 mm).

After a waiting period of six months of bone maturation, it was observed that there was lack of adequate crestal keratinised tissue along with deficient vestibular depth (Fig. 6). Therefore, an apically repositioned split-thickness flap was planned. Porcine dermis (NovoMatrix, BioHorizons Camlog; Figs. 7a & b) would be used as a poncho, stock healing abutments securing the dermis at the crestal aspect and sutures at the facial aspect under the split flap (Figs. 8 & 9). With a single procedure, adequate bound-down tissue and vertical soft-tissue thickness at the crest was achieved. This is imperative to prevent crestal bone loss, according to Linkevicius et al.² The implants on both sides were restored with CONELOG pre-milled abutments and cement-retained zirconia crowns (Fig. 10).

Observations

An obvious increase in the hard tissue was seen in the vertical dimensions from 3 to 4 mm preoperatively to 11 mm postoperatively. The postoperative vestibular depth was 6 mm, measured from the crest anteriorly, and 4 mm at the posteriormost locations (Figs. 11a & b). A vertical soft-tissue thickness of ≥ 2 mm was observed at the crest together with the gain in peri-implant keratinised soft-tissue thickness (Figs. 12a & b).



MIS GLOBAL CONFERENCE

September 12-15, 2024 | Palma de Mallorca, Spain

MIS is proud to introduce the Global Conference Speakers Team:



Tara Aghaloo Juan Arias Serhat Aslan Nitzan Bichacho Darko Božić Victor Clavijo Tali Chackartchi Pablo Galindo Moshe Goldstein



Gustavo Giordani Galip Gurel Hilal Kuday Stefen Koubi Alberto Monje Ariel Raigrodski Ausra Ramanauskaite Isabella Rocchietta Mariano Sanz Alonso



Ignacio Sanz Sanchez Ventseslav Stankov Stavros Pelekanos
Live Surgery Mario Alonso Puig
Guest Speaker

Join us
for 3 days of education, workshops and inspiration alongside the MIS community!