


CI

ceramic
implants



© gfx_nazim / stock.adobe.com

international magazine of **ceramic implant technology**

events

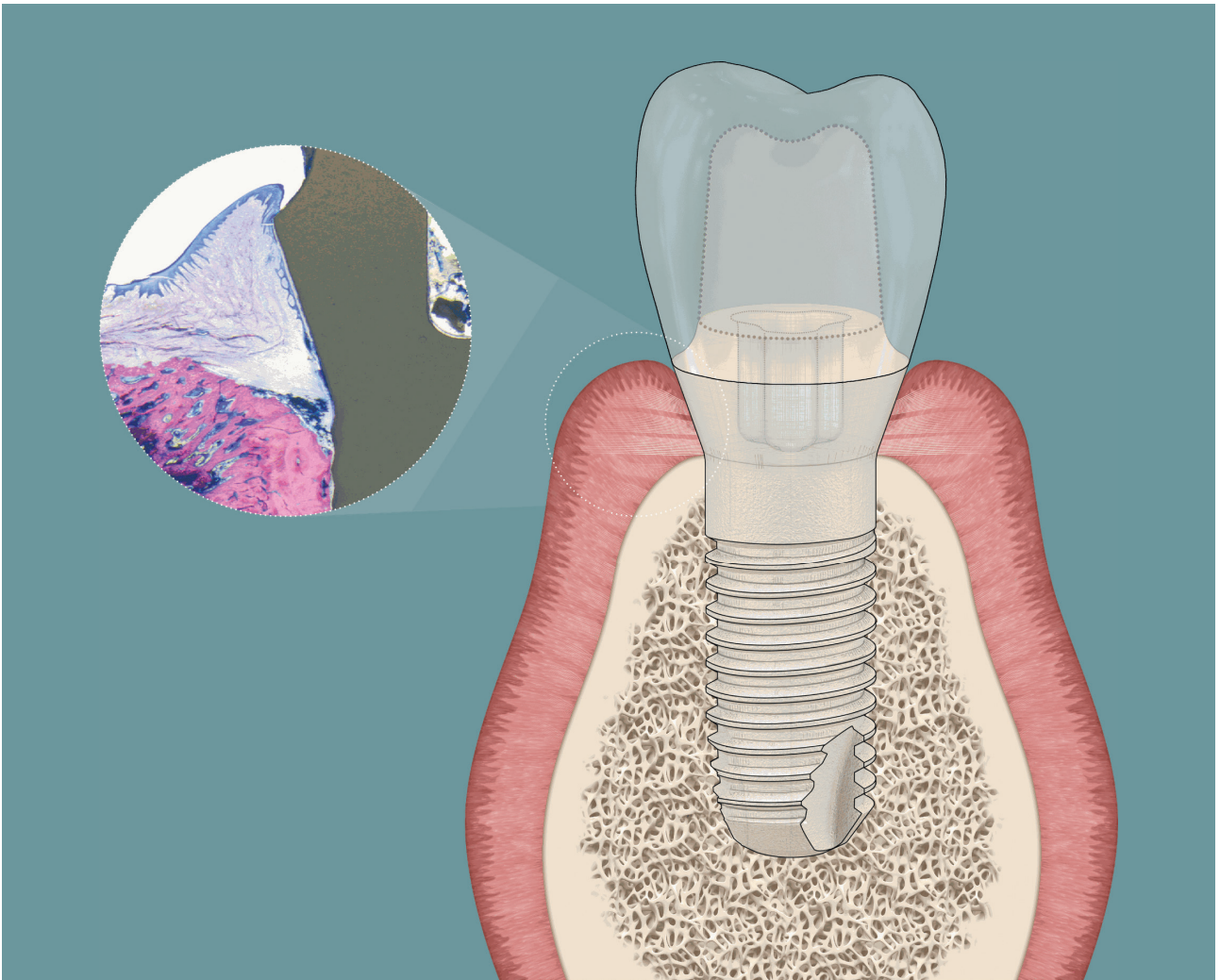
“Ceramic implants—
State of the Art”

case report

Two-piece
ceramic implant

interview

“If this system performs well in these
patients, it will perform in every patient!”



WE LOVE WHAT WE DO

We publish dental for the
past three decades.

YOU CAN RELY ON US.
WWW.OEMUS.COM



welovewhatwedo.org



Dr Sofia Karapataki
 Dr Sofia Karapataki |
 Dentist, Periodontist,
 Ceramic Implantologist.

Dr Sofia Karapataki



A woman's look in ceramic implantology

Our generation is so busy trying to prove that women can do what men can do. Many times, us women lose the unique qualities that make us stand out. Women were not created to do what a man can do—women were created to do what a man cannot do. It is not a matter of competence but an equally important and different addition. A lioness is not trying to be the lion. She embraces her role as a lioness. She is strong, powerful, and nurturing.

Women in dentistry are nowadays minimum as many as their male colleagues. This is earned and not given after a long and difficult struggle during the years. For all the ladies who enter now into this field, there is no need of such a thing as competition. We are here certainly because we are qualified. My advice to the young female dentists: do not play the game of antagonism to the male col-

CONTENT

03

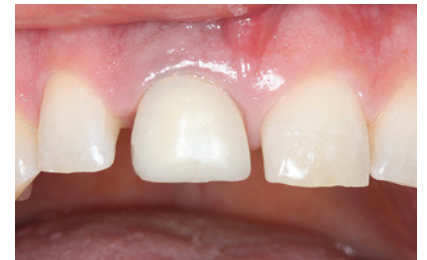editorial

Dr Sofia Karapataki

06

Two-piece ceramic implant

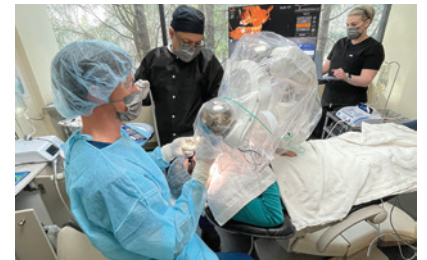Dr Claudia Michl, M.Sc.



12

Robotic facilitation of ceramic implants in compromised alveolar ridges

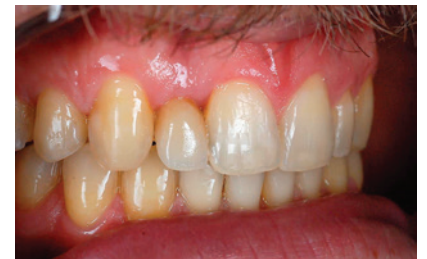Shepard DeLong DMD



16

Reconstruction of a maxillary lateral incisor

Dr Sofia Karapataki



22

Full-arch: Full rehabilitation of the upper jaw—Part 2

Dr Dr Michael Rak, Norbert Wichnalek, Arbnor Saraci & Lukas Wichnalek

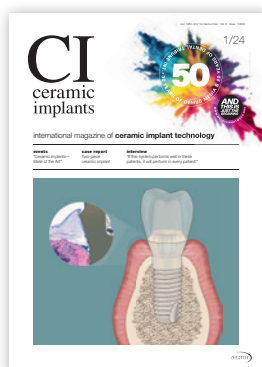

leagues, you don't need to prove anything. Do your job the best way you can and add your own perspective, your personal insight, your imagination, and way of thinking. The only person to compete with is yourself and only in to improve yourself and your skills. The only thing to balance is your inner self—to add one more task within the multiple ones a woman needs to fulfil, but this one here will be out of love and the most care for your patients.

The importance, influence, and role of women in this world has increased and will be much stronger as the years go by. The world needs more kind, compassionate, humble, loyal, persistent, confident, fierce, bold, pure, and loving women. This applies to every field and of course to oral implantology and to be more specifically in ceramic implantology. An open mind and flexibility as well as inner strength are the prerequisites in order to follow the path of ceramic implantology. It is discipline and vision at the same time. A clear look at ceramics with knowledge and respect on the material's nature together with the empathy and natural care of women can make a perfect combination on this field.

Sincerest regards,

Sofia Karapataki



Cover image courtesy of Zircon Medical Management AG | Patent™, www.mypatent.com



CONTENT

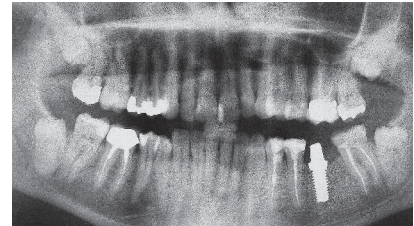30

Compromised patients, yet no peri-implantitis

Interview with Dr Sofia Karapataki

32

Z-SYSTEMS—a 17-year follow-up



34

“Ceramic implants—State of the Art”

36

EACim presents work and shares knowledge at DCIC—Dubai Ceramic Implant Congress

Dr Philippe Duchatelard

40

European Society of Ceramic Implantology (ESCI) presents its satellite symposium

42

Long-awaited Digital Dentistry Show to premiere in Berlin in June 2024



44

manufacturer news

48

news

50

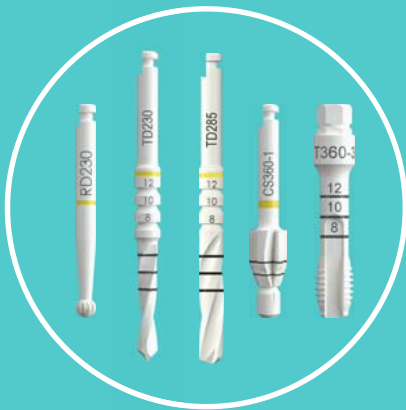events + imprint

The Right Choice & Most Requested By Patients



The only 100% Ceramic Bone-Level implant on the market with a 100% ceramic screw for a metal-free restoration.

Tissue-Level also available!



The World's Most Innovative 100% Ceramic Drill Kit

- Self-Sharpener!
- No Metal Flecking!




A variety of abutment options to accommodate various restoration types, ensuring optimal functionality and visual appeal.

Perfect for single or multiple implant cases.



The World's FIRST & ONLY 100% Ceramic Bone-Level Implant with a Screw-Retained Conical Connection.

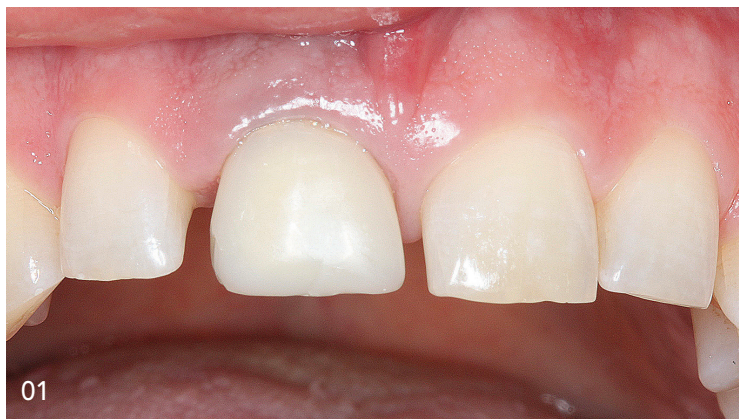Our innovative screw-retained conical connection with an internal thread eliminates the micro-gap and prevents the pump effect.



Patented SLM® Laser Surface Technology provides superior osseointegration and promotes healing and tissue regeneration.

Two-piece ceramic implant: Customised, fully digital solution for highly aesthetic results in the anterior region

Dr Claudia Michl, M.Sc., Germany

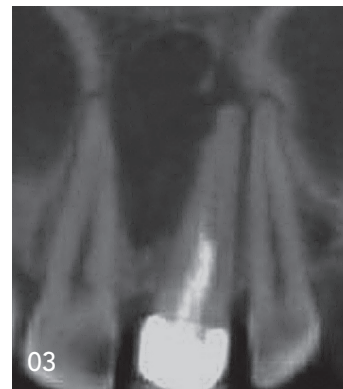
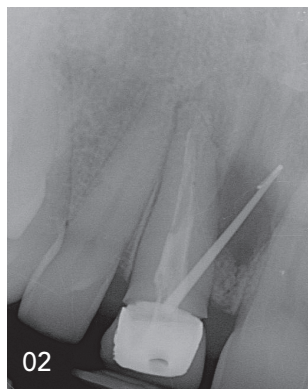


01
Tooth 11 before
extraction.

02
X-ray of tooth 11
before extraction.

04
Tooth extraction
and cystectomy.

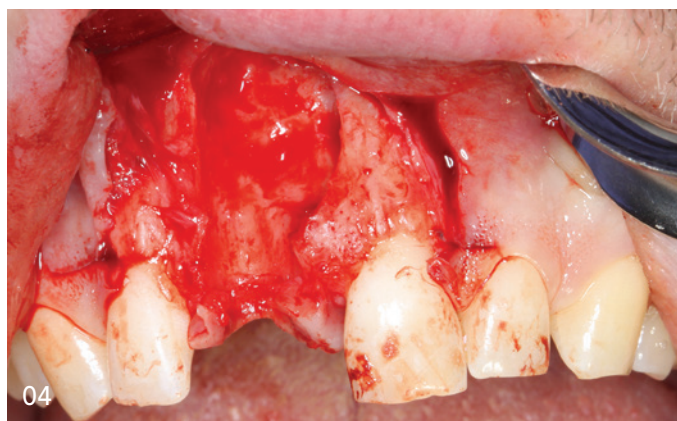03
CBCT of pre-op
cyst.



Introduction

Implants made of high-performance zirconia have now also become an established solution for patients with special aesthetic requirements. Replacing a front tooth with an implant places very high professional demands on the dentist. It is therefore particularly important to carry out precise planning in advance of tooth extraction and implant placement to ensure an attractive result.

However, the use of ceramic implants not only offers aesthetic benefits, but also provides patients with a metal-free restoration. In particular, patients with proven titanium intolerance and an increased individual genetic predisposition to inflammation have a sixfold increased risk of primary or secondary loss of the titanium implant.⁴ Furthermore, the risk of peri-implantitis is significantly reduced due to the high biocompatibility of zirconia. Various studies have demonstrated a high implant survival rate of over 94% after nine years,¹ low BOP and stable gingival conditions around the implant even many years later.



Clinical situation and treatment planning

Initial situation

The 38-year-old patient presented to my practice on 3/11/2020. His main complaint was discomfort in tooth 11. He had undergone root canal treatment several years ago and had been experiencing discomfort for the past two years. This manifested as permanent latent bite pain in tooth 11 and sometimes also pressure on the neighbouring tooth 21. In addition, pus and blood sometimes appeared to be discharged from tooth 11.

Clinical examination

Tooth 11 had been restored with a metal-ceramic crown. The gingiva around the crown showed clear signs of inflammation. The BOP index on tooth 11 was positive, there was no plaque. The crown margin on 11 was insufficient. Apical to the tooth there was a prominent fistula, from which secretions and pus were discharged under pressure. Tooth 11 was clearly sensitive

The ONLY Two-Piece System With Long-Term Studies

- Predictable Osseointegration¹
- No Implant Fractures²
- No Peri-Implantitis^{2,3}

1. **Glauser R, Schupbach P.** Early bone formation around immediately placed two-piece tissue-level zirconia implants with a modified surface: an experimental study in the miniature pig mandible. *Int J Implant Dent.* 2022 Sep 14;8(1):37. doi: 10.1186/s40729-022-00437-z. PMID: 36103094; PMCID: PMC9474793.

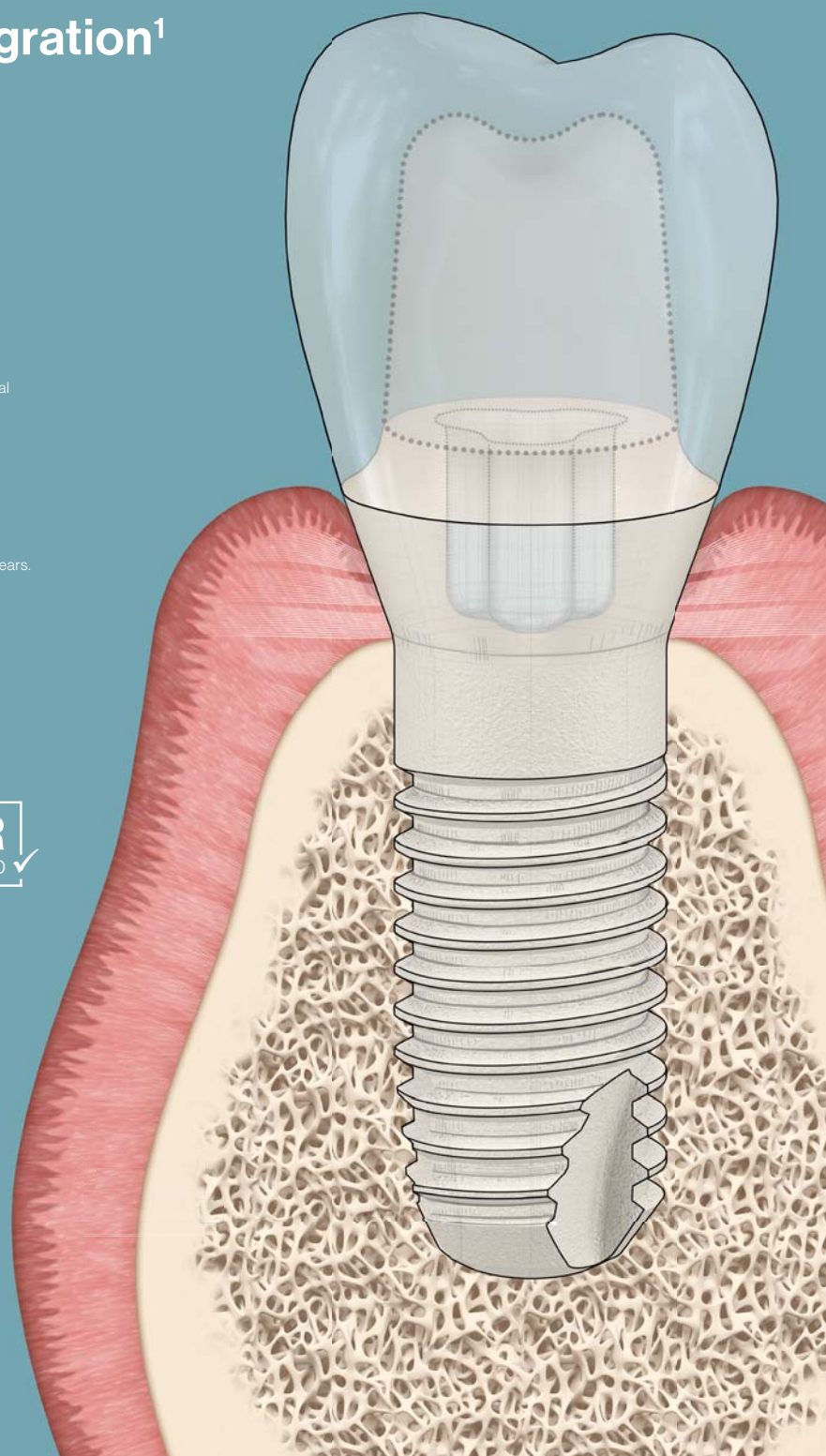
2. **Brunello G, Rauch N, Becker K, Hakimi AR, Schwarz F, Becker J.** Two-piece zirconia implants in the posterior mandible and maxilla: a cohort study with a follow-up period of 9 years. *Clin Oral Implants Res.* 2022 Dec;33(12):1233–44. doi: 10.1111/clr.14005. PMID: 36184914.

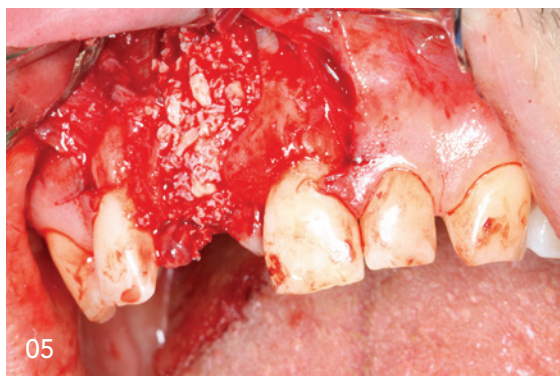3. **Karapataki S, Vegh D, Payer M, Fahrenholz H, Antonoglou GN.** Clinical performance of two-piece zirconia dental implants after 5 and up to 12 years. *Int J Oral Maxillofac Implants* 2023;38:1105–1114. doi: 10.11607/jomi.10284

The New Standard

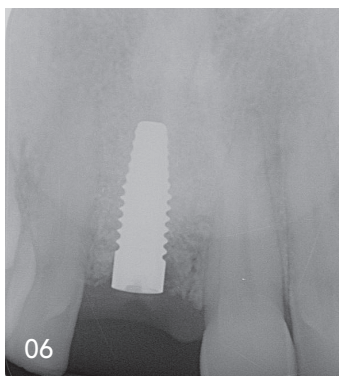


Independent long-term studies report no peri-implantitis around two-piece Patent™ Implants – how is this possible? Find out on www.mypatent.com





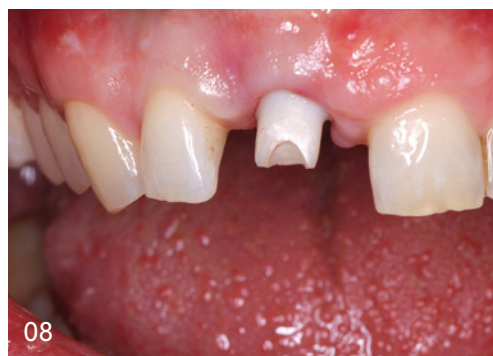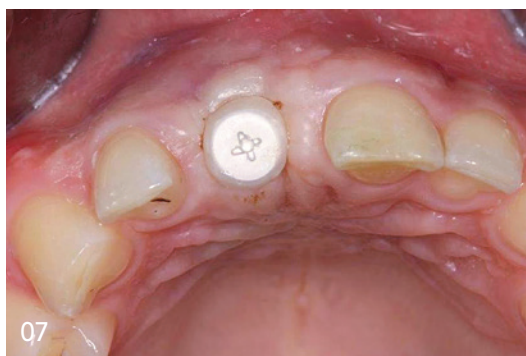
05
Socket preservation with Bio-Oss.



06
Implant *in situ* four months after bone augmentation.

07
Sealing with a 3 mm high gingiva former.

08
Customised abutment.



to percussion. The adjacent teeth were insensitive to percussion and sensitive to cold stimuli. The periodontal screening index was 2 in all sextants and oral hygiene was considered good. The occlusion showed Class 1 interdigitation with many gaps in the maxillary and mandibular anteriors. The vertical dimension was low. The overbite was 4 mm, and the overjet was 1.5 mm. The canines showed clear signs of wear. The Ahlers & Jakstat CMD screening test gave no indication of the presence of arthrogenic or myogenic dysfunction.

Radiological examination

The single-tooth image showed an endodontically treated tooth 11 with a gutta-percha point inserted into the fistula. Bone whitening was visible around the gutta-percha point which, starting apically from tooth 11, clearly occupied the interradicular space between 11 and 21. Based on these radiological findings, a CBCT scan with a FOV of 80 x 90 mm was performed.

The CBCT showed a very extensive interradicular hypodensity in the region 11, 21 starting from tooth 11. The dimension of the interradicular area with low bone density measured from coronal to apical is 19.4 mm and from mesial to distal is 10.9 mm. The buccal bone lamella was extremely thin, and no bone could be detected buccally in the area of root 11. A small hyperdense artefact, which can be interpreted as dispersed, overpressed root filling material, was prominent cranial to the whitening. Diagnosis was inadequacy of crown 11 and radicular cyst originating from tooth 11 with buccal fistula.

Procedure

Based on the findings and in consultation with the patient, the following treatment steps were taken:

1. Removal of tooth 11 with simultaneous cystectomy, reconstruction of the bone defect and fabrication of a temporary restoration (Erkodent aesthetic splint).
2. Placement of a two-piece ceramic implant (Zeramex XT, CeramTec Schweiz) four months after augmentation.
3. Restoration of the implant with a crown.

As the patient had several allergies, a lymphocyte transformation test (LTT) and a basophil degranulation test (BDT) were carried out in advance to rule out type I or VI allergies to the bone replacement material Bio-Oss (Geistlich Biomaterials). Blood samples were taken at our practice and analysed by the IMD laboratory in Berlin. No type I or VI allergy to Bio-Oss was detected. From five days preoperatively to five days postoperatively, the patient was premedicated with amoxicillin-clavulanate 500 mg x 3 daily, prednisolone 60 mg as a single dose one hour prior to surgery. For postoperative pain prophylaxis and anti-inflammatory therapy, a procaine base infusion (4 ml 2% procaine, 100 ml 8.4% sodium bicarbonate and 100 ml physiological saline solution) was administered during surgery and Ibuprofen 600 mg for four days postoperatively, as well as Pantoprazole 20 mg once daily to support the gastric mucosa.

Care was taken to ensure that the tooth removal and cystectomy were as atraumatic as possible and there were no complications. This resulted in a complete buccal fenestration, exposing a three-wall bone defect. This was reconstructed using Bio-Oss bone replacement material, which was biologised with autologous bone in a ratio of 2:1 and PRF (platelet-rich fibrin). In addition, metronidazole powder was added to the augmentation material for antimicrobial prophylaxis. After augmentation, an OSSIX Plus membrane (Regedent) and Plasmamatrix PRF, which

ISMI

INT. SOCIETY OF METAL FREE IMPLANTOLOGY



The innovative specialist society for modern metal-free implantology

Become a member now!

Benefits

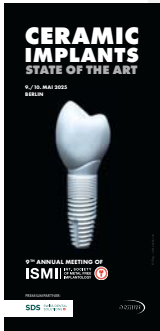

Effective public relations

Benefit from a strong community that elevates the marketing of your practice through effective public relations strategies.

Personal online member profile

ISMI provides a personal profile of all active members on their website—free of charge. In addition, the ISMI patient platform provides important information for patients and features a search tool with which patients can find their perfect dentist.

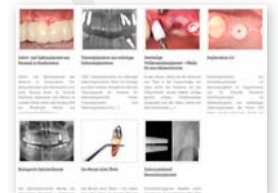

Discount on congress fees

Come and join us! Attend the Annual Meeting of ISMI in Berlin on 9 and 10 May 2025 and benefit from first-rate continuing education. ISMI members receive a special discount on the participation fee.

Online archive for specialists

Get exclusive access to ISMI's extensive online archive. Discuss all relevant questions regarding metal-free implantology with experts and colleagues from around the world and enjoy free access to the online archive where you will find informative training videos and clinical case reports.




Newsletter

The ISMI newsletter keeps you up to date with the latest scientific trends, products, and events on a regular basis. It also features user reports as well as a wide range of information and tips on the subject of metal-free implantology.

Specialist magazine

As a member of ISMI, your membership fee includes a subscription of the independently published English language magazine *ceramic implants*—international magazine of ceramic implant technology. Published three times per year, the magazine offers specialist articles and event reports as well as industry- and science-related news from the international world of metal-free implantology. In addition, *ceramic implants* provides information about manufacturers and their latest products.



ISMI e.V. Office Leipzig
Holbeinstraße 29 | 04229 Leipzig | Germany
Phone: +49 800 4764-000 | Fax: +49 800 4764-100
office@ismi.me | www.ismi.me

Become a
member of ISMI now!

