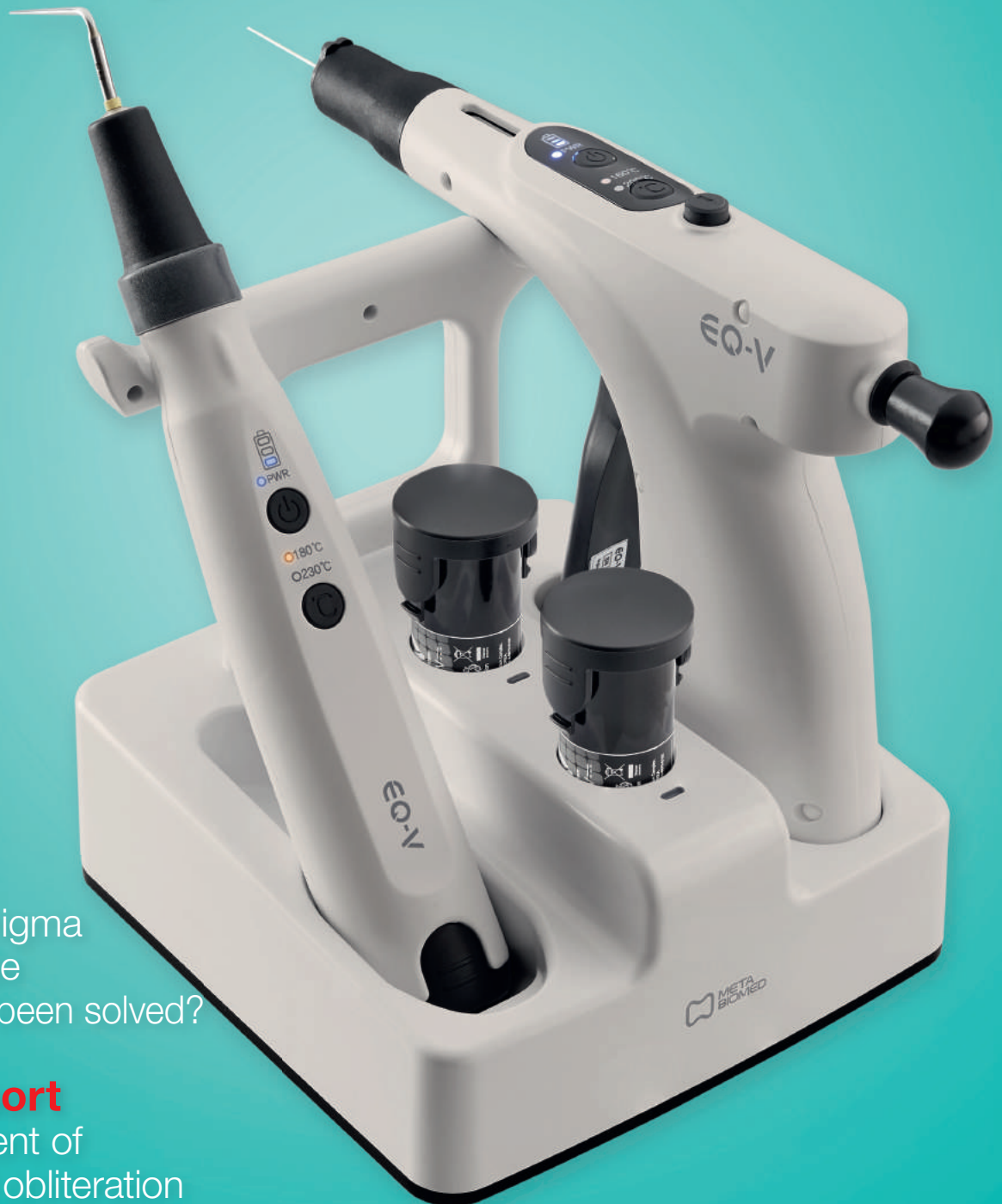

roots

international magazine of endodontics



opinion

Has the enigma of the single instrument been solved?

case report

Management of pulp canal obliteration

practice management

Successful communication in your daily practice



FKG
swiss endo

XP ENDO®
shaper

XP ENDO®
finisher

XP ENDO®
shaper

3D agility_

The One to Shape your Success

- ▶ 3D anatomical root canal preparation
- ▶ Exclusive Adaptive Core™ Technology
- ▶ Remarkable cyclic fatigue resistance

XP ENDO®
finisher

3D efficiency_

Optimal Cleaning while Preserving Dentine

- ▶ 3D cleaning and biofilm removal
- ▶ Enhanced irrigation and debridement
- ▶ Unique expansion capacity



FKG Dentaire SA
www.fkg.ch



Dr Philippe Sleiman

Guest Editor

Comprehensive treatment with **clarity and ease**

Multiple studies of root canal histology have confirmed its complexity, and its intricate anatomy is being revealed more and more to us, via *in vitro* and laboratory studies. As new articles are published and new equipment brought to the market, there is one question to be answered: how can we use all this information to develop a comprehensive clinical treatment that is clear to endodontists and to general dentists in order to serve our patient better?

Root canal therapy is a series of steps, where each procedure depends on the previous one:

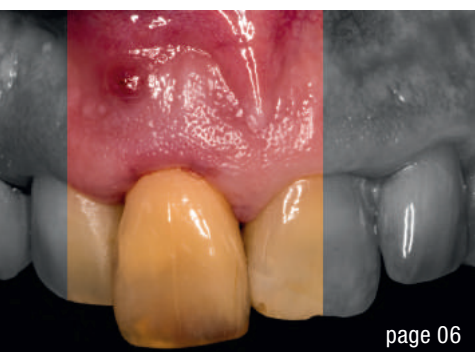
- Clinical judgement and CBCT are used to evaluate the level of 3-D complexity of the root canal system for proper diagnosis and treatment planning.
- Shaping is performed for cleaning of the main canal, or the space of lesser resistance, where the smear layer produced has to be eliminated via the proper sequence and appropriate technique of chemical preparation in order to open access to all spaces and prevent lateral pushing of the debris, thereby blocking the system (often, we, the practitioners, are responsible for blocking the system and “simplifying” the initially complex anatomy). Ongoing studies have shown that

we can accomplish almost a zero bacteria load level via a proper irrigation sequence, using the appropriate timing, volume and chemicals, and this can be accomplished by affordable means and does not require sophisticated and expensive equipment. Chemical preparation is not only used for cleaning the canal system. The latest studies using cryotherapy have shown that it helps reduce postoperative pain at the inexpensive use of cold water at the end of the procedure.

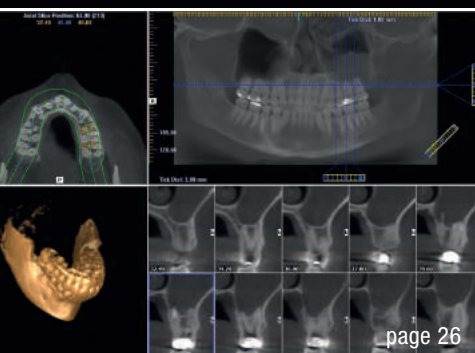
- 3-D obturation sealing of the canal in order to fill what has been cleaned builds on the success of the two previous steps, completes the treatment of the whole complexity of the endodontic system and makes the following restorative steps possible.

A clear understanding of the demands and restrictions of the anatomy, as well as the role of each step in order to treat the root canal system, is essential. Though the temptation may be strong to try what seems an easier route—one file/one chemical/one cone—it is the natural complexity that should be guiding us in how we address it and how we treat it.

Dr Philippe Sleiman
Guest Editor



page 06



page 26



page 46

Cover image courtesy of META BIOMED
(www.meta-europe.com).



editorial

Comprehensive treatment with **clarity and ease** 03
Dr Philippe Sleiman (Guest Editor)

case report

Management of pulp canal obliteration: 06
A clinical case report and **tips and tricks**
Dr Hugo Sousa Dias

How to give a second life to third molars: 12
A case series with follow-up
Drs Pio Bertani & Paolo Generali

Direct pulp capping as a conservative procedure 18
to maintain pulp vitality
Dr Jenner Argueta

Minimally invasive root canal shaping—A new protocol 22
Dr Bogdan Moldoveanu

Maxillary sinus and root canal therapy complications 26
Drs Valerie Batrouni, Pamela Kassabian,
Edgard Jabbour & Philippe Sleiman

Apical lesions: To treat or not to treat? 30
Dr Christophe Verbanck

technique

Soft-tissue management in endodontic microsurgery 34
Dr Francesco Maggiore

practice management

Successful **communication** in your **daily practice** 36
Part IV: Promoting a new service
Dr Anna Maria Yiannikos

opinion

Has the enigma of the single instrument been solved? 38
Dr Guillaume Jouanny

news

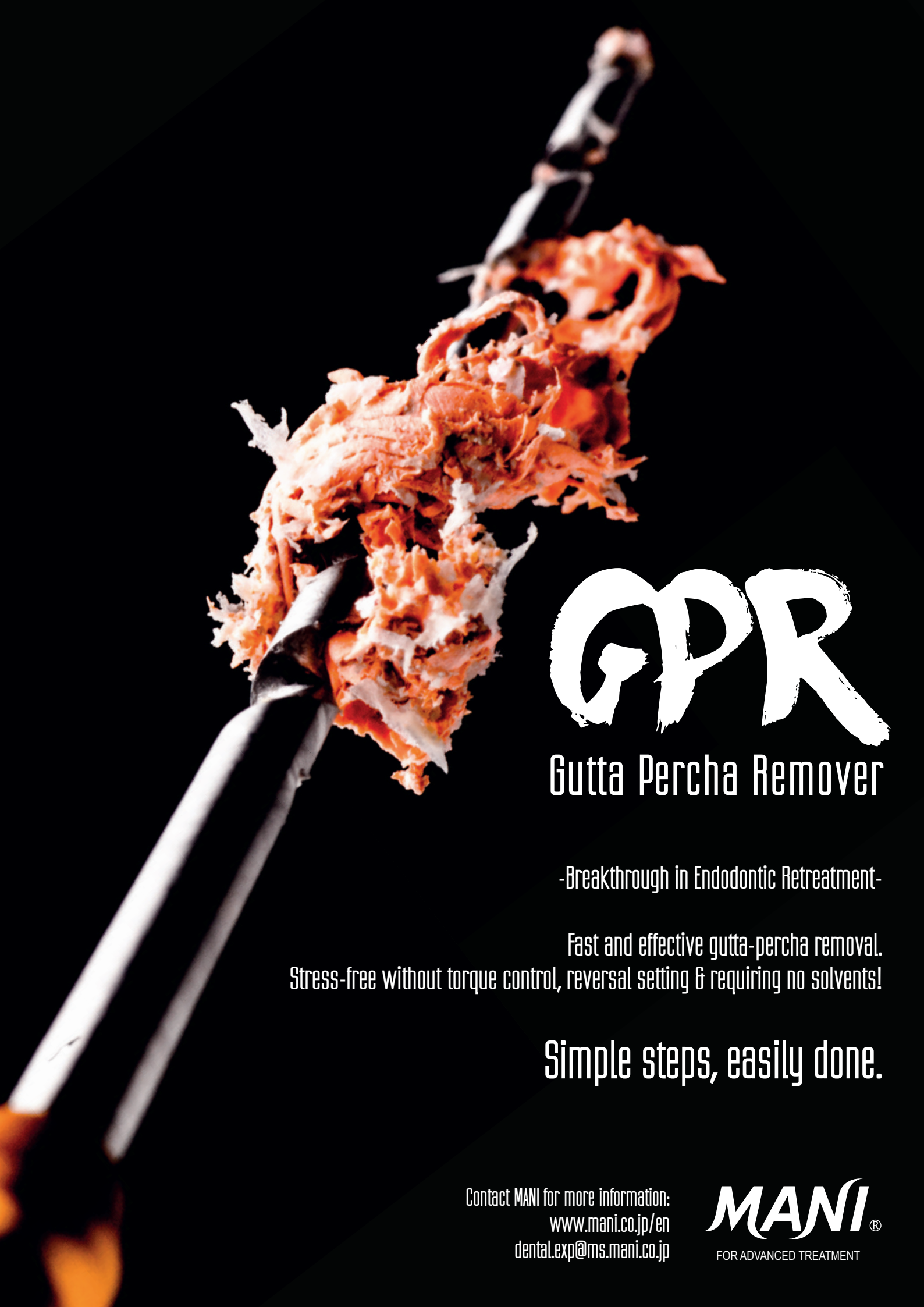manufacturer news 44

meetings

Review: **ROOTS SUMMIT 2018** crew says thank you 46
International events 48

about the publisher

submission guidelines 49
international imprint 50



GPR

Gutta Percha Remover

-Breakthrough in Endodontic Retreatment-

Fast and effective gutta-percha removal.
Stress-free without torque control, reversal setting & requiring no solvents!

Simple steps, easily done.

Contact MANI for more information:
www.mani.co.jp/en
dental.exp@ms.mani.co.jp

MANI[®]
FOR ADVANCED TREATMENT

Management of pulp canal obliteration: A clinical case report and tips and tricks

Dr Hugo Sousa Dias, Portugal

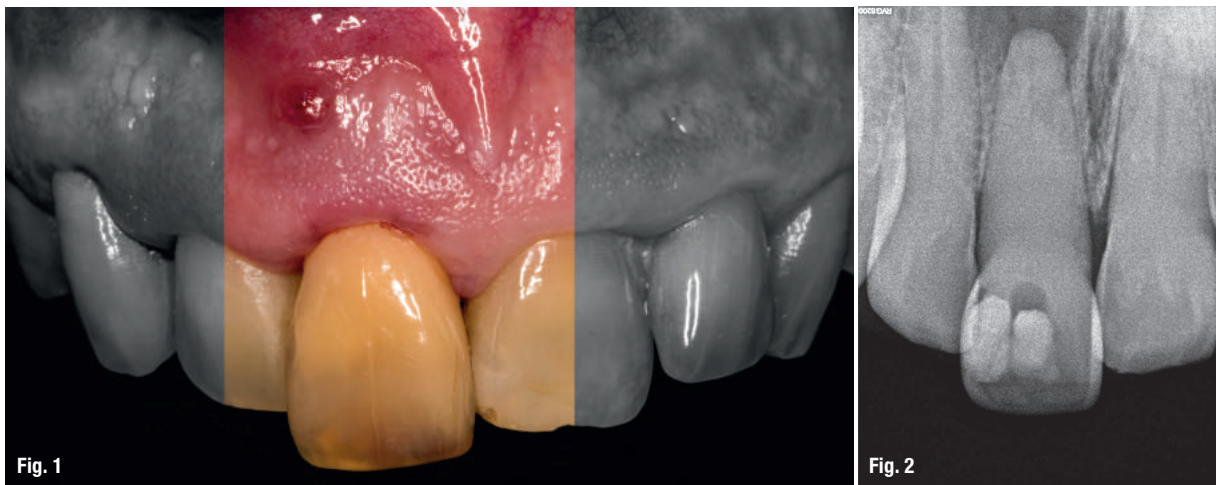

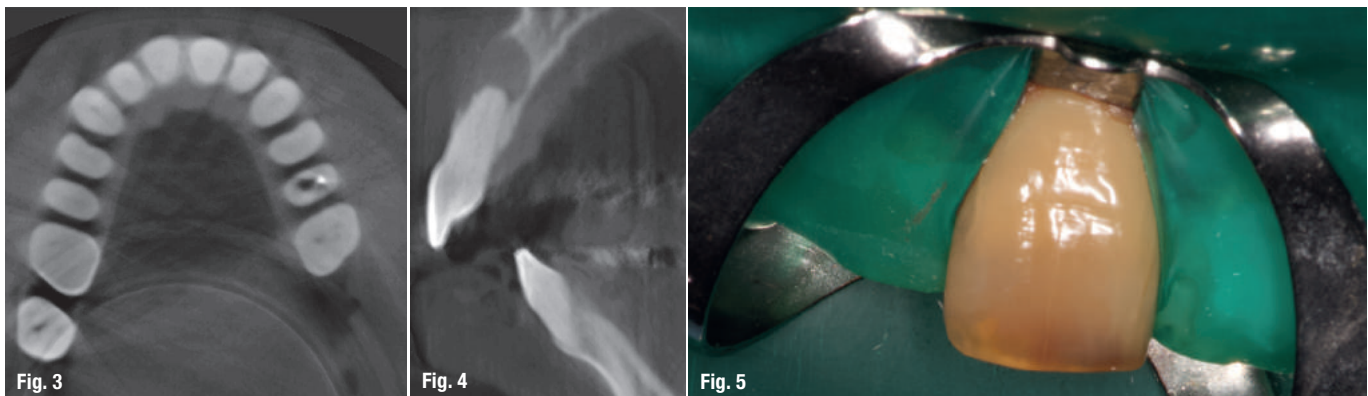
Fig. 1: Initial photograph (tooth #11 was found to have a discoloured crown). **Fig. 2:** Initial radiograph.

Introduction

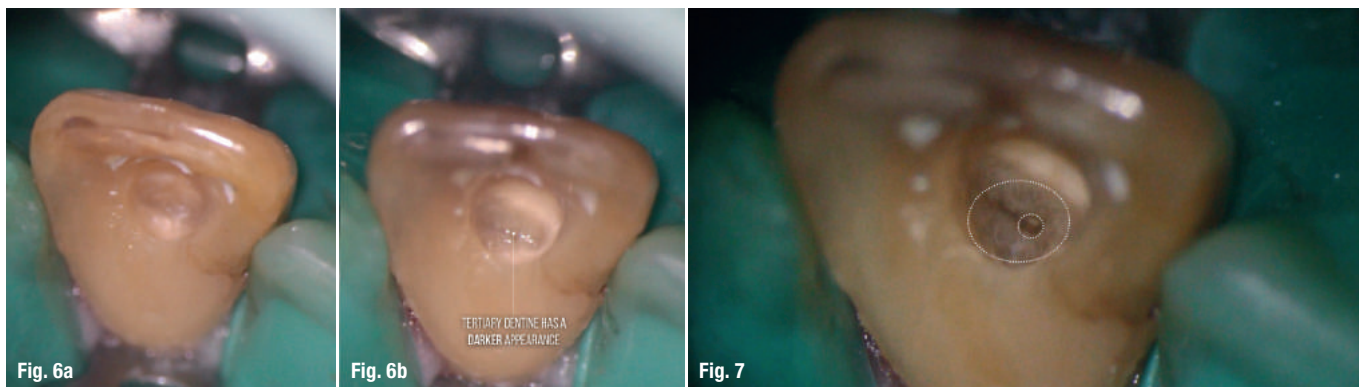
Clinical management of calcified teeth provides an endodontic treatment challenge and makes up a significant portion of current endodontic practice. People are living longer and want to maintain their natural dentition. There are several factors that might influence the development of varying degrees of moderate and severe calcification of the pulp chamber, as well as the root canal system, such as multiple restorations, trauma, vital pulp

therapy and chronic irritation arising from deep restorations or cracks.¹

Pulp stones in the pulp chamber, sclerotic dentine usually in the pulp chamber, dystrophic calcification in the root canals, and pulp canal obliteration in the pulp chamber and the root canal are some of the clinical situations commonly encountered by endodontists.¹ Pulp canal obliteration, also called calcific metamorphosis, is a sequelae of tooth trauma. It has been reported to develop



Figs. 3 & 4: CBCT scans (axial and sagittal planes). **Fig. 5:** Isolated tooth with rubber dam.



Figs. 6a & b: Access cavity preparation. **Fig. 7:** The calcifying process soon becomes circumferential, forming a calcified ring around the nerve.¹⁸

more often in teeth with concussion and subluxation injuries.²⁻⁴

Calcific metamorphosis is defined by the American Association of Endodontists as “a pulpal response to trauma characterised by rapid deposition of hard tissue within the canal space”.¹⁹ It is generally asymptomatic and patients present clinically with yellow discolouration of the affected tooth crown and apparent loss of the pulp space radiographically. This discolouration is due to a greater thickness of dentine deposition. The incidence of pulp canal obliteration after dental trauma has been reported to be approximately 4–24%. It is generally accepted that the frequency of pulp canal obliteration is dependent on the extent of the luxation injury and the stage of root formation, and generally, obliteration of the pulp canal spaces advances in a coronapical direction.⁴⁻⁶ The exact mechanism of canal obliteration is unknown, but is believed to be related to damage to the neurovascular supply of the pulp at the time of injury.⁵

The critical management decision is whether to treat these teeth endodontically immediately, upon detection of the pulpal obliteration,⁷⁻⁹ or to wait until signs and symptoms of pulp or periapical disease occur.¹⁰⁻¹⁵ Only 1–16% of teeth with pulp canal obliteration will develop

pulpal necrosis and only 7–27% of them will develop radiographic signs of periapical disease.⁵

There is a progressive decrease in the response to thermal and electrical pulp testing as pulp canal obliteration becomes more pronounced. Furthermore, a significant difference in electric pulp testing between partially obliterated and totally obliterated teeth has been reported. It is generally accepted that an absence of a positive response to the electric pulp test does not automatically imply pulpal necrosis.² It is also generally accepted that sensibility tests are unreliable.⁵ Teeth undergoing pulpal obliteration are generally asymptomatic.² Such teeth are often an incidental finding during clinical or radiographic investigation.

The literature suggests that pulpal necrosis and periapical disease are not common complications of pulp canal obliteration, and if root canal therapy is selected as a routine procedure, most treatments would be unnecessary, as the majority of teeth with pulp canal obliteration will never suffer pulpal necrosis or periapical disease. Smith recommends delaying treatment until there are symptoms or radiographic signs of periapical disease, a view accepted by many.¹⁰⁻¹⁵

It is possible to differentiate two types of radiographic pulp canal space obliteration: partial pulp canal obliteration

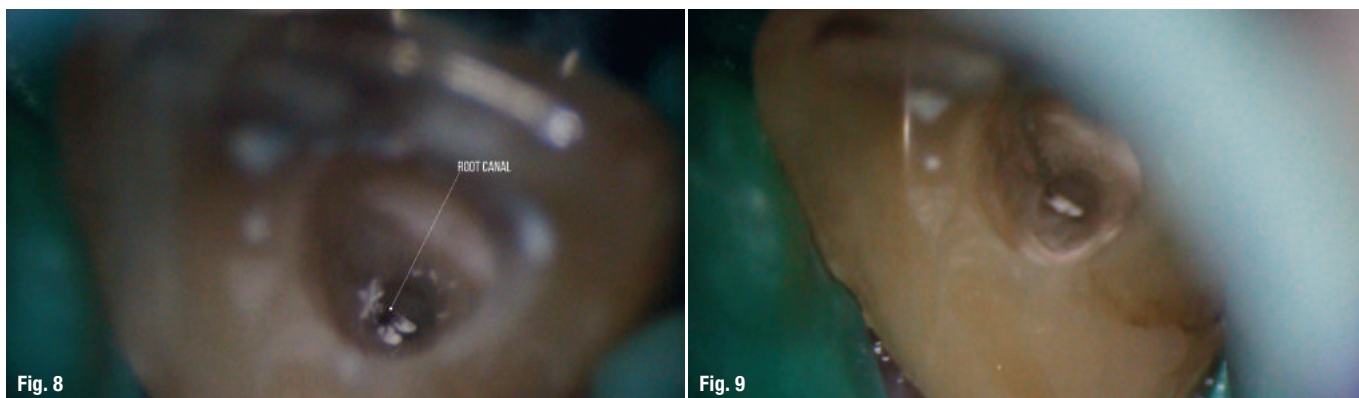
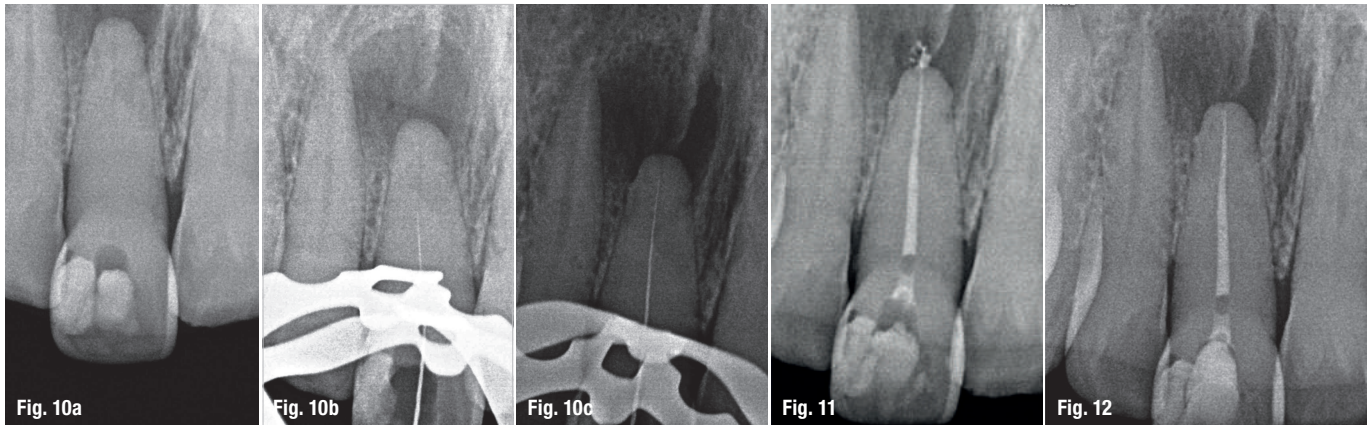


Fig. 8: Root canal entrance. **Fig. 9:** Glide path with D Finder files and M4 Safety Handpiece.



Figs. 10a–c: Working length radiographs. **Fig. 11:** Final radiograph. **Fig. 12:** Three-month follow-up radiograph.

tion (limited to the coronal part of the tooth) and total pulp canal obliteration (extended to the coronal and radicular pulp canal spaces),⁶ with or without associated periapical pathosis. Complete radiographic obliteration of the pulp space does not necessarily mean the absence of the pulp canal space; in the majority of these cases, a pulp space with pulp tissue is present, but the sensitivity of conventional radiographs is too low to allow visualisation of this.⁵

Taking into account the degree of difficulty of the clinical management of these kinds of cases, the practitioner should be aware of the possible complications that may occur. The complications include root perforation and irretrievable instrument fracture.¹⁵ This article presents a case report with some valuable tips regarding the clinical approach to such cases.

Case report

A 47-year-old male patient was referred to our clinic in order to evaluate a symptomatic tooth (tooth #11). The patient had spontaneous pain in the right maxilla, in the

vestibule of the maxillary right central incisor. At the clinical examination, a fistula in the buccal area of the tooth was identified. The tooth was very sensitive to percussion and non-responsive to thermal and electric pulp tests, without mobility, and periodontal probing around it was within physiological limits.

The patient gave a history of trauma in childhood. On examination, tooth #11 was found to have a discoloured crown (Fig. 1) and undergone a previous root canal therapy attempt. Initial radiographs were taken (Fig. 2), and these revealed that the canal could not be traced from the coronal and middle thirds. Cone beam computed tomography (CBCT) scans were requested for the patient (Figs. 3 & 4). Based on the results of the clinical and radiographic examination, a diagnosis of necrotic pulp with chronic apical abscess was made and root canal therapy recommended.

Local anaesthesia was performed, and the tooth was isolated with a rubber dam (Fig. 5). The access cavity was prepared, with an incisal orientation (following the long axis of the tooth), under continuous inspection

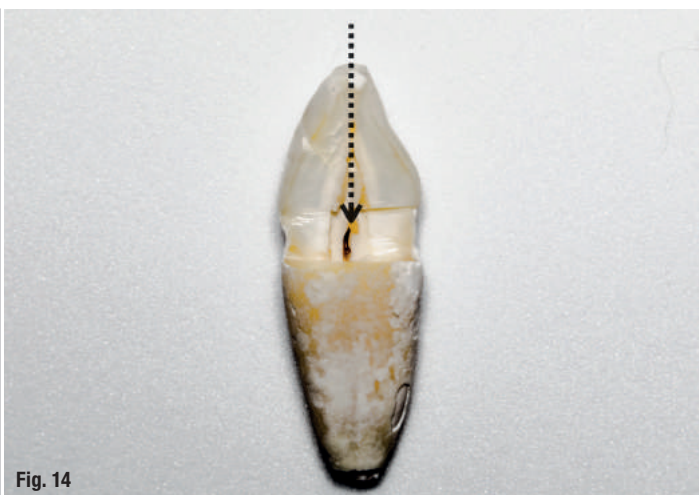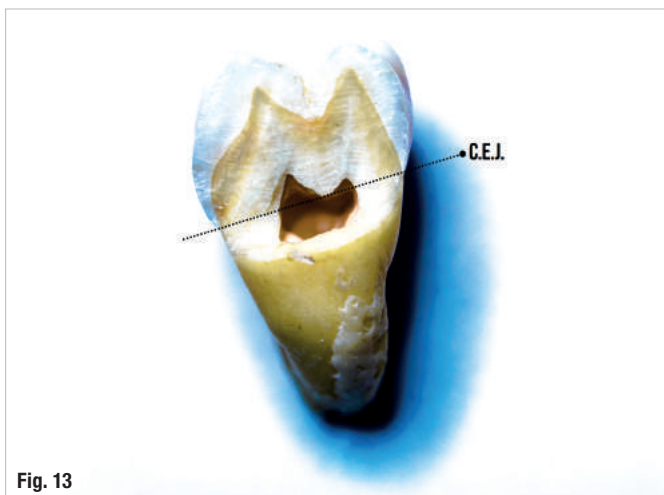


Fig. 13: Level of the cemento-enamel junction (CEJ). **Fig. 14:** Incisal access allows straight-line access to locate the pulp chamber.

under the operating microscope. The action of the long shank bur is only in the darker dentine (tertiary dentine), avoiding removal of the lighter dentine (primary dentine; Figs. 6a & b). After finding a ring of calcification (Fig. 7), we use an ultrasonic tip to have a more controlled cutting action and better visual control; in this clinical case, we selected the RedStar RS-2 ultrasonic tip (Kerr Endodontics).

In such a clinical situation, it is important to follow a basic sequence of irrigate and scrub with sodium hypochlorite/EDTA, dry, observe and cut until one can find the root canal. Radiographic control during this procedure is fundamental in order to avoid any mishap.

When the root canal entrance was identified (Fig. 8), a short (21 mm in length) and more rigid hand file was selected to allow more tactile control and a more effective cutting action. The root canal was instrumented with size 8, 10, 12 and 15 D Finders (Mani Inc.) to obtain a manual glide path using the M4 Safety Handpiece (Kerr Endodontics; Fig. 9).

Working length radiographs were captured (Figs. 10a–c). Cleaning and shaping were performed using TF Adaptive (Kerr Endodontics) up to size 25.06 with the Elements Motor (Kerr Endodontics) in Adaptive Motion. Irrigation was performed during the entire treatment with 5.25% sodium hypochlorite. A final irrigation protocol was done with 17% EDTA and 5.25% sodium hypochlorite, and irrigant was activated with the manual dynamic activation technique. The canals were thoroughly dried and obturation performed using Autofit 4% gutta-percha cones (Kerr) and AH Plus (DENTSPLY Maillefer), employing the continuous wave of condensation technique with the Elements Obturation Unit (Kerr Endodontics). The pulp chamber was sealed with Ionoseal (VOCO) and a temporary restoration was performed (Fig. 11). The patient

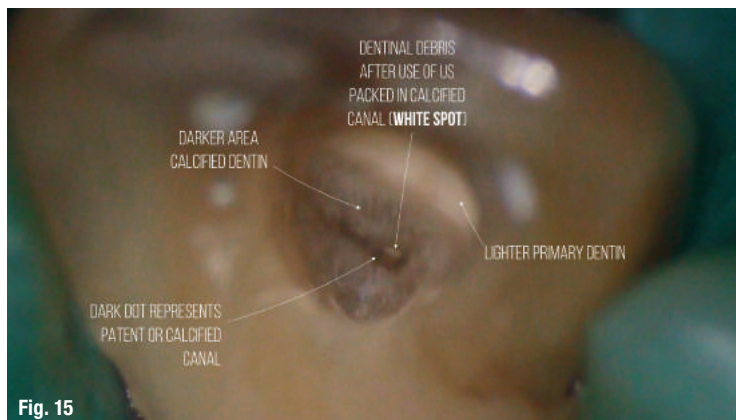


Fig. 15: Colour changes in pulp chamber.

was referred to his dentist for the permanent coronal restoration. At a follow-up visit after three months, the tooth was asymptomatic (Fig. 12).

Tips for clinical management of pulp canal obliteration

1. It is essential to remember that the pulp chamber is always located in the center of the tooth at the level of the cemento-enamel junction (CEJ; Fig. 13).⁵
2. The calcified pulp chamber is darker than and appears a different colour to the axial wall root dentine.⁵
3. A much better solution is to prepare the access cavity close to or through the incisal edge. This approach facilitates straight-line access and is a more predictable approach to locating the pulp chamber while avoiding unnecessary damage (Fig. 14).⁵
4. The use of the dental operating microscope is recommended to identify colour changes (Fig. 15).⁵
5. Using long shank burs in a slow handpiece or preferably ultrasonic tips to penetrate deeply into the canal system is recommended.⁵

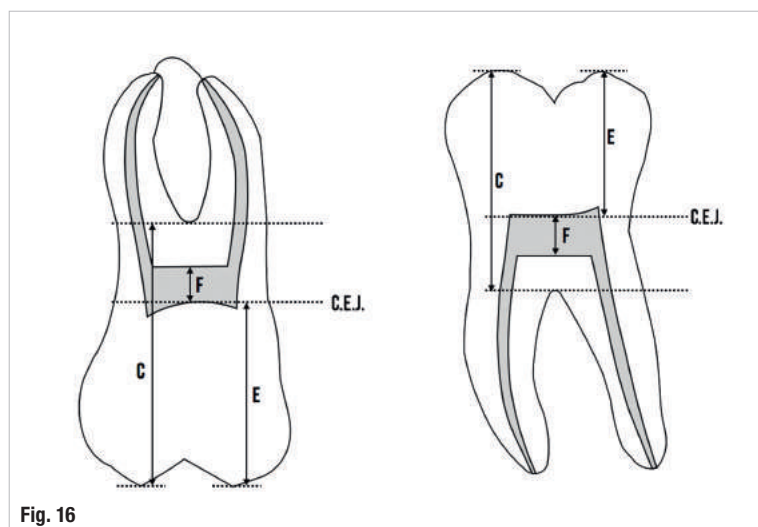


Fig. 16

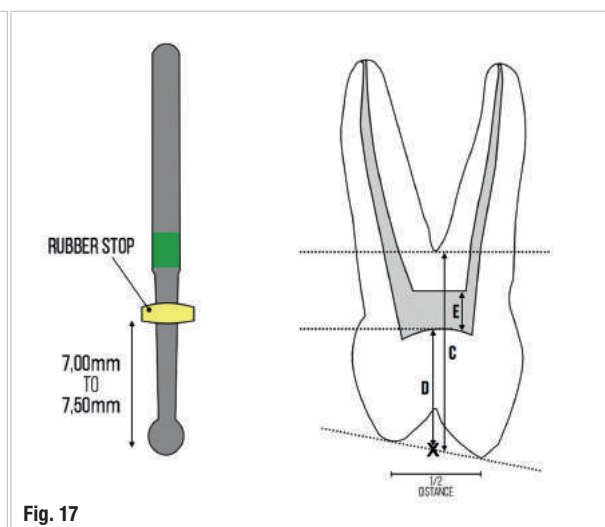


Fig. 17

Figs. 16 & 17: Decision flowchart.