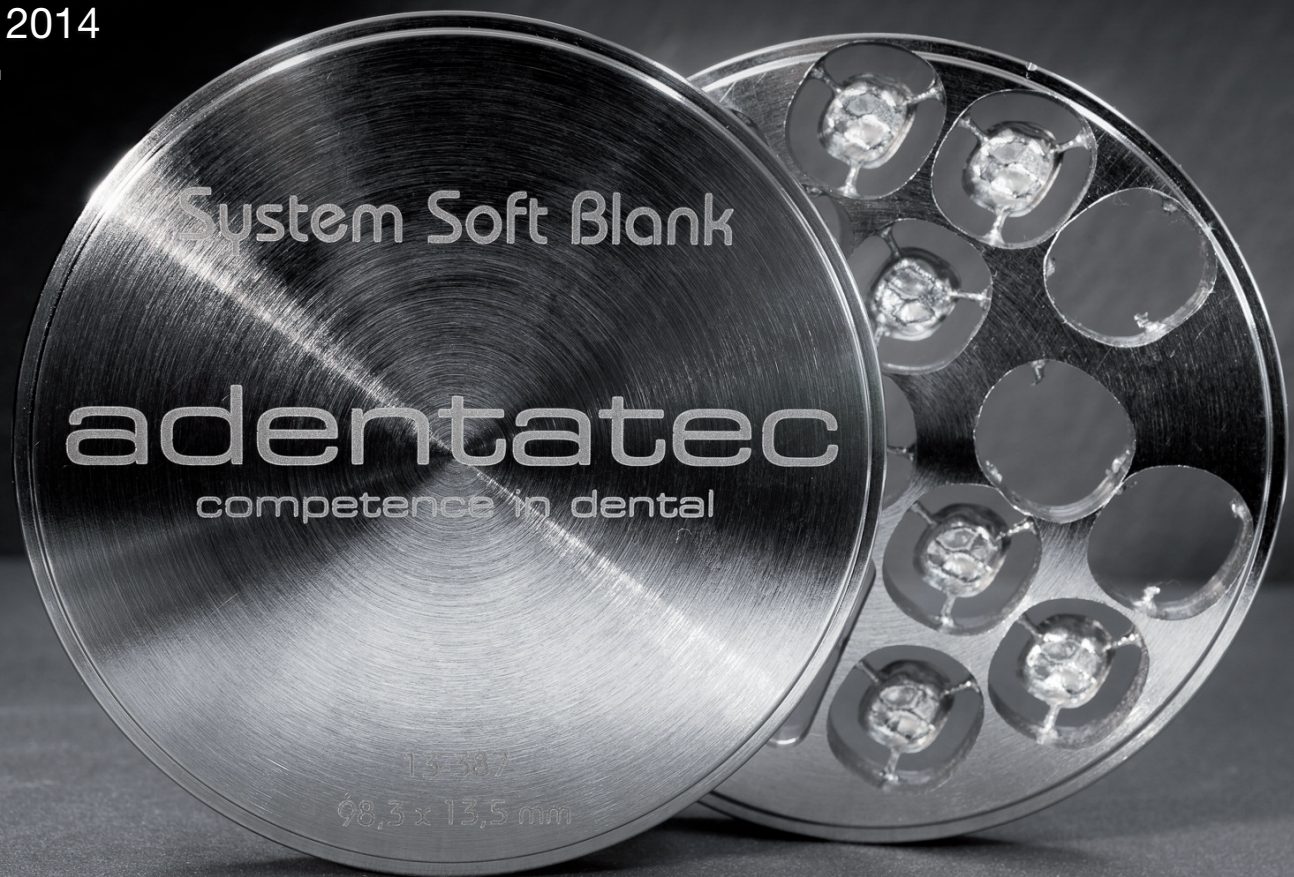

# CAD/CAM

international magazine of digital dentistry

4<sup>2014</sup>



**| special**

Designing real smiles  
with digital tools

**| case report**

Implant-supported immediate restoration  
in the edentulous maxilla

**| industry report**

Zirconia Reinforced Composite



**ATLANTIS™**

For all major  
implant  
systems

# The natural choice

## ATLANTIS™ patient-specific abutments

Give your patients excellent function and natural esthetics.  
ATLANTIS patient-specific abutments go beyond CAD/CAM to deliver:

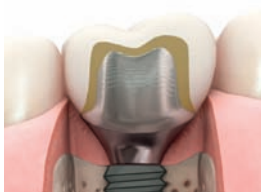- **Freedom of choice in implant system and material**
- **Optimal emergence profiles and soft tissue margins**
- **Anatomical support for the final restoration**
- **A simplified restorative procedure**

To learn more about ATLANTIS patient-specific prosthetic solutions,  
contact your local DENTSPLY Implants representative or visit our website.

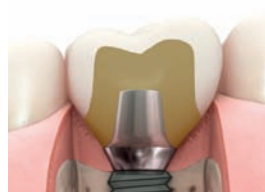

### We have you covered

ATLANTIS abutments are backed by a comprehensive warranty program.  
For full warranty terms and conditions,  
visit [www.atlantisdentsply.com](http://www.atlantisdentsply.com).



ATLANTIS patient-specific abutment



Stock abutment

# Dear Reader,

**Digital technology** is one of the fastest-growing market segments in dentistry; digital processes are increasingly determining everyday practice in dental offices and laboratories and seem to be changing dentistry and dental market forever.

In recent years, an increasing number of dental companies have released innovations in digital hardware, software and consumables, such as 3-D imaging, CAD/CAM and intra-oral devices.

As a response to the market needs Dental Tribune International (DTI) in collaboration with Unione Nazionale Industrie Dentarie Italiane (UNIDI), the Italian dental industry association, held the first Digital Dentistry Show (DDS) at the International Expodental in Milan. The event was the first of its kind, being solely dedicated to digital dental technologies. Over the course of three days, DTI and major industry partners offered visitors to the fair comprehensive information on the latest developments and product innovations in the field of digital technologies.

DDS provides comprehensive information on the latest digital technology and is targeted at dentists, dental technicians and representatives of the dental industry. In contrast to the conventional booth-based presentation of products, DDS is showcasing digital innovations through a combination of sponsored live product presentations, hands-on workshops, discussion sessions, an exhibition and a printed guide, offering participants a dynamic and interactive education experience.

The next Digital Dentistry Show will be held in Rimini in Italy from 21 to 23 May 2015 as part of the Amici di Brugg dental trade fair. Moreover, we are planning to stage another DDS in October 2015 in Shanghai. Plans are also underway for an international edition of the show in Berlin in June 2016.

Digital dentistry is already here, technology is what differentiates a modern dental office from a conventional one, increases patient flow, and advances diagnostic and treatment outcomes, which ultimately leads to increased revenues.

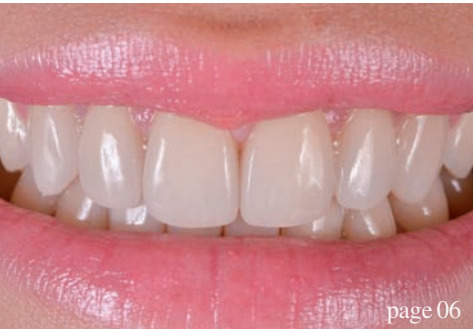Yours sincerely,



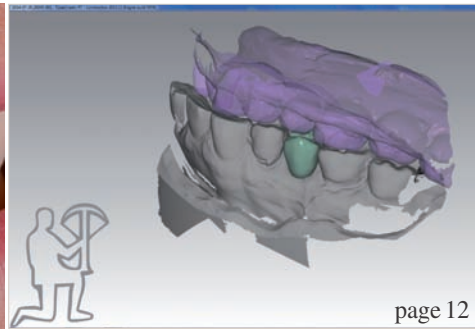
Torsten R. Oemus  
President Dental Tribune International



Torsten R. Oemus



page 06



page 12



page 20

**| editorial**

03 **Dear Reader**  
| Torsten R. Oemus

**| special**

06 **Designing real smiles** with digital tools  
| Drs Eduardo Mahn, Gustavo Mahn, Carlos Cáceres,  
Luis Bustos & Christian Coachman

**| industry report**

12 **Zirconia Reinforced Composite**—a universally applicable material with **many prosthetic uses**  
| Maximilian Kollmuß & Julia Goeke

**| case report**

- 16 **Permanent implant prostheses**  
| Drs Arzu Tuna, Umut Baysal & Rainer Valentin
- 20 **Double crowns made of a new high performance polymer**  
| Drs Rolf Vollmer, Martina Vollmer, ZTM Michael Anger & Dr Rainer Valentin
- 32 **Implant-supported immediate restoration in the edentulous maxilla**  
| Dr Fernando Rojas-Vizcaya
- 36 **Paving the way for a patient-friendly, minimally invasive approach in alveolar ridge augmentation**  
| Dr Yasmin Buchaekert

**| industry news**


- 40 **Planmeca ProMax CBCT with CAD/CAM technology: the perfect combination**  
| Planmeca
- 42 **DENTSPLY Implants** expands into new markets  
| DENTSPLY Implants
- 44 **3Shape TRIOS** recognised with **“Best of Class” Technology Award**  
| 3Shape
- 45 **Adentatec**  
**Competence in Dental**  
| Adentatec
- 46 **One streamlined flow**  
| Nobel Biocare

**| meetings**

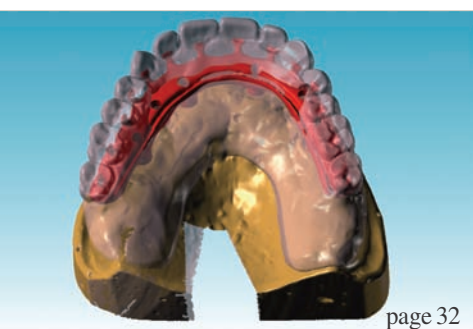
48 **International Events**

**| about the publisher**

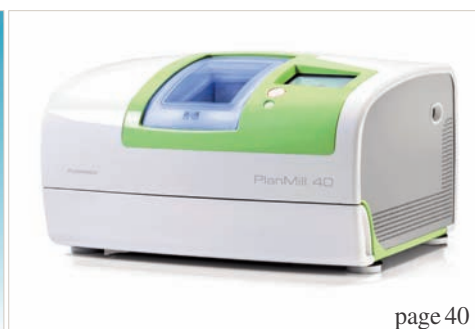- 49 | submission guidelines
- 50 | imprint



Cover image courtesy of Adentatec GmbH ([www.adentatec.com](http://www.adentatec.com)).



page 32



page 40



page 48





More than efficiency.  
Cost-effective  
workflow solutions.



What does efficiency mean to your business?

- Newly introduced one-step and cost-effective implant restorations, titanium base and full-contour crown were added to Straumann® CARES® X-Stream™'s 1 scan, 1 design and 1 delivery
- Directly venerable TAN Abutment for a quick path to your final restoration
- New CARES® Screw-retained Bridges and Bars increase treatment flexibility
- Ability to connect your CAD/CAM system to Straumann® CARES® Prosthetics – no additional investment or training required, visit: [www.straumann.com](http://www.straumann.com)

60 YEARS

 **straumann**  
simply doing more

# Designing real smiles with digital tools

**Authors** Drs Eduardo Mahn, Gustavo Mahn, Carlos Cáceres, Luis Bustos, Chile & Christian Coachman, Brazil

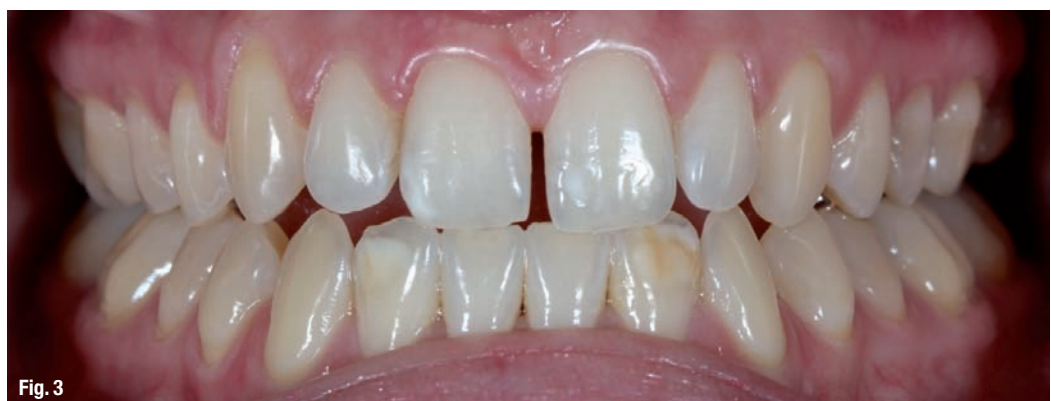

**\_Dental materials and clinical procedures** have changed dramatically in the last decades. Probably the major advances that have occurred during the last two decades have been in the fields of implantology and adhesive dentistry, but the main revolution is the development of digital dentistry. Although these changes have certainly made diagnostics and certain procedures easier, the basics, such as function and the biological aspects, remain essential. At the same time, we

have experienced major improvements in ceramics and composites, helping us to fulfil our patients' aesthetic demands.

A basic prerequisite for these indications is an in-depth understanding of the facial and dental aesthetic parameters. The clinician needs to understand the challenges that each clinical case presents and has to be able to develop an appropriate treatment plan that approaches the case from a multi-disciplinary perspective. Tooth proportions need to be considered in relation to gingival aesthetics and in relation to the facial appearance. It is pointless to make the most beautiful direct veneer if the contours or the texture do not match that of the adjacent teeth or the gingival zeniths are clearly not symmetric and visible. As an example, if we add a tilted occlusal plane or a maxillary tooth midline shift in relation to the facial midline, the results can be frustrating.

Another important aspect is the proper analysis of the patient's smile and display (Figs. 1 & 2). When photographs are taken, people tend to be shy, especially at the beginning and even more so if the person taking the photographs is not a professional photographer and the setting is a dental practice. Figure 3 shows the intra-oral view, where, besides the obvious diastema and the hypomineralised







areas of both central incisors, the major discoloured areas of both mandibular lateral incisors, which were certainly in need of some sort of treatment, are apparent. It is important to try to make a video while conversing with the patient about normal daily issues to avoid overlooking aspects that need

to be considered in the treatment plan. The conversation will relax the patient and evoke natural smiles and laughs in response to something humorous or silly that we might say. Figure 4 shows the differences between the social smile we achieved with our traditional photographs (Figs. 1 & 2) and the

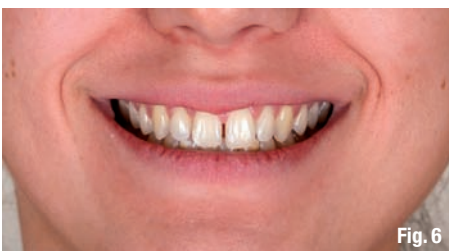

Fig. 6

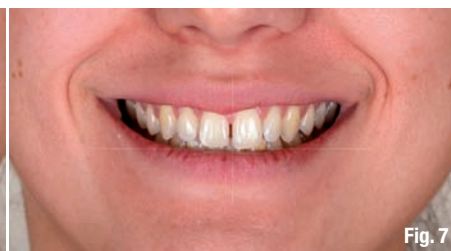

Fig. 7

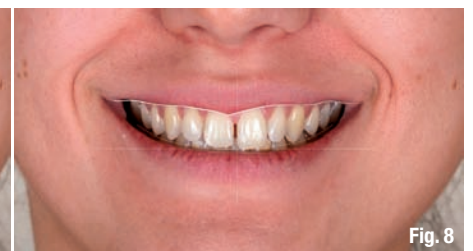

Fig. 8

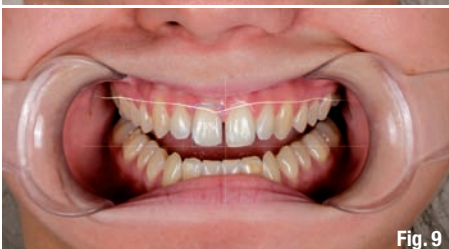

Fig. 9

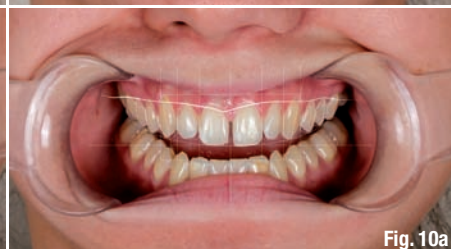

Fig. 10a

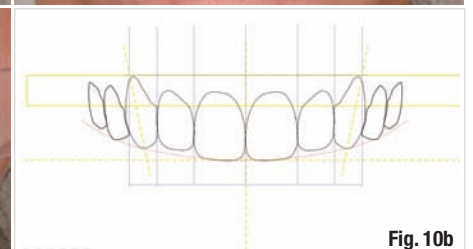


Fig. 10b

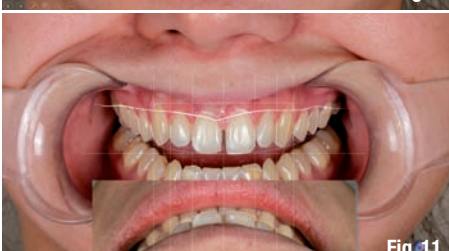

Fig. 11

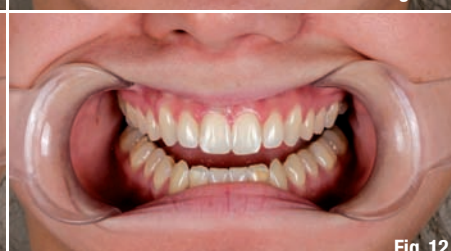

Fig. 12

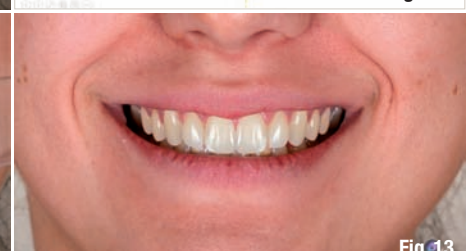

Fig. 13



spontaneous smile, which was captured during dynamic recording. In this particular clinical case, had we based our treatment plan on the social smile photograph, we would have failed to visualise the display of the mandibular incisors, which showed unpleasant stains.

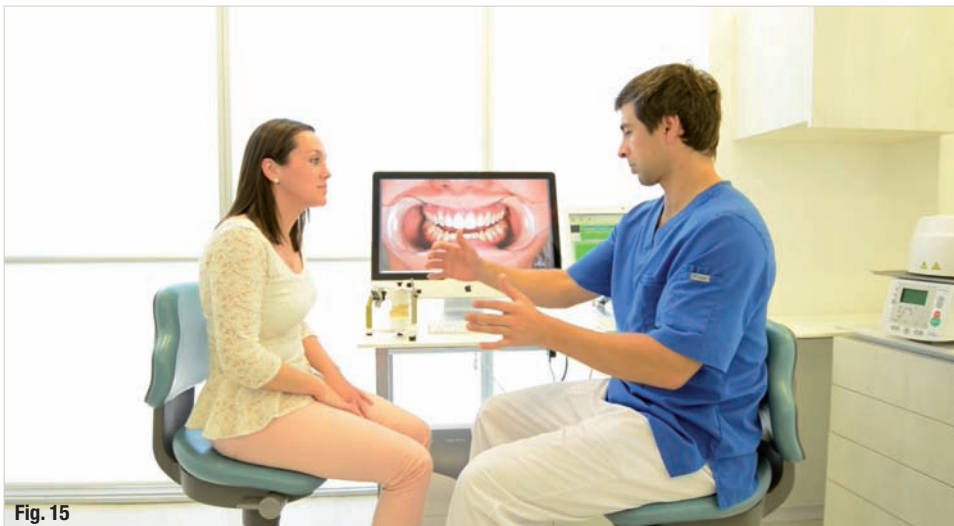The next step was to analyse the patient from the facial perspective based on the details of her teeth. The digital smile design (DSD) concept diagnoses aesthetic problems from a facial perspective and, based on a simplified digital analysis of a few photographs, proposes treatment options and assists with communication between the various specialists in the team.

The first step is to draw a horizontal and a vertical line. The photograph is centred, moved and rotated until the bi-pupillary line is horizontal. The facial midline is subsequently ascertained. Then the same lines are superimposed on to a similar photograph, which has also been centred, but this time taken with lip retractors in place (Figs. 5a–c). The same photographs are then magnified and analysed

(Figs. 6 & 7). The upper lip line is re-created and then superimposed on to the photograph taken with lip retractors in place as reference of its position (Figs. 8 & 9). Then the tooth proportions are measured and their ideal contours are drawn (Figs. 9 & 10a). The isolated situation can be seen in Figure 10b. A photograph taken from the 12 o'clock position is used for the analysis of the labio-palatal position of the teeth and superimposed on to the analysis done previously (Fig. 11).

Once the clinician is clear about the treatment possibilities and limitations, a digitally designed mock-up can be created. This procedure reduces chair time dramatically and increases patient acceptance. Owing to easily accessible software such as Microsoft PowerPoint and Keynote, these effects are easily and quickly created by anyone with minimal training. Recently, new software has been released that simplifies the procedure even more, DSD software for iPads ([www.digitalsmiledesign.com](http://www.digitalsmiledesign.com)). The procedure is based on overlapping certain areas of the teeth in the manner previously described. The result can be seen in detail in Figure 12 and the display in Figure 13. A comparison from the facial perspective between the preoperative situation, the traditional mock-up and the digital mock-up can be seen in Figure 14. Traditional indirect mock-ups are made from a previously created wax-up from the laboratory. First, an impression is taken and a stone cast is then fabricated. Afterwards, the technician waxes the necessary teeth depending on the instructions given by the clinician.

The next step is taking an impression from that wax-up. The excess is removed and a flowable self- or dual-curing composite material (usually bis-acrylic based) is applied to the silicone guide and then placed in the patient's mouth. After a few minutes, the excess is removed and the patient is able to see the changes and the clinician is able to evaluate the proposal directly in the mouth. Generally, photographs are taken of the new situation and analysed. The option of a digital mock-up is much simpler. Once the final forms have been created, a photograph is superimposed on to them, and the texture of the new teeth is created. As seen in Figure 14, the results of the traditional and the digital methods are similar and it is difficult to differentiate between them.





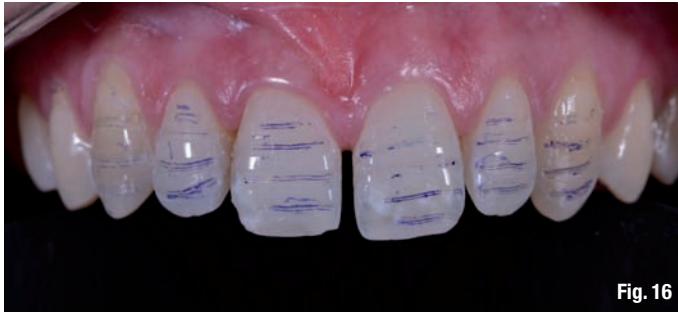


Fig. 16

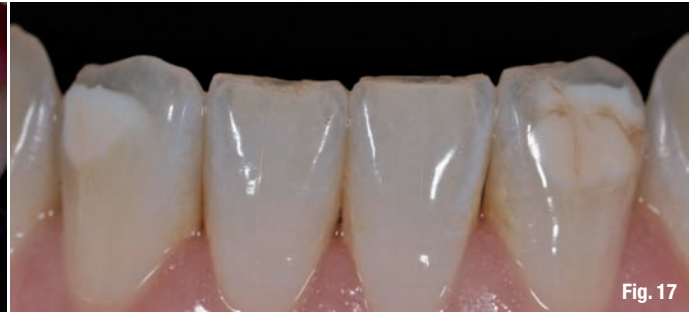

Fig. 17

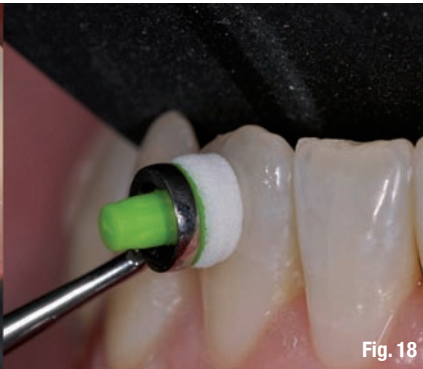
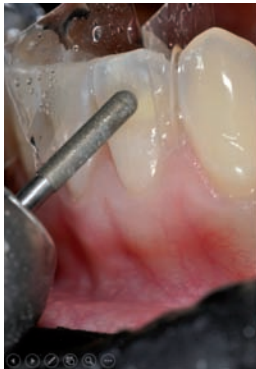
Fig. 18

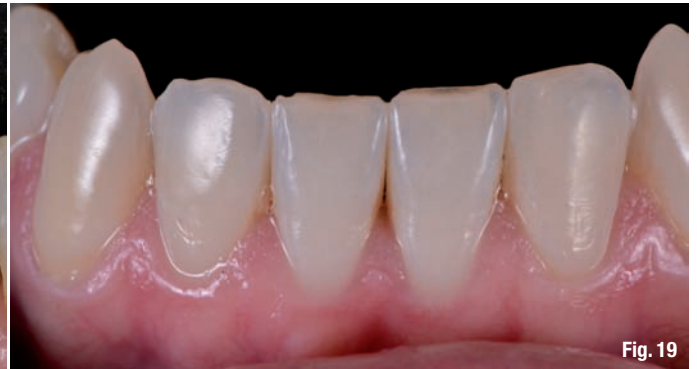

Fig. 19



Fig. 20

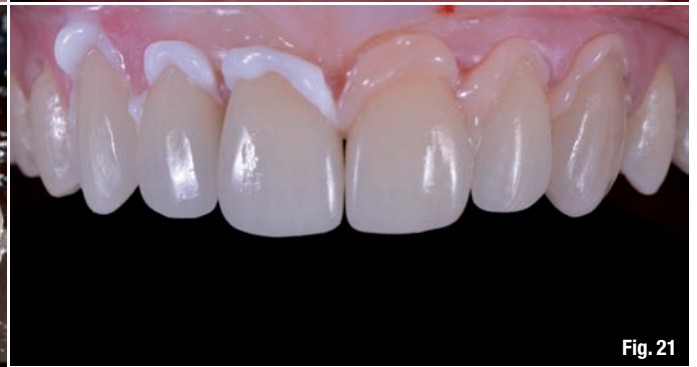

Fig. 21

The protocol is based on photographs and videos that are taken during the first appointment. The analysis is performed, and eventually the case is discussed with the team if necessary. Once the presentation is ready, the treatment plan is presented in a visually attractive way to the patient (Fig. 15). Finally, whether to use ceramic or composite restorative materials is considered depending on different factors. Our philosophy is based on the minimally

invasive concept. As long as we can provide the patient with the same aesthetics, durability and predictability of ceramics, we will select composites. In cases in which many teeth are involved, multiple diastemas are present or occlusal imbalances may jeopardise a successful outcome and major changes need to be made, our choice leans towards ceramics. Whatever approach is chosen, it is of paramount importance for the clinician to understand the ceramic



Fig. 22