


implants

international magazine of oral implantology



research

L-PRF in different
intraoral applications

case report

Polypropylene membrane in
post-extraction alveolar repair

industry

Contaminated implants raise
global concern among dentists

Because time
is precious

Visit us on IDS, we will
guide you through all our
innovations.

SIC invent Group



Raffles with attractive prizes:
FIRST PRIZE 1 x ROLEX



12. – 16.3.2019

**HALL 4.2 AISLE
L 088 / N 089**

Product launch:
SICtapered and
SICvantage® tapered

The new freedom

One drill –
two implant shapes

Define the final
implant type during
osteotomy preparation.



Dr Rolf Vollmer

First Vice President and Treasurer of DGZI



Quality assurance through further training

Dear colleagues,

Especially in the run-up to IDS, implant dentistry is receiving a great deal of attention, as it is one of the crystallisation points for new therapy procedures and innovative products in modern dentistry. In addition to the procedures and products, however, the skill and experience of the dentists is decisive, as is the case in other dental sub-disciplines. The performance of implant treatments requires special training. This is possible in the form of curricula offered by scientific societies, e.g. the German Association of Dental Implantology (DGZI), in which anatomy and complications are taught and discussed in full details. Furthermore, standard techniques such as bone splitting and sinus lift, as well as simple implantations with sufficient bone can be learned in phantom courses.

The German Association of Dental Implantology was one of the pioneers in this field and has been offering corresponding training opportunities for almost 20 years. Personally, I have to state that—especially in recent years—the trend has shifted from conventional prosthetics with a crown or bridge restoration to an implant restoration. Of course, patients should always be informed about alternatives. However, I have to say that most patients' decisions tend towards implant restorations, if financially possible. Especially in the atrophic mandible—where there are practically no alternatives to implantation—patients should always be informed about the possibility of stabilising the prosthesis by implant placement.

In order to deepen these and other relevant topics of modern implantology, DGZI not only organises every year a variety of training events within the framework of various curricula, but also organizes the 49th International Annual Congress of DGZI. This year, at the end of the Oktoberfest season, 4 to 5 October 2019, the congress will be held in Munich, Germany. This so-called “2nd Future Congress” will take place under the motto “Perio-Implantology: Implants, Bone & Tissue—Where are we today and where are we headed?” With practical table clinics on Friday and a top-class scientific lecture programme on Saturday, the implantological advanced training will be realised at the highest level.

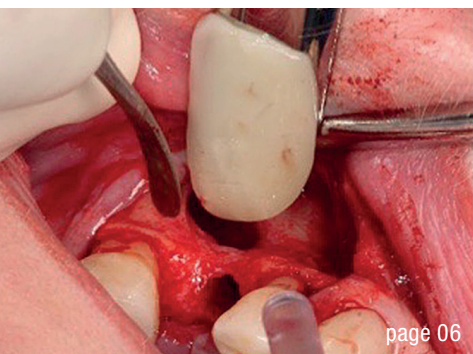
Until then, I hope you enjoy reading the new *implants—international magazine of oral implantology* and would like to draw your attention to the contents relevant to continuing education that our colleagues have once again made available to us in the form of professional articles.

At IDS in Cologne, Germany, DGZI will be located in Hall 11.2, Booth L060, thanks to our long-standing co-operation partner OT medical.

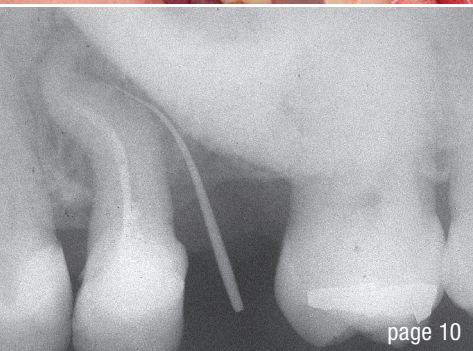
Yours,

A handwritten signature in black ink, appearing to read 'R. Vollmer'.

Dr Rolf Vollmer



page 06



page 10



page 16

Cover image courtesy of
TBR Dental Group
www.tbr.dental



editorial

- Quality **assurance** through **further training** 03
Dr Rolf Vollmer

research

- L-PRF** in different intraoral **applications** (Part III) 06
Prof. Nelson R. Pinto, Dr Andy Temmerman, Ana B. Castro,
Simone Cortellini, Prof. Dr Wim Teughels & Prof. Dr Marc Quirynen

case report

- Polypropylene membrane in **post-extraction alveolar repair** 10
Drs Irineu Gregnanin Pedron & Munir Salomão

industry

- Contaminated implants** raise global **concern** among dentists 16
Dr Dirk U. Duddeck

interview

- Creating **unique smiles** with the **Z1** implant system 20
Confidence beyond **immediacy** 24
Dynamic Navigation: **Closing the gap** between planning and execution 28
“**It is fantastic** to have implants as a treatment option” 30

events

- LCI's **Full Immersion Training** will transform your **practice** 40
Ceramic implants—Game changer in **implant dentistry** 42
A **new chapter** in implant dentistry 44
“**Confidence in You**” contest to mark **BLX implant system** launch 45

news

- manufacturer news 32
news 48

about the publisher

- imprint 50

MAKE NO BONES ABOUT IT.

CONFIDENCE IN ALL BONE QUALITIES:
PROGRESSIVE-LINE



SPECIALIST IN SOFT BONE:

- Apical conical area for high primary stability in soft bone
- Thread up to the apex, ideal for immediate implantation
- Thread design with deeply engaging thread flanks
- Flexible drill protocol for preferred stability

**IDS 2019
HANDS-ON**
HALL 11.3
BOOTH A010 / B019

WWW.CAMLOG.COM

a perfect fit™

camlog

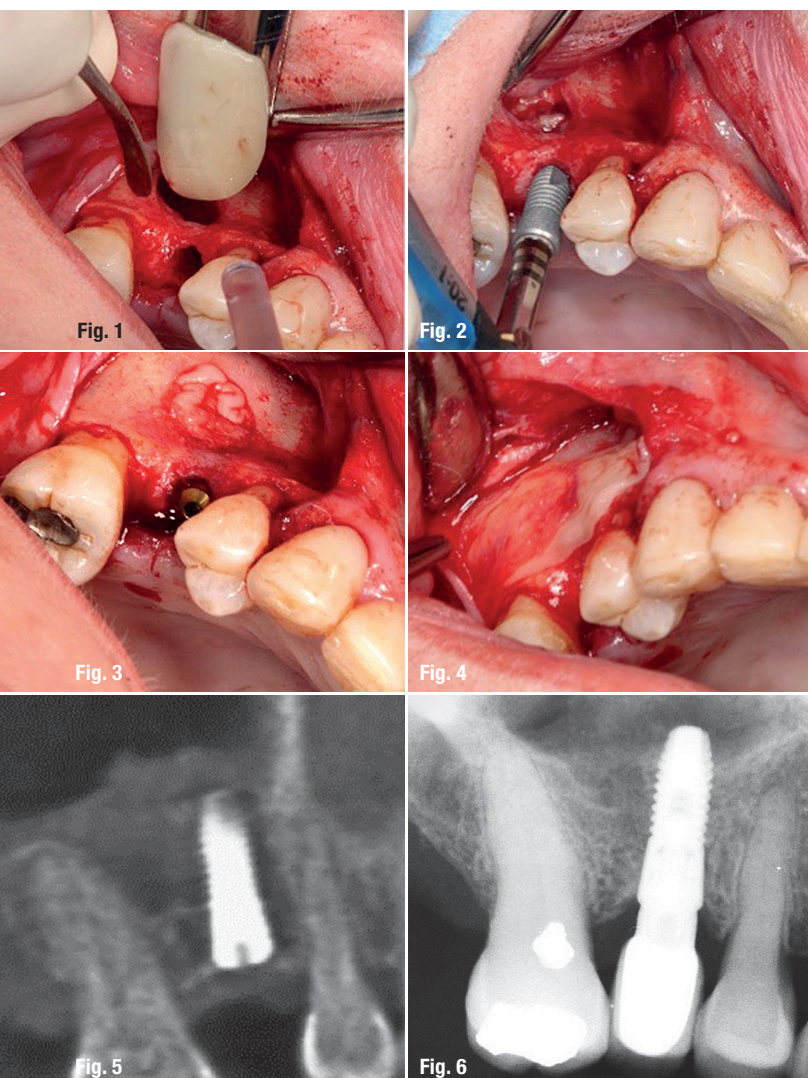
L-PRF in different intraoral applications

Part III: L-PRF in sinus floor elevation

Prof. Nelson R. Pinto¹, Dr Andy Temmerman², Ana B. Castro², Simone Cortellini², Prof. Dr Wim Teughels² & Prof. Dr Marc Quirynen²

¹ Department of Periodontology and Oral Implantology, Faculty of Dentistry, Universidad de Los Andes, Santiago, Chile

² Department of Oral Health Sciences, Section of Periodontology, KU Leuven & Dentistry, University Hospitals, KU Leuven, Leuven, Belgium



Approach 1: Lateral window technique – Fig. 1: After careful preparation of the osteotomy, L-PRF membranes are placed to cover the Schneiderian membrane (at least three layers). **Fig. 2:** Implant placement. **Fig. 3:** Additional L-PRF membranes are placed around the implant. **Fig. 4:** The window is covered with L-PRF membranes (at least two layers). **Fig. 5:** CBCT scan immediately after surgery. **Fig. 6:** Radiograph after one year.

Leukocyte- and platelet-rich fibrin (L-PRF) accelerates wound healing in both soft and hard tissue significantly. Major indications for the use of L-PRF and the step-by-step preparation of L-PRF clots, membranes and plugs, as well as application approaches to open-flap debridement and ridge preservation, were introduced in the first two parts of this article series. In this third part of the series, two treatment approaches to sinus floor elevation will be presented. The first option is the application of the lateral window technique and the use of L-PRF as grafting material. The second approach described below is the transalveolar technique, an alternative to the lateral window technique.

Lateral window technique

The lateral window technique is a minimally invasive approach to surgical access. The clinical procedure provides lateral access to the maxillary sinus with a minimally invasive osteotomy. An incision of relatively small dimensions is made with regular lines to delimit a rectangular shape, and convergent incisions in the cavity direction, resulting in a true chamfer. This surgical approach creates sinus access by detaching the Schneiderian membrane from the sinus floor and placing bone grafting materials into the sinus cavity in order to promote bone augmentation. Local infiltrative anaesthesia in the buccal and palatal regions of the surgical area is administered prior to the surgical procedure. The technique is considered quite successful, even with the use of different types of grafting materials and implants.

Step-by-step approach to sinus floor elevation via the lateral window technique

Elevation of the sinus floor was achieved in the case demonstrated by employing the lateral window technique. The implant was placed simultaneously using L-PRF as sole grafting material.

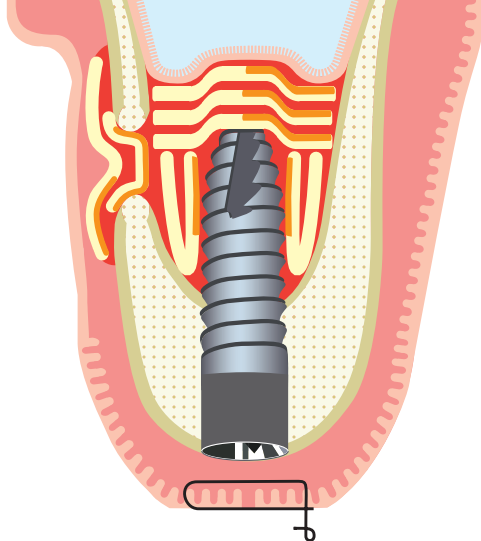


Fig. 7: Final situation after surgery using the lateral window approach with immediate implant placement using L-PRF. At the end of the procedure, the window is sealed with at least two layers of L-PRF membranes.

- Closure of the flap without moving the L-PRF membranes.
- Suture with a monofilament, non-resorbable thread (Fig. 5).

Postoperative care

- Flying, diving or using wind instruments is forbidden for at least six weeks.
- Forceful sneezing should be prevented for at least six weeks.
- Sufficient painkillers, systemic antibiotics, a nose spray and corticosteroids (the last for three days, for example) should be prescribed if needed.
- After four to six months of healing, the abutment can be placed and loaded if the implant has integrated well.
- A control radiograph should be taken at the one-year check-up (Figs. 6 & 7).

Transalveolar technique

The transalveolar approach to sinus floor elevation can be chosen for the subsequent placement of dental implants. This approach to sinus floor elevation is considered less invasive than the lateral window technique. It can be employed in the case of reduced residual bone height (of more than 4mm) in a patient that does not allow for the conventional placement of implants. After the treatment, patients are often advised to take antibiotics, when grafting materials were used, and to perform antiseptic rinses in order to prevent perforation of the Schneiderian membrane or possible postoperative infections. Successful treatment outcomes of the transalveolar technique have been reported with and without the use of grafting materials.

Step-by-step approach to sinus floor elevation via the transalveolar technique

Elevation of the sinus floor was achieved in the case demonstrated by employing the transalveolar technique. The implant was placed simultaneously using L-PRF as sole grafting material.



Shortest Implants – Longest History.

Think Short!

For more than 30 years Bicon® short implants are unchanged in clinical use.

According to the 11th European Consensus Conference (EuCC) 2016 in Cologne, provided the specific treatment parameters are observed, the use of short, angulated or diameter-reduced implants in sites with reduced bone volume can be a reliable treatment option, given the risks associated with the use of standard-dimension implants in combination with augmentation procedures.

For more Information:

Bicon Europe Ltd.

Dietrichshöhe 2

55491 Buechenbeuren

Germany

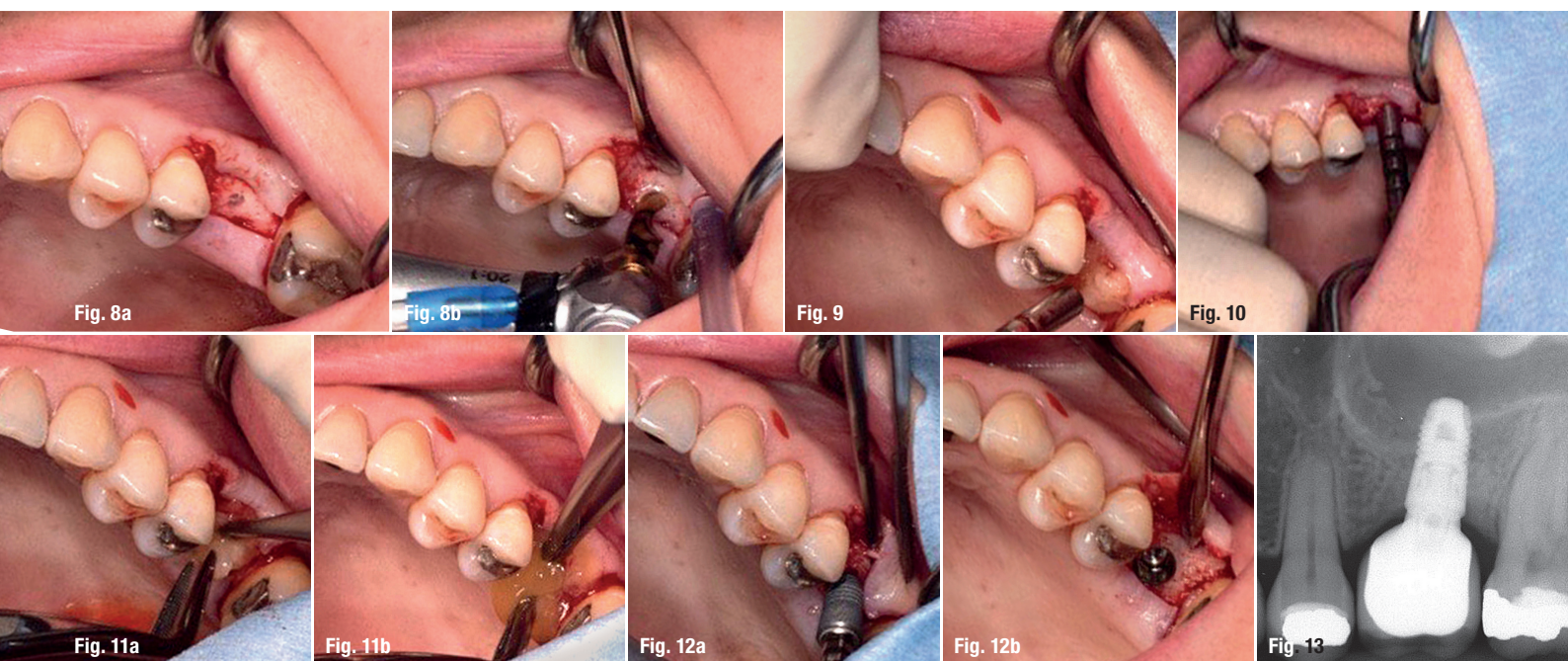
Phone +49 (0)6543 818200

germany@bicon.com

www.bicon.de.com



bicon
DENTAL IMPLANTS



Approach 2: Transalveolar technique – Figs. 8a & b: Osteotomy preparation at a distance of up to 1 mm from the Schneiderian membrane. **Fig. 9:** Placement of one L-PRF membrane into the osteotomy site as a cushion for the osteotomes. **Fig. 10:** Fracturing of the remaining sinus floor with osteotomes. **Figs. 11a & b:** Elevation of the Schneiderian membrane by inserting several (four or more) L-PRF membranes. **Figs. 12a & b:** Implant placement. **Fig. 13:** Radiograph after one year. **Fig. 14:** Final situation after surgery using the trans-alveolar approach to sinus augmentation. Several L-PRF membranes separate the Schneiderian membrane from the apex of the implant and fill the space between the implant and the augmented sinus.

Protocol for the transalveolar technique

- Crestal incision and one or two optional releasing incisions.
- Folding back of the full-thickness flap in order for the crestal bone to be exposed.
- Osteotomy site preparation at a distance of up to 1 mm from the Schneiderian membrane (different techniques can be applied; Figs. 8a & b).
- Placement of one L-PRF membrane into the osteotomy site, which then acts as a cushion for the osteotomes used in the next step (Fig. 9).
- Careful fracturing of the remaining sinus floor with osteotomes (Fig. 10).
- Elevation of the Schneiderian membrane by carefully inserting several L-PRF membranes (one at the time) into the sinus via osteotomy with the use of osteotomes. At least four L-PRF membranes should be placed into the sinus (Figs. 11a & b), since generally at least four membranes are needed for one implant.
- Implant insertion (Figs. 12a & b).
- Suturing with a monofilament non-resorbable thread.

Postoperative care

- Flying, diving or using wind instruments is forbidden for at least six weeks.
- Forceful sneezing should be prevented for at least six weeks.

- Sufficient painkillers, systemic antibiotics, a nose spray and corticosteroids (the last for three days, for example) should be prescribed if needed.
- After four to six months of healing, the abutment can be placed and loaded if the implant has integrated well.
- A control radiograph should be taken at the one-year check-up (Figs. 13 & 14).


Editorial note: The fourth and last part of this article will be published soon. It will cover application approaches to implant coating with L-PRF, gingival recession coverage and the preparation of L-PRF blocks.

contact

Prof. Dr Marc Quirynen


University Hospitals Leuven
Periodontology & Oral Microbiology
Kapucijnenvoer 7 blok a – box 7001
3000 Leuven, Belgium
Phone: +32 163 32483
marc.quirynen@kuleuven.be

Author details





The unique Tissue Level Implant with Zirconia Collar



Aesthetic
gingival area

Zirconia collar

Gingival integration
& Osseointegration

Bone area

Pure Titanium body

Z1[®] Implant Giving you confidence in implantology.

Proven Technology

- ✓ 98.6%* success rate
- ✓ Pure Titanium and Y-TZP Zirconia
- ✓ Suitable for all prosthetic solutions

Proven clinical outcomes for patient safety

- ✓ Anti-bacterial shield
- ✓ Ideal in fresh extraction sockets
- ✓ Immediate aesthetic result

Proven economics for a profitable implant practice

- ✓ Reduced chairtime
- ✓ Practice development
- ✓ Patient satisfaction

Proven surgical protocols for a simplified workflow

- ✓ Only 1 surgery
- ✓ No healing abutment
- ✓ Visibility of the connection

**IDS
2019**

Join us
Hall 4.1
Booth A58



Find us online
www.tbr.dental


Unique, like your smile

*Z1 implants are medical devices of class IIb manufactured by SÜNAMANT S&S. Information taken from the data of the Sintering quality program based on 15,534 patients with Z1 implants from 01/2014 to 07/2016.